



Case report

Renal hilar pheochromocytoma: a case report

Youness Ahallal^{1*}, Mohammed Fadl Tazi¹, Hind Elfatemi², Kaoutar Znati², Elmehdi Tazi³, Afaf Amarti², Mohammed Jamal El Fassi¹ and Hassan Farih M H Moulay¹

Addresses: ¹Department of Urology, Hassan II Teaching Hospital, Fez, Morocco, ²Department of Pathology, Hassan II Teaching Hospital, Fez, Morocco and ³National Institute of Oncology, IbnSina Teaching Hospital, Rabat, Morocco

Email: YA* - dryouness@gmail.com

* Corresponding author

Received: 5 March 2009 Accepted: 15 June 2009 Published: 29 June 2009

Cases Journal 2009, 2:6416 doi: 10.4076/1757-1626-2-6416

This article is available from: <http://casesjournal.com/casesjournal/article/view/6416>

© 2009 Ahallal et al; licensee Cases Network Ltd.

This is an Open Access article distributed under the terms of the Creative Commons Attribution License (<http://creativecommons.org/licenses/by/3.0>), which permits unrestricted use, distribution, and reproduction in any medium, provided the original work is properly cited.

Abstract

Paraganglioma is a rare tumor arising from undifferentiated cells of the primitive neural crest. These tumors are most commonly found in the adrenal gland, other localisations are also possible. A 58-year-old woman who presented with history of left lumbar pain, headache, hypertension, palpitation and sweating was found to have a secreting left renal hilar pheochromocytoma. Radical excision of the tumor was therefore undertaken and her hypertension was controlled. From the case report and literature review, the authors suggest a diagnostic and therapeutic strategy for the management of ectopic localization of pheochromocytoma.

Introduction

Pheochromocytoma is a neuroendocrine tumor that usually develops upon the chromaffin cells of the adrenal medulla. Extraadrenal retroperitoneal paragangliomas arise from paraganglia, which are collections of specialized neural crest cells symmetrically distributed along the aorta in close association with the sympathetic chain. The usual signs are lumbar pain, hypertension associated with generalized symptoms due to raised catecholamines such as headache, blurred vision, heart palpitation and flushing. However, 40% of the retroperitoneal pheochromocytomas don't feature any hormonal activity [1].

Following an observation of a renal hilar pheochromocytoma together with a review of the literature, this paper

aims at reminding the clinical, therapeutic and histological features of this rare tumor.

Case presentation

The patient, a 58-year-old Moroccan housewife, suffered from a 5 year history of left lumbar pain, headache, hypertension, palpitation and sweating. During the physical examination, her blood pressure showed a 200/150 mmHg; she also had a mass in the left subcostal region. The rest of the physical examination was normal. Ultrasonography performed on the patient revealed a 6 cm size heterogeneous mass located in the region of the left renal hilum and an additional computed tomography of the abdomen demonstrated a dumbbell-shaped tumor, measuring 7.0 × 6.5 × 7.5 cm, in the left renal hilum and

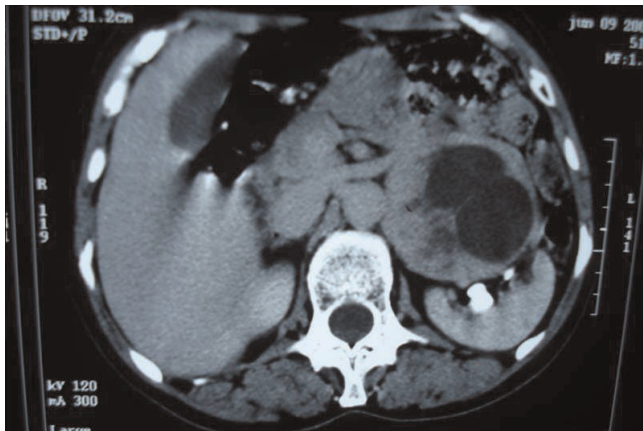


Figure 1. CT scan at level of left renal vein shows a heterogeneous soft-tissue mass.

surrounding the left renal vein with a heterogeneously increasing density after injection of iodine-containing contrast solution. Both adrenal glands were normal with a negative extension summary (Figure 1). Levels of catecholamine metabolites (metanephrine and normetanephrine) in 24-hour urine samples were elevated. The usual paraclinic examinations didn't display any anomaly. The patient underwent preoperative blockade with phenoxybenzamine, atenolol and metyrosine for 2 weeks.

Transperitoneal laparotomy has been therefore performed on the patient; a circumferential dissection of the hilar lesion demonstrated a smooth tumor surrounding the left renal vein (Figure 2). Radical excision of the tumor was undertaken. Pathological examination demonstrated

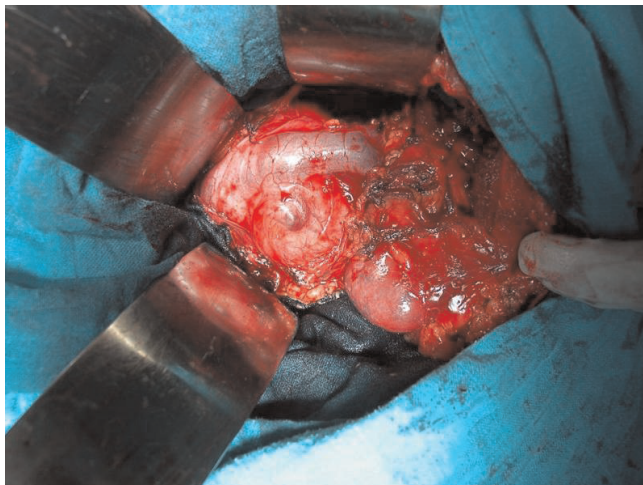

Figure 2. Intraoperative view showing a mass located behind the renal vein.

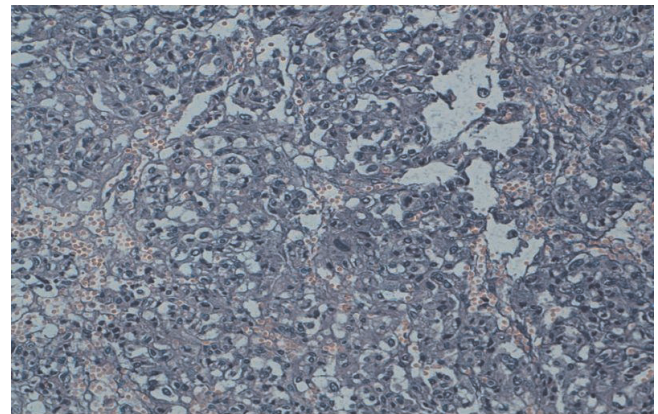


Figure 3. Tumoral proliferation with lobular architecture associated to endocrine vascularisation. (HES × 20)

a pheochromocytoma and the surgical margins of the excised specimen were free of tumor (Figures 3 and 4). The patient's postoperative recovery was smooth and without complications. At the 3-month follow-up, her hypertension was controlled and the urinary catecholamine levels were normal.

Discussion

Pheochromocytoma develops from the germinal cells coming from the neural crest, and is usually an adrenal tumor. Paragangliomas of the retroperitoneum arise from specialized neural crest cells distributed along the aorta in association with the sympathetic chain. Men are affected more frequently than women, and most patients are between the ages of 30 and 40 years [2,3].

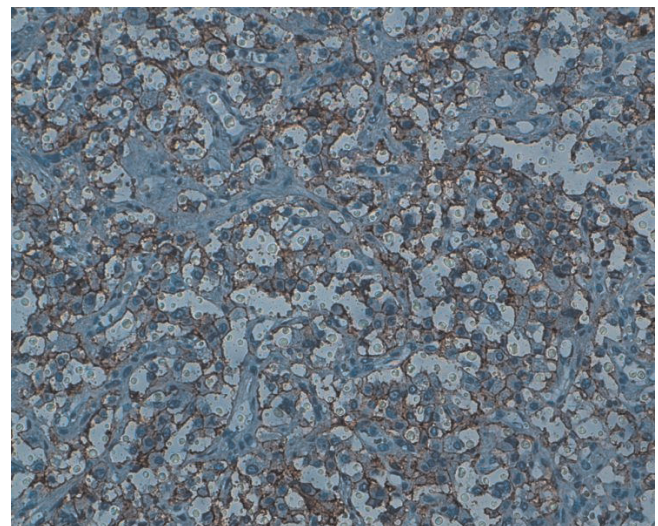


Figure 4. Tumoral cells showing a positive immunostaining for anti-CD56 antibody.

Paragangliomas can be detected early if clinical findings caused by excess secretion of catecholamines are present. The literature states that extraadrenal retroperitoneal paragangliomas are functional for 60% of patients at most [1,3,4]. Characteristic symptoms are sharp headaches, hypertension, palpitation and sweating. For those patients with nonfunctional extraadrenal retroperitoneal paragangliomas, diagnosis usually depends on nonspecific factors related to the growth of a retroperitoneal mass [1,5,6]. The lumbar pain is one of the suggesting signals. The clinical examination can put the light on a lumbar mass. The above mentioned clinical table imposes a measurement of catecholamines and catecholamine metabolites (metanephrine and normetanephrine) in plasma and 24-hour urine samples.

60% of the retroperitoneal pheochromocytomas display signs of hormonal activity; however the hormonal measurement can sometimes be normal [1,3,4].

With regards to the patient mentioned above, the urinary catecholamines measurement was elevated and the radiological diagnosis performed via ultrasonography and computed tomography (CT) maintain the tissue nature of the tumor, which increase its density after iodine contrast solution injection. These two examinations give the opportunity to also seek for concomitant locations, as well as potential ganglionic or visceral metastasis. Computerized tomography is considered as the investigation of choice for demonstrating retroperitoneal structures; it might define the location, extent and nature of these tumors, and may also demonstrate infiltration into surrounding tissues, which provides essential information as to whether the tumor is respectable [7]. Correlation of symptoms and laboratory values of catecholamines is the most efficient way of identifying a soft-tissue retroperitoneal mass, in case it was detected by CT as an extraadrenal retroperitoneal paraganglioma. With non-functional paragangliomas, the CT features of extraadrenal paragangliomas overlap those of other retroperitoneal neoplasms, and the diagnosis is more difficult [8]. Percutaneous aspiration cytology may be performed under computerized tomography guidance to obtain a preoperative tissue diagnosis.

The Magnetic Resonance Imaging (MRI) is a very reliable examination that can also detect other localizations despite their small size. Thanks to an outstanding characterization of the tissues, especially at the level of the retroperitoneum and the vascular axes, the added value of the MRI is greater than the one of the CT in the evaluation of the paragangliomas [9]. In order to enhance the diagnosis and the localization of the paragangliomas, a new imaging method has been recently brought forth, using the iodine-131-MIBG scanning [10]. This

examination has a sensitivity of 78% to the adrenal pheochromocytoma, and varies in the range from 67% to 89% when it comes to extra-adrenal localizations. It also takes all sense when several localizations are investigated and for the purpose of bone metastasis detection. Its use is very limited though, because of its high cost. The preponderant location of extraadrenal retroperitoneal paraganglioma was infrarenal, as described in previous reports [1,3]. This area, known as the organ of Zuckerkandl, encompasses all chromaffin-cell-bearing tissue along the lower abdominal aorta, its bifurcation, and the iliac vessels [4]. 2 cases of that location of the tumor as reported in our case in the left renal hilum has been already described in the literature.

The treatment of the retroperitoneal pheochromocytoma is solely surgical and the patient preparation is a necessary step and covers a preoperative treatment with α - and β -blocking agents. The treatment of choice is radical excision of the tumor: Krugger-Baggesen et al. reported that out of 15 patients who had undergone a radical operation, none had died of the disease; one patient had nonetheless recurrent disease 7 years later [11]. Radiotherapy and chemotherapy have limited effectiveness.

A long term follow up with regular biological and clinical examinations is necessary, in order to detect any recurrence or metastasis. From a histological perspective, the usual criteria of malignancy have no ground, but the appearance of a metastasis is a sign of malignancy.

Paragangliomas are slow-growing tumors which metastasize late. Long-term survival is expected even with extensive local invasion. Radical excision should therefore be attempted, and if achieved, a good prognosis can be given.

Conclusion

The renal hilar pheochromocytoma is a rare tumor. Its diagnosis is suspected in the presence of paroxysmal hyper blood pressure paired with a lumbar mass. The treatment of choice of those uncommon tumors is the radical excision that benefits from a good prognostic.

Abbreviations

CT, Computer tomography; MRI, Magnetic resonance imaging.

Consent

Written informed consent was obtained from the patient for publication of this case report and accompanying images. A copy of the written consent is available for review by the Editor-in-Chief of this journal.

Competing interests

The authors declare that they have no competing interests.

Authors' contributions

YA analyzed and interpreted the patient data regarding the retroperitoneal disease. MFT and ET have made contributions to conception and design, and acquisition of data. EH, ZK and AA performed the histological examination of the kidney, and was a major contributor in writing the manuscript. MJE have been involved in drafting the manuscript and revising it critically for important intellectual content. MHF have given final approval of the version to be published. All authors read and approved the final manuscript.

References

1. Lack EE, Cubilla AL, Woodruff JM, Lieberman PH: **Extraadrenal paragangliomas of the retroperitoneum: a clinicopathologic study of 12 tumors.** *Am J Surg Pathol* 1980, **4**:109-120.
2. Mikhail RA, Moore JB, Reed DN Jr, Abbott AR: **Malignant retroperitoneal paragangliomas.** *J Surg Oncol* 1986, **32**:32-36.
3. Kryger-Baggesen N, Kjaergaard J, Sehested M: **Nonchromaffin paraganglioma of the retroperitoneum.** *J Urol* 1985, **134**: 536-538.
4. Melicow MM: **One hundred cases of pheochromocytoma (107 tumors) at the Columbia-Presbyterian Medical Center, 1926-1976: a clinicopathological analysis.** *Cancer* 1977, **40**:1987-2004.
5. Law NW, Alfano L: **Non-functioning retroperitoneal paraganglioma.** *J R Soc Med* 1987, **80**:246-247.
6. Kryger-Baggesen N, Kjaergaard J, Sehested M: **Nonchromaffin paraganglioma of the retroperitoneum.** *J Urol* 1985, **134**: 536-538.
7. Patel YD, Morehouse HT: **Malignant paragangliomas of the retroperitoneum: value of computerised tomography and angiography.** *Clin Radiol* 1984, **36**:185-188.
8. Hayes WS, Davidson AJ, Griley PM, Hartan DS: **Extraadrenal Retroperitoneal Paraganglioma: Clinical, Pathologic, and CT Findings.** *AJR Am J Roentgenol* 1990, **776**:471-473.
9. Whalen RK, Althausen AF, Daniels GH: **Extra-adrenal pheochromocytoma.** *J Urol* 1992, **147**:1-10.
10. Tissaoui K, El Kamel R, Zidi B, Ben Hamadi F, Karray S, Berraies N, Ben Moussa M: **A propos d'une observation de phéochromocytome vésical.** *Prog Urol* 1992, **2**:253-257.
11. Kryger-Baggesen N, Kjaergaard J, Sehested M: **Nonchromaffin paraganglioma of the retroperitoneum.** *J Urol* 1985, **134**: 536-538.

Do you have a case to share?

Submit your case report today

- Rapid peer review
- Fast publication
- PubMed indexing
- Inclusion in Cases Database

Any patient, any case, can teach us something



**CASES
NETWORK**

www.casesnetwork.com