

## Customized laser vision correction for irregular cornea post-refractive surgery

Rohit Shetty, Vaitheeshwaran Ganesan Lalgudi, Luci Kaweri<sup>1</sup>, Urvija Choudhary<sup>2</sup>, Aishwariya Chabra<sup>1</sup>, Krati Gupta, Pooja Khamar<sup>1</sup>

Ablation-related complications following the refractive procedures are a major challenge for a refractive surgeon, considering the elective nature of the procedure. The use of topography-guided customized ablation has revolutionized the management of irregular corneas postrefractive surgery. This preferred practice highlights various hurdles encountered while managing cases of decentered ablation, small ablation zones, and planning a cataract surgery in patients with irregular corneas. It will give insight to the refractive surgeon on the planning of corneal regularization on various modern-day refractive platforms available, such as the WaveLight®EX-500 (Alcon Laboratories, Inc., Fort Worth, TX, USA), Schwind Amaris 1050 (Peramis; SCHWIND eye-tech-solutions, Kleinostheim, Germany), and Technolas Teneo 317 model 2 excimer laser (Bausch & Lomb, Rochester, NY, USA). The algorithmic approach outlined will enable the refractive surgeon to choose between the wavefront optimized and the topography-guided ablations.

Access this article online

Website: [www.ijo.in](http://www.ijo.in)

DOI:

10.4103/ijo.IJO\_2793\_20

Quick Response Code:



**Key words:** Decentered excimer laser ablations, irregular cornea, small zone ablation, TCAT

Refractive error is a leading cause of reversible visual impairment worldwide across all ages.<sup>[1]</sup> Refractive surgical procedures (laser or nonlaser) are being used to correct refractive errors since their genesis approximately 25 years ago and have reduced the dependency on spectacles and contact lenses. Among these procedures, excimer laser refractive surgery has been the mainstay of treatment. It corrects refractive errors by ablating, thus reshaping the cornea.<sup>[2]</sup> Since the invention of the laser machines, the technology as well as the treatment nomograms has been through constant improvement. As a result, the laser surgeries done in the past using the older generation excimer lasers have sometimes reported postoperative corneal irregularities.<sup>[3]</sup> Postrefractive surgery corneal irregularities comprise of central islands, smaller optical zones, and decentered ablations and were associated with visual impairment, ghosting symptoms, or night vision problems due to the induced higher order aberrations (HOAs), and these can compromise the vision quality.<sup>[4,5]</sup>

### Decentered Ablation

An accurate centration of the ablation zone over the entrance pupil is the cornerstone of a successful laser vision correction. An ablation is eccentric when its center does not correspond to the center of the optical axis.<sup>[6]</sup> Decentration can occur

due to causes such as the pupil not dilating or constricting symmetrically, the amount of myopia, the learning effect, saccadic eye movements, misalignment of patient's head relative to the laser and optics or centration aids in the laser, deviation of the visual axis from mid-pupil, poor laser beam homogeneity, nonhomogeneous corneal hydration, misalignment of the suction ring over the center of the pupil, and a malfunctioning tracking system.<sup>[7]</sup>

Low amount of decentration of 0.5–1.0 mm affects low-contrast visual acuity and induces higher-order aberrations, whereas decentration of more than 1.0 mm (significant decentration) causes highly compromised visual performance. The corneal meridian connecting the ablation zone center to the pupil center is the most affected as it lies in the transition zone between the maximal to the minimal dioptric powers.

Decentered ablation pattern seen in corneal topography maps helps in the confirmation of the diagnosis.<sup>[6,8]</sup> The incorporation of the active eye-tracking systems, technology such as iris registration that uses corneal limbus as a reference point to guide laser ablation and larger ablation zones have helped in limiting decentrations to less than 1 mm. Rigid contact lenses have been the mainstay of visual rehabilitation for decentrations. Till date, arcuate cuts and laser photo ablative techniques, such as diametral ablation, masked ablations through collagen-based lenticules, and the Nizzola

Departments of Cornea and Refractive Surgery and <sup>1</sup>Cataract and Refractive Surgery, Narayana Nethralaya, Bengaluru, Karnataka, <sup>2</sup>Consultant Refractive, Cornea and Cataract, Rajas Eye Hospital and Retina Research Centre, Indore, Madhya Pradesh, India

**Correspondence to:** Dr. Pooja Khamar, Consultant, Cataract and Refractive Surgery, Narayana Nethralaya, 121/c, West of Chord Road, Rajajinagar, Bengaluru, Karnataka, India. E-mail: [dr.poojakhamar@gmail.com](mailto:dr.poojakhamar@gmail.com)

Received: 27-Aug-2020

Revision: 19-Sep-2020

Accepted: 02-Oct-2020

Published: 23-Nov-2020

This is an open access journal, and articles are distributed under the terms of the Creative Commons Attribution-NonCommercial-ShareAlike 4.0 License, which allows others to remix, tweak, and build upon the work non-commercially, as long as appropriate credit is given and the new creations are licensed under the identical terms.

**For reprints contact:** [WKHLRPMedknow\\_reprints@wolterskluwer.com](mailto:WKHLRPMedknow_reprints@wolterskluwer.com)

**Cite this article as:** Shetty R, Lalgudi VG, Kaweri L, Choudhary U, Chabra A, Gupta K, *et al.* Customized laser vision correction for irregular cornea post-refractive surgery. *Indian J Ophthalmol* 2020;68:2867-79.

and Vinciguerra technique have been adopted for surgical management of decentered ablations when the option of contact lens fails.<sup>[9]</sup> Topography-guided customized ablation by excimer laser is a potentially effective technique for treating decentrations and irregular astigmatism.<sup>[6,8,10]</sup>

## Small Ablation Zone

Small diameter of the optical zone post kerato-refractive surgery results in compromised visual function, halos, and glare in mesopic conditions and monocular diplopia in some cases especially in myopic ablations for over 7 diopters sphere.<sup>[6,10]</sup> In the era of first- and second-generation laser machines, the ablation diameter used to be decreased relative to the maximum pupil diameter in dim illumination for treatment of moderate to high myopia and in corneas with central thickness less than 500  $\mu\text{m}$ . By reducing the ablation zone to a maximum of 0.75 mm less than the pupil diameter, the depth of ablation could be decreased by 20–25%, thus reducing the percentage tissue altered and thereby the probability of postsurgical ectasia.<sup>[11]</sup> However, the diameter of the pupil being larger than the optical treatment zone results in the rays of light refracted by the untreated peripheral cornea not getting focused at the same point as the central rays, thus resulting in blurred circles that cause glare and halos in mesopic conditions. In addition, correction of higher refractive errors can be associated with increase in HOAs, due to a larger refractive differential between the ablated and intact cornea.<sup>[11]</sup> Thus, by treatment of high myopia using a small optical ablation zone, there can be reduction in the quality of vision, mainly in scotopic conditions.<sup>[12]</sup> These symptoms have been conservatively managed with mild miotics or topical brimonidine, which help in driving at night. Tinted contact lenses with artificial pupils provide significant symptom free periods too. A well-centered rigid gas permeable (RGP) contact lens is also helpful in certain conditions.<sup>[11]</sup>

**Topography-guided enlargement** of the ablation zone has been shown to be more effective in improving corneal surface regularity, thus reducing patient symptoms. Improvement in topographic optical zone resulted in reduction in HOAs, with a 53% reduction in coma and 44% reduction in spherical aberration (SA), that aided in significant improvement in subjective night vision disturbances.<sup>[8]</sup>

Therefore, in order to improve the visual outcomes of eyes with corneal irregularities, topo-guided ablation to regularize the cornea was considered. Regularization of the cornea prior to cataract also results in better visual outcome. The recently introduced spot scanning excimer laser performs ablation of any precise location on the cornea, which on combining with the corneal topography enables us to perform topographically guided customized ablation.<sup>[4]</sup> This topography-guided customized ablation treatment (TCAT) has helped to improve visual acuity and quality in eyes with irregular corneal topographies. TCAT when performed before cataract surgery also aided in obtaining good post-operative visual outcome.<sup>[3]</sup>

Management of highly aberrated cornea and decentered ablation using the topography-guided ablation on the WaveLight ALLEGRETTO platform and custom topographic neutralizing technique was described by Lin *et al.* in 2008.<sup>[13]</sup> The same protocol has also been used for the management of flap complication in laser *in situ* keratomileusis and as a basis for planning the TCAT procedure.<sup>[14]</sup>

This preferred practice highlights various commonly encountered hurdles while managing cases of decentered ablation, small ablation zone, and planning a cataract surgery in patients with irregular corneas. It will give insight to the refractive surgeon on planning the corneal regularization on various modern-day refractive platforms available such as the WaveLight®EX-500 (Alcon Laboratories, Inc., Fort Worth, TX, USA), Schwind Amaris 1050 (Peramis; SCHWIND eye-tech-solutions, Kleinostheim, Germany), and Technolas Teneo 317 model 2 excimer laser (Bausch & Lomb, Rochester, NY, USA). The algorithmic approach outlined will enable the refractive surgeon to choose between the wavefront-guided and topo-guided ablation options.

## Case 1

A 35-year-old female visited us with complaints of diminution of vision, glare, haloes, and starbursts for the preceding 10 years. She gave a history of undergoing photorefractive keratectomy (PRK) 10 years back elsewhere. The best corrected visual acuity (BCVA) was plano 6/9 in the left eye (OS). On evaluation, the near point of convergence and accommodation (NPC, NPA) were 5 cm and 13 cm, respectively. A trial of rigid gas permeable (RGP) lens showed improvement in the visual quality.<sup>[15]</sup> The corneal topography on Pentacam-HR system (Oculus, Wetzlar, Germany) [Fig. 1a] was suggestive of a decentered ablation with a smaller ablation zone.<sup>[7]</sup> In view of the complaints of starbursts and halos, a TCAT was planned on the WaveLight interface based on the corneal topography on the topolyser [Fig. 1b]. All scans of the cornea were done with the Allegro Topolyzer-Vario (WaveLight, Erlangen, Germany) and processed. The ablation was performed using the WaveLight EX500 laser. Eight scans of each eye were taken, of which the four with the best quality were chosen for exporting to the TCAT excimer planning software. Since this also required a zone enlargement, a larger ablation zone of 6.5 mm was planned.

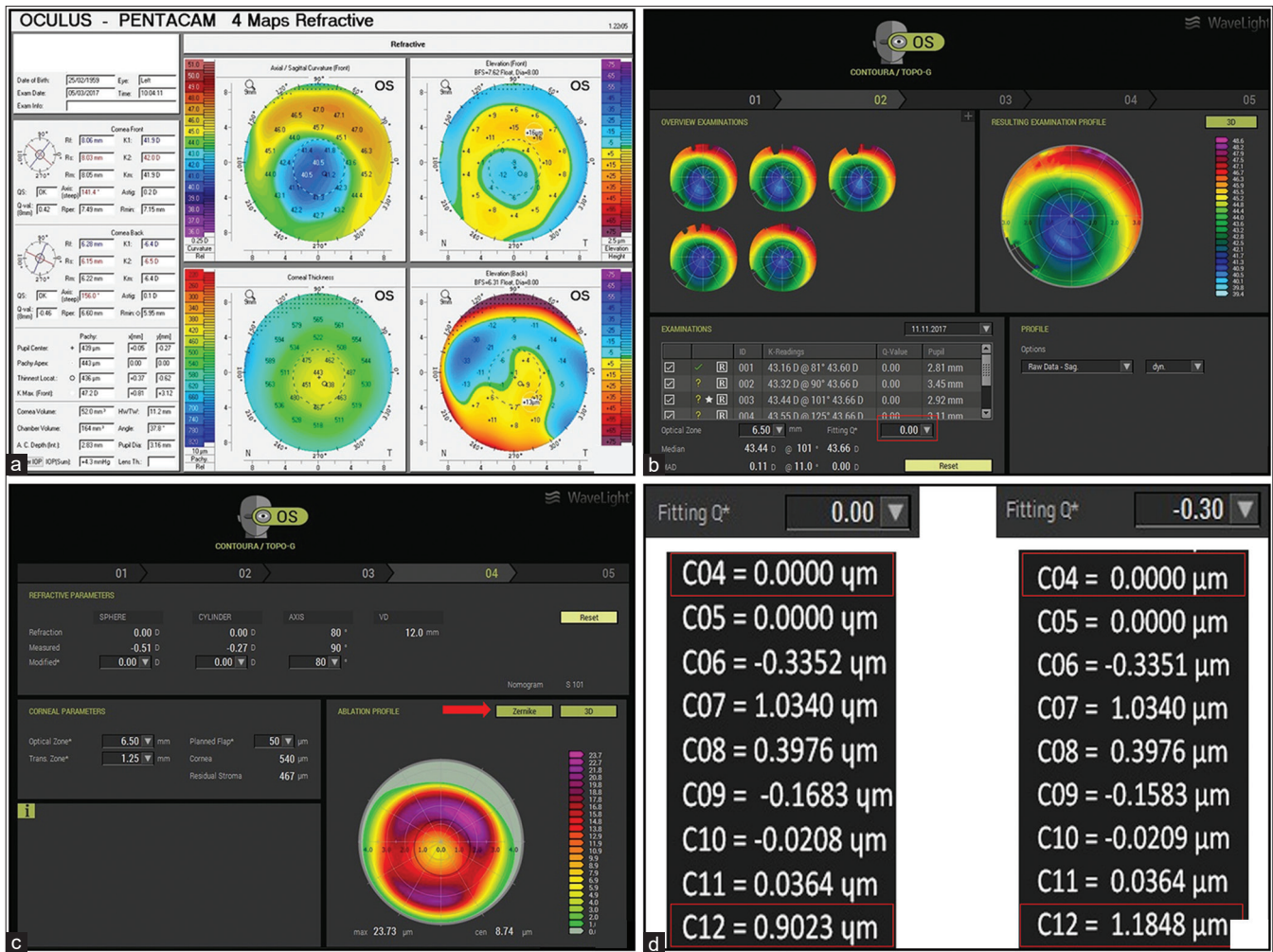
## Impact of Q value on the cornea

Once the scans are exported, valid Q value has to be entered for further planning [Fig. 1b]. In Fig. 1c, the refraction is kept as 0 followed by the generation of the Zernike profile [Fig. 1d].

It is essential to first check the Zernike polynomials keeping the refraction as 0 for sphere and cylinder, so as to get an overview of the existing aberrations in the absence of any refractive correction. As part of the surgical planning, the effect of the ablation on the spherical power must be ascertained using the Zernike polynomials. C4 and C12 denote the defocus and higher order spherical aberrations (SA), respectively, and must be equalized.<sup>[13]</sup> Subsequently, if the Q value is changed, the SA also changes [Fig. 1d].

## How do we neutralize the C4/C12?

C4 and C12 denote the defocus and higher order spherical aberration, respectively, and must be equalized. This equalization process is used to determine the induced spherical effect of tissue ablation for the aberration correction and it is used to calculate the effect on the final power treated of the cornea.<sup>[16]</sup> C4 and C12 neutralization is done by feeding in the spherical correction step-wise and then comparing the C4 and C12 values in the Zernike tab on the treatment-planning page for two different sets of Q values 0 and -0.3, respectively. Equalizing the two values allows you to estimate how much SA change will occur, and the induced spherical power must



**Figure 1:** Case 1. (a) Refractive 4 maps on Pentacam showing decentered ablation OS with a smaller punched out ablation zone (b) Topolyser display of exported scans showing a target Q value of 0. (c) Q value and the modified refraction is kept as 0 followed by the generation of the Zernike profile (red arrow) (d) C4 and C12 values for Q value 0.00 and -0.30

be adjusted accordingly. The closest equalization of C4 and C12 was achieved with -0.50DS correction at the Q value set at 0, while when the Q value was changed to -0.30, the equalization was achieved with -0.75DS. [Fig. 2a green box].

**Which ablation to prefer based on Q value?**

The Q Value and the refraction which balance out the C4 and C12 along with minimal ablation should be chosen for the procedure; that is, at Q value of 0 and modified refraction of -0.50DS and this was chosen for this patient [Fig. 2b green box].

**Ablation-Based Compensation (ABC) refraction**

Addition of compensated refraction (C4 and C12) with patients accepted refraction is done post the equalization of C4 and C12. Since the difference between the central and the maximal ablation at Q value of 0 and -0.50DS modified refraction was 13 microns, additionally contributing to -0.75DS of myopic shift, it was added to the patient’s refraction. Hence, the final correction planned was -1.25DS (-0.5DS based on C4/C12 and -0.75DS based on ABC).

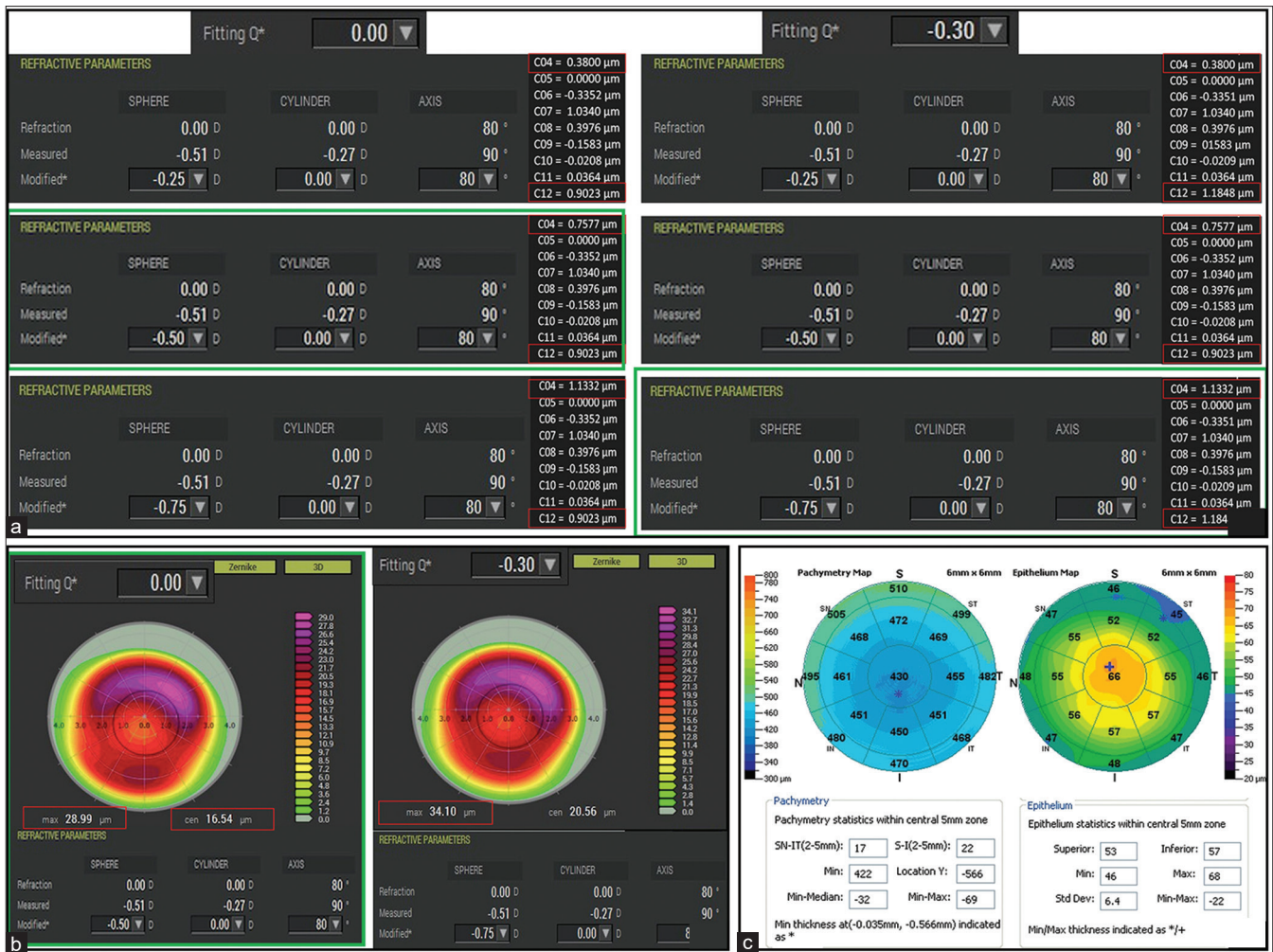
A Phototherapeutic keratectomy (PTK) followed by PRK was done with the use of 0.02% Mitomycin-C (MMC) for 60 seconds (s) for haze prevention, since it was a second

surgical intervention.<sup>[17]</sup> Epithelial thickness of 66 microns was documented on Rtuve (Optovue, Fremont, USA) [Fig. 2c].

A bandage contact lens (Bausch & Lomb, New York, USA) was applied at the end of the procedure for 2 days until the epithelium healing was complete. Postoperatively, the patient was started on a tapering dose of Loteprednol Etabonate 0.5% OS (Lotepred eye drops, Sun Pharamceuticals, Mumbai, India) in tapering dose for 30 days and preservative-free lubricants (Sodium hyaluronate 0.1%, Entod Pharmaceuticals Pvt Ltd, India). Postoperatively, after BCL removal, OS had a refractive error of 0 DS, and the uncorrected visual acuity (UCVA) improved to 6/6. NPC, NPA were 5 and 13 cm, respectively, postoperatively. The complete planning is outlined in Table 1.

**Case 2**

A 58-year-old female visited us with complaints of starbursts for 20 years and diminution of vision in the right eye (OD) for the past 2 years. The BCVA with -3DS/-1.25DC x 100 was 6/18 in the right eye (OD). She had undergone photo refractive keratectomy in OD 20 years ago. The operative notes and the preoperative refractive error records were unavailable. The anterior segment examination revealed nuclear sclerosis



**Figure 2:** Case 1 (a) C4 and C12 values in the Zernike tab on the treatment planning page for two different sets of Q values, 0 and -0.3, respectively. The closest equalization of C4 and C12 was achieved with -0.50DS correction at the Q value set at 0, while when the Q value was changed to -0.30, the equalization was achieved with -0.75DS (green box) (b) C4 and C12 along with minimal ablation should be chosen for the procedure, that is at Q value of 0 and modified refraction of -0.50DS was chosen in this patient (green box). Hyperopic ablation 28.99 microns, Myopic ablation 16.54 microns (red box) (c) ASOCT showing central epithelial thickness of 66 microns OS

grade two OD and rest of the anterior and posterior segment examination were within normal limits. Corneal topography was done on Pentacam-HR which showed a decentered ablation [Fig. 3a]. Epithelial map on Rtvue showed a central thickness of 51 microns [Fig. 3d].

In view of her complaints of starburst and findings of decentered ablation on topography, a TCAT followed by a cataract surgery was planned. The corneal scans were done with the Topolyzer Vario and a topography-guided customized ablation treatment was planned on WaveLight EX500.

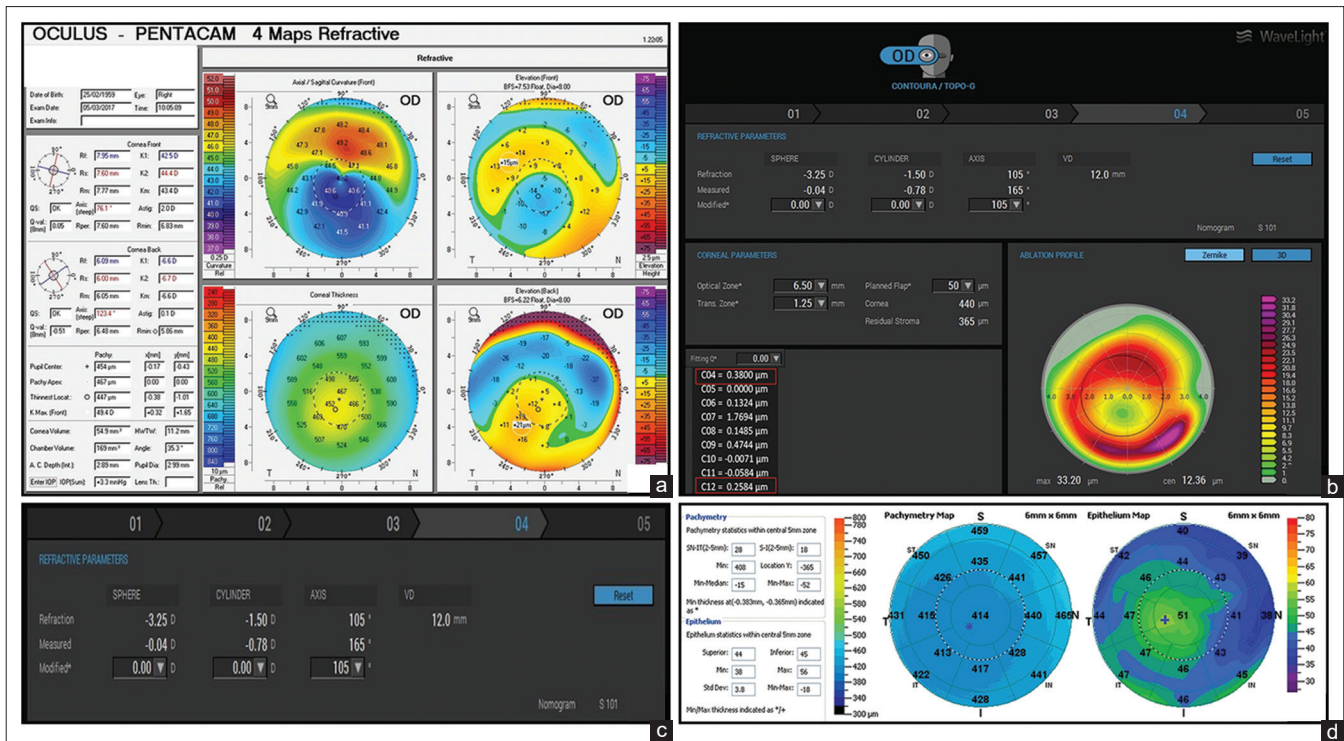
Once the scans were exported, the Q value and refraction were set to 0 as explained in the earlier case and the Zernike's polynomials were evaluated to check for the C4 and C12 values [Fig. 3b]. Since C4 and C12 did not exhibit major difference [Fig. 3b red box], a customized ablation for regularization of the cornea was performed over a 6.5 mm zone. However, the refractive error was not treated as the patient had cataract [Fig. 3c]. PTK (50 microns – based on epithelium thickness) followed by PRK was done with the use of 0.02% MMC for 60 s as in the previous case and the same postoperative regime was followed.<sup>117]</sup>

The Holladay EKR detail report was evaluated before and after TCAT procedure and Aberrometry using iTrace (Tracey Technologies, Texas, USA) were evaluated before and after the TCAT procedure [Fig. 4a-c].

Considering that the patient had a nuclear sclerosis grade 2, a cataract surgery with IOL implantation was planned after 3 months, ensuring stability of corneal topography. Stability post TCAT is defined as a change of 0.2 diopters or less in mean K over three consecutive visits.<sup>[3]</sup> The IOL power calculation based on the EKR map was done using the ASCRS online calculator. An aspheric monofocal IOL of power + 8DS was implanted. The postoperative BCVA was 6/6 with 0.75DS/-0.75 DC at 90 degrees OD and the aberrometric profile also improved, reflective of the improvement in the quality of vision [Fig. 4c].

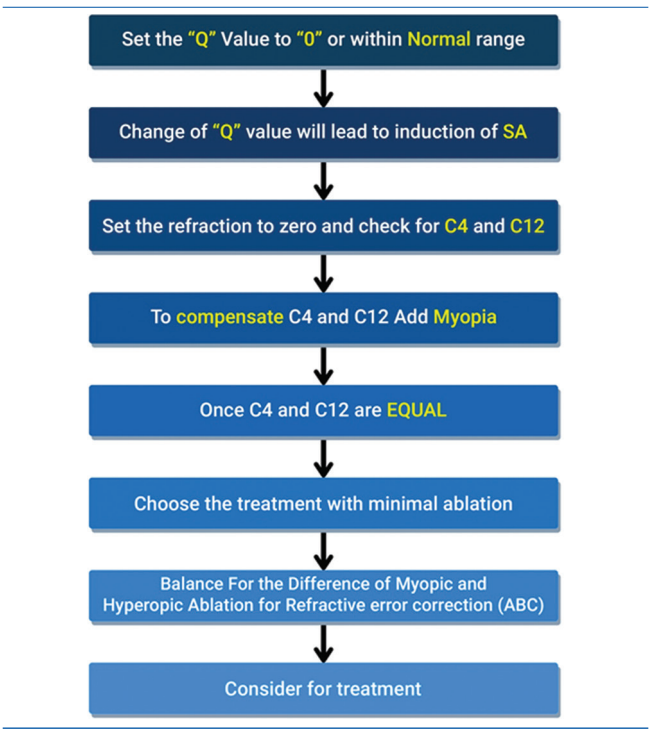
### Case 3

A 31-year-old male presented with diminution of vision OS for the last 6 months. His BCVA was 6/75 OS. He had undergone PRK elsewhere, 3 years back for a refractive correction of -3DS as per the preoperative records available with the patient. Following the refractive procedure, he experienced persistent



**Figure 3:** Case 2 (a) Refractive 4 maps on Pentacam showing decentered ablation OD (b) Q value and the modified refraction are kept as 0 followed by the generation of the Zernike profile. C4 and C12 did not show major differences (red boxes) (c) Zero refraction treatment (d) Epithelial map on Rtvue

**Table 1: Flowchart showing sequential planning of TCAT in irregular cornea on Wavelight Ex-500 Platform**

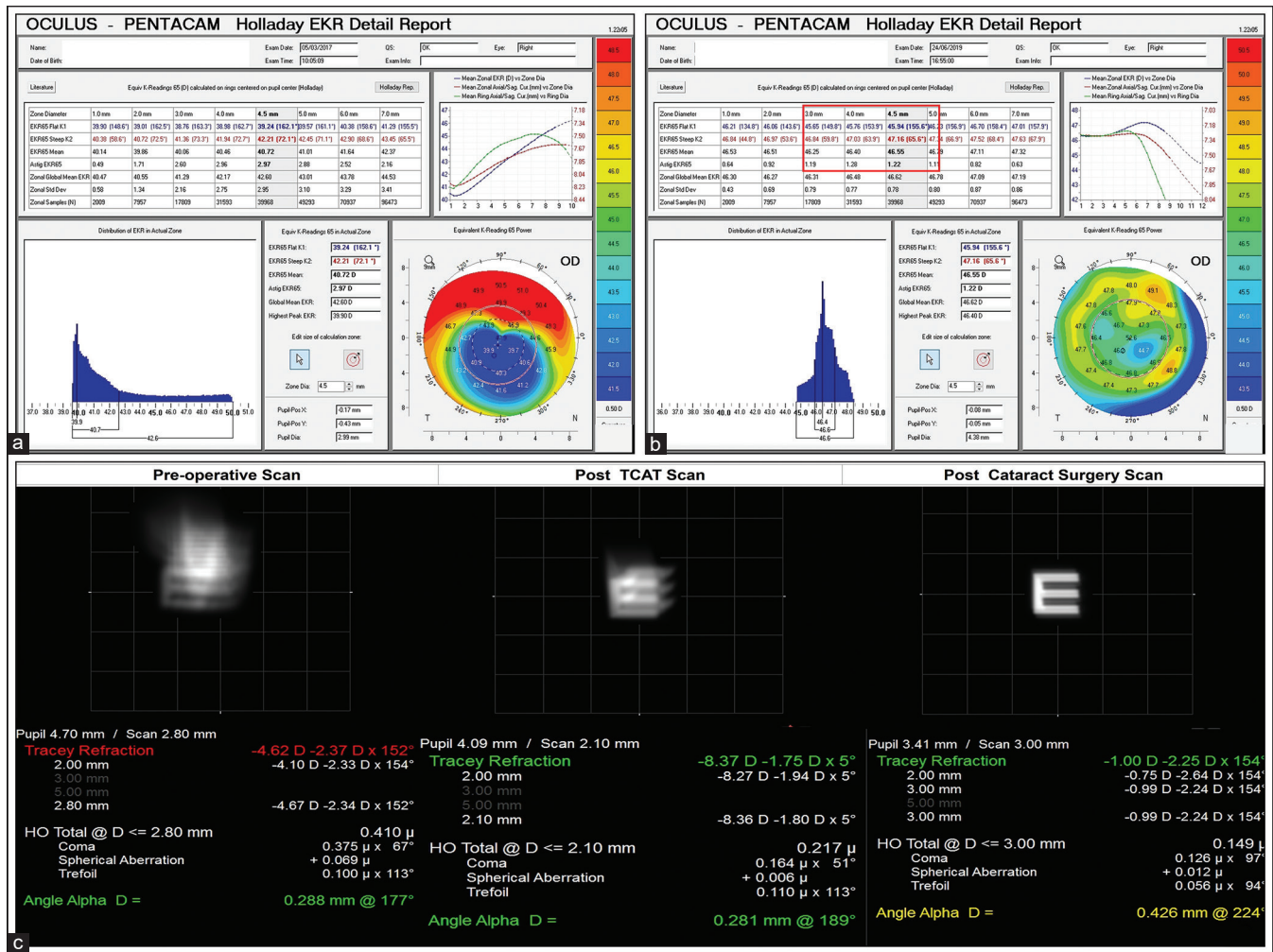


glare and halos. On slit-lamp examination, nuclear sclerosis grade 2 with posterior subcapsular cataract OS was noted. The patient was advised phacoemulsification elsewhere with

a monofocal IOL implantation. However, the patient insisted on emmetropia postsurgery. Hence, a more meticulous approach was required to ensure spectacle free status post cataract surgery. A corneal topography was done on Pentacam, which revealed decentered ablation and an astigmatism of 2.2 D [Fig. 5a]. The epithelial thickness was 61 microns as noted on MS-39 (Costruzione Strumenti Oftalmici, Florence, Italy) [Fig. 5b] Taking into account the decentered ablation and the irregular astigmatism which could be accountable for the glare and halos, a TCAT procedure on Schwind Amaris 1050 RS was performed as follows, prior to the phacoemulsification.

Corneal topography was performed on the Sirius topographer (Costruzione Strumenti Oftalmici, Florence, Italy). After ensuring the static cyclotorsion check, good quality scans were exported to the Schwind planning software and a corneal wavefront (CW) guided PRK option was chosen to regularize the cornea. Laser ablative surgery was performed in a single step using the PRK nomogram (Amaris laser's ORKCAM software, SCHWIND eyetechnologies, Kleinostheim, Germany) [Fig. 6a]

Keeping the target refraction as 0, the central and maximal ablation were noted to be 86 and 93.2 microns, respectively [Fig. 6b]. Following this, the Zernike list option on Schwind custom ablation was used. This allows us to analyze the various higher order aberrations (HOA) of the patient. The minimize+ depth option on this planning software allows us to correct the HOAs with minimal central and maximal ablations as seen in our case. After using the minimize depth option, the central and maximal ablation reduced to 53.73 and 46.52, respectively.[18] [Fig. 6b-e, red box] Minimizing the ablation while regularizing the cornea holds importance as the patient



**Figure 4:** Case 2 (a) Holladay EKR detail report before the TCAT procedure (b) Holladay EKR detail report after TCAT procedure (c) Preoperative, Post-TCAT, and Postcataract surgery aberrometric simulated vision on i-Trace

has already undergone one refractive procedure and the corneal thickness is thus low. The planned laser ablation using the minimize depth nomogram was performed, followed by MMC 0.02% application for 60 s and balanced salt solution irrigation of the residual stromal bed.

Following the TCAT, the ablation profile of the patient as seen on the topography was centered [Fig. 7a] The Holladay equivalent K-reading (EKR) map also showed a regular cornea as compared to the preoperative picture [Fig. 7b and c]. Thus, IOL calculation was done using the ASCRS online calculator and a monofocal nontoric IOL of +28.5D was implanted. The BCVA post TCAT + Phacoemulsification + IOL implantation was plano 6/6 OS.

**Case 4**

A 25-year-old male presented with chief complains of glare and starbursts progressively worsening by the evening in both the eyes (OU). He gave a history of undergoing LASIK for a myopic correction of -3DS OU. His BCVA on manifest refraction was 6/6P OU with +0.25 DS/-0.5 DC at 50 degrees OD, +0.5 DS OS and cycloplegic refraction was 6/6P OU with +0.25 DS/+0.25DC at 45 degrees OD, +0.5 DS OS. On evaluation, the binocular near point of convergence and accommodation were 6 cm and

11 cm, respectively. Improvement in the VA was documented on trial of RGP lens OU.<sup>[14]</sup> His corneal topography showed a decentered small zone of ablation OU since it failed to cover the 4.5 mm zone in the pupillary region [Fig. 8a]. Good quality scans were performed on the Allergo topolyser vario, which revealed a difference between the measured cylinder and the refractive cylinder OU. [Fig. 8b].

Considering the difference in the astigmatism, the patient was evaluated for the HOAs using the Galilei (Ziemer, Port, Switzerland), i-Trace aberrometry, and Osiris-T (Costruzione Strumenti Oftalmici, Florence, Italy). Galilei aberration profile revealed around 55–60% of the measured astigmatism on Topolyser was due to coma OU. The component of corneal coma was more in OS as compared to OD [Fig. 8c].

i-Trace aberrometry revealed that the internal aberrations (lens) were compensating for the corneal coma, resulting in balancing of total eye aberrations in the right eye. However, the lens compensation was very minimal in OS as compared to OD and it was the corneal coma that had a maximum effect on the quality of vision in OS accounting for the glare and starbursts. [Fig. 8d]

This was further confirmed on the Osiris-T (Costruzione Strumenti Oftalmici, Florence, Italy) based on the difference

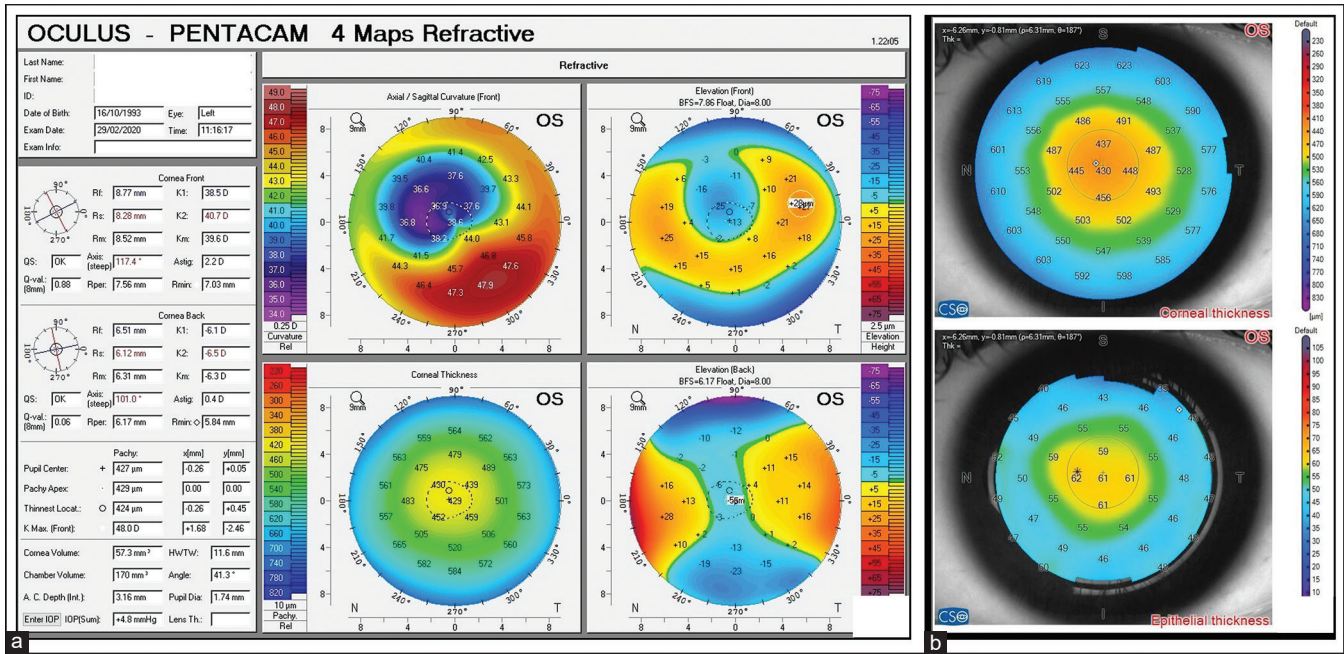


Figure 5: Case 3 (a) Refractive 4 maps on Pentacam revealed decentered ablation and an irregular astigmatism of 2.2DC (OS) (b) Epithelial map on MS-39 showing a central thickness of 61 microns (OS)

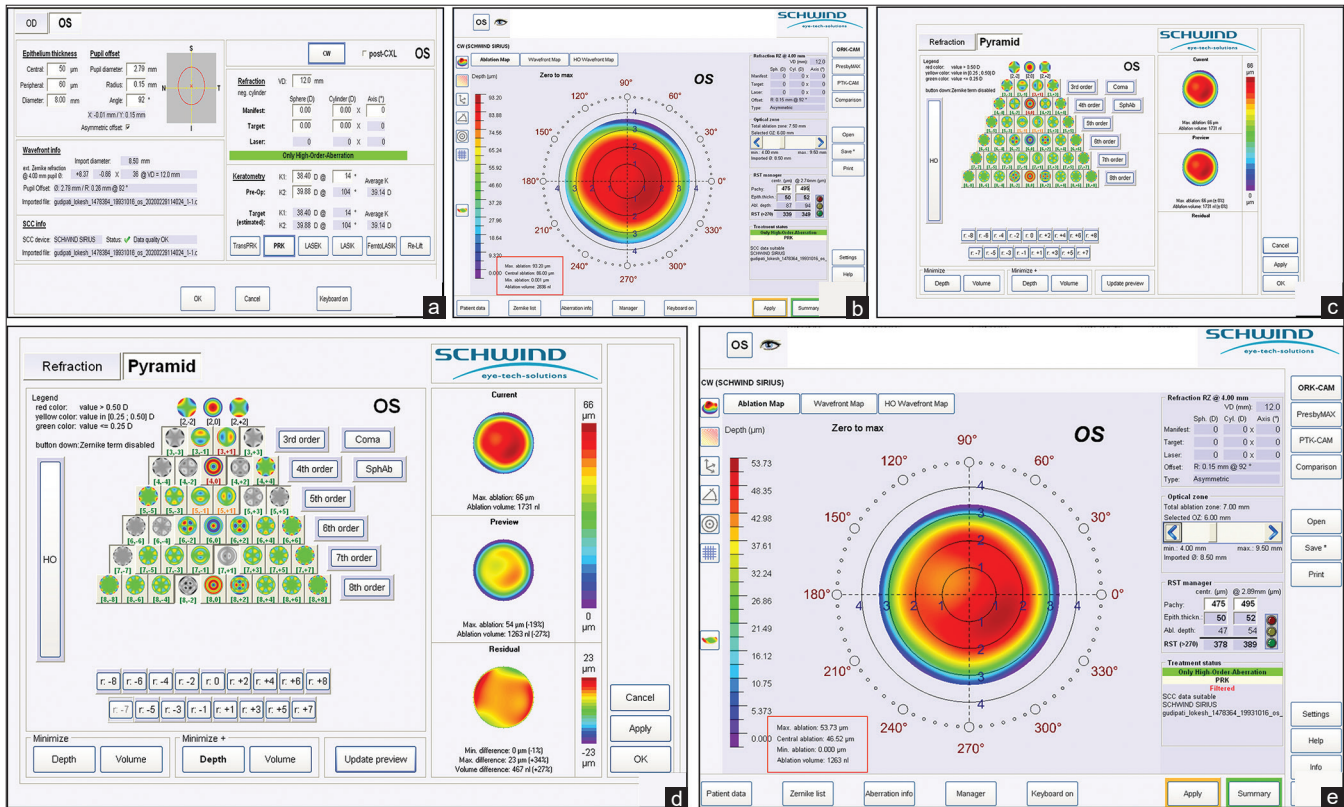
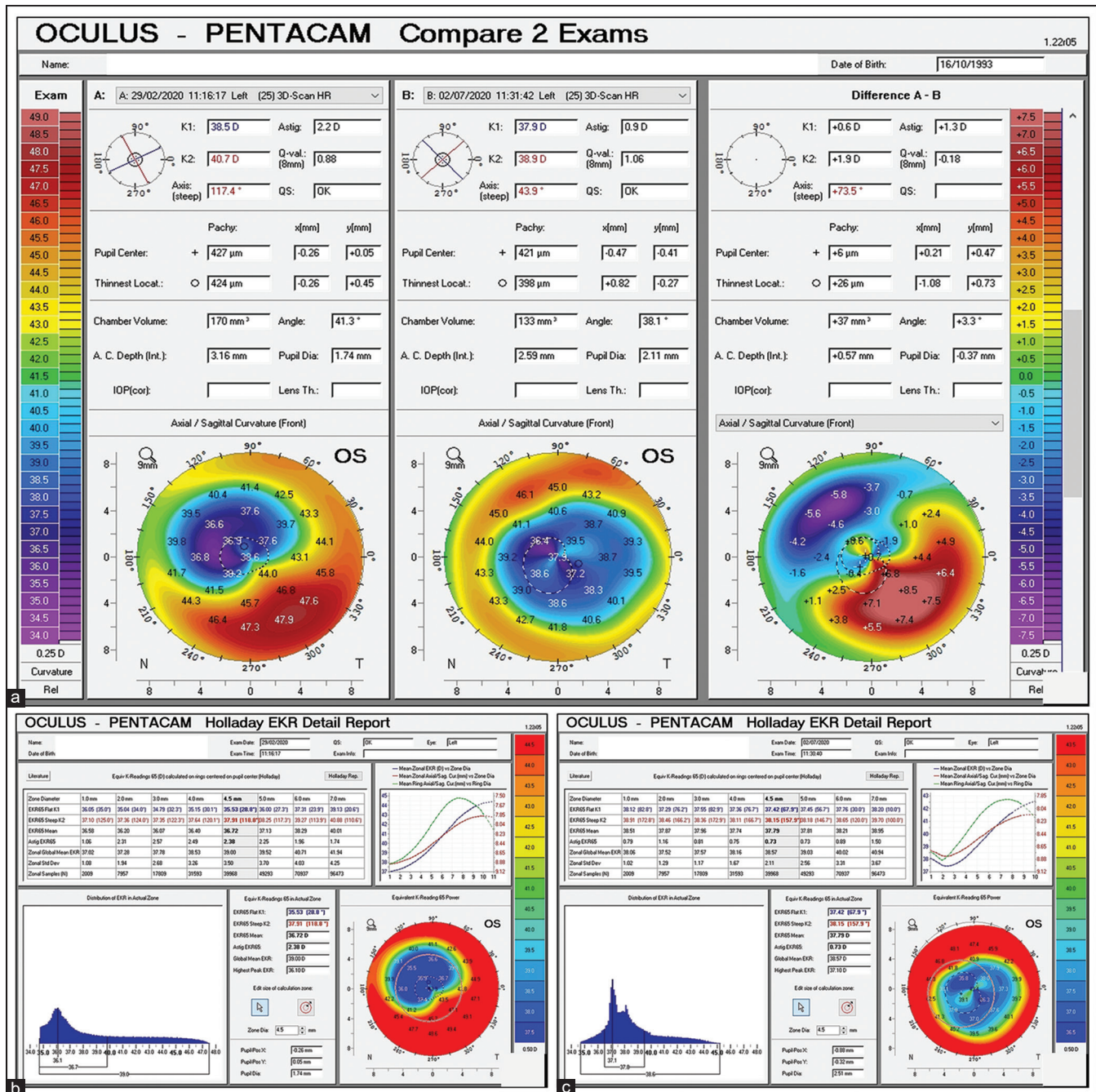


Figure 6: Case 3 (a) CW option for corneal topography-guided PRK option was chosen to regularize the cornea (b-e) The minimize+ depth option chosen to correct the HOAs with minimal central and maximal ablation. After choosing the minimize depth option, the central and maximal ablation reduced to 53.73 and 46.52, respectively (red box)

in the coma calculated when the accommodation was at rest (Coma 0.53 Eq.D) versus when the accommodation was at work (Coma - 0.15 Eq.D) in OD. Around 70% of coma was compensated by the lens during accommodation in the right eye. Thus, the lens was under constant stress in the right eye.

OS showed no change in the total eye coma during the two phases of accommodation. [Fig. 8e]

Predicted phoropter refraction (PPR) vs Pupil Size on Zywave (Bausch & Lomb Zywave, Rochester, NY) demonstrated



**Figure 7:** Case 3 (a) Comparative curvature map showing pre and post TCAT topographies; the map in the middle column shows the post TCAT status of OS and corneal regularization can be appreciated (b and c) Post-operative EKR map also showing a regular cornea as compared to the preoperative EKR map

that the quality of vision was being maintained up to 5–5.25 mm pupil size in the right eye and up to 4 mm pupil size in the left eye, but not beyond it. This difference could be due to the previously appreciated factor of enhanced lens compensation in the right eye compared to the left eye. PPR vs pupil size enables the prediction of refraction at variable pupil sizes [Fig. 8f].<sup>[19]</sup> This was the cause of worsening of glare and starbursts in the evening as the pupil dilates in mesopic conditions.

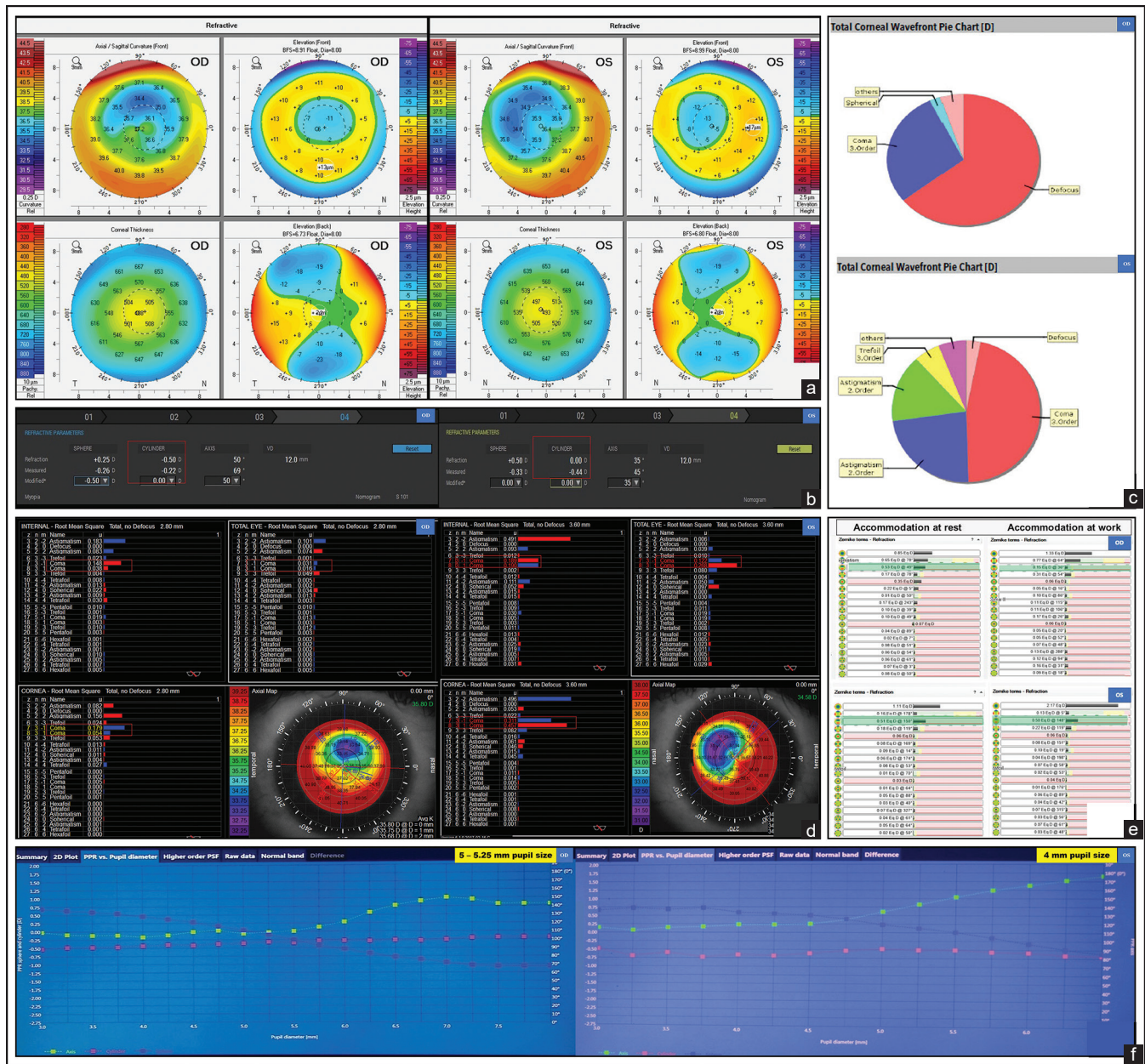
Hence, a zone enlargement was planned – wavefront-guided treatment using the Zyoptix platform OD (Technolas Teneo 317 model 2 excimer laser, Bausch & Lomb, Rochester, NY, USA)

[Fig. 9a] and topography-guided treatment on the WaveLight OS [Fig. 9b]. Unlike the WaveLight, the Zyoptix platform does not allow for the compensation of C4 and C12. Subsequently, the PPR vs Pupil Size on Zywave and the patient’s refraction were used for planning the regularization.

For OD, +0.12DS/-0.19DC at 65 degrees was treated by wavefront-guided treatment profile and the optical zone was enlarged to 6.5 mm.

For OS, cylinder with topolyser axis was treated along with adjustment of sphere based on C4/C12. As discussed earlier, we start with a Q value and modified refraction





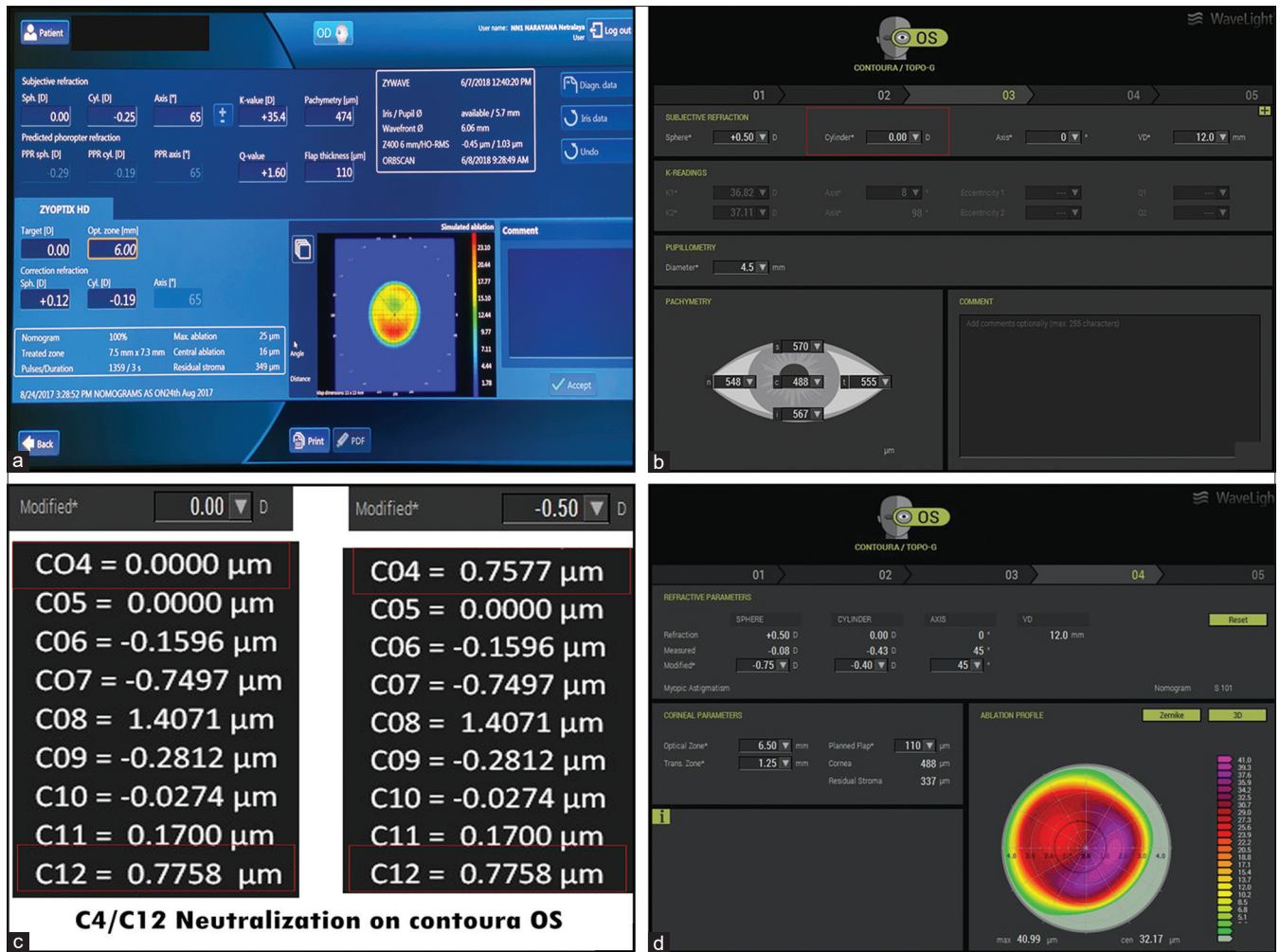
**Figure 8:** Case 4 (a) Refractive 4 map on Pentacam showing small zone of decentered ablation OU (b) Allergo topolyser vario showing a difference between the measured cylinder and the refractive cylinder OU (c) Galilei aberration profile (d) i-Trace aberrometry showing very minimal lens compensation OS as compared to OD (e) Osiris-T showing difference in the coma calculated when the accommodation was at rest versus when the accommodation was at work in OD and OS (f) PPR vs Pupil Size on Zywave (Bausch & Lomb Zywave, Rochester, NY)

as 0, since C4 and C12 were unequal [Fig. 9c], spherical correction of -0.50DS was added and the C4 and C12 values in the Zernike tab were found to be equalized. However, the difference in the ablation had to be compensated. The ablation-based customization as discussed in earlier cases was done and OS -0.75DS/-0.40DC at 45° with an optical zone of 6.5 mm was treated [Fig. 9d].

Postoperatively, the vision improved to 6/6 OU with Plano OD and -0.25 DS OS. The topography revealed enlargement of the zone [Fig. 10a]. On i-Trace aberrometry, postoperatively coma and trefoil minimized on cornea, lens, and entire eye OU. Coma change during accommodation was noted to be minimal and no coma compensation by lens was documented postoperatively in OD [Fig. 10b and c].

## Discussion

The US Food and Drug Administration (FDA) approved the Wavelight system for primary refractive correction.<sup>[20]</sup> The correction of decentered ablations due to prior surgeries, corneal irregularity, and small ablation zones using the Wavelight topographic-guided ablation have been listed as “with precaution”; implying that these procedures are not a contraindication, but need a special consent from the patient.<sup>[21]</sup> These patients need to be counseled in depth regarding the possibility of a partial correction and refractive surprises following the treatment. It is better to avoid patients with unrealistic expectations. The above-mentioned conditions result in corneal irregularities making the measurement of the manifest



**Figure 9:** Case 4 (a) OD planning on the Zyoptix platform for treatment of +0.12DS/-0.19DC at 65 degrees (b) OS Topo G planning on WaveLight showing treatment of +0.50DS (c) OS, C4/C12 at modified refraction of 0 and -0.50DS (Red box) (d) Final treatment planned on Contoura-OS -0.75Ds/-0.40DC at 45 degree with an optical zone of 6.5 mm

refraction close to impossible. Presence of HOAs could also result in patients not accepting the spectacle correction in spite of prescribing the astigmatism measured on the topolyser. All of these factors must be taken into consideration while planning a corneal regularization using the topography-guided customized ablation.

The first part of the surgical planning is to predict effect of the ablation on the spherical power and the Zernike polynomials help us in ascertaining that as seen in the case 1. C4 represents the defocus and the C12 represents the SA, respectively, and it is important to equalize them. The equalization process helps us in determining the spherical effect caused as a result of differential tissue ablation to treat the aberration. This in turn helps us to calculate the final corneal power.

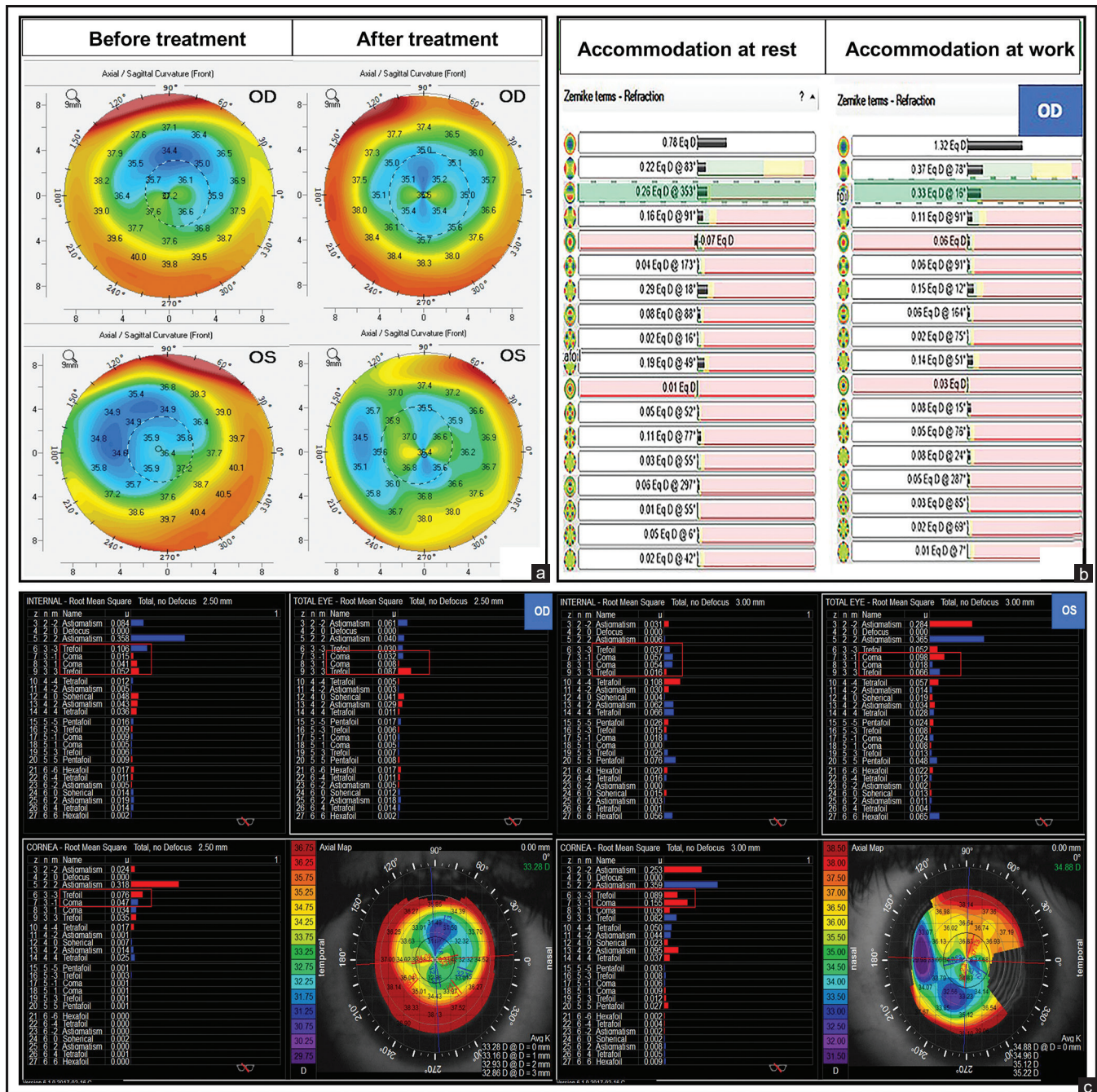
As in our case 1, equalizing C4 and C12 allows us to predict how much spherical power may be expected, so that the spherical power can be adjusted accordingly. Refractive surprises will be a major complication if the TCAT is attempted without equalization. We believe a software for the same can be designed to predict the amount of sphere necessary to equalize C4 and C12.

If TCAT procedure is done before the phacoemulsification like in cases 2 and 3, it gives us an advantage of planning a

toric or multifocal IOL, in case the patient desires spectacle free vision for all distances. This can be made possible as the TCAT before phacoemulsification enables corneal regularization. It also helps avoid refractive surprises that may be encountered post IOL implantation in an irregular cornea, as the IOL power calculation in an irregular cornea is likely to be erroneous. If the TCAT is performed prior to the IOL implantation, the residual refractive error can be taken care of by the IOL.

In case 2, the patient had cataract with an irregular cornea making a primary cataract surgery with IOL implantation prone to refractive surprises. Since C4 and C12 did not exhibit major differences in this case, a customized ablation on WaveLight was performed over a 6.5 mm zone for regularization of the cornea and the refractive error was not treated. Three months post TCAT, an uneventful cataract surgery treated the final myopic shift of the patient.

The minimization approach used in case 3, consisted of selecting a subset of Zernike polynomials that minimize the necessary ablation volume, while respecting the Zernike terms that were clinically relevant. Using this function, we were able to treat the HOAs with surface regularization, along with reducing the ablation depth and surface area by 40%.

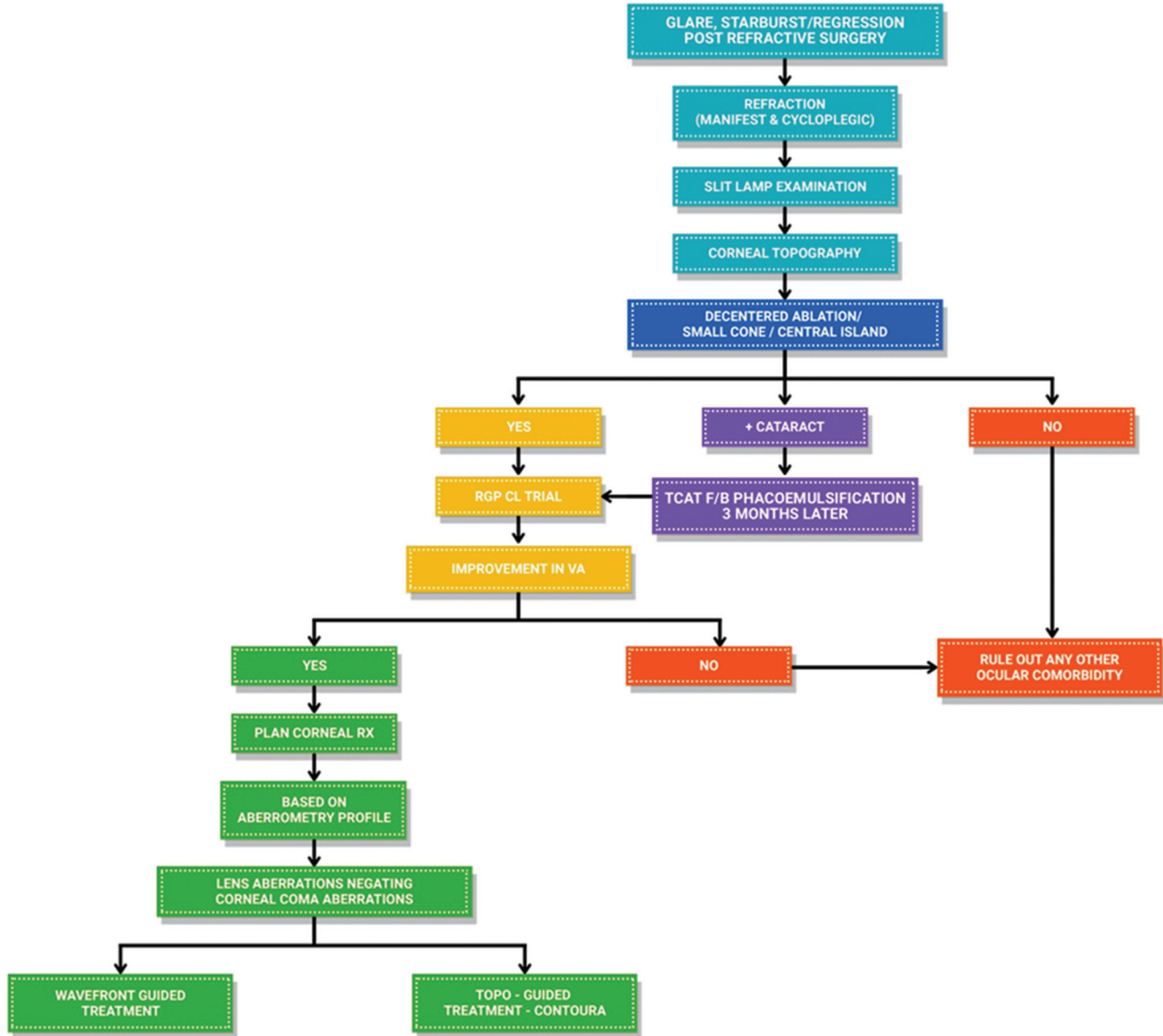


**Figure 10:** Case 4 Postoperative outcomes (a) Axial/Sagittal map on Pentacam showing enlargement of zone OU along with regularization (b) Osiris-T showing total eye coma change during accommodation was minimal and no coma compensation by lens postoperatively in ODi (c) Trace aberrometry showing improvement of the aberration profile; coma and trefoil on cornea, lens, and entire eye OU postoperatively have reduced compared to preoperative status

In case 4, the difference in the manifest versus the topolyser measured cylinder can be attributed to the corneal coma. However, OD aberrometry demonstrated that the lens was compensating for the corneal aberrations. Hence, a wavefront-guided treatment using the Zyoptix platform was best suited for this eye. Coincidentally, in OS, the corneal coma was responsible for most of the visual complains of halos and starburst. Hence, in this scenario, the regularization of the cornea using the topography-guided treatment on the Wavelight along with enlargement of the zone to 6.5 mm was the treatment of choice.

Based on the understanding of various causes of irregular corneas and their specific treatment, the algorithm outlined in Table 2 will help the refractive surgeons decide the further course of management in such cases.

The use of topographic-guided customized ablation has revolutionized the management of irregular corneas postrefractive surgery. It has proved to be a powerful tool for both the refractive surgeon and the patient. However, individualized case-based planning, informed patient consent and detailed

**Table 2: Flowchart outlining management of irregular cornea**

patient counseling are the pillars that make TCAT a robust system.

## Conclusion

- Management of irregularity requires a customized approach.
- Ablation-based compensation prevents refractive surprises.
- The minimize depth function enables tissue sparing ablation along with the correction of essential HOAs.
- Aberrometry is essential before deciding on the Wavefront optimized or topography-guided management.
- An informed consent and counseling at length, explaining the possibility of refractive surprises should be an integral part of the preoperative work-up.

## Declaration of patient consent

The authors certify that they have obtained all appropriate patient consent forms. In the form the patient(s) has/have given his/her/their consent for his/her/their images and other

clinical information to be reported in the journal. The patients understand that their names and initials will not be published and due efforts will be made to conceal their identity, but anonymity cannot be guaranteed.

## Financial support and sponsorship

Nil.

## Conflicts of interest

There are no conflicts of interest.

## References

1. Kim TI, Alió Del Barrio JL, Wilkins M, Cochener B, Ang M. Refractive surgery. *Lancet* 2019;393:2085-98.
2. Sakimoto T, Rosenblatt MI, Azar DT. Laser eye surgery for refractive errors. *Lancet* 2006;367:1432-47.
3. Kummelil MK, Shetty R, Kaweri L, Shaligram S, Paryani M. Outcomes of a management strategy in eyes with corneal

- irregularity and cataract. *Biomed Res Int* 2016;2016:8497858. doi: 10.1155/2016/8497858.
4. Knorz MC, Jendritza B. Topographically-guided laser *in situ* keratomileusis to treat corneal irregularities. *Ophthalmology* 2000;107:1138-43.
  5. Reinstein DZ, Archer TJ, Carp GI, Stuart AJ, Rowe EL, Nesbit A, *et al.* Incidence and outcomes of optical zone enlargement and recentration after previous myopic LASIK by Topography-guided custom ablation. *J Refract Surg* 2018;34:121-30.
  6. Lin DY, Manche EE. Custom-contoured ablation pattern method for the treatment of decentered laser ablations. *J Cataract Refract Surg* 2004;30:1675-84.
  7. Alessio G, Boscia F, La Tegola MG, Sborgia C. Topography-driven excimer laser for the retreatment of decentralized myopic photorefractive keratectomy. *Ophthalmology* 2001;108:1695-703.
  8. Kymionis GD, Panagopoulou SI, Aslanides IM, Plainis S, Astyrakakis N, Pallikaris IG. Topographically supported customized ablation for the management of decentered laser *in situ* keratomileusis. *Am J Ophthalmol* 2004;137:806-11.
  9. Vinciguerra P, Nizzola GM, Airaghi P. A new technique for the excimer laser correction of decentration after PRK and LASIK. In: Pallikaris IG, Siganos DS, editors. *LASIK*. Thorofare, NJ: Slack; 1998. p. 281
  10. Hafezi F, Mrochen M, Seiler T. Two-step procedure to enlarge small optical zones after photorefractive keratectomy for high myopia. *J Cataract Refract Surg* 2005;31:2254-6.
  11. Sridhar MS, Rao SK, Vajpayee RB, Aasuri MK, Hannush S, Sinha R. Complications of laser-in-situ-keratomileusis. *Indian J Ophthalmol* 2002;50:265-82.
  12. Kremer I, Bahar I, Hirsh A, Levinger S. Clinical outcome of wavefront-guided laser *in situ* keratomileusis in eyes with moderate to high myopia with thin corneas. *J Cataract Refract Surg* 2005;31:1366-71.
  13. Lin DT, Holland SR, Rocha KM, Krueger RR. Method for optimizing topography-guided ablation of highly aberrated eyes with the ALLEGRETTO WAVE excimer laser. *J Refract Surg* 2008;24:S439-45.
  14. Shetty R, Shroff R, Grover T, Roshan T, Jayadev C. Topography-guided neutralization technique for the management of flap complication in laser *in situ* keratomileusis. *Indian J Ophthalmol* 2017;65:618-20.
  15. Steele C, Davidson J. Contact lens fitting post-laser-in situ keratomileusis (LASIK). *Cont Lens Anterior Eye* 2007;30:84-93.
  16. Motwani M. A protocol for topographic-guided corneal repair utilizing the US Food and Drug Administration-approved wavelight contoura. *Clin Ophthalmol* 2017;11:573-81.
  17. Thornton I, Xu M, Krueger RR. Comparison of standard (0.02%) and low dose (0.002%) mitomycin C in the prevention of corneal haze following surface ablation for myopia. *J Refract Surg* 2008;24:S68-76.
  18. Arba Mosquera S, de Ortueta D. Optimized zernike term selection in customized treatments for laser corneal refractive surgery: Case report. *J Refract Surg* 2011;27:148-52.
  19. Hament WJ, Nabar VA, Nuijts RM. Repeatability and validity of Zywave aberrometer measurements. *J Cataract Refract Surg* 2002;28:2135-41.
  20. Byrne J. Topography-guided ablation: A promising option for patients with irregular corneas. *Prim Care Optom News* 2012;14:13.
  21. WaveLight® Excimer Laser Systems [Product Information]. Fort Worth, TX: Alcon Laboratories, Inc; 2016.