



# The Brazilian Journal of INFECTIOUS DISEASES

[www.elsevier.com/locate/bjid](http://www.elsevier.com/locate/bjid)



## Brief communication

# Schistosomal liver fibrosis and hepatocellular carcinoma – case series of patients submitted to liver transplantation

Norma Arteiro Filgueira<sup>a,\*</sup>, Camilla Maria de Alencar Saraiva<sup>a</sup>, Norma Thomé Jucá<sup>b</sup>,  
Matheus Filgueira Bezerra<sup>c</sup>, Claudio Moura Lacerda<sup>b</sup>

<sup>a</sup> Universidade Federal de Pernambuco, Hospital das Clínicas, Serviço de Clínica Médica, Recife, PE, Brazil

<sup>b</sup> Universidade de Pernambuco, Hospital Universitário Oswaldo Cruz, Unidade de Transplante de Fígado, Recife, PE, Brazil

<sup>c</sup> Universidade Federal de Pernambuco, Laboratório de Imunopatologia Keizo Asami (LIKA), Recife, PE, Brazil

## ARTICLE INFO

### Article history:

Received 14 February 2018

Accepted 12 June 2018

Available online 12 July 2018

### Keywords:

*Schistosoma mansoni*

Hepatocellular carcinoma

Liver transplantation

## ABSTRACT

Schistosomiasis affects approximately 207 million people in 76 countries. The association between hepatocellular carcinoma and *Schistosoma mansoni* infection has been investigated. Studies using animal models suggest that the parasite may accelerate the oncogenic process when combined with other factors, such as hepatitis C virus infection or exposure to a carcinogen. Herein, we report a case series of six hepatocellular carcinoma patients from Northeast Brazil, with negative serology for both hepatitis B and C virus, submitted to liver transplantation, whose explant showed evidence of schistosomal liver fibrosis. Since all patients enrolled in this study were submitted to liver transplantation, we were able to access the whole explanted liver and perform histopathological analysis, which is often not possible in other situations. Although 50% of them showed signs of liver failure, no cirrhosis or any liver disease other than schistosomal fibrosis had been detected. These uncommon findings suggest that *Schistosoma mansoni* infection might predispose to hepatocellular carcinoma development, regardless of the absence of other risk factors.

© 2018 Sociedade Brasileira de Infectologia. Published by Elsevier Editora Ltda. This is an open access article under the CC BY-NC-ND license (<http://creativecommons.org/licenses/by-nc-nd/4.0/>).

The World Health Organization estimated that 207 million people from 76 countries were infected by the various species of *Schistosoma* in 2016.<sup>1</sup> The Brazilian Ministry of Health estimates that up to 6 million people are infected with *Schistosoma mansoni* in Brazil, of whom 5–10% will develop the hepatosplenic form. Most cases occur in the Northeast region and

the state of Pernambuco accounts for 35% of national deaths due to this condition.<sup>2</sup>

The hepatosplenic form of *S. mansoni* infection (SMI) is due to egg-induced inflammation and fibrosis in liver presinusoidal portal areas, leading to portal hypertension, esophageal varices formation and digestive bleeding. A typical feature of

\* Corresponding author.

E-mail address: [norma.arteiro@hotmail.com](mailto:norma.arteiro@hotmail.com) (N.A. Filgueira).

<https://doi.org/10.1016/j.bjid.2018.06.001>

1413-8670/© 2018 Sociedade Brasileira de Infectologia. Published by Elsevier Editora Ltda. This is an open access article under the CC BY-NC-ND license (<http://creativecommons.org/licenses/by-nc-nd/4.0/>).

**Table 1 – Demographic, clinical, laboratory and histopathological data of six patients with HCC and SLF submitted to liver transplantation in Recife – Brazil.**

	Patients					
	1	2	3	4	5	6
Sex	Male	Male	Male	Female	Male	Male
Age (years)	53	45	46	34	70	57
UGB	Yes	No	No	Yes	Yes	No
Splenectomy	No	No	No	Yes	Yes	No
LFS	Ascites	No	No	Ascites	Ascites + jaundice	No
MELD	12	7	7	10	15	8
Comorbidities	None	DM, AC	None	None	DM, AC	DM
Liver/body weight (%)	1.61	4.50	2.22	2.14	1.34	1.60
Liver parenchyma	SLF + SG	SLF + SG	SLF	SLF + SG	SLF	SLF + SG
Milan criteria	In	Out	Out	In	In	Out

HCC, hepatocellular carcinoma; SLF, schistosomal liver fibrosis; UGB, upper gastrointestinal bleeding; LFS, liver failure signs; MELD, model for end-stage liver disease; DM, diabetes mellitus; AC, alcohol consumption; SG, schistosomal granuloma.

this condition is the maintenance of liver perfusion due to an increase in hepatic arterial flow, allowing the preservation of hepatocyte function.<sup>3</sup>

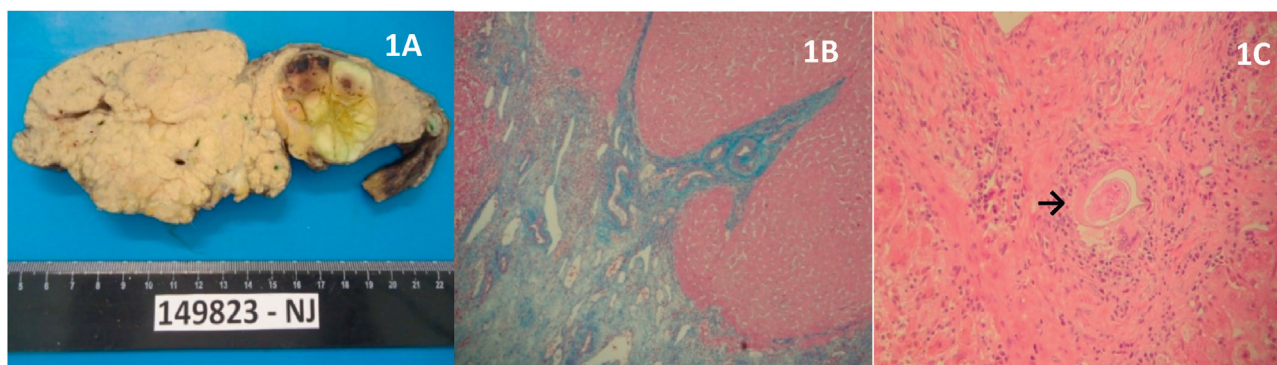
The association between SMI and hepatocellular carcinoma (HCC) has been evaluated over the last 40 years in both experimental and clinical studies, of which many were performed in Egypt. However, due to the use of non-sterile shared syringes for SMI treatment in the past, that country has a high prevalence of hepatitis C and schistosomal coinfection.<sup>4</sup> Therefore, the co-occurrence of HCV and SMI in the Egyptian population makes it difficult to comprehend the real contribution of SMI in the oncogenesis of HCC. Importantly, the previous studies lack histopathological material that analyzes the whole liver. Such resource is essential to rule out other conditions that may contribute to carcinogenesis.

The aim of this study is to identify the frequency of schistosomal liver fibrosis (SLF) in patients submitted to liver transplantation (LT) due to HCC in a reference center in Northeastern Brazil, describing the clinical, laboratory and histological characteristics of the patients whose explant showed only SLF. A case series was drawn up from data collected from the medical records of 170 patients submitted to LT for HCC treatment at the Liver Transplantation Unit of the Oswaldo Cruz Hospital in Recife, Pernambuco, Northeast Brazil, from 1999 to December 2016. The study included cases

for which the histopathological examination of the explant demonstrated the presence of SLF. Patients with current or previous evidence of hepatitis B or C and with histopathological evidence of cirrhosis or other liver diseases were excluded.

Of the 170 patients submitted to LT for HCC treatment between 1999 and 2016, six (3.5%) were identified with an isolate finding of SLF when the explant was analyzed. A summary of these six included cases is shown in Table 1. Five of them were male and all were from endemic areas of Northeast Brazil. The age at transplantation ranged from 34 to 70 years, with a median of 53 years. Three patients reported a previous episode of upper gastrointestinal bleeding (UGB) due to rupture of esophageal varices, and two of them had undergone splenectomy. In three patients, the indication of LT as HCC therapy was due to bilobar tumor involvement and in the remaining three due to signs of hepatic failure, such as ascites and/or jaundice. All patients with clinical signs of liver failure had previous UGB.

All explants showed stellate portal fibrosis with vascular proliferation, typical of Symmers' fibrosis and in four cases there were schistosomal granulomas (Fig. 1). As to the weight of the explant, three cases had a reduction in the ratio explant/total body weight, two of which had signs of liver failure. Although three patients had other risk factors for HCC,



**Fig. 1 – Explant showing a hepatocellular carcinoma in the left lobe of a liver with schistosomal fibrosis and absence of nodular transformation (A). Microscopic slides showing stellate portal fibrosis with vascular proliferation (B – Masson's trichrome, 40x) and a schistosomal granuloma (C, arrow, hematoxylin-eosine, 100x).**

such as diabetes and alcohol consumption, the histopathological analysis of their explants did not show any cirrhosis, steatosis, or other liver diseases. No complete portal vein thrombosis was found in any case; only one patient had partial occlusion of this vessel.

It is speculated that parasitic infections may play a role in carcinogenesis due to changes of the host inflammatory response. The association between *Schistosoma haematobium* and squamous cell carcinoma of the bladder is already well established.<sup>5</sup> The association between SMI and HCC has been studied since the 1970s. Studies with experimental animals showed a higher frequency of liver dysplasia and HCC in the group exposed concomitantly to carcinogens and SMI.<sup>6,7</sup>

In a case-control study with 75 patients with HCC and HCV divided according to the presence of SMI, El-Tonsy et al. observed that the co-infected patients were younger and had a higher proportion of larger and multifocal tumors.<sup>8</sup> Sabry et al. found serologic evidence of SMI in 20 of 60 HCC cases in Egypt, of whom only four were co-infected with HCV.<sup>9</sup> Another Brazilian cases series described seven HCC patients with schistosomiasis; however, some of these patients had portal thrombosis or previous hepatitis B.<sup>10</sup> It is important to highlight that none of these studies performed histopathological analysis of the liver to exclude other predisposing diseases or some degree of liver cirrhosis.

It is important to note that, in this study, half of the patients had clinical signs of liver failure, with no histological evidence of cirrhosis, and they were precisely those who had a history of UGB. Due to portal obstruction, schistosomiasis patients present hepatic sinusoidal arterialization. Consequently, they are more vulnerable to sudden falls in blood pressure due to UGB episodes, developing focal areas of hepatic necrosis.<sup>11</sup>

In summary, by studying HCC patients from a schistosomiasis endemic region who had undergone liver transplantation, we were able to perform histopathologic analyses of the explanted liver, which is not commonly available in non-transplanted HCC patients due to biopsing-related risks. Therefore, the present case series is the first to describe an association between HCC and SLF based on the whole analysis of the liver, which permits the exclusion of other associated hepatic diseases. Although this case series brings clinical evidence about the possible association between SMI

and HCC, it does not establish a causal relation, thus, further investigations are required to better understand the current observations.

### Conflicts of interest

The authors declare no conflicts of interest.

### REFERENCES

1. World Health Organization. Schistosomiasis [Internet]. Geneva: WHO. Available from <http://www.who.int/schistosomiasis/en/> [cited 22.10.17].
2. Martins-Melo FR, Pinheiro MCC, Ramos AN Jr, Alencar CH, Bezerra FSM, Heukelbach J. Trends in schistosomiasis-related mortality in Brazil, 2000–2011. *Int J Parasitol.* 2014;44:1055–62.
3. Shaker Y, Samy N, Ashour E. Hepatobiliary schistosomiasis. *J Clin Transl Hepatol.* 2014;(2):212–6.
4. Strickland GT. Liver disease in Egypt: hepatitis C superseded schistosomiasis as a result of iatrogenic and biological factors. *Hepatology.* 2006;43:915–22.
5. International Agency for Research on Cancer. *Schistosoma haematobium*. IARC Monographs on the evaluation of carcinogenic risks to humans, vol. 100B; 2012. p. 371–82.
6. Haese WH, Bueding E. Long-term hepatocellular effects of hycanthone and two other anti-schistosomal drugs in mice infected with *Schistosoma mansoni*. *J Pharmacol Exp Ther.* 1976;197:703–13.
7. El-Tonsy MM, Hussein HM, Helal TE, Tawfik RA, Koriem KM, Hussein HM. *Schistosoma mansoni* infection: is it a risk factor for development of hepatocellular carcinoma? *Acta Trop.* 2013;128:542–7.
8. El-Tonsy MM, Hussein HM, Helal TES, Tawfik RA, Koriem KM, Hussein HM. Human *Schistosomiasis mansoni* associated with hepatocellular carcinoma in Egypt: current perspective. *J Parasit Dis.* 2016;(40):976–80.
9. Sabry AEHA, El-Aal AAA, Mahmoud NS, Nabil Y, Aziz IAA. An initial indication of predisposing risk of *Schistosoma mansoni* infection for hepatocellular carcinoma. *J Egypt Soc Parasitol.* 2015;45:233–40.
10. Toda KS, Kikuchi L, Chagas AL, et al. Hepatocellular carcinoma related to *Schistosoma mansoni* infection: case series and literature review. *J Clin Transl Hepatol.* 2015;3:260–4.
11. Andrade ZA. Schistosomal hepatopathy. *Mem Inst Oswaldo Cruz.* 2004;99:51–7.