

Perfect anterior capsulorhexis using a dented cystitome

Anjali Khadia, Aditi Ghosh¹, Isha Gupta², Fredrick Mouttapa, Veena K, Rengaraj Venkatesh³

We describe a novel intraoperative technique of measuring and creating an adequate size continuous curvilinear capsulorhexis (CCC) in phacoemulsification, using a dented cystitome as the ruler. A pair of curved tenotomy scissors is used to create a dent on the cystitome at a distance of 2.5 mm length (i.e., half of the desired approximate capsulorhexis diameter). The dented cystitome is used as a guide for making a CCC of approximately 5 mm diameter, which is considered adequate for phacoemulsification. This method of measuring the capsulorhexis helps in achieving a well centered and stable intraocular lens with a 360° overlap of the optic edge by the anterior capsular rim in the postoperative period. Using a dented cystitome for capsulorhexis mandates reliable and consistent results in the hands of the novice as well as the experienced surgeons.

Key words: Capsulorhexis, dented cystitome, phacoemulsification

Gimbel and Neuhann first popularized continuous curvilinear capsulorhexis (CCC) for removal of the lens and intraocular lens (IOL) implantation in the bag, which has now become the preferred technique for anterior capsulotomy. It prevented radial tears, which was a frequent complication with the can-openers capsulotomy.^[1] The recommended size of an ideal capsulorhexis ranges from 5 to 5.5 mm in diameter. Its size should be approximately 0.25–0.50 mm smaller than the optic size of the IOL to allow overlap of optic edge.^[2] A correctly sized and a well-centered capsulorhexis with a 360° overlapping capsular edge prevents IOL tilt, myopic shift, postoperative complications like optic decentration, and opacification of posterior and anterior capsule due to a combination of the symmetric contractile forces of the capsular bag and the shrink-wrap effect. A small capsulorhexis can lead to anterior capsule opacification, capsule contraction syndrome, and capsular bag distension syndrome.^[1] A large capsulorhexis is associated with an increased incidence of posterior capsule opacification.^[3]

Various methods have been used to measure the dimensions of the capsular opening intraoperatively and achieve a perfect CCC. Verion-guided CCC,^[4] corneal impression marker,^[2] and calipers placed over the cornea are the commonly used extraocular instruments. However, the disadvantage with the extraocular techniques is that the dimensions of the capsulorhexis are altered by the relative magnification of image by the cornea. Intraocular instruments (that are introduced

inside the anterior chamber over anterior lens capsule (ALC)) like ring calipers^[5] and Fogla instrument^[3] have also been used. The dimensions can also be measured relative to other structures such as the IOL optic and from photographs or the video monitor.^[6,7] All these techniques, however, either allow an approximate measurement of the actual dimensions or are cumbersome with increased intraocular instrumentation.

The choice of instrument to perform the CCC is the surgeon's preference, which may be a cystitome needle, Utrata forceps, or the 23-gauge vitrectomy forceps. For better planning of anterior capsulorhexis location and size, we turned to a novel technique of creating a measured dent over the cystitome before starting the capsulorhexis and using it as a guide to make an adequately sized CCC.

Requirement

A 26 G cystitome, a Castroviejo's calipers, and curved tenotomy large blade scissors

Technique

Preparing the cystitome

A cystitome is prepared by bending a 26 G needle at two angles (90° at the bevel and 120° at the hub). A distance of 2.5 mm length (i.e., half of the desired capsulorhexis diameter) from

Video Available on:

www.ijo.in

Access this article online

Website:

www.ijo.in

DOI:

10.4103/ijo.IJO_2767_20

Quick Response Code:



Department of Paediatric Ophthalmology Services, ¹IOL Fellow, ²Post Graduate and ³Glaucoma Service, Aravind Eye Care System, Pondicherry, India

Correspondence to: Dr. Aditi Ghosh, Aravind Eye Hospital, Cuddalore Main Road, Thavalakuppam, Pondicherry - 605 007, India. E-mail: aditi.ghosh.gmc@gmail.com

Received: 26-Aug-2020

Revision: 09-Oct-2020

Accepted: 11-Oct-2020

Published: 30-Apr-2021

For reprints contact: WKHLRPMedknow_reprints@wolterskluwer.com

Cite this article as: Khadia A, Ghosh A, Gupta I, Mouttapa F, Veena K, Venkatesh R. Perfect anterior capsulorhexis using a dented cystitome. Indian J Ophthalmol 2021;69:1311-3.

the 90° bent is measured over the cystitome with a Castroviejo's calipers, and a dent is created with the help of a curved tenotomy scissors [Fig. 1a-d].

Surgical procedure

After staining the anterior capsule with Trypan blue (0.06%) and filling the anterior chamber with viscoelastic substance, the dented cystitome is introduced into the anterior chamber. The needle is placed over the ALC and a nick is made from the center of the ALC extending up to approximately 2.5 mm, using the dent mark over the cystitome as a reference. A flap is raised followed by tearing the ALC. The mark over the cystitome is used as a guide, every 2–3 clock hours, and the capsulorhexis is completed in a controlled manner in an anticlockwise direction. Corneal reflex of microscope is used as the capsulorhexis center. Circular and adequate capsulorhexis is ensured in all clock hours by repeatedly measuring capsulorhexis radius with dented cystitome as the ruler. The surgical landmarks to be aligned are the central corneal reflection, margin of the capsulorhexis, tip of the cystitome, and dent on the cystitome [Fig. 2]. As a result, a 5 mm diameter of continuous curvilinear circular capsulorhexis can be obtained. Double-dented cystitome can also be used as a guide to measure the final diameter of capsulorhexis. After completion of lens removal, a single-piece foldable IOL is implanted in the capsular bag [Video 1]. The anterior capsule rim is found to overlap the edges of the IOL optic by approximately 0.5–0.25 mm [Fig. 3].

Discussion

Certain styles of capsule forceps have been designed with laser marks to help surgeons produce various capsulotomy diameters. However, these forceps are limited in their ability to provide a diameter reference in the horizontal meridian parallel to the phaco incision. The main advantage of this technique is that the dented mark over the cystitome can be easily made by the routine instruments available for the operation theatre procedures. It does not require special skills on the part of the operating surgeon and it does not require any extra instrument other than the minimal requirements of a routine cataract procedure. It is very cost effective. There is no risk of anterior chamber inflammation as no other new add-on instruments are inserted inside the anterior chamber. It measures the dimensions of the capsulorhexis intraoperatively in all axes with greater accuracy. The measurements are not affected by corneal magnification as the measuring instrument and capsulorhexis opening have the same magnification by the cornea. This modified cystitome is of great help to the phaco beginners for determining the appropriate size of the capsulorhexis, especially during the learning process. It is also useful in manual small Incision cataract surgeries. We have considered the approximate diameter of the capsulorhexis in MSICS to be 7 and 5 mm in phacoemulsification procedures, respectively.

Also, in a hard brown cataract with a small capsulorhexis complication like zonular dialysis, posterior capsular rent and nucleus drop are common, so a larger size capsulorhexis is mandatory. In these cases, a dented cystitome (mark made according to the choice of the surgeon) may be of value. This small modification is greatly useful to make perfect capsulorhexis mandatory for toric IOLs and also for primary posterior capsulorhexis in case of pediatric cataracts. In a

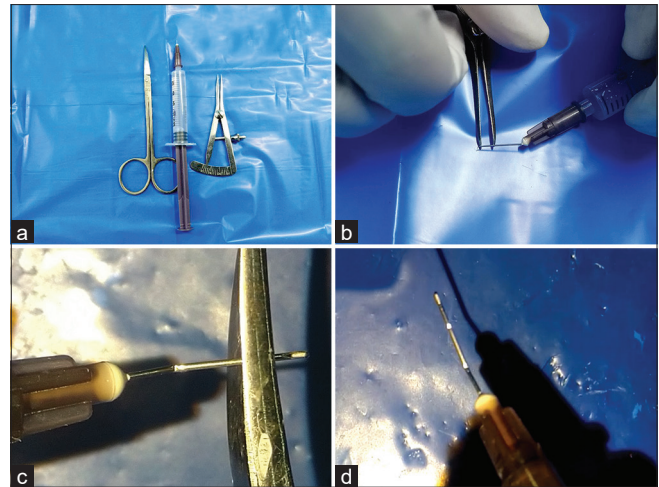


Figure 1: Preparation of the dented cystitome. (a) Curved tenotomy scissors, 26 G cystitome, Castroviejo's calipers, (b) measurement of 2.5 mm mark over the cystitome using Castroviejo's calipers, (c) dent created over the marked area using curved tenotomy scissors, and (d) dented cystitome

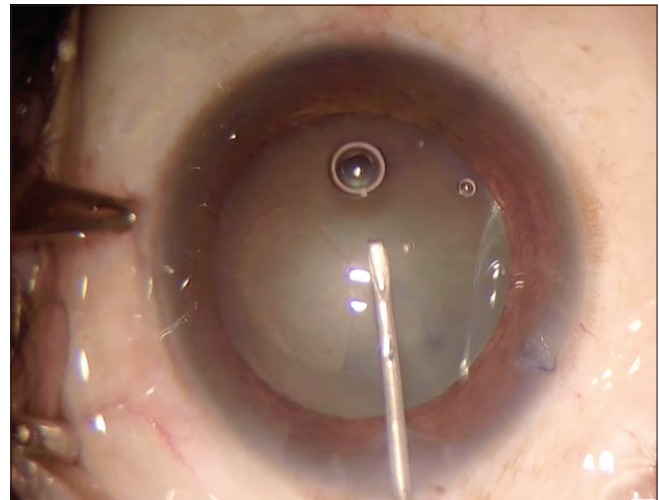


Figure 2: Surgical landmarks – Central corneal reflex, tip of the cystitome, dent over the cystitome, and margin of the capsulorhexis

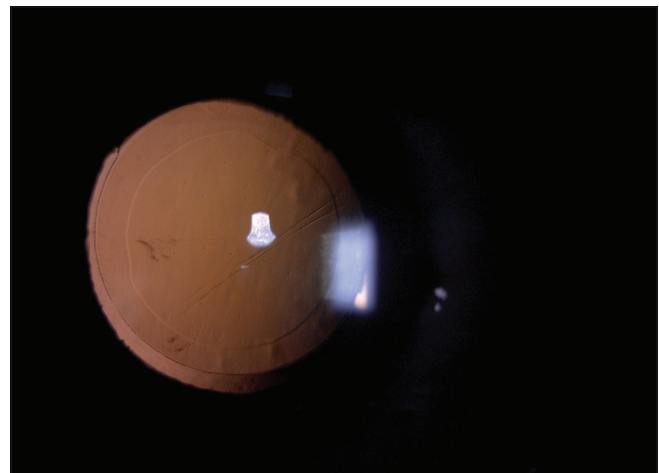


Figure 3: 360° overlap of the IOL optic by the capsulorhexis margin

semidilated pupil, the cystitome can be placed over the iris, an approximate capsulorhexis size is measured, and a blind capsulorhexis can be done beneath the iris using the dented marking over the cystitome, which acts as a guide.

We have used this technique of capsulorhexis with a dented cystitome in more than 60 eyes of phacoemulsification. Most of the patients had a stable well-centered IOL with an anterior capsule overlap of 360° on the anterior surface of the IOL.

Limitation

Dent mark, if made superficially, might not be visible under the microscope. Width of the blade of the curved tenotomy scissors is approximately 0.5 mm, so the dent created over the cystitome is in the range of 0.5–0.75 mm, so there is a possibility of a margin of error of 0.5–0.75 mm in measuring the approximate size of the rhexis. Chances of multiple dents over the cystitome are possible; therefore, to overcome this limitation, the scissor should indent over the cystitome with sustained uniform compressive force. In a very small pupil, it is difficult to visualize the capsulorhexis edge.

Conclusion

In conclusion, several sweeping changes have been made in the recent past for mastering the technique of achieving a perfect CCC. This article enumerates one such technique. With improvements and ease of accessibility of technology, it is expected that these changes would be accepted and incorporated widespread in clinical practice. This technique is safe, easily available, less time consuming, and cost-effective.

Performing the capsulorhexis with a dented cystitome is a simple technique to acquire the basic surgical skills. Thus, whenever possible, trainees can be trained through these modalities to transform their surgical skills at a faster pace.

Financial support and sponsorship

Nil.

Conflicts of interest

There are no conflicts of interest.

References

1. Gimbel HV, Neuhann T. Development, advantages, and methods of the continuous circular capsulorhexis technique. *J Cataract Refract Surg* 1990;16:31-7.
2. Wallace III RB. Capsulotomy diameter mark. *J Cataract Refract Surg* 2003;29:1866-8.
3. Fogla R, Rao SK. Device for intraoperative measurement of capsulorhexis dimensions. *J Cataract Refract Surg* 2003;29:1643-4.
4. Blanckaert J. The perfect anterior capsulorhexis getting the right shape and right size generates optimal optical outcomes. *The Ophthalmologist*. 2014; 5:26-28.
5. Tassignon MJ, Rozema JJ, Gobin L. Ring-shaped caliper for better anterior capsulorhexis sizing and centration. *J Cataract Refract Surg* 2006;32:1253-5.
6. Kimura W, Yamanishi S, Kimura T, Sawada T, Ohte A. Measuring the anterior capsule opening after cataract surgery to assess capsule shrinkage. *J Cataract Refract Surg* 1998;24:1235-8.
7. Park TK, Chung SK, Baek NH. Changes in the area of the anterior capsule opening after intraocular lens implantation. *J Cataract Refract Surg* 2002;28:1613-7.