

Anterior Skull Base Reconstruction: Does Fat Preparation Matter?

Joshua Wood¹ Jaron Densky² John Boughter³ Merry Sebelik⁴ Courtney Shires¹

¹Department of Otolaryngology, Head and Neck Surgery, University of Tennessee Health Science Center, Memphis, Tennessee, United States

²Department of Otolaryngology, Head and Neck Surgery, Ohio State University, Columbus, Ohio, United States

³Department of Anatomy and Neurobiology, University of Tennessee Health Science Center, Memphis, Tennessee, United States

⁴Department of Otolaryngology, Head and Neck Surgery, Emory University, Atlanta, Georgia, United States

Address for correspondence Joshua W. Wood, MD, Department of Otolaryngology, Head and Neck Surgery, University of Tennessee Health Science Center, 910 Madison Ave, Suite 428, Memphis, TN 38163, United States (e-mail: jwood43@uthsc.edu).

J Neurol Surg Rep 2018;79:e31–e35.

Abstract

Objectives This article aims (1) to determine whether there is any difference in cerebrospinal fluid (CSF) leak rate after anterior skull base autologous fat reconstruction based on how the fat is prepared, and (2) to measure impact on surgical times by reconstruction type.

Design Translational animal model surgical technique 3-arm trial, comparing two different methods of autologous fat skull base reconstruction versus a nonreconstructed control group.

Setting Animal study.

Subjects Adult Sprague-Dawley rats.

Main Outcome Measures Resolution of CSF rhinorrhea after repair of a surgically created anterior skull base defect.

Results Both wet (uncompressed) and dry (compressed) fat reconstruction of an anterior skull base defect demonstrated lower CSF leak rates than nonreconstructed defects. Dry fat reconstruction achieved significance in superiority of controlling CSF leak over no reconstruction (64% success vs. 31%); while wet fat reconstruction trended toward significance (50% vs. 31%). Reconstruction procedure time was longer than nonreconstructed controls, but there was no significant difference between type of fat preparation in surgical time.

Conclusions This study demonstrates that drying and compressing the fat graft improves autologous fat reconstruction success for anterior skull base defects, and does not add significantly to surgical time over nonprepared fat.

Keywords

- ▶ autologous fat graft
- ▶ cerebrospinal fluid leak
- ▶ anterior skull base
- ▶ skull base reconstruction

Introduction

Autologous fat grafting for repair of skull base defects has a long history in otolaryngology and neurosurgery. In 1966 and 1969, Montgomery et al first described the use of fat grafts to prevent cerebrospinal fluid (CSF) leaks after sub-

occipital and translabyrinthine approaches to resect vestibular schwannomas.^{1,2} Collins was then the first to describe using fat grafts after transsphenoidal hypophysectomies to fill the sella and sphenoid sinuses in 1973.³ Shortly thereafter, from 1975 to 1979, multiple accounts of using autologous fat grafts from the thigh and abdomen were reported

received
October 10, 2017
accepted
March 12, 2018

DOI <https://doi.org/10.1055/s-0038-1645886>.
ISSN 2193-6358.

© 2018 Georg Thieme Verlag KG
Stuttgart · New York

License terms



after transthemoidal and transsphenoidal hypophysectomies.⁴ In current practice, autologous fat grafting has been ubiquitously adapted as a major component of skull base reconstruction.

Wigand first described the endoscopic repair of nasal CSF leaks in 1981.⁵ During the next three decades, alongside the advancement of endoscopic endonasal surgery, refinements in anterior skull base (ASB) reconstruction techniques have resulted in more successful endoscopic CSF leak repairs and radical tumor extirpations.⁶ Now, endoscopic endonasal repair is the standard of care for most ASB reconstructions.⁷ The goal of reconstruction is to create a watertight dural seal to effectively isolate the intracranial cavity from the sinonasal cavity and obliterate dead space.

The most commonly used free tissue grafts for ASB repair are fat, fascia, muscle, bone, and periosteum. Locoregional vascularized flaps and free tissue transfers are used for larger defects and persistent CSF leaks. Additionally, several biomaterials are often adjunctively utilized for preventing and treating CSF leaks.^{8–13} The choice of graft is based on the size, location, and character of the defect in addition to the presence of an intraoperative CSF leak, and other factors such as prior or future radiation treatment. Despite varying surgeon preferences and clinical scenarios, one of the most universal autologous grafts is adipose tissue, either alone or in combination with other tissues.

Although there are numerous publications reviewing methods of fat harvesting and fat processing,^{14–17} there is a paucity of literature in regards to fat harvesting and processing for ASB reconstruction and CSF leak repair. Based on current evidence, the majority of fat grafts for ASB repair are simply harvested and placed without further processing, either alone or as part of a multilayered closure.^{8,9,18} There are no studies validating whether processing of the fat prior to implantation makes any difference as compared with nonprocessed fat in ASB repair for CSF leak control.

This study was initiated to evaluate the postharvest processing of autologous fat grafts for ASB repair. After reviewing the processing techniques used for fat grafts in soft-tissue augmentation,^{14–17,19,20} we selected gauze sponge drying and compressing as a practical and proven method for enhancing fat graft survival. We then expanded this technique to the preparation of autologous fat grafts for ASB repair in an animal model—previously established by Nishihira and McCaffrey²¹—to determine whether processed fat would lead to lower rates of postoperative CSF leaks. Since autologous adipose tissue will remain an important element in skull base repair due to proven efficacy, low morbidity, and high availability, establishing whether processed fat is equally effective may result in quicker surgical times, less donor-site morbidity, and improved patient outcomes.

Methods

The protocol was reviewed and approved by the Institutional Animal Care and Use Committee at University of Tennessee Health Science Center. Adult male Sprague-Dawley rats were used for the study, and they were housed and cared for in the

Animal Care Center. A minimum of 10 animals per group (control, wet fat, and dry fat) was anticipated to carry sufficient power in a power analysis.

For all three groups of animals, ASB defects were created in the same manner, using a protocol modified from that previously described by Nishihira and McCaffrey. Anesthesia was induced with intraperitoneal injection of ketamine and xylazine, dosed at 86/13 mg/kg. The rats were placed prone on a heating pad and under a dissecting microscope to facilitate lighting and magnification. A midline incision from the skull vertex to the nasion (~20 mm) was performed, with subperiosteal elevation to expose the nasofrontal suture line (► **Fig. 1**). A unilateral skull base defect was created at the nasofrontal suture line using a rotary tool (Dremel, Robert Bosch Tool Corp.) with a 2-mm burr, creating an ~2 × 5 mm opening. The side of the defect, right or left, was alternated between animals. To ensure the skull base defect had been sufficiently created to allow passage of CSF from the cranial cavity to the nasal cavity, sinus mucosa was visualized at the anterior portion of the defect and the frontal lobe and olfactory bulb was seen at the posterior aspect.

The animals were divided among three reconstruction arms. To minimize technical bias, the reconstruction groups were interspersed throughout surgery days and not performed sequentially. Right- and left-sided defects were assigned evenly among reconstruction groups. All the surgeries were performed by a single researcher. One-third of

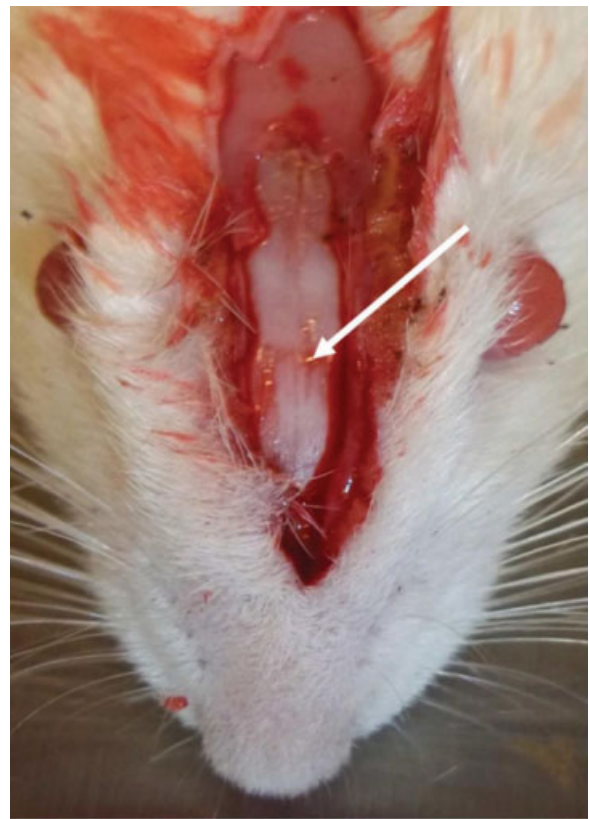

Fig. 1 The nasofrontal suture line (arrow) was identified to orient an anterior skull base defect, created using a Dremel rotary tool. Left- and right-sided defects were evenly created within each group.

the animals served as the control group, in which the scalp incision was closed with 4-0 nylon suture immediately after creation of the skull base defect, and allowed to emerge from anesthesia.

The second group was the unprepared, or wet fat group. In this group, an autologous, uncompressed wet fat graft was used to fill the defect. The fat was harvested by making a 1-cm incision in the intrascapular area to remove ~1 to 2 mm³ of adipose tissue. This area was chosen because it is accessible while the animal is still in position for skull base exposure, and eliminates the need to mobilize the animal while the skull base defect is open. Additionally, in the rat model, there is a relatively greater amount of adipose tissue in the intrascapular region than in the abdominal or thigh region, as would be selected in a clinical scenario. The fat harvest site was closed with 4-0 nylon suture. The harvested fat was packed tightly into the skull base defect, and fibrin sealant (Evicel, a product of Ethicon US, LLC) was placed over the reconstruction. The skin was closed as previously described for the control group, and the animal allowed to emerge from anesthesia.

The third group was the specially prepared fat, or dry fat group. Intrascapular fat was harvested as before but a greater volume (2–3 mm³) was procured to account for compression. The fat was dried and compressed by rolling it between gauze sponges. The prepared fat was used to tightly fill the defect, sealed over with fibrin sealant, with skin closure accomplished as in the wet fat and control groups, followed by emergence from anesthesia.

Animals in all groups received subcutaneous injection of 3 mL of normal saline for postoperative hydration, and an injection of buprenorphine 0.03 mg/kg for analgesia prior to awakening. The animals were monitored for 2 to 3 hours until fully awake and taking oral feeds, after which they were transported to the animal care facility. The daily monitoring and care were performed by staff in the animal care facility. The animals were allowed to recover and heal for a minimum of 21 days; the length of time averaged 26.7 days.

After this recovery time, anesthesia was again induced with intraperitoneal ketamine/xylazine mixture as described above. The incision over the skull was carefully opened as to not disturb the reconstruction. A burr hole was created in the parietal skull using the rotary tool, away from the skull base defect, and 0.1 mL of 5% fluorescein was injected into the subarachnoid space. The animals were monitored for 2 hours under anesthesia to allow circulation

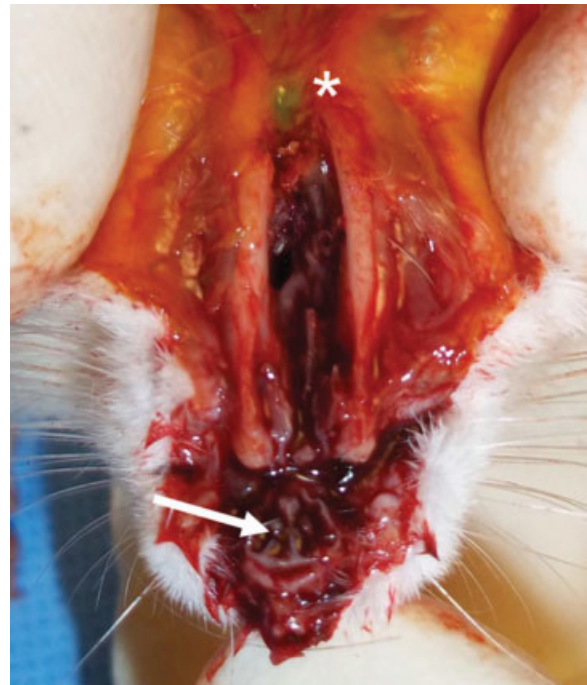


Fig. 2 Fluorescein was introduced through a parietal skull burr hole (asterisk). After time for cerebrospinal fluid (CSF) circulation and subsequent euthanasia, nasal bones were removed (arrow) and the nasal cavities inspected for the presence or absence of fluorescein under microscopic vision.

of the fluorescein in the CSF, after which the animals were humanely euthanized by asphyxiation and cervical dislocation. The nasal bones were removed (→Fig. 2) and the nasal cavities were inspected under the dissection microscope for the presence or absence of fluorescein.

Results were recorded and statistical analysis performed on the animal characteristics, procedural times, and CSF leak rates, using statistics embedded in Microsoft Excel for Mac and SISA.

Results

A total of 47 male adult Sprague-Dawley rats were used, with 41 animals completing the protocol. Four animals expired during induction of anesthesia, and two from the control group expired during the postoperative period. ▶Table 1 shows the characteristics of the animals in each of the

Table 1 Characteristics of each treatment group

	Control (no reconstruction)	Wet (uncompressed) fat	Dry (compressed) fat
Number of animals	13	14	14
Preoperative weight (g)	327.8	346.9	339.4
Left:Right defects	7:6	7:7	6:8
Healing time (d)	25.54	27.14	27.29
Weight gain (g)	43.3	36.8	39.8

Note: There were no differences between the groups, $p = 0.16$.

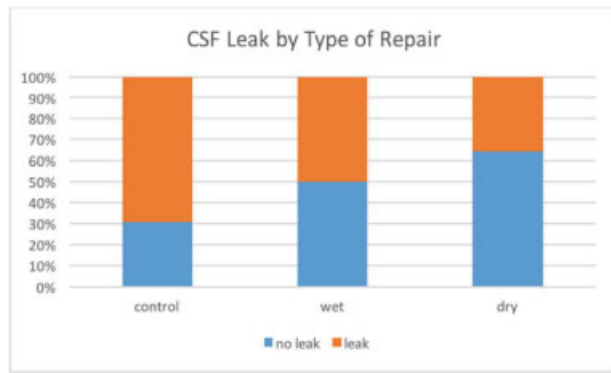

Fig. 3 Results: cerebrospinal fluid leak rates. Control to wet, $p = 0.15$, control to dry, $p = 0.04$, wet to dry, $p = 0.22$; significance defined as $p < 0.05$.

reconstruction arms. The days between the creation of the defect and fluorescein injection (healing time), averaged 25.5, 27.1, and 27.3 days, respectively, for the three groups. Baseline weights and change in weight over the study period were recorded. There were no differences among the groups calculated by an analysis of variance (ANOVA).

The main outcome was the rate of persistent CSF leak, as indicated by presence of visualized fluorescein in the nasal cavity. The control group had a persistent CSF leak rate of 69%, the wet fat group had a leak rate of 50%, and the dry fat group had a leak rate of 36% (►Fig. 3). The most striking difference was observed between the dry compressed fat animals and control nonreconstructed animals (64% vs. 31% success, $p < 0.05$). While the wet fat group appeared superior to no reconstruction (50% vs. 31% success), analysis did not achieve significance ($p = 0.15$). Similarly, direct comparison of wet versus dry preparation showed a higher success rate for dry compressed fat (64% vs. 50% success), but analysis did not achieve significance ($p = 0.22$).

We also looked at surgical times between the groups. As anticipated, the average surgical times between the control and reconstruction groups differed significantly at 15.3 minutes (control), 20.1 minutes (wet fat), and 22.6 minutes (dry fat) (►Fig. 4). One-way ANOVA significant effect of group $F(2, 40) = 35.14$, $p < 0.0001$. Post hoc tests (Turkey) show that each group is significantly different from one another.

Discussion

In analysis of surgical times, we found that there was a statistically significant difference between no reconstruction, and the two types of fat reconstruction. In the clinical setting, this difference may not occur as the fat graft harvest can take place simultaneously. The clinically relevant graft harvest donor sites, abdomen and thigh, are accessible during the skull base exposure portion of the case. Simultaneous harvest and preparation was not feasible in this animal model.

The mechanism of skull base repair relies mainly on dead space obliteration and mechanical reinforcement of the primarily repaired dura against CSF pressure. For large skull

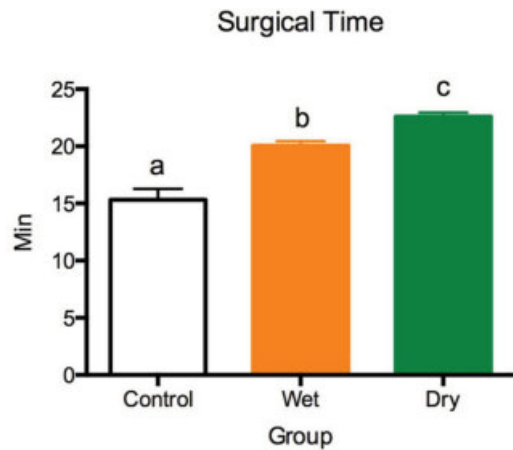


Fig. 4 Procedure (surgical) time. One-way analysis of variance (ANOVA) significant effect of group $F(2, 40) = 35.14$, $p < 0.0001$.

base defects, adipose tissue is often used as a bolster for a multilayered closure. However, successful use of a fat graft alone for large defects has been reported.¹⁴ The success of a fat graft depends on adipocyte survival which in turn relies on graft neovascularization and neoadipogenesis.¹⁵ A major factor in graft survival and performance is contact with a vascularized recipient site.¹⁶ Mashiko and Yoshimura showed that grafted adipocytes and adipocyte-derived stem cells (ASCs) within 100 to 300 μm of a surface exposed to a vascularized recipient will survive. Within 2 to 4 weeks, zones of survival and regeneration are demarcated.²² Therefore, maximizing the number of adipocytes and ASCs available to survive and regenerate would seem to enhance integrity of the graft over time.

In our study, we sought to determine if drying and compressing the autologous fat graft led to a higher success rate in ASB reconstruction. We hypothesized that by preparing the adipose tissue in such a way, it would allow the grafting of a higher percentage of viable cells. This would in turn lead to a higher rate of successful closure of the skull base defect.

We defined success as no evidence of fluorescein in the nasal cavities on final inspection after the animals had been sacrificed. The rate of success in the control group with no reconstruction was 31%. When wet, or unprepared fat, group was used for the reconstruction, the success rate increased to 50%. However, when fat that had been prepared by drying and compression was used for the reconstruction, the success rate rose to 64%.

Conclusion

This study demonstrates that drying and compressing the fat graft improves autologous fat reconstruction success for ASB defects, and does not add significantly to surgical time over nonprepared fat. Further, our results show that although wet fat reconstruction trended toward higher success rates in the closure of ASB reconstructions as compared with no reconstruction, dried and compressed autologous fat grafts did achieve statistically significant improvement. This study

validates the practice of compressing fat grafts prior to reconstruction of ASB defects.

Note

This was presented as an oral presentation at the North American Skull Base Society Annual Meeting in February 20–22, 2015.

Disclosures

None.

References

- Montgomery WW, Ojemann RG, Weiss AD. Suboccipital-translabrynthine approach for acoustic neuroma. *Arch Otolaryngol* 1966;83(06):566–569
- Montgomery WW. Translabrynthine resection of the small acoustic neuroma. *Arch Otolaryngol* 1969;89(02):319–325
- Collins WF. Hypophysectomy: historical and personal perspective. *Clin Neurosurg* 1974;21:68–78
- Ziu M, Jimenez DF. The history of autologous fat graft use for prevention of cerebrospinal fluid rhinorrhea after transsphenoidal approaches. *World Neurosurg* 2013;80(05):554–562
- Wigand ME. Transnasal ethmoidectomy under endoscopic control. *Rhinology* 1981;19(01):7–15
- Schmalbach CE, Webb DE, Weitzel EK. Anterior skull base reconstruction: a review of current techniques. *Curr Opin Otolaryngol Head Neck Surg* 2010;18(04):238–243
- Schlosser RJ, Bolger WE. Nasal cerebrospinal fluid leaks: critical review and surgical considerations. *Laryngoscope* 2004;114(02):255–265
- Soudry E, Turner JH, Nayak JV, Hwang PH. Endoscopic reconstruction of surgically created skull base defects: a systematic review. *Otolaryngol Head Neck Surg* 2014;150(05):730–738
- Zanation AM, Thorp BD, Parmar P, Harvey RJ. Reconstructive options for endoscopic skull base surgery. *Otolaryngol Clin North Am* 2011;44(05):1201–1222
- Dusick JR, Mattozo CA, Esposito F, Kelly DF. BioGlue for prevention of postoperative cerebrospinal fluid leaks in transsphenoidal surgery: a case series. *Surg Neurol* 2006;66(04):371–376, discussion 376
- Seda L, Camara RB, Cukiert A, Burattini JA, Mariani PP. Sellar floor reconstruction after transsphenoidal surgery using fibrin glue without grafting or implants: technical note. *Surg Neurol* 2006;66(01):46–49, discussion 49
- Germani RM, Vivero R, Herzallah IR, Casiano RR. Endoscopic reconstruction of large anterior skull base defects using acellular dermal allograft. *Am J Rhinol* 2007;21(05):615–618
- Eloy JA, Choudhry OJ, Friedel ME, Kuperan AB, Liu JK. Endoscopic nasoseptal flap repair of skull base defects: is addition of a dural sealant necessary? *Otolaryngol Head Neck Surg* 2012;147(01):161–166
- Kakagia D, Pallua N. Autologous fat grafting: in search of the optimal technique. *Surg Innov* 2014;21(03):327–336
- Bucky LP, Percec I. The science of autologous fat grafting: views on current and future approaches to neoadipogenesis. *Aesthet Surg J* 2008;28(03):313–321, quiz 322–324
- Pu LL. Towards more rationalized approach to autologous fat grafting. *J Plast Reconstr Aesthet Surg* 2012;65(04):413–419
- Gir P, Brown SA, Oni G, Kashfi N, Mojallal A, Rohrich RJ. Fat grafting: evidence-based review on autologous fat harvesting, processing, reinjection, and storage. *Plast Reconstr Surg* 2012;130(01):249–258
- Fonmarty D, Bastier PL, Lehot A, Gimbert E, de Gabory L. Assessment of abdominal fat graft to repair anterior skull base after malignant sinonasal tumor extirpation. *Otolaryngol Head Neck Surg* 2016;154(03):540–546
- Minn KW, Min KH, Chang H, Kim S, Heo EJ. Effects of fat preparation methods on the viabilities of autologous fat grafts. *Aesthetic Plast Surg* 2010;34(05):626–631
- Ramon Y, Shoshani O, Peled IJ, et al. Enhancing the take of injected adipose tissue by a simple method for concentrating fat cells. *Plast Reconstr Surg* 2005;115(01):197–201, 202–203
- Nishihira S, McCaffrey TV. The use of fibrin glue for the repair of experimental CSF rhinorrhea. *Laryngoscope* 1988;98(6 Pt 1):625–627
- Mashiko T, Yoshimura K. How does fat survive and remodel after grafting? *Clin Plast Surg* 2015;42(02):181–190