

# Convulsive syncope as presenting symptom of carotid body tumors: Case series

Ali Akbar Beigi, Fereshteh Ashtari<sup>1</sup>, Mehri Salari<sup>1</sup>, Rasul Norouzi<sup>1</sup>

Departments of Vascular Surgery, <sup>1</sup>Neurology, Isfahan University of Medical Sciences, Isfahan, Iran

Carotid body tumor (CBT) is paraganglioma and mainly found in the carotid bifurcation. The manifestations of the tumor are variable; in most cases, it presents as a non-symptomatic slow-growing mass, rarely compression of carotid body induces bradycardia and hypotension and repeated syncope, prolonged syncope can cause convulsion. Convulsive syncope occurred in 0.03% of patients with syncope. In this paper, we report three cases with CBT and convulsive syncope for which surgery was done and patients did not experience syncope again.

**Key words:** Carotid body tumor-convulsive syncope, epilepsy, dnmscns

## INTRODUCTION

Carotid body tumors (CBT) are rare tumor developed from the neural crest. Manifestations of the tumor are variable; mainly it presents as a asymptomatic mass having slow growth and compressing the surrounding anatomic structures,<sup>[1]</sup> it can rarely cause syncope by compression of the peripheral nerves such as the vagus and cervical sympathetic nerve.<sup>[2]</sup>

Syncope is characterized by loss of consciousness and falling, because of transient cerebral hypo perfusion.<sup>[3]</sup> We report three cases with CBT and recurrent syncope attacks and convulsive syncope. Their symptoms disappeared after surgical removal.

## CASE REPORT

### Case 1

A 78-year-old woman was admitted to Al-Zahra Hospital, Isfahan, Iran, in December 2010, because of episodic vertigo and attack of loss of consciousness when she was in a sitting position. These attacks were accompanied with perspiration, pallor and bradycardia and after a few seconds followed with colonic movement of left extremities. She regained consciousness after taking supine posture.

The past medical history was negative except for the history of toxoplasmosis 7 years ago; drug and family history were unremarkable. Neurological examination was normal in a lying position but when she was sitting she became pale, lost her consciousness and convulsive syncope happened. Electroencephalography (EEG) did not show any abnormal discharges, Brain magnetic

resonance imaging (MRI) and computed tomography scan, Holter monitoring, echocardiography and coronary angiography were normal. Cervical MRA and digital subtraction angiography (DSA) revealed CBT [Figure 1].

Classic resection of the CBT was performed and a 3 cm × 4 cm mass in the carotid bifurcation was removed. The post-operative period was uneventful, and the patient became completely symptom free.

### Case 2

A 65-year-old woman has referred to Al-Zahra Hospital, Isfahan, Iran, in September 2011, because of recurrent episodes of loss of consciousness since 10 months ago, the first one occurred when she was standing for a long time; her relatives described this attack as a fit of falling, loss of consciousness, and tonic movements that took 1-2 min; she was treated with antiepileptic drugs, but her attacks continued and repeated more and more. She has been treated as a case of intractable epilepsy. Her attacks began with the rotation of neck as focal seizure, too.

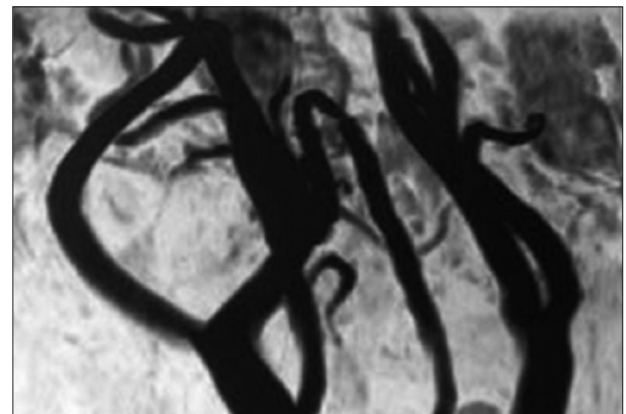


Figure 1: Cervical MRI confirming the presence of a carotid body tumor

**Address for correspondence:** Dr. Mehri Salari, Al-Zahra Hospital, Isfahan, Iran. E-mail: mehri.salari@gmail.com

**Received:** 14-05-2012; **Revised:** 20-11-2012; **Accepted:** 21-01-2013

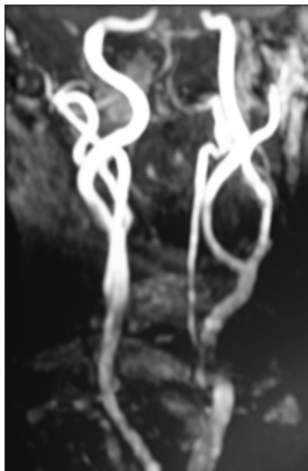
Drug history was negative except for phenytoin and carbamazepin that started from 10 months ago. The neurological examination was normal but in the general examination during carotid auscultation suddenly the patient became pale and impaired her consciousness as well as, adverse head movement and then tonic movement of limbs. This event continued for 1-2 min and then she became conscious. Gentle examination revealed painless, oval shape, mobile, 2 cm × 3 cm mass in the right mandibular angle.

Cervical magnetic resonance imaging (MRA) and computed tomography (CT) angiography showed separation between the right internal and external carotid arteries on left-side [Figure 2]. Cervical Doppler color sonography showed soft-tissue, hypo echo mass at carotid bifurcation. Electrocardiography (ECG), echocardiography and exercise test were in normal category. The patient was referred to the vascular surgeon and excision of CBT and lymphadenectomy was done. Report of pathology confirmed carotid body of three rather firm, tan colored tissue fragments measuring 5.5 cm × 5.2 cm that on section were solid with homogenous features.

After surgery, the patient did not experience another attack of syncope and anticonvulsive drugs discontinued.

### Case 3

A 37-year-old woman was admitted to our hospital because of repeated attack of loss of consciousness for the last 3 months without any predisposing factor, aura and postictal period with duration of some seconds; her relative said that she became pale and unresponsive and sometimes ending to clonic movements of limbs when she did not have a recombinant position. She was healthy otherwise. The drug history and family history of epilepsy was negative; neurological examination was unremarkable but general



**Figure 2:** Cervical MRA showed separation between internal and external carotid arteries on left side suggested carotid body tumor

examination revealed bilateral non tender, mobile, well defined masses in her neck.

EEG did not show any epileptic discharges. ECG showed sinus rhythm at a rate of 70 beats/min, other cardiac investigation, including echocardiography and treadmill exercise test were in a normal range. Brain MRI showed no abnormality. Because of the neck masses multi slice CT angiography of the neck was done and revealed enhanced mass lesions on the carotid bifurcation bilaterally. Common carotid arteries, internal carotid arteries, vertebralbasilar arteries and thyroid glands were normal; these findings were mostly consistent with CBT. Cervical MRA and Doppler sonography confirmed this diagnosis.

Surgery was performed for neck mass on the both sides. A 4 cm × 5 cm mass was removed from right carotid bifurcation and 3 cm × 4 cm mass from left side too. The patient passed post-operative period successfully and in the follow-up work up she became free from her previous symptoms.

## DISCUSSION

CBT arising from paraganglia has higher incidence in female than males and more common presenting in 50-70.<sup>[4]</sup>

The pathogenesis of CBT remains uncertain but hypoxia and genetic factors are probable mechanisms. Some studies have shown that low pressure of oxygen in the blood and chronic hypoxia both continuously and intermittently due to living in high altitude and sleep apnea respectively, can precipitate carotid gland hyperplasia and hypertrophy. Genetic bases established in up to 35% of individual with CBT who have a higher occurrence of multiple ganglioneuroma in childhood if they experience chronic hypoxia.<sup>[5]</sup>

A common manifestation of CBT is a slow-growing, painless mass in the neck, located anterior to the sternocleidomastoid muscle at the level of the hyoid bone that usually was found accidentally by patients or physicians.<sup>[6]</sup> Occasionally, a carotid pulse, bruit or thrill may be associated with the mass.<sup>[6]</sup> In rare instances carotid sinus syndrome is manifestation of CBT that is characterized by syncope and hypotension due to a hypersensitive carotid sinus located in the carotid bifurcation.<sup>[7,8]</sup> Actually, carotid sinus is a baroreceptor which is a collection of nerve ending that locates at the carotid bifurcation, regulates the cardiac rhythm and blood pressure.<sup>[7]</sup> Its compression, therefore, induces bradycardia, hypotension, repeated syncope and falling.<sup>[2]</sup> Syncope is an important differential diagnosis for patients with recurrent loss of consciousness. Prolonged syncope can cause tonic movements and it has been shown that as a convulsive syncope<sup>[9,10]</sup> the prevalence of convulsive

syncope is approximately 0.03%.<sup>[11]</sup> Furthermore, seizure must be considered in recurrent episode of unconsciousness; Clinically, distinguishing between seizure and syncope is difficult, although the presentation of both conditions are the same, their pathophysiology are totally different; cerebral hypo perfusion marked in syncope does not happen in epilepsy because epilepsy is due to abnormal electrical activity.<sup>[11]</sup>

To the best of our knowledge, there are just a few cases reported by syncope and CBT,<sup>[2,11,12]</sup> and recurrent convulsive syncope as presentation of carotid body is very rare. We had three patients with convulsive syncope and CBT, which were female.

CBTs is an infrequent cause of syncope, and convulsion is a rare presentation of syncope, so frequent happening of convulsive syncope and CBTs assume that convulsive syncope is more common in CBTs than other causes of syncope. In addition, the higher frequency in females increases probability for genetic base of this tumor, this hypothesis is supported by bilateral CBT in third case who is young, and based on previous report bilateral CBT more commonly occurring on familial basis.<sup>[13]</sup> Another hypothesis is that females are more sensitive to hypoxic events to improve CBT. Finally, the improvement of syncope by surgery suggested that CBTs is a reversible cause of syncope and that surgery could be a good therapeutic approach.

The gold standard for the diagnosis of CBTs is a DSA, another diagnostic way which can confirm the CBTs is Color Doppler Sonography.<sup>[6]</sup>

Treatment of choice for CBTs is the surgical resection.<sup>[5]</sup> Surgical planning depends on the relation of the tumor to the internal carotid artery (ICA), so, degree of contact of the tumor with the ICA was used to classify the tumor radiologically into three types in an attempt to predict the Shamblin group of the tumors: Type I, less than or equal to 180°; type II, greater than 180° and less than 270°; and type III, greater than or equal to 270°,<sup>[13]</sup> based on this criteria all of our patients have had grade I CBT, If the tumor have small and still display.

Outlying involvement of the ICA, this needs to refer patients to the surgeon, because the small size may understand incorrectly to signify greater ease of resection.<sup>[14]</sup>

Subsequently, in each patient with recurrent episodes of syncope, especially convulsive syncope CBT must be considered as a suspected treatable cause.

## REFERENCES

1. Ghoreishi M, Akbar-Beigi A, Tahery D, Sehhat S. Fever as the main presenting symptom of a carotid body tumor. *Arch Iran Med* 2008;11:214-7.
2. da Gama AD, Cabral GM. Carotid body tumor presenting with carotid sinus syndrome. *J Vasc Surg* 2010;52:1668-70.
3. Kohno R, Abe H, Akamatsu N, Oginosawa Y, Tamura M, Takeuchi M, *et al.* Syncope and ictal asystole caused by temporal lobe epilepsy. *Circ J* 2011;75:2508-10.
4. Ma D, Liu M, Yang H, Ma X, Zhang C. Diagnosis and surgical treatment of carotid body tumor: A report of 18 cases. *J Cardiovasc Dis Res* 2010;1:122-4.
5. Wieneke JA, Smith A. Paraganglioma: Carotid body tumor. *Head Neck Pathol* 2009;3:303-6.
6. Wang SH, Chiu KM, Cheng PW. Bilateral carotid body paragangliomas. *CMAJ* 2011;183:E606.
7. Toorop RJ, Scheltinga MR, Moll FL, Bleys RL. Anatomy of the carotid sinus nerve and surgical implications in carotid sinus syndrome. *J Vasc Surg* 2009;50:177-82.
8. Rosenkranz L, Schell AR. Carotid body tumor as reversible cause of recurrent syncope. *N Y State J Med* 1984;84:38-9.
9. Lempert T, Bauer M, Schmidt D. Syncope: A videometric analysis of 56 episodes of transient cerebral hypoxia. *Ann Neurol* 1994;36:233-7.
10. Lin JT, Ziegler DK, Lai CW, Bayer W. Convulsive syncope in blood donors. *Ann Neurol* 1982;11:525-8.
11. Ozkara C, Metin B, Kucukoglu S. Convulsive syncope: A condition to be differentiated from epilepsy. *Epileptic Disord* 2009;11:315-9.
12. Vincelj J, Kirin M, Borković Z, Lajtman Z, Horzić M. Syncope caused by carotid body tumor. *Acta Med Croatica* 1996;50:213-5.
13. RUSH BF Jr. Familial bilateral carotid body tumors. *Ann Surg* 1963;157:633-6.
14. Arya S, Rao V, Juvekar S, Dacruz AK. Carotid body tumors: Objective criteria to predict the Shamblin group on MR imaging. *AJNR Am J Neuroradiol* 2008;29:1349-54.

**How to cite this article:** Beigi AA, Ashtari F, Salari M, Norouzi R. Convulsive syncope as presenting symptom of carotid body tumors: Case series. *J Res Med Sci* 2013;18:164-6.

**Source of Support:** Nil, **Conflict of Interest:** None declared.