

Primary adrenal lymphoma: Differential involvement with varying adrenal function

Shiekh Aejaaz Aziz, Bashir Ahmad Laway¹, Imran Rangreze, Mohd Iqbal Lone², Syed Nisar Ahmad

Departments of Medical Oncology, ¹Endocrinology and ²Pathology, Sher-I-Kashmir Institute of Medical Sciences, Srinagar, Kashmir, India

ABSTRACT

Primary adrenal Non-Hodgkin's lymphoma is rare. The symptoms of the disease and response to treatment are variable depending on the type of lymphoma, tumor size, and presence of adrenal insufficiency. We report two cases of primary adrenal lymphoma who had varied presentations. One presenting with abdominal pain and weight loss was documented to have unilateral disease without any adrenal insufficiency and showed a good response to combination chemotherapy, while the second one had bilateral adrenal involvement with adrenal insufficiency and died after second chemotherapy. Functional adrenal involvement in lymphoma depends on the extent of involvement; patients with bilateral involvement almost always have adrenal insufficiency.

Key words: Adrenal insufficiency, primary adrenal Non-Hodgkin's lymphoma, unilateral disease

INTRODUCTION

Adrenal involvement as a part of disseminated lymphoma is common. Adrenal gland is a rare site of primary non-Hodgkin's lymphoma (NHL).^[1] About 100 such cases have been reported so far, with bilateral involvement in 70% of them.^[2-4] Symptoms may occur due to tumor itself or adrenal failure. Prolonged disease-free survival appears uncommon, and most of the patients reported in the literature have died within 1 year despite aggressive chemotherapy.^[5] Unilateral involvement can occur in less than one-third of the cases. We report two cases of primary adrenal NHL. One with unilateral adrenal involvement had a normal adrenal function and other with bilateral involvement had adrenal insufficiency.

CASE REPORTS

Case 1

A 34-year-old male presented with 3 months history of pain in the left flank and weight loss of around 20 kg over 3 months. His medical history was non-contributory. Clinical examination revealed blood pressure of 120/80 mmHg without any postural drop. There was no lymphadenopathy, and abdominal examination revealed mild splenomegaly. Investigations revealed a normal complete blood count with normal liver and kidney function tests. Serum electrolytes were within normal limits. Lactate dehydrogenase was 487 U/L (normal range 320–460 U/L). X-ray chest was within normal limits. Ultrasonography (USG) of the abdomen demonstrated a retroperitoneal mass in the left side of the abdomen with hepatosplenomegaly without lymphadenopathy. Contrast-enhanced computed tomography (CT) scan abdomen showed a large 13 × 8.8 × 9.7 cm, heterogeneously enhancing mass in left suprarenal area involving superior pole of left kidney, displacing spleen and pancreas with a normal sized adrenal gland on the right side without any retroperitoneal lymphadenopathy [Figure 1a]. Fine needle aspiration cytology of the lesion revealed malignant round cell tumor favoring high-grade lymphoma. Subsequently a CT-guided trucut biopsy of

Access this article online

Quick Response Code:



Website:
www.ijem.in

DOI:
10.4103/2230-8210.83414

Corresponding Author: Dr. Bashir Ahmad Laway, Department of Endocrinology, Sher-I-Kashmir Institute of Medical Sciences, Srinagar, Kashmir, India. E-mail: drlaway@gmail.com

the mass lesion was performed. Microscopic examination of the material revealed adipose tissue infiltrated by sheets of large monomorphic, transformed lymphoid cells with basophilic cytoplasm, and nuclei having vacuolar chromatin with two to three prominent nucleoli suggestive of non-Hodgkin's diffuse large B-cell lymphoma (DLBCL). Immunohistochemistry demonstrated CD20 positivity and did not stain for CD3 suggestive of B-cell lymphoma. Examination of bone marrow and CT imaging of chest was normal. Thus, based on the radiological and pathological assessment, a final diagnosis of primary adrenal non-Hodgkin's DLBCL was made. Although the patient had a normal sized right adrenal gland, the patient was subjected to adrenocorticotrophic hormone (ACTH) test. Serum sample for cortisol was taken in the morning in the basal state and 1 hour after giving 250 µg of synthetic ACTH. Basal cortisol was 11 µg/dL, and peak 1 hour cortisol was

23.2 µg/dL (normal value of >18 µg/dL). An informed consent was obtained from the patient. Meanwhile the patient was started on combination chemotherapy Rituximab, Cyclophosphamide, Adriamycin, Vincristine and Prednisolone(R-CHOP). Presently, the patient is asymptomatic for his disease and a follow-up contrast enhanced computed tomography (CECT) abdomen showed a marked regression in the adrenal size measuring 7.5 × 2.5 cm [Figure 1b].

Case 2

A 55-year-old male smoker, with diabetes mellitus for 4 years, controlled on metformin 500 mg/day, was admitted with 2 months history of marked weight loss, abdominal pain, vomiting, and passage of loose stools. His medical history was insignificant. On admission, physical examination revealed a normal blood pressure without any postural drop, decreased skin turgor, and hyperpigmentation over the buccal mucosa and lips. Investigations revealed anemia (Hb of 11 g/dL) with normal blood counts. His kidney and liver function tests were normal. Serum electrolytes were within normal limits. Lactate dehydrogenase was 813 U/L (normal range 320–460 U/L). Clinical suspicion of primary adrenal insufficiency was confirmed by a low morning serum cortisol of 7.2 µg/dL (normal value of 12–25 µg/dL) and peak cortisol response of 5.2 µg/dL to ACTH stimulation test (normal value of >18 µg/dL). Contrast-enhanced CT abdomen revealed bilateral solid adrenal masses encasing renal hilar vessels and inferior venacava with gastric antral wall thickening and splenomegaly [Figure 2a]. Subsequent CT-guided biopsy of the adrenal mass disclosed non-Hodgkin's DLBCL [Figure 2b], and immunohistochemistry showed diffuse CD20 positivity of lymphomatous cells [Figure 2c]. Bone marrow, CT

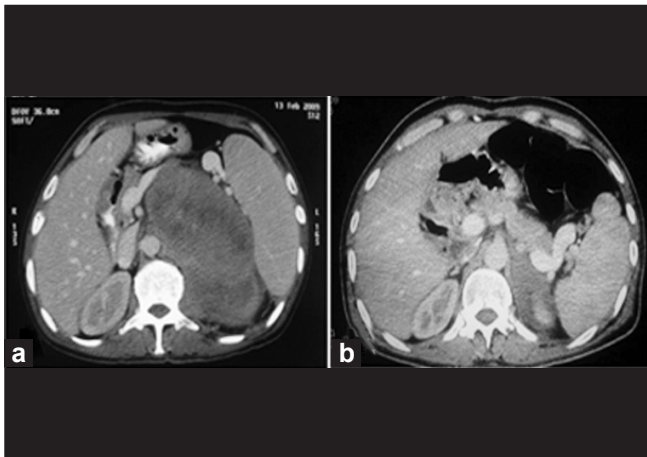


Figure 1: a) CECT abdomen revealing a large heterogeneously enhancing mass in the left suprarenal area involving superior pole of left kidney. b) CECT abdomen (post-chemotherapy) demonstrating a regressed left adrenal mass

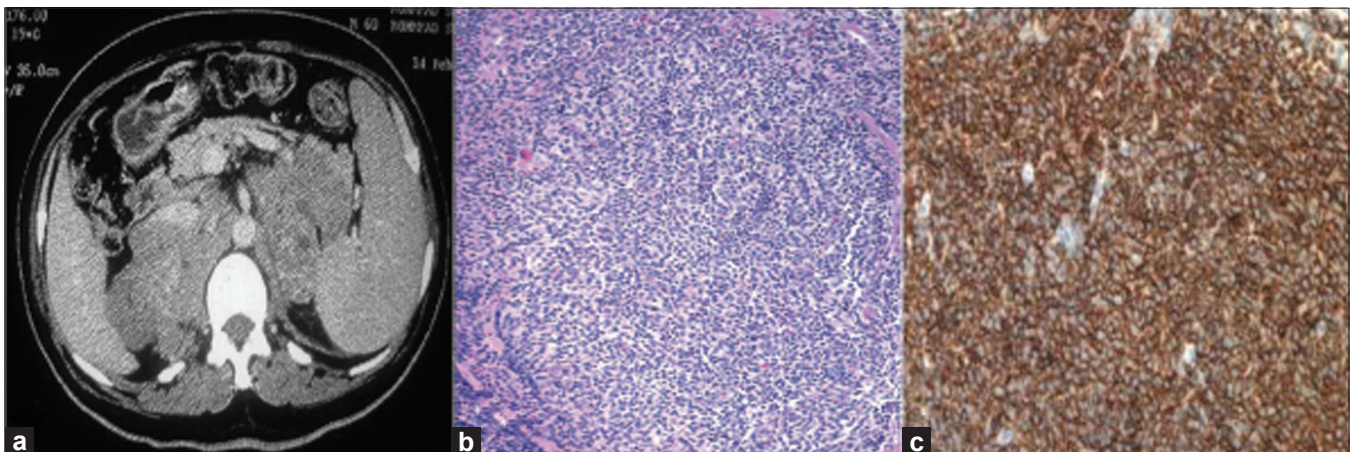


Figure 2: a) CECT abdomen revealing bilateral adrenal mass encasing renal vessels and inferior vena cava. b) Microphotograph showing total replacement of adrenal tissue by diffuse lymphomatous infiltrate of NHL (H and E, ×100). c) Immunohistochemistry showing diffuse CD20 positivity of lymphomatous cells

chest, and upper GI endoscopy revealed no abnormality. With this background of primary bilateral NHL and adrenal insufficiency, patient was started on steroids (prednisolone 5 mg and fludrocortisone 100 µg in the morning) and diabetes was controlled with two doses of premixed (30/70) insulin. He stabilized and was planned for combination chemotherapy Cyclophosphamide, Adriamycin, Vincristine and Prednisolone (CHOP). An informed consent was obtained from the patient. Patient received two cycles of chemotherapy but died at home after few days; cause of death could not be ascertained.

DISCUSSION

Most common bilateral adrenal masses in an area which is not endemic for tuberculosis are metastases from malignant tumors arising from lungs, breast, or colon; these are not usually associated with adrenal insufficiency because 90% of the adrenal glands have to be destroyed before adrenal insufficiency becomes clinically apparent.^[6] This explains the normal adrenal function in our first case who had unilateral adrenal involvement and presence of hypocortisol state in second having bilateral involvement. Adrenal gland involvement in disseminated NHL has been reported in 24% of patients in an autopsy study.^[5] In a series of 127 patients with NHL, adrenal insufficiency was reported in four cases.^[7] Primary adrenal lymphoma represents 3% of extranodal lymphomas that are extremely rare. To the best of our knowledge, only 116 such case have been reported so far.^[8]

With the use of advanced imaging techniques, there has been an increase in the incidence of adrenal lymphomas. Males are affected more than the females (M:F, 2:1), with a median age of presentation being 65 years. Bilateral cases constitute 70% of the total adrenal lymphomas with a median maximum diameter of 8 cm. The most common type of adrenal NHL is DLBCL phenotype, comprising 70% of cases.^[8,9] This type follows aggressive clinical course which can manifest itself as rapid adrenal enlargement and primary adrenal insufficiency without typical skin pigmentation.

The symptoms of this disease are variable and depend on the tumor size, type of lymphoma, or presence of adrenal insufficiency.^[8] Thus, patient may present with fever, lumbar pain, and or symptoms of adrenal insufficiency.^[6,10] Our cases represent two ends of the spectrum, viz, abdominal pain and marked weight loss as predominant manifestations in one with unilateral lesion, while as adrenal failure was the presentation in the second one with bilateral involvement.

Primary adrenal lymphomas should be considered in patients with elevated serum lactate dehydrogenase, characteristic CT findings of appearance of enlargement of adrenal gland with maintenance of adreniform shape with variable density of the lesion, and primary adrenal insufficiency.^[9,10] Magnetic resonance imaging enables differentiation of adrenal adenomas from other adrenal malignancies, but specific diagnosis might not be achieved during the study. The initial diagnosis can usually be established on the basis of image-guided FNA/ biopsy; however, it is still considered inadequate for diagnosis by many clinicians. Histological diagnosis is a gold standard in the evaluation of lymphoma. In our patients, diagnosis was established by image -guided FNA biopsy and subsequent immunohistochemistry.

Therapeutic modalities for adrenal lymphomas include surgery, combination chemotherapy, surgery followed by chemotherapy and/radiotherapy, and corticosteroid replacement. All the patients given palliative treatment had a fatal outcome. Relapses during the first few months after curative treatment have been reported.^[8,9] Old age, initial presentation with primary adrenal insufficiency, large tumor size, elevated serum Lactate dehydrogenase, and involvement of other organs generally carry a poor prognosis. After establishing diagnosis, our patients were started on combination chemotherapy. Presently, our first case with unilateral adrenal involvement has shown dramatic subjective and radiological response to chemotherapy (gained body weight and had marked regression in the size of affected adrenal gland on CECT abdomen), while as second patient died after two cycles of chemotherapy.

REFERENCES

1. Harris GJ, Tio FO, Von Hoff DD. Primary adrenal lymphoma. *Cancer* 1989;63:799-803.
2. Venizelos I, Tamiolakis D, Petrakis G. High grade primary adrenal intravascular large B-cell lymphoma manifesting as Addison's disease. *Rev Esp Enferm Dig* 2007;99:471-4.
3. Choi CH, Durishin M, Garbadawala ST, Richard J. Non-Hodgkin's lymphoma of the adrenal gland. *Arch Pathol Lab Med* 1990;114:883-5.
4. Freeman C, Berg JW, Culter SJ. Occurrence and prognosis of extranodal lymphomas. *Cancer* 1972;29:252-60.
5. Straus DJ, Filippa DA, Lieberman PH, Rousselet MC, Rievx D, Rohmer V, Ifrah N *et al.* The non-Hodgkin's lymphomas. A retrospective clinical and pathological analysis of 499 cases diagnosed between 1958-1969. *Cancer* 1983;51:101-9.
6. Ellis RD, Read D. Bilateral adrenal non-Hodgkin's lymphoma with adrenal insufficiency. *Postgrad Med J* 2000;76:508-9.
7. Gamelin E, Baldent V, Non V. Non-Hodgkin's lymphoma presenting with primary adrenal insufficiency. A disease with an under-estimated frequency? *Cancer* 1992;69:2333-6.

8. Ozimek A, Diebold J, Linke R, Heyn J, Hallfeldt K, Mussack T. Bilateral primary adrenal Non-Hodgkin's Lymphoma and primary adrenocortical carcinoma-Review of the literature pre operative differentiation of adrenal tumors. *Endocr J* 2008;55:625-38.
9. Mantzios G, Tsirigotis P, Veliou F, Boutsikakis I, Petraki L, Kolovos J, *et al.* Primary adrenal lymphoma presenting as Addison's disease: Case report and review of literature. *Ann Hematol* 2004;83:460-3.
10. Hamid Zargar A, Ahmad Laway B, Alam Wani K, Shah A, Ahmad M, Aejaz Aziz S, Iftikhar Bashir M, *et al.* Adrenal insufficiency due to primary adrenal non-Hodgkin's lymphoma. *Exp Clin Endocrinol Diabetes* 2004;112:462-4.

Cite this article as: Aziz SA, Laway BA, Rangreze I, Lone MI, Ahmad SN. Primary adrenal lymphoma: Differential involvement with varying adrenal function. *Indian J Endocr Metab* 2011;15:220-3.

Source of Support: Nil, **Conflict of Interest:** None declared.