




Technical Notes

Downward penetrating endplate screw technique under O-arm navigation posterior fusion in patients with osteoporotic vertebral body fractures associated with diffuse idiopathic skeletal hyperostosis

Daimon Shiraishi¹, Yu Yamamoto¹, Ishii Motonori¹, Yusuke Nishimura², Masahito Hara³, Ryuta Saito², Masakazu Takayasu¹

¹Department of Neurosurgery, Inazawa Municipal Hospital, Inazawa City, ²Department of Neurosurgery, Nagoya University Graduate School of Medicine, Nagoya, ³Department of Neurosurgery, Aichi Medical University, Nagakute, Japan.

E-mail: *Daimon Shiraishi - daimo333@yahoo.co.jp; Yu Yamamoto - yu_yamamoto_yuhcho@yahoo.co.jp; Ishii Motonori - mottoii99@gmail.com; Yusuke Nishimura - yusukenishimura0411@gmail.com; Masahito Hara - masahara219@hotmail.co.jp; Ryuta Saito - ryuta@med.nagoya-u.ac.jp; Masakazu Takayasumtakayas@aichi-med-u.ac.jp



*Corresponding author:

Daimon Shiraishi,
Department of Neurosurgery,
Inazawa Municipal Hospital,
Inazawa City, Japan.

daimo333@yahoo.co.jp

Received : 20 August 2022

Accepted : 08 September 2022

Published : 23 September 2022

DOI

10.25259/SNI_762_2022

Quick Response Code:



ABSTRACT

Background: A downward penetrating endplate screw (PES) technique combined with caudal anchor screws inserted in the upward direction under O-arm navigation (i.e., crossing screw technique) avoided screw backout and proximal junctional kyphosis (PJK) in three patients with osteoporotic vertebral body fractures and diffuse idiopathic skeletal hyperostosis (DISH).

Methods: The PES techniques were utilized for patients with T12 (one patient) and L1 (two patients) spontaneous fusion across the targeted vertebrae, with minimal damage to the involved endplates/intervertebral discs. The average number of instrumented vertebrae was 5.3.

Results: There were no perioperative complications over the mean follow-up period of 28.7 months; no screw loosening, and no PJK.

Conclusion: The PES technique prevented screw backout, and PJK in three patients with lumbar osteoporotic vertebral fractures and DISH.

Keywords: Diffuse idiopathic skeletal hyperostosis, Endplates penetrating screw, Osteoporotic vertebral body fracture, Posterior spinal fixation

INTRODUCTION

The penetrating endplate screw (PES) technique (i.e., single or double endplate penetrating screw SEPS or DEPS) was utilized for posterior fusions in three patients with lumbar osteoporotic vertebral body fractures and diffuse idiopathic skeletal hyperostosis (DISH).^[5] The PES technique involved the oblique insertion of longer screws penetrating one or two cephalad/caudad endplates.^[3,5] Here, we successfully utilized the PES technique under O-arm navigation to treat three patients with DISH and T12 or L1 osteoporotic lumbar vertebral fractures.

This is an open-access article distributed under the terms of the Creative Commons Attribution-Non Commercial-Share Alike 4.0 License, which allows others to remix, transform, and build upon the work non-commercially, as long as the author is credited and the new creations are licensed under the identical terms.

©2022 Published by Scientific Scholar on behalf of Surgical Neurology International

MATERIALS AND METHODS

Technique

Our institutional review board approved this study. The PES technique was utilized to treat three patients with lumbar vertebral body osteoporotic fractures (i.e., T12 [1 patient] and L1 [2 patients]) and DISH. Notably, the posterior rod/screw fusion was performed two levels above and two levels below the spontaneously fused index level fractured vertebral body.

Operative technique

For the two levels above the index fractured vertebral body, the cephalad PES screws were inserted in a downward direction from the outer cranial side to the inner caudal side; this included attempted penetration by the screw of two endplates, one at the index level and the other at the adjacent caudal level [Figures 1 and 2]. Application of each screw was included in the study: routine bony probing (i.e., with gear shift), K-wire placement, exchange with the screw tap, and finally, application of the cannulated screw (i.e., 50–55 mm in length). The caudal screws are similarly inserted but in an upward direction. Anchor screws are usually placed 2–3 levels above and below the vertebral fracture and were connected with appropriately contoured rods [Figure 3].

RESULTS

The average number of instrumented vertebrae was 5.3 (4–6) [Table 1]. The anchor screws were inserted two or three levels above (14 screws) and below (14 screws) the index vertebral body fracture levels. Three cranial screws penetrated two endplates, while ten screws penetrated only a single endplate. Of the 14 caudally placed screws, nine penetrated two endplates, while five penetrated a single endplate. There were no perioperative complications. Further, over the mean

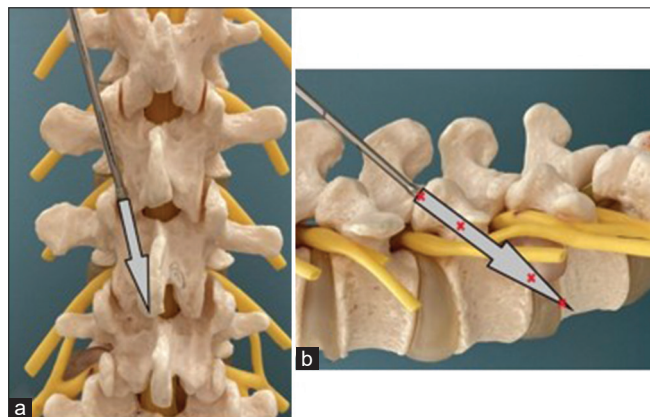


Figure 1: Trajectory of downward penetrating endplate screw (PES) technique. (a) AP view and (b) lateral view. Arrow; direction of insertion and red cross; strong fixation point with cortical bone.

follow-up period of 28.7 months, no screw loosening or proximal junctional kyphosis (PJK) was observed.

DISCUSSION

It is difficult to obtain rigid fixation in osteoporotic bone for patients with osteoporotic compression fractures and DISH patients. The endplate penetrating screw technique (i.e., lumbar pedicular transvertebral screw fixation) was first reported by Abdu *et al.* in 1994.^[1] It was extended to the

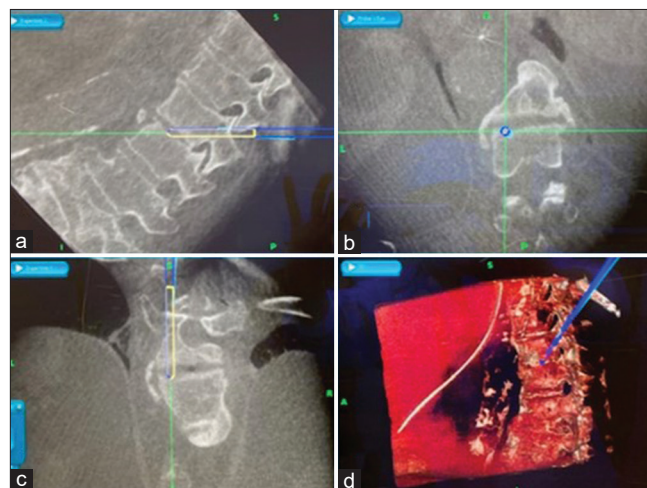


Figure 2: Screenshot from the O-arm image guidance system showing the intraoperative planned trajectory. (a) Sagittal view, (b) coronal view, white line; screw, green line; direction of insertion, blue line and circle; screwdriver. (c) axial view, and (d) 3D reconstructed cone-beam CT imaging.

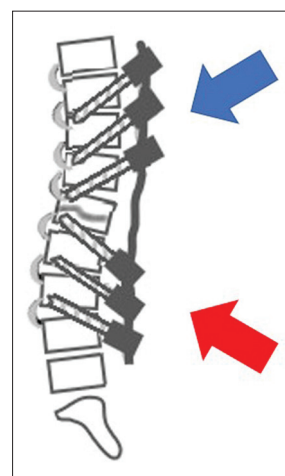


Figure 3: Rod connection in patients with diffuses idiopathic skeletal hyperostosis between downward (blue arrow) and upward (red arrow) PESSs, resulting in crossing screw direction between the cranial and caudal anchors.

Table 1: Demographic information in patients with downward penetrating endplate screw technique.

	Case 1	Case 2	Case 3
Sex	Male	Male	Male
Age (years)	88	82	70
DISH range	T2-L3	T7-L4	T7-L4
Affected vertebrae	T12	L1	L1
Instrumented vertebrae	T9-L3	T10-L4	T11-L3
Number of Instrumented vertebrae	6	6	4
Applied d/u PES technique	T9 10 dPES L2 3 uPES	T10 11 12 dPES L2 3 4 uPES	T11 12 dPES L2 3 uPES
Applied Conventional PPS technique	T11 L1	none	none
Implant failure	none	none	none
Follow-up period (months)	31	30	25

d/u PES: downward/upward penetrating endplate screw, DISH: Diffuse idiopathic skeletal hyperostosis

thoracic spine by Nottmeier *et al.* in 2013.^[4] Takeuchi *et al.* in 2020 developed the DEPS technique that showed a 134% higher average insertion torque in spite of using a smaller diameter screw versus conventional PPS techniques.^[5] The screw torque in the DEPS technique was stronger as the longer obliquely inserted screws could penetrate two vertebral endplates whereas conventional pedicle screws penetrated no endplates.

Downward and upward PES technique

In the downward PES technique, the screw is inserted downward from the outer cranial side to the inner caudal side, penetrates the inferior facet, the superior facet, the pedicle, the caudal endplate of the vertebral body at the index level, and reaches the cranial endplate of the adjacent caudal vertebral body. The caudal screws are similarly inserted but in an upward direction. The PES technique offers more cortical bone-screw interface, better resists screw back-out, and largely prevents PJK, and proximal junctional failure (PJF).^[2] O-arm navigation, further, makes cephalad PES safe and a more precise technique for screw insertion typically three levels above and three levels below the index level of the vertebral fracture.^[6]

CONCLUSION

The combined use of the PES cephalad (i.e., downward) and caudal (i.e., upward) PES technique utilized in three patients with DISH 2–3 levels above/below osteoporotic T12 and L1 lumbar vertebral fractures, resisted screw back-out, prevented PJK, and avoided PJF.

Declaration of patient consent

Institutional Review Board (IRB) permission obtained for the study.

Financial support and sponsorship

Nil.

Conflicts of interest

There are no conflicts of interest.

REFERENCES

1. Abdu WA, Wilber RG, Emery SE. Pedicular transvertebral screw of lumbosacral spine in spondylolisthesis. *Spine (Phila Pa 1976)* 1994;19:710-5.
2. Harris AB, Kebaish FN, Puvanesarajah V, Raad M, Wilkening MW, Jain A, *et al.* Caudally directed upper-instrumented vertebra pedicle screws associated with minimized risk of proximal junctional failure in patients with long posterior spinal fusion for adult spinal deformity. *Spine J* 2021;21:1072-9.
3. Minamide A, Akamaru T, Yoon ST, Tamaki T, Rhee JM, Hutton WC. Transdiscal L5-S1 screws for the fixation of isthmic spondylolisthesis: A biomechanical evaluation. *J Spinal Disord Tech* 2003;16:144-9.
4. Nottmeier EW, Pirris SM. Placement of thoracic transvertebral pedicle screws using 3D image guidance. *J Neurosurg Spine* 2013;18:479-483.
5. Takeuchi T, Hosogane N, Yamagishi K, Satomi K, Matsukawa K, Ichimura S. Result of using a novel percutaneous pedicle screw technique for patients with diffuse idiopathic skeletal hyperostosis-the single or double endplates penetrating screw (SEPS/DEPS) technique. *Spine Surg Relat Res* 2020;4:261-8.
6. Xiao R, Miller JA, Sabharwal NC, Lubelski D, Alentado VJ, Healy AT, *et al.* Clinical outcomes following spinal fusion using an intraoperative computed tomographic 3D imaging system. *J Neurosurg Spine* 2017;26:628-37.

How to cite this article: Shiraishi D, Yamamoto Y, Motonori I, Nishimura Y, Hara M, Saito R, *et al.* Downward penetrating endplate screw technique under O-arm navigation posterior fusion in patients with osteoporotic vertebral body fractures associated with diffuse idiopathic skeletal hyperostosis. *Surg Neurol Int* 2022;13:436.