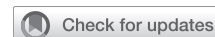

# Robotic-assisted left lower-lobe pulmonary lobectomy: Eleven steps



Elliot L. Servais, MD, Boston, Mass

From the Division of Thoracic and Cardiovascular Surgery, Lahey Hospital and Medical Center, Burlington; and Tufts University School of Medicine, Boston, Mass.

Disclosures: Dr Servais reported consultant for Intuitive Surgical.

The *Journal* policy requires editors and reviewers to disclose conflicts of interest and to decline handling or reviewing manuscripts for which they may have a conflict of interest. The editors and reviewers of this article have no conflicts of interest.

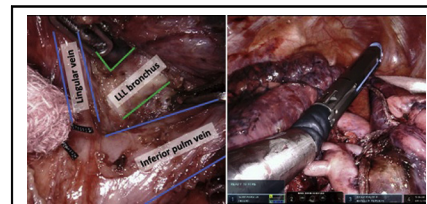
Received for publication March 31, 2021; accepted for publication May 28, 2021; available ahead of print Aug 23, 2021.

Address for reprints: Elliot L. Servais, MD, 41 Mall Rd, Burlington, MA 01805 (E-mail: [Elliot.Servais@lahey.org](mailto:Elliot.Servais@lahey.org)).

JTCVS Techniques 2021;10:473-9  
2666-2507

Copyright © 2021 The Author(s). Published by Elsevier Inc. on behalf of The American Association for Thoracic Surgery. This is an open access article under the CC BY-NC-ND license (<http://creativecommons.org/licenses/by-nc-nd/4.0/>).

<https://doi.org/10.1016/j.jtc.2021.05.031>



Superior visualization and precise dissection during robotic-assisted left lower lobectomy.

## CENTRAL MESSAGE

The technique described herein is an effective and reproducible approach to robotic-assisted left lower lobectomy for lung cancer, which can be extrapolated to other robotic pulmonary operations.

See Commentaries on pages 480 and 481.

Video clip is available online.

**Feature Editor's Introduction**—*In the following Video Atlas Article, you will find some of the clearest and most comprehensive video-based instruction for robotic lobectomy. Herein, the author distills a robotic left upper lobectomy procedure into a logical and discrete series of steps, each peer-reviewed and each demonstrated with high-quality video and short-format text. Included are instructions for lean instrumentation with printable a case card and illustration of a highly nuanced surgical technique that optimizes economy of motion and that thinks several steps ahead to improve overall case efficiency. Whereas there are no shortage of lobectomy videos dissecting pristine fissures, this proceeding includes video instruction for strategies to approach difficult and incomplete fissures in a reliable and reproducible manner. To the maximal extent possible, this video-based article crystallizes the precious learning experience unique to the operating room into an enduring educational format, epitomizing the spirit of the Video Atlas Article. This article is highly recommended for cardiothoracic surgery residents and junior faculty alike and is offered as a challenge to experienced robotic surgeons to not at least slightly modify their technique after viewing.*

Bryan M. Burt, MD

Since its introduction in the early 1990s,<sup>1</sup> minimally invasive thoracic surgery for anatomic pulmonary resection has progressively supplanted open thoracotomy, becoming the dominant approach for lung cancer operations performed by board-certified thoracic surgeons.<sup>2</sup> Video-assisted thoracic surgery, or VATS, has been shown in several studies to have similar oncologic and improved short-term outcomes compared with open thoracotomy for pulmonary resection.<sup>3,4</sup> However, the traditional VATS approach is limited by 2-dimensional optics and instrumentation with restricted degrees of freedom. This continues to limit more widespread adoption of VATS, particularly for complex pulmonary surgery. Robotic-assisted thoracic surgery (RATS) offers potential advantages over VATS related to improved 3-dimensional optics with magnification, 3 additional degrees of freedom compared with VATS allowing for wristed instrumentation, instrument stabilization, and a surgeon-controlled camera while operating. Recent studies demonstrate RATS anatomic pulmonary resection to be safe, efficacious, and at a minimum to have equivalent outcomes compared with VATS.<sup>4,5</sup> RATS lobectomy is rapidly gaining favor among thoracic surgeons, and a recent analysis of the Society of Thoracic Surgeons General Thoracic

Surgery Database demonstrated a 243% increase in RATS lobectomy from 2013 to 2018.<sup>2</sup>

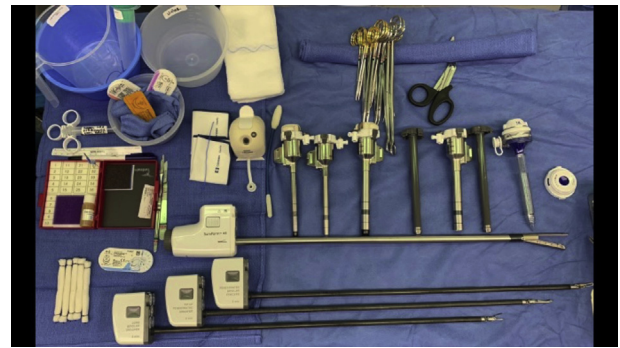Herein, we describe a safe and reproducible technique for RATS left lower lobectomy in 11 steps. The fundamental concepts and techniques can be extrapolated to the other 4-pulmonary lobectomies as well as more complex robotic pulmonary operations.

### MATERIALS AND METHODS

Our technique for left lower lobectomy for lung cancer is described in a series of 11 steps, each with an accompanying narrated video. An additional alternate step is provided for patients in whom the major fissure is poorly developed. A 4-arm completely portal robotic-assisted approach using the da Vinci Xi system (Intuitive Surgical, Sunnyvale, Calif) is employed. A complete list of equipment and instrumentation is provided in [Figure 1](#). Approval for this study was waived by the Lahey institutional review board, and all case videos were obtained with patient consent.

### RESULTS

1. Room setup and patient positioning ([Video 1](#)): The da Vinci Xi system has a rotating boom, allowing the robot

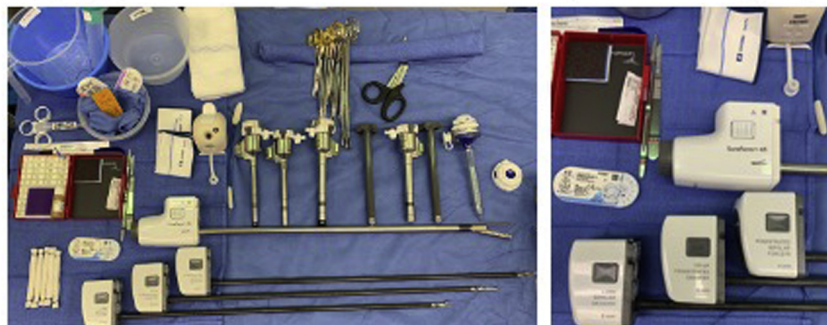


**VIDEO 1.** Video available at: [https://www.jtcvs.org/article/S2666-2507\(21\)00582-4/fulltext](https://www.jtcvs.org/article/S2666-2507(21)00582-4/fulltext).

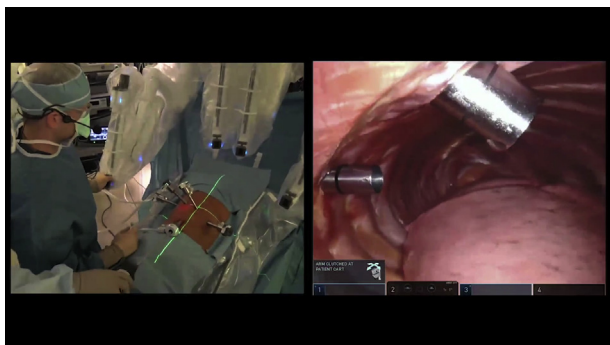
to be docked from either side regardless of operative laterality or specific lobe being removed. The center column of the patient robot cart is centered on the patient's mid-thorax to ensure optimal location of the robotic arms for docking. The bedside vision cart can be placed either at the head or foot of the bed, ensuring

### Robotic lobectomy – case card

- Thoracic minor instrument kit
  - Robotic instruments:
    - Long bipolar grasper
    - Tip-up fenestrated grasper
    - Fenestrated bipolar forceps
    - SureForm 45mm stapler (straight and curved tip)
    - Vessel sealer extend (available, unopened)
  - Robotic 0-degree camera
  - AirSeal insufflator (Conmed, Largo, FL)
  - Remote operated suction irrigator
  - Ports:
    - 2 – 8mm robotic ports
    - 2 – 12mm robotic ports,
    - 1 – 12mm AirSeal assistant port
  - Rolled gauze sponges
  - 4-O Prolene RB-1 with pledgets
  - 5-inch vessel loops
  - Surgicel
- Available in room, unopened:
- Major thoracotomy tray



**FIGURE 1.** Case card showing equipment and instrumentation for robotic-assisted lobectomy.



**VIDEO 2.** Video available at: [https://www.jtcvs.org/article/S2666-2507\(21\)00582-4/fulltext](https://www.jtcvs.org/article/S2666-2507(21)00582-4/fulltext).

the bedside assistant has unobstructed access to the patient's chest. Similarly, monitors should be easily visible to all members of the bedside team. Ideally, there should be a direct line of sight between the surgeon seated at the robotic console and the robotic arms once docked so as to allow the surgeon to troubleshoot any external robotic arm collisions without leaving the console.

The patient is positioned right lateral decubitus. The bed is flexed to widen the intercostal spaces and to broaden the space between the costal margin and iliac crest to help avoid collision between the camera and/or assistant port and the patient's hip. Importantly, the patient's upper arm (left arm in the setting of a left lower lobectomy) must be positioned no higher than parallel to the floor to avoid collision

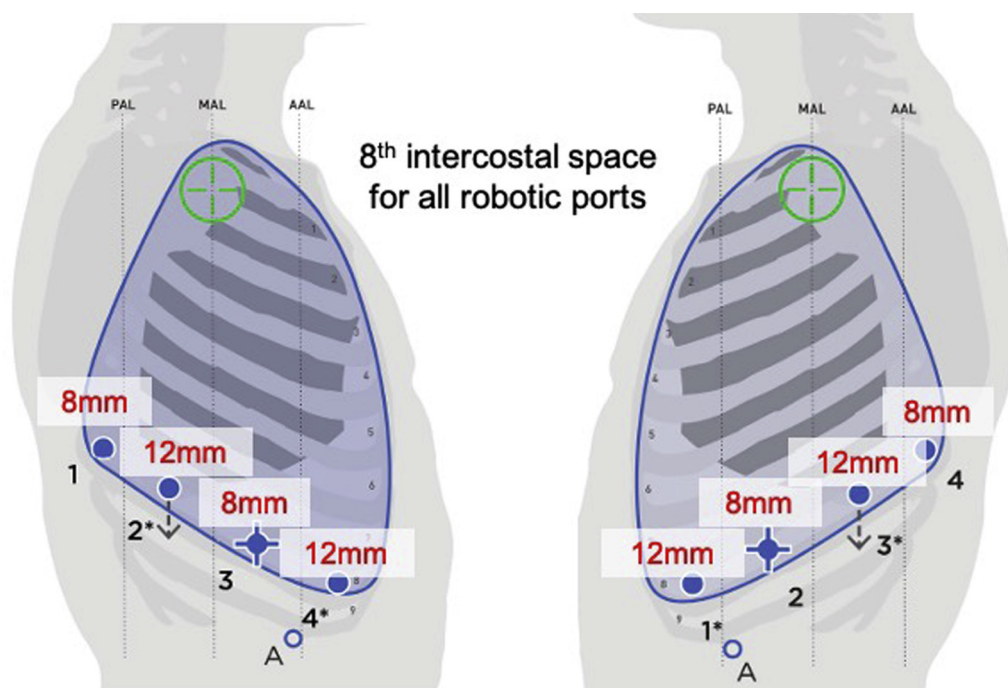
with the anterior robotic arm (detailed in the accompanying Video 1).

2. Port placement and docking (Video 2): The robotic ports should be placed in the eighth intercostal space. We begin by placing the camera port at the greatest point on the convexity of the chest to optimize visualization of both anterior and posterior hilar dissections. Carbon dioxide insufflation is attached to this initial port to establish capnothorax at 7-9 cmH<sub>2</sub>O pressure.

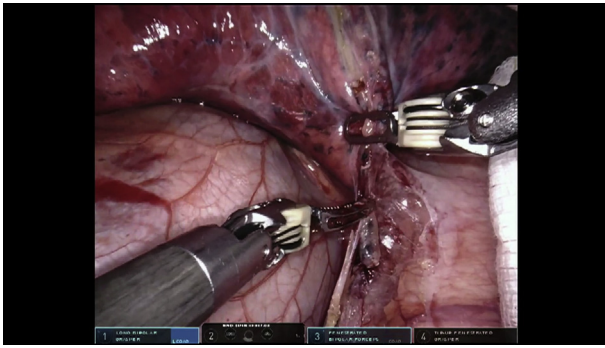
Intercostal nerve blocks are then performed percutaneously under thoracoscopic visualization to ensure placement along the neurovascular bundle without puncturing the overlying parietal pleural.

Next, the additional 3 robotic ports are placed as demonstrated in the associated video. We place a 12-mm port in both an anterior and posterior position to allow for stapling from either direction. The robotic ports should be placed a minimum of 7 to 8 cm apart from one another with the most posterior port placed lateral to the border of the erector spinae muscles. An assistant port is placed immediately superior to the diaphragmatic attachments to the chest wall equidistant between the 2 anterior robotic ports and the CO<sub>2</sub> insufflation switched to this port (Figure 2).

The robot is positioned with the laser crosshairs centered on the camera port, and all 4 arms are docked. The robotic arm docked to the camera port is positioned parallel to the long axis of the patient's body. Each remaining arm is then positioned relative to this initial camera port. The robotic



**FIGURE 2.** Port placement for robotic-assisted lobectomy.

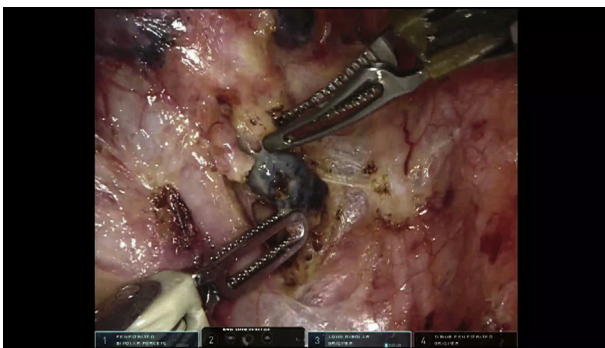


**VIDEO 3.** Video available at: [https://www.jtcvs.org/article/S2666-2507\(21\)00582-4/fulltext](https://www.jtcvs.org/article/S2666-2507(21)00582-4/fulltext).

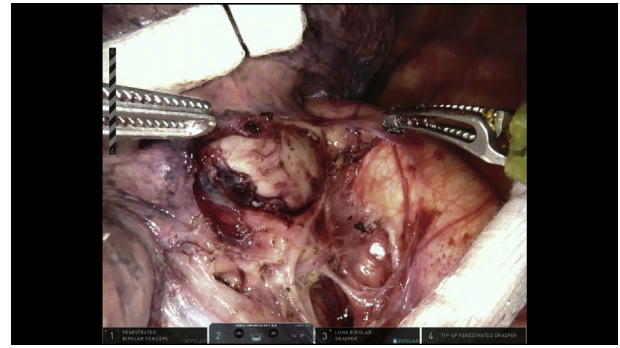
arms should be placed approximately 20 cm apart (one can use 2 fists side-by-side to approximate this distance) and the clearance function of each robotic arm is maximally dropped. The robotic port remote center, which represents the fulcrum point, is positioned directly overlying the ninth rib and the instruments are advanced into the chest under thoracoscopic vision via the assistant port.

3. Chest exploration and division of the inferior pulmonary ligament (Video 3): A thorough inspection of the entire hemithorax is performed specifically evaluating the lung and parietal pleural surfaces for evidence of unsuspected metastatic disease. Any suspicious areas should be sampled and sent for intraoperative pathologic analysis. In addition, the surgeon makes note of any anatomic variations including the presence of a single pulmonary vein trunk, the completeness of the fissures, and presence of pleural adhesions.

The lung is then retracted cephalad using rolled gauze sponges taking care to minimize grasping the lung parenchyma with the robotic instruments. With the inferior ligament under mild tension, the ligament is divided with bipolar energy cephalad to the inferior pulmonary vein. Level 8 and 9L nodes are excised completely and sent for



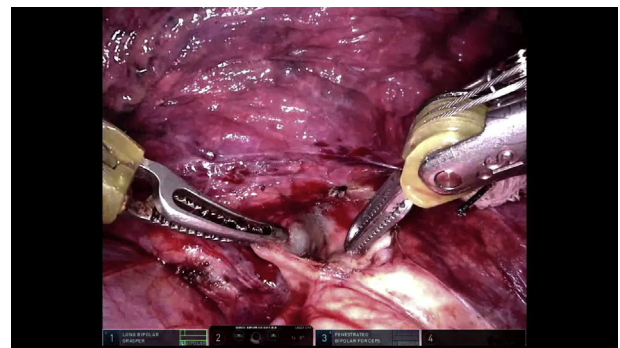
**VIDEO 4.** Video available at: [https://www.jtcvs.org/article/S2666-2507\(21\)00582-4/fulltext](https://www.jtcvs.org/article/S2666-2507(21)00582-4/fulltext).



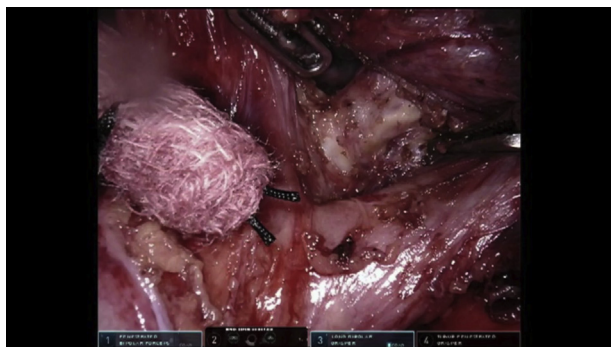
**VIDEO 5.** Video available at: [https://www.jtcvs.org/article/S2666-2507\(21\)00582-4/fulltext](https://www.jtcvs.org/article/S2666-2507(21)00582-4/fulltext).

pathology. Small nodes can be extracted by the bedside assistant using a thoracoscopic grasper via the assistant port; whereas large lymph node packets are typically extracted using a small specimen retrieval bag.

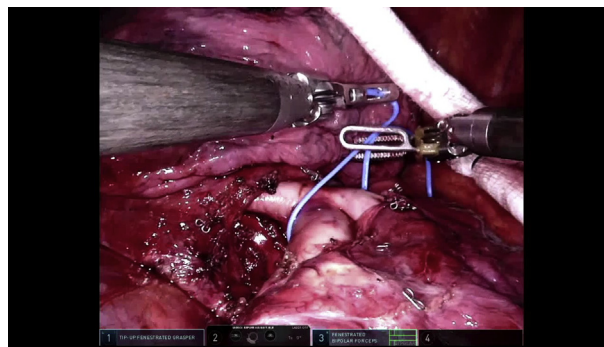
4. Mediastinal lymphadenectomy (Video 4): A mediastinal lymphadenectomy is then completed by retracting the lung anteriorly and laterally with the fourth retraction arm. This maneuver effectively exposes the posterior mediastinal space for dissection. The subcarinal space is then opened and the level 7 lymph node packet removed completely. The lung is then retracted inferiorly and the aortopulmonary and para-aortic lymph nodes are removed. Care is taken to avoid injury to the phrenic or recurrent laryngeal nerves.
5. Posterior hilar dissection (Video 5): With the lung retracted anteriorly, the posterior mediastinal pleura is opened in a cephalad direction to the aortic arch. The posterior hilar structures are dissected to define the left main bronchus and pulmonary artery (PA). Lymph nodes situated between these structures are excised for pathology. During this step, it is important to fully dissect the posterior fissure to create a window overlying the PA. This will facilitate passage of the stapler when later dividing the major fissure.



**VIDEO 6.** Video available at: [https://www.jtcvs.org/article/S2666-2507\(21\)00582-4/fulltext](https://www.jtcvs.org/article/S2666-2507(21)00582-4/fulltext).



**VIDEO 7.** Video available at: [https://www.jtcvs.org/article/S2666-2507\(21\)00582-4/fulltext](https://www.jtcvs.org/article/S2666-2507(21)00582-4/fulltext).

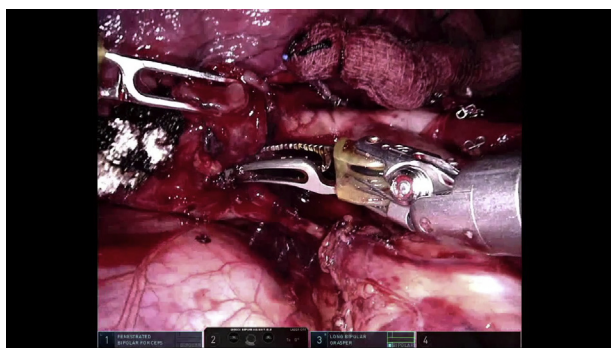

**VIDEO 9.** Video available at: [https://www.jtcvs.org/article/S2666-2507\(21\)00582-4/fulltext](https://www.jtcvs.org/article/S2666-2507(21)00582-4/fulltext).

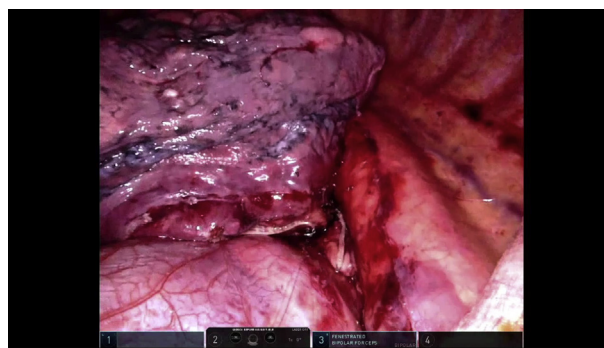
6. Dissection of the interlobar PA and major fissure division (Video 6): When the major fissure is relatively complete, we preferentially begin dissection of the interlobar PA in the fissure. The surgeon develops the plane directly on the surface of the artery and continues this towards the posterior fissure. The connective tissue in the fissure may be divided with electrocautery; however, lung parenchyma crossing the fissure is divided with the robotic stapler. In nearly all cases the “blue load” staple cartridge is appropriate for the fissure although this can be upsized as needed. This dissection is continued until the prior dissection from the posterior hilum is reached and the fissure division thus completed. In the setting of an incomplete fissure, a fissure/PA last approach is taken (see alternate steps in Video 7).
7. Remove 11L sump node (Video 8): The lung is retracted posteriorly using rolled gauze sponge placed on the lower lobe. The level 11L “sump” node is reliably situated overlying the secondary carina between the left upper and lower-lobe bronchi. This lymph node is removed in its entirety thereby exposing the interface between the bronchus and the overlying interlobar PA.
8. Division of lower-lobe PA (Video 9): The PA is gently dissected off the underlying bronchus. A blunt-tip

robotic grasper is ideal for this maneuver. In the event that the PA does not readily separate from the bronchus, one must proceed with caution, as this may indicate a fibrotic desmoplastic reaction or frank tumor invasion of the PA. In such situations, due consideration must be given to either obtaining proximal and distal PA control prior to proceeding or conversion to open thoracotomy. Once circumferentially dissected, a vessel loop is passed around the PA to assist in guiding a robotic vascular stapler with a curved tip around the artery. Tension on the artery is relaxed and a sponge is placed in a ready position to tamponade any bleeding should it occur prior to engaging the stapler and dividing the PA.

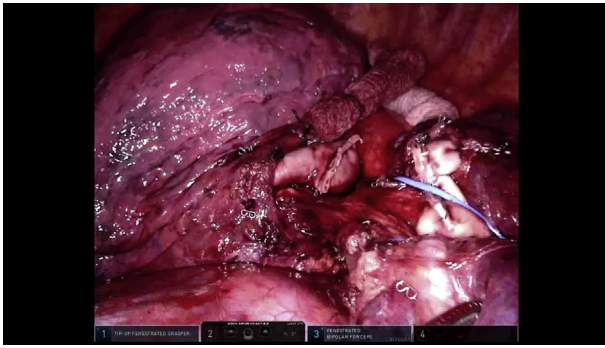
9. Division of the inferior pulmonary vein (Video 10): The lung is retracted cephalad exposing the inferior pulmonary vein. If the vein was not circumferentially dissected earlier, this dissection is completed, and a vessel loop placed to assist in passing the vascular curved tip robotic stapler from the anterior stapling port. (Note: occasionally, depending on patient anatomy and body habitus, the posterior stapling port may provide the best angle.) The stapler is placed distal on the vein (towards the mediastinum) so as to minimize the length of the stapled vein stump. Tension on the vein is relaxed and the stapler



**VIDEO 8.** Video available at: [https://www.jtcvs.org/article/S2666-2507\(21\)00582-4/fulltext](https://www.jtcvs.org/article/S2666-2507(21)00582-4/fulltext).



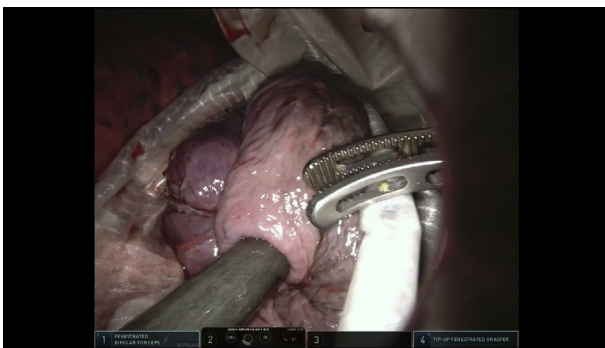
**VIDEO 10.** Video available at: [https://www.jtcvs.org/article/S2666-2507\(21\)00582-4/fulltext](https://www.jtcvs.org/article/S2666-2507(21)00582-4/fulltext).



**VIDEO 11.** Video available at: [https://www.jtcvs.org/article/S2666-2507\(21\)00582-4/fulltext](https://www.jtcvs.org/article/S2666-2507(21)00582-4/fulltext).

closed; the robotic stapler is then activated and the inferior pulmonary vein divided.

10. Division of the lower-lobe bronchus (Video 11): The lung is returned to its anatomic position, and lymph nodes situated along the lower-lobe bronchus are dissected toward the specimen to ensure removal with the lower lobectomy and to clear a landing zone for the stapler. The robotic stapler with the medium-thick tissue load is inserted through the anterior stapling port across the lower-lobe bronchus just distal to the secondary carina. After clamping the stapler, a test ventilation to the left lung may be performed to ensure the patency of the upper lobe bronchus, following which the lower-lobe bronchus is divided.
11. Specimen extraction (Video 12): The assistant port is removed and enlarged to approximately 3 to 4 cm. It is critical that the bedside assistant take care to enlarge this incision staying directly on the superior surface of the inferior rib so as to avoid inadvertent injury to the intercostal neurovascular bundle. A large specimen retrieval bag is inserted and the lobectomy carefully placed into the bag for removal taking care not to traumatize the vascular or bronchial stumps in the surgical field.



**VIDEO 12.** Video available at: [https://www.jtcvs.org/article/S2666-2507\(21\)00582-4/fulltext](https://www.jtcvs.org/article/S2666-2507(21)00582-4/fulltext).

12. Alternate steps 6-10 for an incomplete fissure (Video 7): If the major fissure is poorly developed, we alter the approach by retracting the lung posteriorly and dissecting the level 11L sump node, which reliably reveals the underlying secondary carina. The inferior pulmonary vein is then separated from the lower-lobe bronchus and divided. The lower-lobe bronchus is circumferentially dissected and divided with the robotic stapler. With the vein and bronchus divided, one can easily identify the interlobar PA and safely dissect the fissure by remaining on the anterior surface of the PA. The fissure is then completed with the robotic stapler, followed by division of the PA, thus completing the “PA last” or “inferior-to-superior” lobectomy approach.

## DISCUSSION

RATS is an increasingly common approach for anatomic lung resection. In recent years, increased early exposure to and training with robotic surgery during surgical residency and cardiothoracic training has accelerated RATS adoption.<sup>6</sup> It is reasonable to anticipate more widespread adoption of RATS as robotic technology evolves and becomes more efficient and economical. In this context, it is particularly important to establish safe, effective, and reproducible RATS techniques that surgeons can employ to facilitate improved patient outcomes, higher value care, education, and research. Several groups, including our own, have published technical aspects of RATS lobectomy and other complex pulmonary operations.<sup>7-9</sup> The step-by-step technique outlined in this report was developed through the careful adoption and modification of described techniques to achieve a safe and easily reproducible approach to RATS lobectomy as well as to optimize the learning curve.

In adopting RATS lobectomy, it is of paramount importance that surgeons follow a safe paradigm for implementing this new technology and also appreciate the effort required to master the learning curve. The 2016 consensus statement by Blackmon and colleagues,<sup>10</sup> providing a tool kit for surgeons using new technology in general thoracic surgery, is a useful resource. The robotic lobectomy learning curve has been suggested to be 20 to 40 cases depending on a surgeon’s previous experience with minimally invasive and robotic techniques.<sup>11</sup> Appropriate case selection and adherence to fundamental principles of safe thoracic surgery, including a low threshold for open conversion early in the learning curve, use of experienced case proctors, and rigorous credentialing processes, are key to maintaining high quality standards. Adoption of a standardized technique for RATS lobectomy, as described in this manuscript, will facilitate uniformity in the training of new robotic thoracic surgeons as well as a provide a standard approach for studying RATS outcomes.

## CONCLUSIONS

This report describes one approach in 11 steps to a completely portal RATS left-lower lobectomy with complete lymph node dissection for lung cancer. The technique demonstrated can be extrapolated to other RATS anatomic lung resections and provides a standardized, safe and reproducible platform that can be used to facilitate research, education, and optimal patient outcomes. Additional prospective evaluation of the differing VATS and RATS approaches is required, and future innovation will be necessary as robotic technology continues to evolve.

## References

1. Landreneau RJ, Hazelrigg SR, Ferson PF, Johnson JA, Nawarawong W, Boley TM, et al. Thoracoscopic resection of 85 pulmonary lesions. *Ann Thorac Surg.* 1992;54:415-9; discussion 419-20.
2. Servais EL, Towe CW, Brown LM, Broderick SR, Block MI, Burfeind WR, et al. The Society of Thoracic Surgeons general thoracic surgery database: 2020 update on outcomes and research. *Ann Thorac Surg.* 2020;110:768-75.
3. Demmy TL, Yendamuri S, D'Amico TA, Burfeind WR. Oncologic equivalence of minimally invasive lobectomy: the scientific and practical arguments. *Ann Thorac Surg.* 2018;106:609-17.
4. Yang HX, Woo KM, Sima CS, Bains MS, Adusumilli PS, Huang J, et al. Long-term survival based on the surgical approach to lobectomy for clinical stage I nonsmall cell lung cancer: comparison of robotic, video-assisted thoracic surgery, and thoracotomy lobectomy. *Ann Surg.* 2017; 265:431-7.
5. Reddy RM, Gorrepati ML, Oh DS, Mehendale S, Reed MF. Robotic-assisted versus thoracoscopic lobectomy outcomes from high-volume thoracic surgeons. *Ann Thorac Surg.* 2018;106:902-8.
6. Linsky PL, Wei B. Training in robotic thoracic surgery. *J Vis Surg.* 2018;4:1.
7. Cerfolio RJ, Bryant AS, Minnich DJ. Starting a robotic program in general thoracic surgery: why, how, and lessons learned. *Ann Thorac Surg.* 2011;91: 1729-36; discussion 1736-7.
8. Oh DS, Tisol WB, Cesnik L, Crosby A, Cerfolio RJ. Port strategies for robot-assisted lobectomy by high-volume thoracic surgeons: a nationwide survey. *Innovations (Phila).* 2019;14:545-52.
9. Watkins AA, Quadri SM, Servais EL. Robotic-assisted complex pulmonary resection: sleeve lobectomy for cancer. *Innovations (Phila).* 2021; 16:132-5.
10. Blackmon SH, Cooke DT, Whyte R, Miller D, Cerfolio R, Farjah F, et al. The Society of Thoracic Surgeons expert consensus statement: a tool kit to assist thoracic surgeons seeking privileging to use new technology and perform advanced procedures in general thoracic surgery. *Ann Thorac Surg.* 2016;101: 1230-7.
11. Power AD, D'Souza DM, Moffatt-Bruce SD, Merritt RE, Kneuert PJ. Defining the learning curve of robotic thoracic surgery: what does it take? *Surg Endosc.* 2019;33:3880-8.