

# Thymoma with Autoimmune Hemolytic Anemia

Kensuke Suzuki<sup>a</sup> Minehiko Inomata<sup>b</sup> Shiori Shiraishi<sup>b</sup> Ryuji Hayashi<sup>b</sup>  
Kazuyuki Tobe<sup>b</sup>

<sup>a</sup>Toyama Prefectural Central Hospital, and <sup>b</sup>First Department of Medicine, Toyama University Hospital, Toyama, Japan

## Key Words

Thymoma · Autoimmune hemolytic anemia · Chemotherapy · Corticosteroid therapy

## Abstract

A 38-year-old Japanese male was referred to our hospital with abnormal chest X-ray results and severe Coombs-positive hemolytic anemia. He was diagnosed with a stage IV, WHO type A thymoma and was treated with oral prednisolone (1 mg/kg/day) and subsequent chemotherapy. After chemotherapy, the patient underwent surgical resection of the thymoma. Hemolysis rapidly disappeared and did not return after the discontinuation of oral corticosteroids. Corticosteroid therapy may be preferable to chemotherapy or thymoma surgical resection in the management of autoimmune hemolytic anemia with thymoma.

© 2014 S. Karger AG, Basel

## Introduction

Thymomas originate from thymus epithelial cells, and they are the most common tumors in the anterior mediastinum. Additionally, paraneoplastic syndromes that may be associated with thymomas have an underlying autoimmune characterization. Anemia in a patient with a thymoma can be caused by pure red cell aplasia (PRCA), which develops in approximately 2–5% of thymoma patients.

## Case Report

A 38-year-old Japanese male with no relevant medical history presented at our hospital with complaints of facial and leg edema and dyspnea on exertion for 2 weeks' duration. He

Kensuke Suzuki, MD, PhD  
Toyama Prefectural Central Hospital  
2-2-78 Nishi-nagae  
Toyama-city 930-8550 (Japan)  
E-Mail [khiro.tm@gmail.com](mailto:khiro.tm@gmail.com)

had abnormal chest imaging findings 2 years previously. His family history was unremarkable; he was a lifelong smoker with an 18-pack-year history and he did not frequently consume alcohol.

On examination, he was hemodynamically stable with a pulse of 118 beats/min and a blood pressure of 106/58. His oxygen saturation level was 100% on air. Laboratory tests revealed elevated lactate dehydrogenase and bilirubin, as well as a hemoglobin level of 5.1 g/dl.

A chest X-ray demonstrated 2 masses in the upper lung field proximal to the mediastinum and adjacent to the diaphragm (fig. 1). A chest CT demonstrated a greater than 10-cm mass with spotty calcifications in the right anterior mediastinum (fig. 2a) that disseminated to the right thoracic cavity (fig. 2b). Ultrasound-guided fine needle biopsy of the right anterior mediastinal mass showed that it was predominantly composed of spindled to oval epithelial cells with a scant lymphoid component. Immunohistochemical analysis revealed positivity for pan-cytokeratin AE1/AE3 in the tumor cells, and positivity for TdT and CD99 in the immature T lymphocytes. The pathological and radiological results demonstrated the presence of a stage IVa, WHO type A thymoma.

Further evaluation ruled out PRCA with thymoma. A haptoglobin level of 3 mg/ml, a positive Coombs test for complement (C3) and immunoglobulin G antibody, and increased reticulocytes in the peripheral blood (39.8%) were observed. A diagnosis of autoimmune hemolytic anemia (AIHA) with a WHO type A thymoma was made.

The patient underwent corticosteroid therapy (prednisolone 1 mg/kg; 60 mg/body weight), and his anemia immediately improved. Four weeks later, the patient was treated with ADOC chemotherapy (doxorubicin 40 mg/m<sup>2</sup> on day 1, cisplatin 50 mg/m<sup>2</sup> on day 2, vincristine 0.6 mg/m<sup>2</sup> on day 3, cyclophosphamide 700 mg/m<sup>2</sup> on day 4, every 3 weeks) (fig. 3). After 5 cycles of chemotherapy, the patient achieved good partial remission and underwent surgical resection. We found no viable tumor cells in the tumor specimen; thus, the patient did not undergo postthymectomy radiotherapy. The patient has remained asymptomatic to date.

## Conclusion

Many autoimmune phenomena have been shown to be related to thymomas; this indicates an immunopathological association between thymomas and autoimmune diseases. The most common and best-studied autoimmune association is myasthenia gravis [1].

As the site of T-cell maturation, the thymus plays a central role in adaptive immunity and can produce autoreactive T-cell clones that are responsible for autoimmune diseases [2]. Thymic epithelial cells are an essential component of the thymic stromal microenvironment, and dysfunction of the thymic stromal microenvironment can cause autoimmune diseases [3].

In anemic patients with thymomas, the association of PRCA with thymoma, as well as thymoma-associated PRCA, is known to account for a significant proportion of secondary cases [4]. The coexistence of a thymoma and AIHA is very rare. A literature review revealed 17 cases of thymomas with AIHA. The most common type of thymoma with AIHA is thymic cancer (WHO type C), and the second most common type is the spindle cell type (WHO type A). Most patients (82%) are treated with corticosteroids for AIHA, and 78% of patients achieved clinical anemia remission with corticosteroids [5].

Classical cisplatin-based chemotherapy has been used in the treatment of locally advanced or metastatic thymomas. Particularly, the ADOC regimen has repeatedly been found

to be highly effective against advanced disease, with overall response rates ranging from 81.2 to 100% [6, 7]. The usefulness of neoadjuvant chemotherapy for unresectable thymomas has been unclear; only a few studies have reported that neoadjuvant chemotherapy followed by surgery can improve both the curability and the resection rate [8]. As a preoperative approach, neoadjuvant chemotherapy can be effective for patients who are not amenable to surgery or for those whose tumors are surgically resectable but are associated with morbidity.

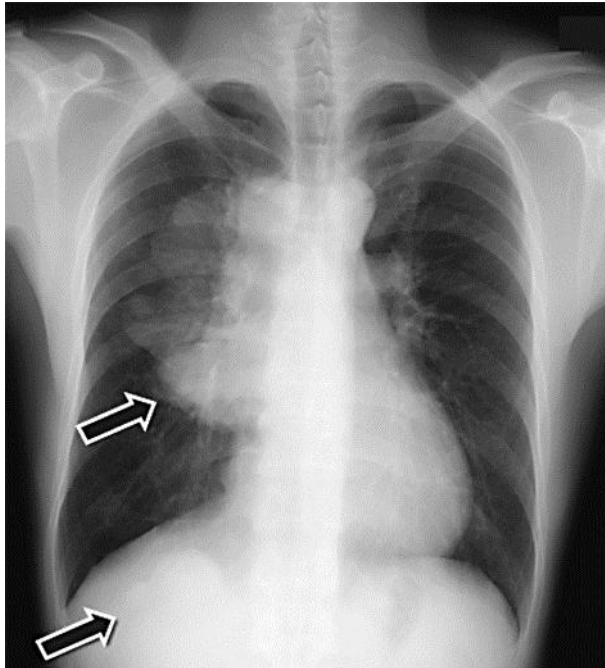
Corticosteroid therapy was preferred over chemotherapy or surgical resection in the present case. Comprehensive strategies to treat thymomas with AIHA have not been formulated, but anemia remission is necessary for chemotherapy and surgical resection of thymomas; thus, early corticosteroid therapy is reasonable.

### Disclosure Statement

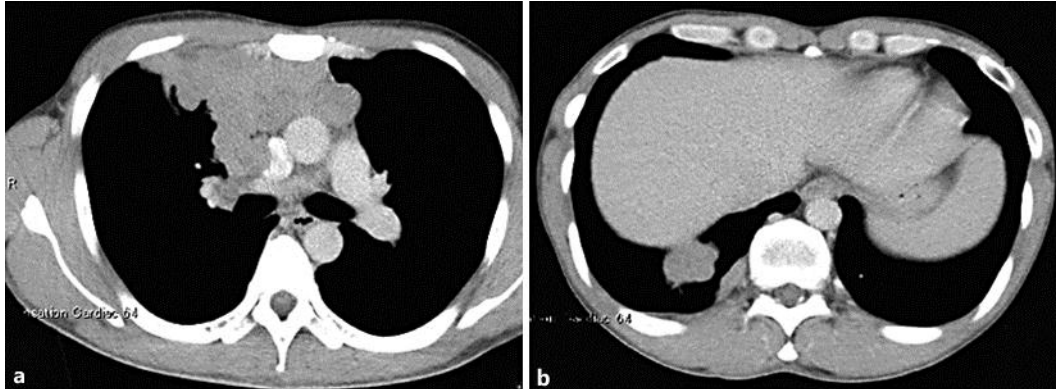
The authors have no conflicts of interest to disclose.

### References

- 1 Thomas CR, Wright CD, Loehrer PJ: Thymoma: state of the art. *J Clin Oncol* 1999;17:2280–2289.
- 2 Muller-Hermelink HK, Marx A: Thymoma. *Curr Opin Oncol* 2000;12:426–433.
- 3 Fletcher AL, Calder A, Hince MN, Boyd RL, Chidgey AP: The contribution of thymic stromal abnormalities to autoimmune disease. *Crit Rev Immunol* 2011;31:171–187.
- 4 Hirokawa M, Sawada K, Fujishima N, et al: Long-term response and outcome following immunosuppressive therapy in thymoma-associated pure red cell aplasia: a nationwide cohort study in Japan by the PRCA collaborative study group. *Haematologica* 2008;93:27–33.
- 5 De Keyzer K, Peeters P, Verhelst C, Dendooven A, Vonck A, Vanholder R: Autoimmune haemolytic anaemia associated with a thymoma: case report and review of the literature. *Acta Clin Belg* 2009;64:447–451.
- 6 Fornasiero A, Daniele O, Ghiotto C, et al: Chemotherapy for invasive thymoma. A 13-year experience. *Cancer* 1991;68:30–33.
- 7 Berruti A, Borasio P, Gerbino A, et al: Primary chemotherapy with adriamycin, cisplatin, vincristine and cyclophosphamide in locally advanced thymomas: a single institution experience. *Br J Cancer* 1999;81:841–845.
- 8 Berruti A, Borasio P, Roncari A, Gorzegno G, Mossetti C, Dogliotti L: Neoadjuvant chemotherapy with adriamycin, cisplatin, vincristine and cyclophosphamide (ADOC) in invasive thymomas: results in six patients. *Ann Oncol* 1993;4:429–431.



**Fig. 1.** Chest X-ray at the first visit.



**Fig. 2.** Chest CT. **a** Tumor in the anterior mediastinum. **b** Dissemination in the thoracic cavity.

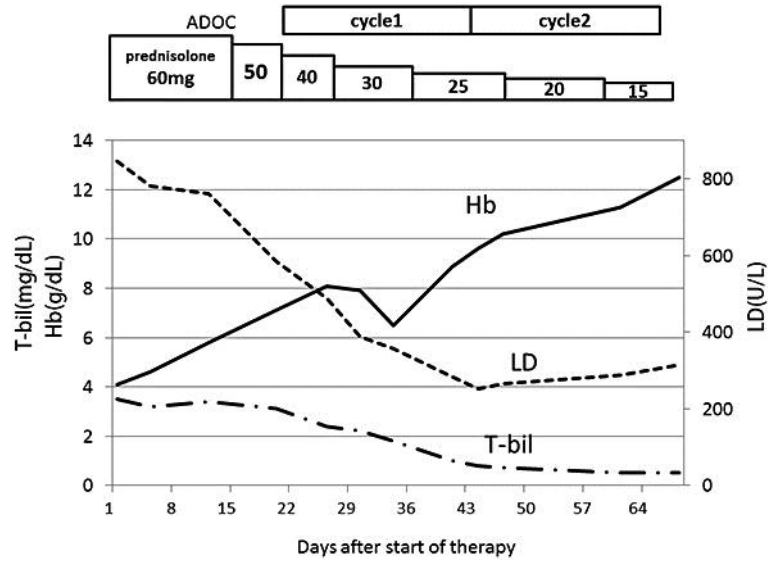


Fig. 3. Clinical course.