

Successful treatment of Epstein-Barr virus-related post-transplant lymphoproliferative disease with central nervous system involvement following allogeneic haematopoietic stem cell transplantation – a case study

MAŁGORZATA WRÓBLEWSKA¹, LIDIA A. GIL², MIECZYŚLAW A. KOMARNICKI²

¹Students' Scientific Society, Poznan University of Medical Sciences, Poznan, Poland

²Department of Haematology and Bone Marrow Transplantation, Poznan University of Medical Sciences, Poznan, Poland

Abstract

Post-transplant lymphoproliferative disease (PTLD) is a rare but severe form of Epstein-Barr virus (EBV)-driven complication that develops in patients after haematopoietic stem cell transplantation. In rare cases it manifests as primary central nervous system (CNS) involvement, which is thought to be the most unfavourable localisation with respect to outcome. Disease confined to the CNS is much more challenging than systemic PTLD, and one of the contributing factors is the limited drug penetration across the blood-brain barrier. We describe the case of a 29-year-old woman who was successfully treated for PTLD with CNS involvement. The patient was diagnosed with T-cell lymphoblastic lymphoma and underwent the procedure of haematopoietic stem cell transplantation from an unrelated donor. Two months after transplantation she manifested severe headache and progressive mental deterioration accompanied by enlargement of the lymph nodes. Magnetic resonance imaging (MRI) scan revealed segmental, asymmetrical thickening of the meninges. Based on the clinical picture and the laboratory findings diagnosis of PTLD was made. The patient was effectively treated with reduction of immunosuppressive therapy and intravenous rituximab. Initially started intrathecal chemotherapy was stopped due to iatrogenic complications. We conclude that in this case the involvement of meninges in the course of the lymphoproliferative process might have compromised the blood-brain barrier. This factor probably improved rituximab's penetration to CNS, contributing to our patient's recovery.

Key words: rituximab, post-transplant lymphoproliferative disease, PTLD, EBV, HSCT.

(Centr Eur J Immunol 2015; 40 (1): 122-125)

Introduction

Post-transplant lymphoproliferative disease (PTLD) is a rare but severe complication that develops in patients after haematopoietic stem cell transplantation (HSCT) or solid organ transplantation (SOT) [1]. It is a heterogeneous group of lymphoproliferations with spectrum ranging from benign hyperplasia to aggressive lymphomas. The majority of cases are of B-cell origin, T-cell PTLD is reported in 10-15% of cases [2]. More than half (60-70%) of cases of PTLD are associated with Epstein-Barr virus, and these are usually early cases, within the first year after transplantation. Epstein-Barr virus-negative PTLD usually occurs

late after transplantation, and more often after SOT than HSCT [3]. According to the World Health Organisation (WHO) classification, PTLD may have one of four major histological forms: early benign lesions, polymorphic PTLD, monomorphic PTLD, or the least common form of classical Hodgkin lymphoma [4].

The underlying mechanism of EBV-positive PTLD is based on the inability of the immune system to control latent EBV infection [5]. The most significant risk factors for the development of EBV-related PTLD in patients after HSCT are transplantation from an unrelated or HLA-mismatched donor, including haploidentical or cord blood

Correspondence: Małgorzata Wróblewska, Department of Haematology and Bone Marrow Transplantation, Poznan University of Medical Sciences, Szamarzewskiego 84, 60-569 Poznań, Poland, e-mail: m.wroblewska@yahoo.com

transplantation, donor-recipient serological mismatch regarding EBV, and T-cell depletion in transplanted material or use of antithymocyte globulin (ATG) [1, 6]. The disease is usually diagnosed as B-cell lymphoma but with a highly heterogeneous clinical picture. The diagnosis is likely when significant lymphadenopathy or other organ involvement is observed along with high blood EBV-DNAemia and in the absence of other disease. To establish a proven diagnosis EBV must be detected in material from a biopsy of an involved organ [7]. Post-transplant lymphoproliferative disease with central nervous system (CNS) involvement, which is difficult to confirm, is considered a high risk disease [8].

Case report

The patient, a 29-year-old woman, was diagnosed with T-cell lymphoblastic lymphoma stage IIB in 2012. She received chemotherapy according to Polish Adult Leukaemia Group protocol ALL – 2007, with complete remission (CR). Because of early relapse, therapy with fludarabine, cytarabine, and mitoxantrone (FLAM regimen) was administered, and after the second CR was achieved the patient was qualified for allogeneic HSCT. The transplantation procedure was performed on 28th August 2013. The

patient was conditioned with ablative therapy based on total body irradiation and cyclophosphamide and transplanted with peripheral blood stem cells from an unrelated donor: a 45-year-old male with one HLA mismatch. Both donor and recipient were serologically EBV-positive and CMV-negative prior to the transplantation. Graft-versus-host disease (GvHD) prophylaxis consisted of standard doses of cyclosporine A and methotrexate, as well as ATG-Fresenius in a dose of 40 mg/kg. The post-transplant period was uncomplicated. Neutrophil recovery (absolute neutrophil count $> 0.5 \times 10^6/l$) occurred on day +16. The patient was discharged from the hospital on day +28 in good general condition. She was under careful clinical monitoring every 7 to 10 days in an outpatient clinic, with no adverse symptoms and no GvHD. Assays for EBV and CMV reactivation performed with PCR method to detect viral DNA remained negative for 60 days after transplantation.

On day +63 the patient was urgently admitted to the transplant centre with severe headache. There were no focal neurological signs on admission; however, enlarged cervical and inguinal lymph nodes were found. Since the lymph nodes were only about 2 cm in diameter and painful, the biopsy was postponed. Blood count and biochemistry were normal. Other laboratory tests revealed blood EBV – DNAemia at the level of 1.03×10^7 copies per ml and plasma monoclonal IgG at the level of 18.8 g/l. The assays for blood CMV – DNA, HHV6 – DNA and Adenovirus – DNA were negative. Bone marrow aspiration followed by immunophenotyping revealed no abnormalities. Chest X-ray was normal, but abdominal sonography revealed mild hepatosplenomegaly. Magnetic resonance imaging (MRI) of the central nervous system revealed segmental, asymmetrical thickening of the meninges as well as subtle vasogenic changes with no brain focal lesions (Fig. 1). Lumbar puncture (LP) was performed, and on the cerebrospinal fluid (CSF) examination there were 40 leukocytes per μl , identified in 100% of cases as monoclonal B-lymphocytes with flow-cytometry. Cerebrospinal fluid culture was negative.

Based on the above findings and the clinical picture, diagnosis of probable EBV-driven systemic PTLD with CNS involvement was made. Because the patient was still on low doses of Cyclosporine A, immunosuppression was withdrawn. The patient immediately received intravenous rituximab (375 mg/m^2) with the intention to continue injections every 7 days. Additionally, intrathecal chemotherapy with methotrexate and dexamethason was administered. Previously enlarged lymph nodes became impalpable after the first dose of rituximab. Despite the immediate introduction of therapy, the patient's neurological status deteriorated and she became unconscious. On the 12th day after admission the patient unexpectedly experienced a sudden cardiac arrest in the form of asystole. After successful resuscitation the treatment with rituximab and intrathecal

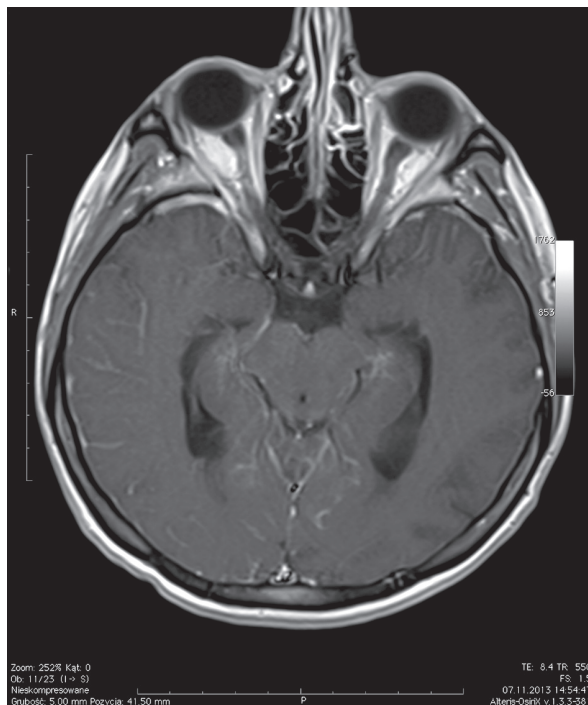


Fig. 1. MRI of the patient with CNS involvement in the course of PTLD – segmental, asymmetrical thickening of the meninges. Courtesy of dr Dariusz Poplawski, Department of Radiology, Poznan University of Medical Sciences

chemotherapy was continued at the Intensive Care Unit with a gradual decrease of blood EBV – DNA load. Cerebrospinal fluid assessment revealed 48 leukocytes per μl with monoclonal B-lymphocytes comprising $< 1\%$ of the cells; however, EBV – DNA load in the CSF was 6.90×10^4 copies per ml. After the second dose of intrathecal chemotherapy, an oedema of the lumbosacral region was noticed, presumably resulting from CSF extravasation. At this time, probably due to the mentioned complication, transient flaccid tetraparesis occurred. Intrathecal treatment was therefore discontinued, but therapy with intravenous rituximab was continued. After the third dose of intravenous rituximab, the patient's condition significantly improved. As the sedation was gradually withdrawn, she remained in good logical contact. Serum EBV – DNAemia reached undetectable level on the 27th day after admission. No monoclonal plasma protein was present.

At eight months after transplantation there were no symptoms of PTLD, and blood EBV – DNA assay remained negative. There was no evidence of monoclonal plasma protein. The picture of bone marrow remained free from abnormalities. The control MRI revealed only discreet sustained vasogenic changes, and the previously seen oedema and meningeal thickening were absent. The patient regained motor skills with only slight debilitation of left lower limb. Limited GvHD with skin involvement developed five months after transplantation.

Discussion

Post-transplant lymphoproliferative disease is a rare condition, but its incidence is increasing because of the growing number of transplantation procedures and longer survival of patients thereafter [8]. After SOT, PTLD occurs in 1-16% of patients, depending on the transplanted organ [9]. After HSCT the general incidence of PTLD is 3.2% [7]. Central nervous system involvement occurs in 10-15% of PTLD cases after SOT [2]. There is no exact data on CNS involvement in PTLD following HSCT, but it is said that CNS presentation occurs more frequently when compared to the general population of aggressive lymphoma patients. Both after SOT or HSCT procedures, CNS-PTLD is associated with significantly inferior survival in comparison to non-CNS-PTLD.

The spectrum of clinical pictures of CNS-PTLD has not been fully characterised yet. According to the analysis of reported events [10, 11], it usually manifests as parenchymal lesions (multifocal in 61% of cases) or as meningeal involvement, seen in about 40% of cases. Isolated leptomeningeal and ependymal localisation is rare (10%). Histopathologically CNS-PTLD is usually of monomorphic form with diffuse large B-cell lymphoma (DLBCL) or Burkitt lymphoma as the most commonly recognised [8].

In the course of aggressive lymphomas in general, CNS involvement occurs in 2-30% of cases, depending on

the risk factors, and it is usually fatal with a median survival time of 2-6 months in the subgroup of patients with secondary CNS disease [12]. Current treatment options for CNS lymphoma, both primary and secondary, include CNS penetrating chemotherapy, intrathecal chemotherapy, and/or brain radiation therapy, with a low rate of durable responses. High-risk patients usually receive CNS prophylaxis with intrathecal chemotherapy [12].

Therapy of PTLD in general is targeted at reconstitution of T-cell function and reduction of proliferating B-cells, whereas antiviral treatment has no clinical significance since it is of low effectiveness against the latent form of EBV [7]. Methods aimed at T-cell reconstitution include reduction of immunosuppression (RI) and T-cell immunotherapy, which can be donor lymphocyte infusion (DLI) or use of EBV-specific cytotoxic T-lymphocytes (EBV-CTL). Since DLI, although very effective, significantly increases the risk of GvHD and EBV-CTL is a complicated and not commonly available method, RI remains the basic T-cell restoring treatment. Reduction of immunosuppression or its withdrawal allows the immune system to recover and potentially control the EBV infection. It is recommended whenever possible, but its use is limited in the presence of GvHD [13]. Methods targeted at reduction of B-cells include the use of monoclonal antibodies, chemotherapy, and/or surgery [3]. Therapy with monoclonal antibodies aimed at B-cells plays the major role in the therapy of PTLD, both probable and proven. Rituximab, a monoclonal anti-CD20 antibody that depletes the number of B-cells, has proven efficacy in the therapy of systemic PTLD and significantly improves the outcomes of patients [3, 13, 14]. Rituximab and reduction of immunosuppression remain the first-line therapeutic modalities against PTLD [3, 7, 15]. In cases of resistance to rituximab or disease progression, chemotherapy and DLI are the second-line methods [7]. Surgery has only limited use in the therapy of PTLD [15].

For cases of PTLD with CNS involvement there is no established optimal treatment, but it should probably be similar to the one used in immunocompetent lymphoma, as described above. Despite the known value of rituximab in the treatment of B-lymphomas and PTLD, in case of CNS involvement the problem of blood-brain barrier impermeability occurs as a factor limiting the effectiveness of this drug administered intravenously [16]. There are attempts to administer rituximab intrathecally [5, 17] to improve its efficacy in the CNS; however, such treatment has not been licensed so far.

In the presented case PTLD with CNS involvement was successfully treated with intravenous rituximab and reduction of immunosuppression. Because the lymph node biopsy could not be performed, we did not obtain the histological type of PTLD. We had to base our therapeutic decisions on a diagnosis of probable EBV-driven systemic PTLD with B-lymphocyte proliferation. Due to the com-

plication of LP that occurred during the treatment, initially administered intrathecal chemotherapy had to be terminated and therapy was continued solely with intravenous rituximab. The patient recovered, so we assume that penetration of rituximab to the CNS was been improved due to the compromised permeability of the blood-brain barrier resulting from meninges being involved in the course of the lymphoproliferative process. There have been other reported cases of successful CNS PTLD treatment using intravenous rituximab [18, 19], in which disruption of the blood-brain barrier probably contributed to the favourable outcome.

Our observations suggest that it is possible to achieve a positive outcome of PTLD with CNS involvement once penetration of rituximab across the blood-brain barrier is facilitated. Otherwise this improvement might be reached with intrathecal administration of rituximab. Until now there are no recommendations regarding therapy with intrathecal rituximab in PTLD with CNS involvement. This treatment modality requires further studies because it is potentially beneficial in the treatment of life-threatening complications of HSCT.

The authors declare no conflict of interest.

References

1. Styczyński J, Gil L, Piątkowska M, et al. (2010): EBV-dependent post-transplant lymphoproliferative disorder after allogeneic hematopoietic stem cell and solid organ transplantations: similarities and differences. *Acta Haematologica Pol* 41: 35-44.
2. Evens A, Rupali R, Sterrenberg D, et al. (2010): Post-transplantation lymphoproliferative disorders: diagnosis, prognosis and current approaches to therapy. *Curr Oncol Rep* 12: 383-394.
3. Gil L, Styczyński J (2011): Rituximab in treatment of post-transplant lymphoproliferative disease after allogeneic hematopoietic stem cell transplantation. *Współcz Onkol* 15: 155-158.
4. Swerdlow SH, Campo E, Harris NL, et al. (eds.) (2008): WHO Classification of Tumors of Haematopoietic and Lymphoid Tissues. IARC, Lyon, France.
5. Rasche L, Kapp M, Einsele H, Mielke S (2014): EBV-induced post transplant lymphoproliferative disorders: a persisting challenge in allogeneic hematopoietic SCT. *Bone Marrow Transplant* 49: 163-167.
6. Landgren O, Gilbert ES, Rizzo JD, et al. (2009): Risk factors for lymphoproliferative disorders after allogeneic hematopoietic cell transplantation. *Blood* 113: 4992-5001.
7. Styczyński J, Gil L, Kyrz-Krzemicz S, et al. (2012): Strategy of management in Epstein-Barr virus infections in hematology, oncology and transplantology. Guidelines of Polish Federation of Bone Marrow Transplant Centers. *Acta Haematologica Pol* 43: 48-53.
8. Kempf C, Tinguely M, Rushing EJ (2013): Posttransplant lymphoproliferative disorder of the central nervous system. *Pathobiology* 80: 310-318.
9. San-Juan R, Comoli P, Caillard S, et al. (2014): Epstein-Barr virus-related post-transplant lymphoproliferative disorder in solid organ transplant recipients. *Clin Microbiol Infect* 20 Suppl 7: 109-118.
10. Castellano-Sanchez A, Li S, Qian J, et al. (2004): Primary central nervous system posttransplant lymphoproliferative disorders. *Am J Clin Pathol* 121: 246-253.
11. Cavaliere R, Petroni G, Lopes M, Schiff D (2010): Primary central nervous system post-transplantation lymphoproliferative disorder. An International Primary Central Nervous System Lymphoma Collaborative Group Report. *Cancer* 116: 863-870.
12. Schmitz N, Zeynalova S, Glass B, et al. (2012): CNS disease in younger patients with aggressive B-cell lymphoma: an analysis of patients treated on the Mabthera International Trial and trials of the German High-Grade Non-Hodgkin Lymphoma Study Group. *Ann Oncol* 23: 1267-1273.
13. Styczyński J, Gil L, Tridello G, et al. (2013): Response to rituximab-based therapy and risk factor analysis in Epstein Barr virus-related lymphoproliferative disorder after hematopoietic stem cell transplant in children and adults: a study from the Infectious Diseases Working Party of the European Group for Blood and Marrow Transplantation. *Clin Infect Dis* 57: 794-802.
14. Fox CP, Burns D, Parker AN, et al. (2014): EBV-associated post-transplant lymphoproliferative disorder following in vivo T-cell-depleted allogeneic transplantation: clinical features, viral load correlates, and prognostic factors in the rituximab era. *Bone Marrow Transplant* 49: 280-286.
15. Styczyński J, Einsele H, Gil L, et al. (2009): Outcome of treatment of Epstein-Barr virus-related post-transplant lymphoproliferative disorder in hematopoietic stem cells recipients: a comprehensive review of reported cases. *Transpl Infect Dis* 11: 383-392.
16. Jahnke K, Doolittle ND, Muldoon LL, et al. (2006): Implications of the blood-brain barrier in primary central nervous system lymphoma. *Neurosurg Focus* 21: E11.
17. van de Glind G, de Graaf S, Klein C, et al. (2008): Intrathecal rituximab treatment for pediatric post-transplant lymphoproliferative disorder of the central nervous system. *Pediatr Blood Cancer* 50: 886-888.
18. Said-Conti V, Amrolia P, Gaze M, et al. (2008): Successful treatment of central nervous system PTLD with Rituximab and cranial radiotherapy. *Pediatr Nephrol* 28: 2053-2056.
19. Stuhler G, Knop S, Topp MS, et al. (2006): Intravenously administered rituximab induces remission of EBV associated Non Hodgkin lymphoma confined to the brain in a patient after allogeneic stem cell transplantation. *Haematologica* 91: ECR01.