



Contents lists available at [ScienceDirect](http://www.sciencedirect.com)

Trauma Case Reports

journal homepage: <http://www.journals.elsevier.com/trauma-case-reports/>



Case Report

Isolated complete jejunal transection following abdominal blunt trauma with delayed presentation

Ghassan Al-Ramahi, Mohamed Mohamed *, Kristin Kennedy, Gul Sachwani-Daswani, Michael McCann

Trauma Services Department, Hurley Medical Center, One Hurley Plaza, Flint, MI 48439, USA

ARTICLE INFO

Article history:

Accepted 19 October 2015

Available online 6 November 2015

Keywords:

Jejunal transection
Isolated
Blunt trauma
Injury
Small bowel
Delayed

ABSTRACT

In blunt trauma, diagnosis of small bowel injury is infrequent and accounts for less than 1.1% of blunt trauma admissions. Of those, only 0.3% are perforated.¹ Isolated transection of the jejunum following blunt abdominal trauma has rarely been reported in literature.^{2,3} Most cases of small bowel perforations after blunt trauma occur as a result of motor vehicle crashes and falls from heights and are often associated with multiple injuries.⁴ This is a report of a 26 year-old female that presented 14 h after being involved in a motor vehicle crash and was found to have complete transection of her proximal jejunum with underlying mesenteric injury. Following the crash, the patient extricated herself from the vehicle, went home, and fell asleep with no significant complaints initially reported. She woke up hours later with severe abdominal pain and presented to our emergency department. CT was performed and revealed free fluid in the abdomen. Subsequently, an exploratory laparotomy was performed that revealed complete jejunal transection with underlying mesenteric injury. Isolated complete transection of the proximal jejunum should be considered in the evaluation of patients following blunt abdominal trauma, and presentation may be delayed up to 14 h. To the best of our knowledge, this is the first case report of complete transection of the proximal small bowel following a motor vehicle crash with the longest delay in presentation reported in the literature.

© 2015 The Authors. Published by Elsevier Ltd. This is an open access article under the CC BY-NC-ND license

(<http://creativecommons.org/licenses/by-nc-nd/4.0/>).

* Corresponding author. Tel.: +1 810 262 9658; fax: +1 810 262 6341.

E-mail address: mmohame4@hurleymc.com (M. Mohamed).

Introduction

In blunt abdominal trauma, the intestine, although unusual, represents the third most commonly injured organ with a reported incidence of 5%–15% [4]. Injury to the small bowel and mesentery is estimated to account for an incidence of 1%–5% [5]. The jejunum and the ileum are the most commonly injured sites of the small bowel. In blunt trauma, diagnosis of small bowel injury is infrequent and accounts for less than 1.1% of blunt trauma admissions with only 0.3% being perforated [1]. In polytrauma, bowel injuries are difficult to evaluate and often missed despite improved diagnostic techniques. Delayed diagnosis is often associated with increased morbidity and mortality [6,7]. Most cases of small bowel perforations after blunt trauma occur as a result of motor vehicle crashes and falls from heights, and associated with multiple injuries. To the best of our knowledge, there have been only three reported cases of isolated jejunal transection following blunt abdominal trauma (bicycle handle bar, soccer, rugby) [2,3] making this case the first report of isolated, complete transection of the jejunum following a motor vehicle crash, with the longest delay in presentation reported in literature. The only similar report found was of a complete jejunal transection presenting 3 h post injury after a rugby game [2].

Case report

A 26 year-old female involved in a head on motor vehicle collision as a restrained front seat passenger presented to our emergency department approximately 14 h after the incident complaining of severe abdominal pain, neck pain, chest pain, and shortness of breath. The car was travelling at moderate speed (50–60 mph) at the time of the crash. After the collision, the patient got out of the car independently, went home and slept. Hours later, she woke up with severe abdominal pain and presented to our emergency department. She had two episodes of non-bilious, non-bloody vomiting. There was no history of loss of consciousness. Social history was positive for drug use with suspicion for alcohol ingestion prior to the crash, however, a blood alcohol level was not assessed.

On examination, the patient was anxious and diaphoretic. Vital signs revealed tachycardia at 100 beats/min., but were otherwise normal. GCS score was 15/15 with no sensory or motor deficits. Abdominal examination revealed a contusion to the mid-epigastric area, and severe diffuse tenderness with rebound and guarding especially in the epigastric area and left upper quadrant. Head and neck examination revealed midline neck tenderness, but no obvious facial trauma. Chest examination revealed right sided tenderness with ecchymosis under the right breast, and breath sounds were normal bilaterally. Laboratory investigations revealed a white cell count of 12,900/mm³, haemoglobin level of 17.1 g/dL, amylase of 231, lipase of 80, and normal transaminases. Plain X-rays of the chest were negative. CT of the head and neck were negative. CT of the abdomen and pelvis was performed and revealed large amount of free fluid in the abdomen and pelvis (Fig. 1). The density of the fluid was not suggestive of blood with an attenuation coefficient of 40HU. There was no visceral injury detected and the fluid source was unclear at this point.

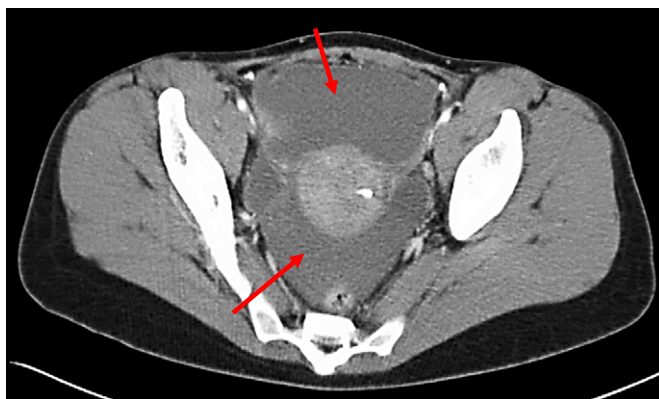

Fig. 1. CT of the pelvis (axial view) showing free fluid in the pelvis.

Diagnostic laparoscopy was performed to assess the nature of the fluid and revealed a large amount of old blood in all gutters. Conversion to open laparotomy was undertaken and all gutters were packed. The small bowel was eviscerated to assess for injury and was found to be completely transected with underlying mesenteric injury at the level of the proximal jejunum. No other injuries were found. Primary repair of the jejunal transection with side-to-side anastomosis was performed with repair of the mesenteric defect. Upon revision of the CT images postoperatively, the two ends of the transected jejunum, initially overlooked, were identified (Fig. 2). The postoperative course was uneventful. The patient was discharged on postoperative day six and is doing well.

Discussion

The incidence of major intestinal injury after blunt abdominal injury is 5%–15% and although unusual, this makes the intestine the third most common injured abdominal organ in blunt trauma [4]. Injury to the small bowel and mesentery is estimated to account for an incidence of 1%–5% [5]. The three most common mechanisms of injury are: (1) crush injury between the vertebrae and abdominal wall, (2) sudden increase in the intraluminal pressure of the bowel, and (3) tangential tears at relatively fixed points along the bowel. Most of these injuries occur as a result of motor vehicle crashes and many of the patients have multisystem injuries [4].

Bowel injuries with or without polytrauma are difficult to diagnose. Most symptoms are vague at initial presentation and only become obvious after repeated clinical abdominal examinations [8]. Patients typically complain of abdominal pain, tenderness, and distension [9]. The jejunum and the ileum represent the most commonly injured sites of the small bowel. In blunt trauma, diagnosis of small bowel injury is infrequent and accounts for less than 1.1% of blunt trauma admissions with only 0.3% being perforated [1].

CT is considered the gold standard for diagnosis of small bowel perforations and has a sensitivity of 92% and specificity of 94% [9]. Ultrasonography, diagnostic laparoscopy, and diagnostic peritoneal lavage (DPL) are other methods of testing. Bowel injuries are still missed despite improved diagnostic techniques. An overlooked bowel injury is perhaps the most dangerous of all abdominal injuries because of the tremendous infection potential. Delayed presentation may occur if the bowel is not ruptured immediately and in such cases, sepsis may develop with increased mortality [6]. Complete jejunal transection presenting 3 h post injury after a rugby game has been reported [2]. Repeated studies have shown increased mortality rates to be directly related to delay in diagnosis [3]. Mortality rates quoted range from 10% to 30% [4].

Management of bowel perforations involves prompt surgical intervention and prophylactic antibiotics. Debridement of devitalised tissue, lavage, and primary closure with or without partial resection and anastomosis may be necessary depending on the location and severity of injury [9].

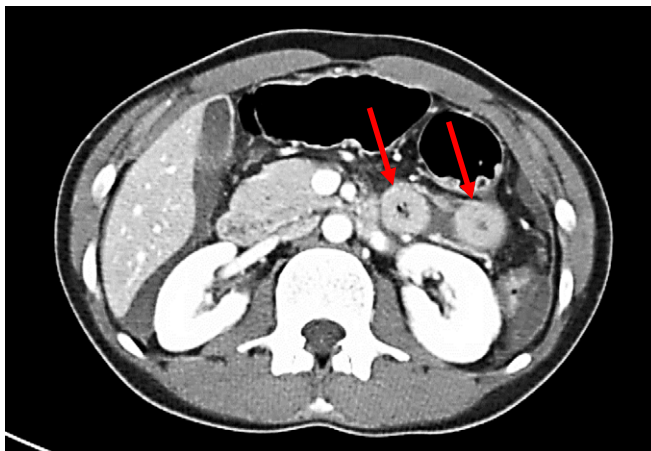


Fig. 2. CT of the abdomen (axial view) showing the two ends of the transected jejunum.

Conclusion

The intestine is the third most commonly injured abdominal organ in blunt trauma. The jejunum and the ileum represent the most commonly injured sites of the small bowel, however, are rarely encountered. Delayed diagnosis is associated with increased mortality. Isolated complete transection of the proximal jejunum following blunt abdominal trauma is possible and should be considered in the evaluation of patients following blunt abdominal trauma. Presentation may be delayed up to 14 h.

Conflict of interest statement

None.

Funding

Nothing to declare.

References

- [1] R.E. Barnett, K.M. Love, E.A. Sepulveda, W.G. Cheadle, Small bowel trauma: current approach to diagnosis and management, *Am. Surg.* 80 (12) (Dec 2014) 1183–1191.
- [2] W. Perry, J. Fischer, C. Wakeman, Jejunal tackle: a case report of complete jejunal transection in rugby union, *Clin. J. Sport Med.* 24 (5) (Sep 2014) e54–e55, <http://dx.doi.org/10.1097/JSM.000000000000012>.
- [3] N.A. Sandiford, R.P. Sutcliffe, H.T. Khawaja, Jejunal transection after blunt abdominal trauma: a report of two cases, *Emerg. Med. J.* 23 (10) (Oct 2006) e55, <http://dx.doi.org/10.1136/emj.2006.038604>.
- [4] A.H. Dauterive, L. Flancbaum, E F Cox. Blunt intestinal trauma, A modern-day review, *Ann. Surg.* 201 (2) (Feb 1985) 198–203.
- [5] J. Pimenta de Castro, G. Gomes, N. Mateus, R. Escrevente, L. Pereira, P. Jácome, Small bowel perforation and mesentery injury after an unusual blunt abdominal trauma—Case report, *Int. J. Surg. Case Rep.* vol. 7 (2015) 51–53.
- [6] E.M. Eltahir, D. Hamilton. Seat belt injuries and Sigmoid colon trauma. *Accid Emerg Med.* 97; 14:338–339.
- [7] Victor J. Sorenson, Judy N. Mikhail, Riyad C. Karmy-Jones, Is delayed laparotomy for blunt abdominal trauma a valid quality improvement measure in the era of non-operative management of abdominal injuries? *J. Trauma* 52 (2002) 426–433.
- [8] N. Symeonidis, K Ballas, K Psarras, et al. Isolated small bowel perforation after blunt abdominal trauma: Report of 2 Cases. *Internet Journal of Surgery*. <https://ispub.com/IJS/27/1/6291>
- [9] M. Mukhopadhyay, Intestinal injury from blunt abdominal trauma : a study of 47 cases, *OMJ* 24 (2009) 256–259, <http://dx.doi.org/10.5001/omj.2009.52>.