

# Multilayer bare stent technique in treating intact mycotic suprarenal aortic aneurysm: a case report

Chao Song <sup>1</sup>, Qing Cai <sup>2</sup>, Yi Huang <sup>3</sup>, and Qingsheng Lu <sup>1\*</sup>

<sup>1</sup>Department of Vascular Surgery, Shanghai Changhai Hospital, Navy Medical University, Shanghai 200082, People's Republic of China; <sup>2</sup>Department of Rheumatology and Immunology, Shanghai Changhai Hospital, Navy Medical University, Shanghai, People's Republic of China; and <sup>3</sup>Department of Respiratory Medicine, Shanghai Changhai Hospital, Navy Medical University, Shanghai, People's Republic of China

Received 22 March 2020; first decision 14 April 2020; accepted 10 September 2020; online publish-ahead-of-print 6 November 2020

## Background

Invasive aspergillosis (IA) related mycotic aortic aneurysm is rare in immunocompetent patient. The endovascular therapy remains controversial due to potential risk of graft infection, while the suprarenal cases might face catastrophic complications during open surgery.

## Case summary

We presented an IA case with suprarenal abdominal aortic aneurysm confirmed by joint effusion. Multilayer bare stent technique was performed to preserve visceral blood flow and promote aneurysmal thrombus formation, along with antifungal treatment. Two years of follow-up revealed complete aneurysm thrombosis without evidence of infection.

## Discussion

Fungal infection that affects the aorta is difficult to recognize due to often negative blood cultures. Close observation is recommended in case of suspicion of mycotic aneurysms. Multilayer bare stent technique can restore luminal laminar blood flow and reduce the risk of infection in intact mycotic suprarenal aortic aneurysm.

## Keywords

Mycotic aortic aneurysm • Fungal infection • Endovascular repair • Case report

## Learning points

- Primary aspergillosis suprarenal abdominal aortic aneurysm is a rare and catastrophic disorder due to the risk of aneurysm rupture and the difficulty of the aorta repair.
- The multilayer bare stent technique can minimize the risk of graft infection and reduce flow velocity in the aneurysm sac while maintaining flow in the parent artery and branch vessels.

## Introduction

Invasive aspergillosis (IA) is a rare but life-threatening disease commonly seen in immunocompromised patients, which is featured with acute or chronic pulmonary aspergillosis infection and the major symptom is breathing difficulty caused by bronchial

pseudomembrane.<sup>1,2</sup> Infections outside the lung is often seen in patients with intracranial infection (10–40%), and there are several reports reporting cases involving infections in the skin, kidney, heart, and aorta.<sup>3,4</sup> However, such cases are seldom seen in immunocompetent patient, very few cases are considered to be related to trauma or history of open cardiovascular surgery.<sup>5,6</sup>

\* Corresponding author. Tel: +86-21-31161668, Email: [luqs@xueguan.net](mailto:luqs@xueguan.net)

Handling Editor: Adjedj Julien

Peer-reviewers: Bonaros Nikolaos; Iskandar Zaid; Singh Arvind

Compliance Editor: Vamvakidou Anastasia

Supplementary Material Editor: Memtsas Vassilios Parisis

© The Author(s) 2020. Published by Oxford University Press on behalf of the European Society of Cardiology.

This is an Open Access article distributed under the terms of the Creative Commons Attribution Non-Commercial License (<http://creativecommons.org/licenses/by-nc/4.0/>), which permits non-commercial re-use, distribution, and reproduction in any medium, provided the original work is properly cited. For commercial re-use, please contact [journals.permissions@oup.com](mailto:journals.permissions@oup.com)

We report a rare case of IA in a middle-aged immunocompetent woman causing suprarenal abdominal aortic aneurysm. This case highlights the possibility of multilayer bare stent technique (two or more bare-metal stents overlapping with each other) in the mycotic aortic aneurysm treatment. It also illustrates the importance of thorough history taking in the diagnosis of IA.

effusion polymerase chain reaction (PCR) for fungus was performed and finally showed positive result. To eliminate the possibility of sample contamination, we further allied highly specific serum immunological test to confirm the positive antibody of *Aspergillus fumigatus*. Following exclusion of involvement of other organs (i.e. head and lung) from IA, Voriconazole (400 mg, bid, for 1st day and followed by 200 mg, bid), and Caspofungin (70 mg, for 1st day and followed by

## Timeline

Time	Event	
1 year prior	Thoracic aortic aneurysm treated with thoracic endovascular aortic repair	
3 months prior	Follow-up computed tomography angiography confirmed the thoracic aortic aneurysm recovered uneventfully	
First presentation	15-day history of severe hip pain with hip joint tenderness, the joint effusion polymerase chain reaction and highly specific serum immunological test confirmed the infection of <i>Aspergillus fumigatus</i> . A 54 mm suprarenal abdominal aortic aneurysm was found during computed tomography (CT) scan. Voriconazole and Caspofungin were recommended.	
2nd admission (3 months later)	Initial evaluation	The result was negative for <i>A. fumigatus</i> in two consecutive tests.
	Hospital Day 3	Three overlapping metal bare stents (24–80 mm, Sinus-XL, OptiMed, Germany) were successfully and accurately deployed from pre-existing stent to the distal end of abdominal aorta.
	Hospital Day 6	Patient discharged home to continue antifungal treatment
2 years post-discharge	CT scan confirmed complete thrombosis of the aneurysm sac while the visceral arteries maintained patency	

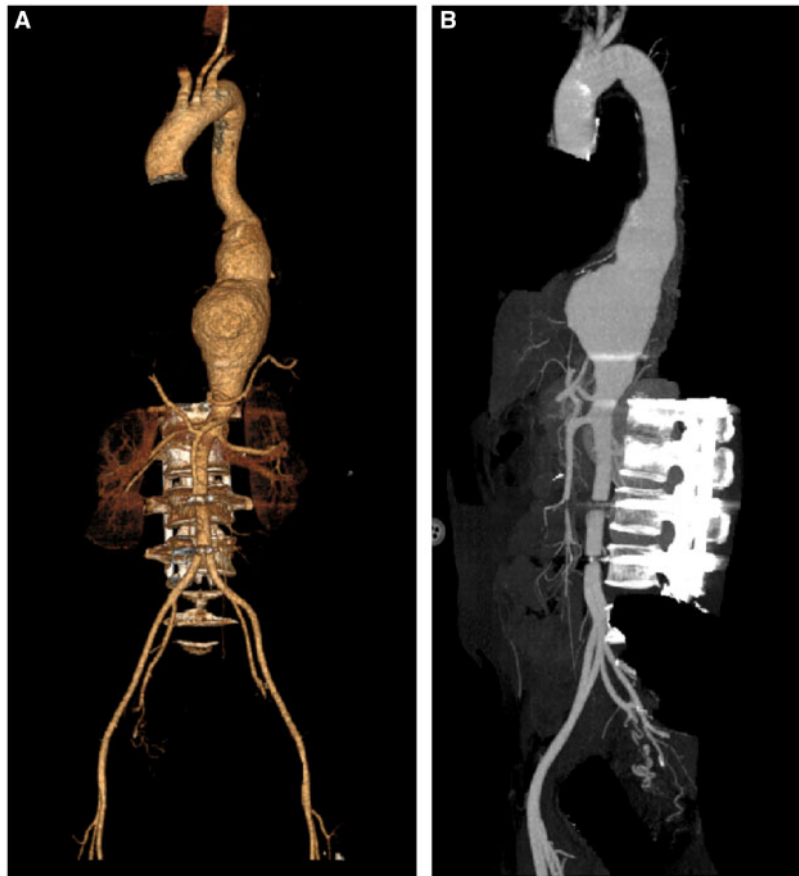
## Case summary

A 43-year-old, non-smoking woman was sent to the emergency room with a 15-day history of severe left hip pain. She received thoracic endovascular aortic repair (TEVAR) due to descending aortic aneurysm 1 year ago (Figure 1) and recovered uneventfully in the 9 months of follow-up. The patient was diagnosed with hypertension 5 years ago, and was on regular nifedipine 30 mg once daily. Past medical history also includes lumbar internal fixation of fractured lumbar vertebra 5 years ago. The family history of congenital disease was negative and recent foreign travel was also denied. Her physical examination revealed a temperature of 36.3°C, pulse rate 82 b.p.m., breathing of 16 times/min and blood pressure 118/75 mmHg. She had no focal oedema or restriction of hip motion, but noted hip tenderness to palpation, other physical examination was unremarkable. Results of laboratory testing, including white blood cell count and erythrocyte sedimentation rate, were within normal limits and no biomarkers of autoimmune disease were found.

Compared to the computed tomography angiography 1 year earlier, a 54 mm suprarenal abdominal aortic aneurysm combined with left renal artery and proximal superior mesenteric artery ( ) occlusion was detected, which raised the suspicion of a mycotic aneurysm due to previous patient exposure to farming and composting in greenhouse in addition to the rapid dilation of abdominal aorta from 12 mm to 54 mm within 1 year (Figures 1 and 2). Blood cultures and  $\beta$ -glucan measurements were conducted and resulted in two negative results. Considering the possibility of occult infection, the joint

therapy (50 mg up to Day 21) were then recommended and the systolic blood pressure was no greater than 120 mmHg during the combination therapy.

Three months after antifungal therapy, the result was negative for *A. fumigatus* in two consecutive tests. Despite active anti-hypertension therapy, the patient's systolic blood pressure remained persistently above 140 mmHg, and she felt intermittent abdominal pain which might have been associated with abdominal aortic aneurysm. So we decided to choose more aggressive treatment other than conservative approach. Considering the location of the pre-existing bare stent and the history of fungal infection, open surgery, and covered stent were not suitable for this patient, instead the multilayer bare stent technique was chosen to restore laminar flow, promote aneurysmal thrombus formation, and maintain branches patency. The diameter of proximal abdominal aorta was 20 mm based on CT angiography measurement, and we confirmed this data from fluoroscopy on the day of procedure. Three overlapping metal bare stents (diameter: 24 mm, length: 80 mm, Sinus-XL, OptiMed, Germany) were successfully and accurately deployed from pre-existing stent to the distal end of abdominal aorta. The length of overlap area is 60 mm. Immediate post-operative angiography demonstrated that the blood flow velocity was reduced in the aneurysm sac. The patient was discharged 3 days later and advised to take extended antifungal treatment for at least 1 year. The patient recovered without any symptoms during 2 years of follow-up. The CT angiography demonstrated complete thrombosis of the aneurysm sac while the right



**Figure 1** Computed tomography angiography of pre-existing descending thoracic aortic aneurysm. (A, anterior view; B, left lateral view).

renal artery and coeliac artery patency are maintained, and no signs of endoleak were revealed from the cross-section images (Figure 3).

Informed consent was obtained from the patient in agreement to publish case details and images.

## Discussion

Primary aspergillosis aortic aneurysm is very rare, occurs mostly in immunocompromised patients, and is associated with high mortality. The intramural growth tendency as a central element in the pathophysiology of *Aspergillus* hyphae compromise the structural integrity of the aorta, resulting in the aortic aneurysm.<sup>7</sup> The angioinvasiveness of this pathogen results in aneurysm enlargement and rupture. However, the diagnosis is often delayed owing to non-specific clinical manifestations. As a result, enhanced diagnostic awareness and more intensive diagnostic efforts (repeated blood cultures; serum fungal cell wall antigen detection; microscopic, cultural, and PCR examination of joint aspirate and specimen from aortic wall) may help to identify the fungus earlier.

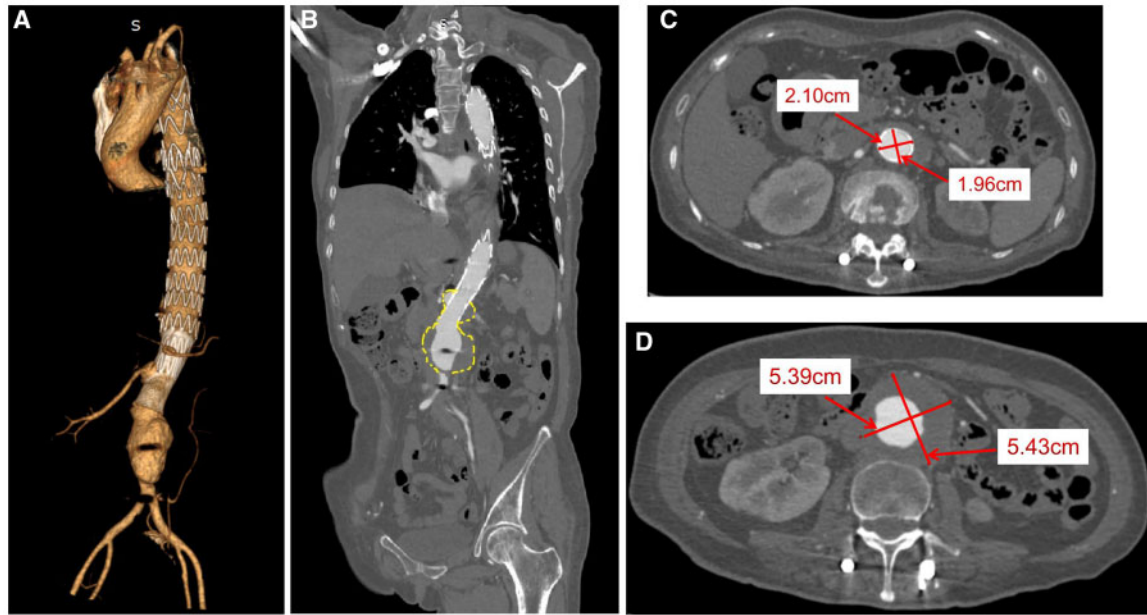
The source and the route of the fungal infection should also be noticed. This immunocompetent patient was not subject to any trauma or surgery histories, the possibility of open wound contact could thus be excluded. With further investigation, the patient had a

long time experience of farm work, especially composting in greenhouse. The content of *A. fumigatus* is extremely high in the greenhouse soil and compost.<sup>8</sup> Although this possibility is hard to verify, it is still suggested that for patients engaged in the agriculture field, physicians should pay attention to exclude the possibility of such infection.

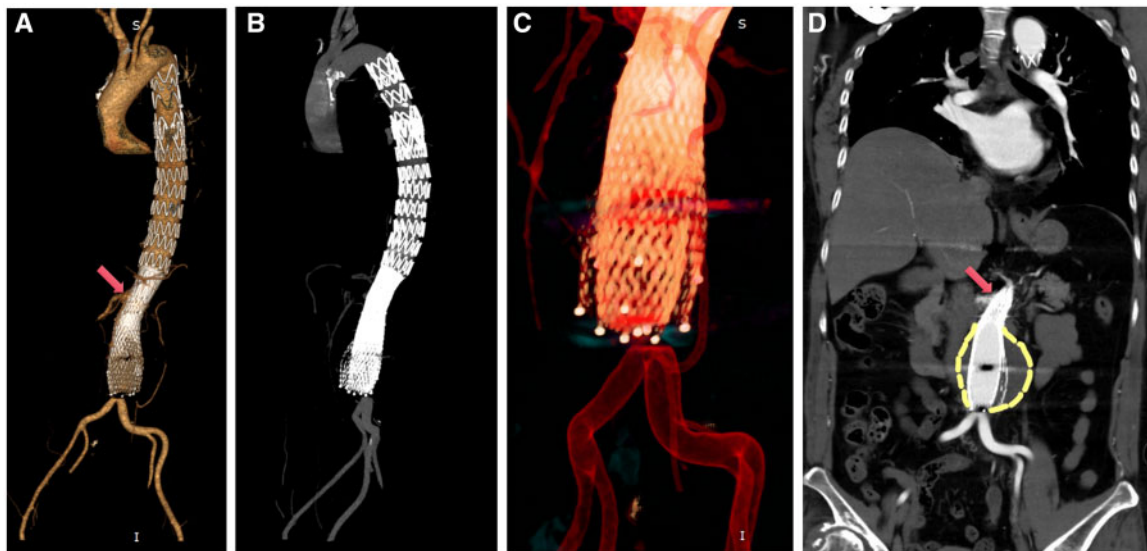
Although infectious aneurysms were initially named mycotic aneurysms, common pathogens are mainly bacteria, including *Streptococcus*, *Pneumococcus*, *Haemophilus influenzae*, and iatrogenic infections such as *Staphylococcus* and *Salmonella*. Currently, open surgical treatment for such aneurysm remains the gold standard.<sup>4</sup> It consists of infected-tissue resection and aortic replacement with a prosthetic graft or an allograft if available.

Despite this first-line aggressive approach, survival is very poor. Furthermore, some patients cannot receive surgical treatment due to the severity of the infection. Although there is a lack of first-level evidence, there are studies suggesting that the 1-year survival rate after endovascular treatment of infectious abdominal aortic aneurysm is 75–83.9%, which has a significantly better outcome than open surgery,<sup>9</sup> and this superiority is more apparent in infectious thoracic aortic aneurysm.

The pre-existing distal restrictive bare stent was deployed at the level of renal arteries as a bridge to provide a relatively normal distal landing zone for TEVAR, but it also adds to the difficulty of



**Figure 2** Computed tomography angiography of abdominal aortic aneurysm. (A) 3D reconstruction (anterior view); (B) coronal-section image (Yellow dashed line: abdominal aortic aneurysm). (C) The proximal diameter of abdominal aortic aneurysm. (D) The maximal diameter of aneurysm.



**Figure 3** Two years of follow-up computed tomography angiography. (A, anterior view; red arrow: right renal artery. B, left lateral view; C, 3D reconstruction of multilayer bare stents; D, coronal-section image demonstrated no endoleaks. Red arrow: right renal artery; Yellow dashed line: thrombosed abdominal aortic aneurysm).

anastomosis during open surgery. And in case of incomplete control over the systemic fungal infection, we chose multilayer bare stent technique to redirect the blood flow, reduce the pressure of the aneurysm sac, maintain branches patency, and minimize the risk of graft infection at the same time. The multilayer bare stent technique has

been well described by our group previously,<sup>10</sup> and it has been gradually applied to treat aneurysms, and the curative effect has been proven by clinical follow-up trials and haemodynamic theories. A retrospective study which contained 61 patients exhibiting complex aneurysms revealed that the technical success was 95%, and the

percentage of patients who were free from rupture and re-intervention was 97.5% and 100%, 96% and 84%, and 86% and 75% for 1 month, 6 months, and 12 months, respectively.<sup>11</sup> Considering the difficulty of revascularization, we carefully evaluated compensatory blood supply from collateral artery (e.g. Riolan arch). The gastrointestinal and renal function were normal, and no additional operation was selected to minimize the risk of branches stenosis or occlusion. Compared with stent grafts, multilayer bare stents seem to be effective in preserving the spinal cord blood supply in previous study,<sup>12</sup> and our result was consistent with that.

With the multilayer bare stent technique, shrinkage occurred with the growth of sac thrombosis, and it is even found that the maximum shrinkage could be as high as 57%.<sup>13</sup> The haemodynamics indicated that the blood flow and pressure inside the sac declined immediately after multilayer bare stents were employed. Furthermore, a numerical investigation concluded that the pressure on the aneurysmal wall were more uniformly distributed, wall shear stress declined, and oscillatory shear index and relative residence time increased with two-layer stent employment.<sup>14</sup> In our case, the 2-year follow-up confirmed the remain right renal artery and coeliac artery patency, along with complete thrombosis of the aneurysm sac, suggesting that this technique can be an emergency treatment for non-ruptured infectious aneurysms.

To our knowledge, there is no definite follow-up plan for mycotic aneurysm related to fungal infection. According to the study by Sörelius *et al.*,<sup>15</sup> most of the infection-related complications occurred within 6 months after the operation. Notably, the fungal infection is more dangerous, so the patient should be closely followed up under the guidance of infection specialists and the anti-infection treatment should be maintained for at least 6–12 months, and even lifelong if necessary.<sup>9</sup>

## Conclusion

Primary aspergillosis suprarenal abdominal aortic aneurysm is a rare and catastrophic disorder due to the risk of aneurysm rupture and the difficulty of the aorta repair. The multilayer bare stent technique can minimize the risk of graft infection and reduce flow velocity in the aneurysm sac while maintaining flow in the parent artery and branch vessels.

## Lead author biography



Chao Song, MD, PhD, is a vascular surgeon at the Shanghai Changhai Hospital, he earned his MD and PhD degrees from the Second Military Medical University, Shanghai, China. His clinical and academic interests are in endovascular treatment of aortic diseases. He has held an hon-

orary contract with Dr Qingsheng Lu, Consultant vascular surgeon, within Shanghai Changhai Hospital allowing him to take formative steps and experience prior to formal core training.

## Supplementary material

Supplementary material is available at *European Heart Journal - Case Reports* online.

**Slide sets:** A fully edited slide set detailing this case and suitable for local presentation is available online as [Supplementary data](#).

**Consent:** The author/s confirm that written consent for submission and publication of this case report including image(s) and associated text has been obtained from the patient in line with COPE guidance.

**Conflict of interest:** none declared.

## References

- Dagenais TRT, Keller NP. Pathogenesis of *Aspergillus fumigatus* in invasive aspergillosis. *Clin Microbiol Rev* 2009;**22**:447–465.
- Li Y, Yu F, Parsons C, Chen C, Ye M, Ye J *et al.* Pseudomembranous *Aspergillus tracheobronchitis*: a potential for high mortality in low-risk patients. *Am J Med Sci* 2013;**346**:366–370.
- Latgé JP. *Aspergillus fumigatus* and aspergillosis. *Clin Microbiol Rev* 1999;**12**: 310–350.
- Tresson P, Roussel A, Mordant P, Cerceau P, Castier Y, Pellenc Q. Endovascular repair as a bridge to open repair of a ruptured descending thoracic aspergillus aortitis. *Ann Thorac Surg* 2017;**104**:e425–e428.
- Cheon S, Yang MK, Kim C-J, Kim TS, Song K-H, Woo SJ *et al.* Disseminated aspergillosis in the immunocompetent host: a case report and literature review. *Mycopathologia* 2015;**180**:217–222.
- Pasqualotto AC, Denning DW. Post-operative aspergillosis. *Clin Microbiol Infect* 2010;**12**:1060–1076.
- Jain A, Goyal K, Meher R, Passey JC. Internal carotid artery bleed: a rare complication of invasive sphenoidal aspergillosis. *World Neurosurg* 2019;**129**:292–294.
- Kwon-Chung KJ, Sugui JA. *Aspergillus fumigatus* - what makes the species a ubiquitous human fungal pathogen? *PLoS Pathog* 2013;**9**:e1003743.
- Sörelius K, Wanhainen A, Furebring M, Björck M, Gillgren P, Mani K, *et al.*; On behalf of the Swedish Collaborator Group for Mycotic Abdominal Aortic Aneurysms. Nationwide study of the treatment of mycotic abdominal aortic aneurysms comparing open and endovascular repair. *Circulation* 2016;**134**: 1822–1832.
- Zhang Y-X, Lu Q-S, Feng J-X, Zhao Z-Q, Bao J-M, Feng R *et al.* Endovascular management of pararenal aortic aneurysms with multiple overlapping uncovered stents. *J Vasc Surg* 2013;**58**:616–623.
- Ibrahim W, Spanos K, Gussmann A, Nienaber CA, Tessarek J, Walter H *et al.* Early and midterm outcome of multilayer flow modulator stent for complex aortic aneurysm treatment in Germany. *J Vasc Surg* 2018;**68**:956–964.
- Wang M, He Q, Yao C, Yin H-H, Wang S-M, Chang G-Q. Treatment of high surgical risk thoracoabdominal aortic aneurysms with stent graft and multilayer bare stents joint technique: mid-long-term clinical results. *Ann Vasc Surg* 2020;**63**: 108–116.
- Balderi A, Antonietti A, Pedrazzini F, Sortino D, Vinay C, Grosso M. Treatment of visceral aneurysm using multilayer stent: two-year follow-up results in five consecutive patients. *Cardiovasc Intervent Radiol* 2013;**36**:1256–1261.
- Zhang P, Liu X, Sun A, Fan Y, Deng X. Hemodynamic insight into overlapping bare-metal stents strategy in the treatment of aortic aneurysm. *J Biomech* 2015; **48**:2041–2046.
- Sörelius K, Mani K, Björck M, Sedivy P, Wahlgren C-M, Taylor P *et al.* European MAA Collaborators. Endovascular treatment of mycotic aortic aneurysms: a European multicenter study. *Circulation* 2014;**130**:2136–2142.