



CASE REPORT

Cerebral sinovenous thrombosis in pediatric hemolytic uremic syndrome

Kirk D. Wyatt MD¹ | Vilmarie Rodriguez MD¹ | Paul E. Youssef DO² |
 Laurence J. Eckel MD³ | Deepti M. Warad MBBS¹  

¹Division of Pediatric Hematology/Oncology, Department of Pediatric and Adolescent Medicine, Mayo Clinic, Rochester, Minnesota

²Division of Child and Adolescent Neurology, Department of Neurology, Mayo Clinic, Rochester, Minnesota

³Division of Neuroradiology, Department of Radiology, Mayo Clinic, Rochester, Minnesota

Correspondence

Deepti M. Warad, Division of Pediatric Hematology/Oncology, Department of Pediatric and Adolescent Medicine, Mayo Clinic, 200 First Street Southwest, Rochester, MN 55905.
 Warad.Deepti@mayo.edu

Handling Editor: Mary Cushman

Abstract

Hemolytic uremic syndrome (HUS) may result in thrombotic central nervous system complications. We present a child with diarrhea-associated HUS who developed new-onset focal seizures secondary to cerebral sinovenous thrombosis (CSVT). Her CSVT was treated with low-molecular-weight heparin. The patient's seizures were controlled with levetiracetam, and her HUS was managed supportively with hemodialysis. Repeat imaging nearly 6 months following presentation and initiation of anticoagulation demonstrated cerebral sinus enlargement and persistent intraluminal webbing. Anticoagulation was discontinued after 6 months, and she did not experience long-term gross neurologic sequelae. CSVT is a complication of HUS that has not been previously described. In this report, we summarize the thrombotic central nervous system complications of pediatric HUS.

KEYWORDS

central nervous system, child, hemolytic uremic syndrome, stroke, venous thrombosis

Essentials

- Central nervous system thromboses in diarrhea-associated hemolytic uremic syndrome (HUS) are primarily arterial events.
- Cerebral sinovenous thrombosis (CSVT) has not been described in diarrhea-associated HUS.
- Early recognition can be challenging due to broad neurologic differential diagnoses.
- A multidisciplinary team approach is essential for anticoagulation management of CSVT in HUS.

1 | INTRODUCTION

Hemolytic uremic syndrome (HUS) is characterized by acute kidney injury, thrombocytopenia, and microangiopathic hemolytic anemia, and it is most commonly caused by Shiga toxin-producing *Escherichia coli*.¹ Although the clinical effects of the disease on the

microvasculature are primarily manifest by renal involvement, Shiga toxin-induced endothelial damage and elevations of prothrombotic factors may theoretically lead to a generalized predisposition to thrombosis. We report a child who developed cerebral sinovenous thrombosis (CSVT) associated with HUS. Although focal cerebral infarction has been previously reported in patients with HUS,^{2,3}

Key Clinical Question: What are the thrombotic central nervous system complications of pediatric hemolytic uremic syndrome?

This is an open access article under the terms of the Creative Commons Attribution-NonCommercial-NoDerivs License, which permits use and distribution in any medium, provided the original work is properly cited, the use is non-commercial and no modifications or adaptations are made.

© 2020 The Authors. *Research and Practice in Thrombosis and Haemostasis* published by Wiley Periodicals, Inc on behalf of International Society on Thrombosis and Haemostasis.

CSVT has not been previously described with diarrhea-associated HUS.

2 | CASE

A previously healthy 17-month old girl initially presented to a local emergency department after development of bloody diarrhea, decreased oral intake, and irritability. She was initially managed with intravenous hydration and dismissed home. Stool polymerase chain reaction (PCR) testing was performed for pathogen identification, and she received intravenous hydration. After clinical improvement, she was discharged to home. Three days following her initial presentation, she developed irritability and decreased urinary output. Initial stool PCR testing returned showing *E coli* O157:H7. On reevaluation at the local emergency department, her creatinine had risen to 1.17 mg/dL (Table 1). Electrolytes were notable for hyponatremia, and complete blood count revealed normal hemoglobin, leukocytosis, and thrombocytopenia, with peripheral blood smear showing schistocytes (Table 1). She was transferred to our institution for management of HUS. At the time of admission, coagulation studies revealed normal fibrinogen with slightly

shortened prothrombin time and partial thromboplastin time (Table 1).

The following day, the patient developed a prolonged focal clinical seizure, characterized by left periocular muscle twitching, followed by left facial twitching and jerking movements of the left hand that progressed to the right face. Seizure rescue was attempted with intranasal midazolam; however, seizures continued. A 20-mL/kg bolus of normal saline was administered out of concern for hyponatremic seizure, and the seizure subsequently stopped after approximately 35 minutes. The patient was transferred to the pediatric intensive care unit for further management. Repeat laboratory studies revealed worsening anemia, persistent leukocytosis, and worsening thrombocytopenia. Electrolytes revealed stable hyponatremia, rising creatinine, normal glucose, and slightly low ionized calcium (Table 1). Because her electrolyte derangements were not thought to be severe enough to account for her seizure, neuroimaging was obtained to further investigate for a cause. Emergent head computed tomography scan revealed hyperdensity throughout the superior sagittal sinus concerning for venous sinus thrombosis (Figure 1A). Magnetic resonance angiography (MRA) and magnetic resonance venography (MRV) performed later that day confirmed a nonocclusive thrombus in the superior sagittal sinus,

Laboratory test (reference range)	Time point		
	Initial presentation (+0)	Reevaluation and hospital transfer (+3 d)	Initial seizure (+4 d)
Electrolyte panel			
Creatinine (0.1-0.4 mg/dL)	0.37 mg/dL	1.7 mg/dL	2.9 mg/dL
Blood urea nitrogen (7-20 mg/dL)		35 mg/dL	51 mg/dL
Sodium (135-145 mmol/L)		128 mmol/L	131 mmol/L
Glucose (70-140 mg/dL)			96 mg/dL
Ionized calcium (4.9-5.5 mg/dL)			4.82 mg/dL
Complete blood count			
Hemoglobin (10.5-13.5 g/dL)		12.2 g/dL	8.3 g/dL
Leukocyte count (6.0-11.0 × 10 ⁹ /L)		21 × 10 ⁹ /L	21.2 × 10 ⁹ /L
Platelet count (150-450 × 10 ⁹ /L)		96 × 10 ⁹ /L	59 × 10 ⁹ /L
Coagulation studies			
Fibrinogen (200-393 mg/dL)		276 mg/dL	
Prothrombin time (9.4-12.5 seconds)		9.2 s	
Partial thromboplastin time (25-37 s)		17 s	

TABLE 1 Laboratory parameters

with sinus dilation (Figure 1B, C). Small acute infarctions in the right temporo-occipital region and parafalcine frontal gyrus were noted. No intracranial hemorrhage or arterial abnormalities were present. Prolonged video electroencephalography while intubated and sedated revealed expected changes from anesthetic effect but did not capture any clinical or electrographic seizures. Family history was negative for thrombotic disorders.

With worsening thrombocytopenia and need for hemodialysis due to acute kidney injury, the risks of anticoagulation were thought to outweigh the benefits. She underwent Mahurkar dialysis catheter placement for hemodialysis. She was extubated and started on levetiracetam at renal function-adjusted dosing. After sedation was weaned over the course of 2 days, she was noted to be at her neurologic baseline, with no evidence of seizures on continuous electroencephalogram.

Five days after the seizure, she remained on intermittent hemodialysis. Her platelet counts stabilized, and she was considered stable enough to initiate anticoagulation. Because of the risk of propagation of the thrombus and challenges of dosing low-molecular-weight heparin in the setting of intermittent hemodialysis, unfractionated heparin was initiated with a plan for transition to low-molecular-weight heparin once hemodialysis was discontinued. To minimize the risk of bleeding complications, a conservative goal anti-Xa level of 0.2-0.5 IU/mL while on unfractionated heparin was chosen with gradual adjustment to achieve therapeutic levels. Within a week of starting unfractionated heparin, she was transitioned to enoxaparin 1 mg/kg subcutaneously twice daily (goal anti-Xa level of 0.5-1.0 IU/mL).

MRA and MRV performed 11 weeks after initial diagnosis revealed marked interval decrease in the extent of nonocclusive

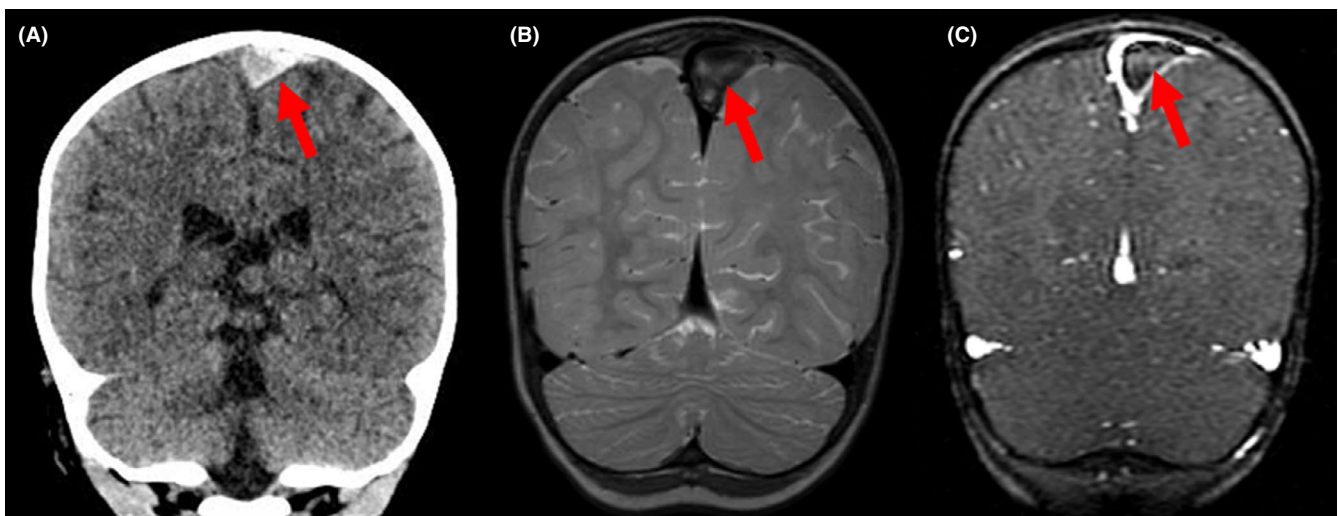


FIGURE 1 Initial neuroimaging. A, Coronal reformatted noncontrast head computed tomography; B, coronal T2-weighted magnetic resonance imaging; and C, coronal time-of-flight magnetic resonance angiography show a nonocclusive thrombus in an enlarged superior sagittal sinus (arrows)

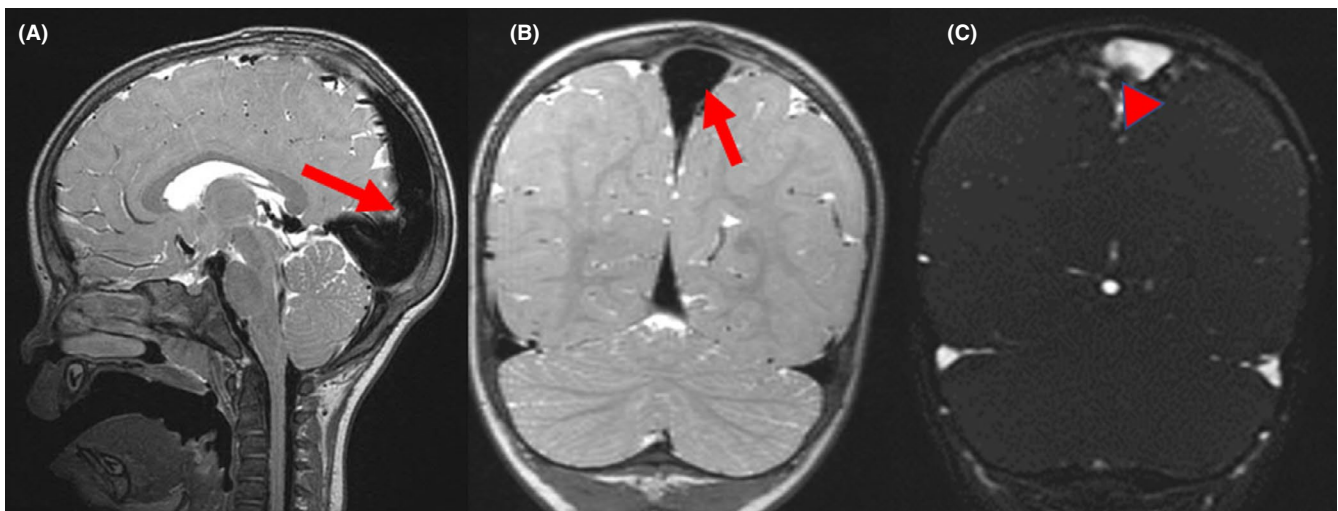


FIGURE 2 Neuroimaging 11 weeks after initial. A, Sagittal T2-weighted magnetic resonance imaging (MRI); B, coronal T2-weighted MRI; and C, coronal time-of-flight magnetic resonance angiography show the enlarged sagittal and straight sinuses and torcula (arrows), with decrease in the extent of thrombus (arrowhead)

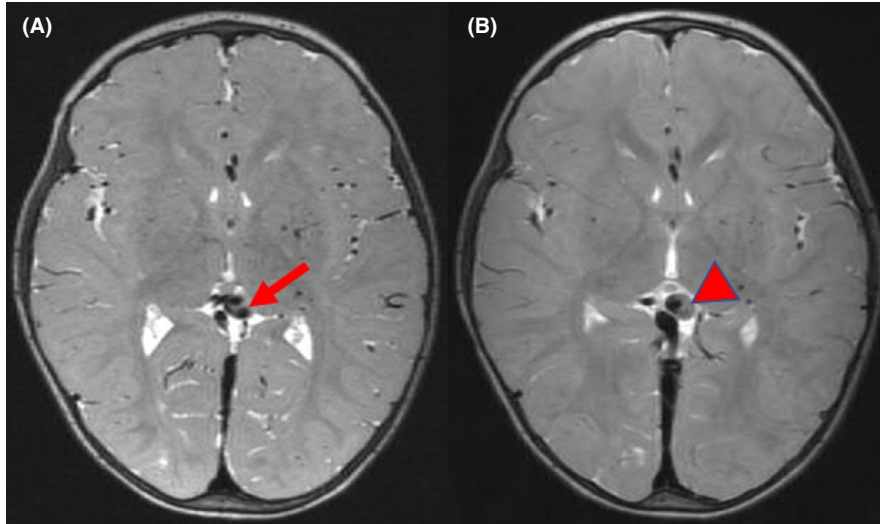


FIGURE 3 A, Axial T2-weighted magnetic resonance imaging (MRI) 11 weeks after diagnosis; and B, axial T2-weighted MRI 5.5 months after diagnosis. Imaging shows altered flow-related signal at the confluence of the internal cerebral vein and vein of Galen, thought to represent a partially thrombosed varix (arrow). On later imaging, reduced flow-related signal indicates additional thrombosis of the varix, without occlusion (arrowhead)

superior sagittal sinus thrombosis but new findings of markedly abnormal ectatic/enlarged sigmoid, straight, and left transverse sinuses with ectatic internal cerebral veins as well as abnormal signal at the confluence of the internal cerebral vein and vein of Galen, thought to represent aneurysmal dilatation of the vein, now partially thrombosed (Figure 2; Figure 3A).

She was continued on enoxaparin with repeat magnetic resonance imaging performed 5.5 months after her initial diagnosis, which demonstrated patent and dilated superior sagittal sinus with residual intraluminal webbing. The transverse sinuses were also mildly irregular with intraluminal webbing consistent with prior thrombus. The previously seen abnormality in the region of the internal cerebral vein was unchanged in size but with increased internal heterogeneity, again consistent with partially thrombosed varix or aneurysmal dilatation (Figure 3B).

At that time, neurologic examination by a pediatric neurologist revealed no gross deficits, and there was no clinical history of recurrent seizures. Therefore, levetiracetam was discontinued. Enoxaparin was also discontinued. Three weeks after discontinuing enoxaparin, a comprehensive thrombophilia profile, including lupus anticoagulant testing, demonstrated no evidence of thrombophilia. Antiphospholipid antibody titers were not performed. The most recent follow-up was 1.5 years after diagnosis, at which point no gross neurologic deficits were noted on neurologic examination, and she was meeting age-appropriate developmental milestones. She has had no known long-term complications relating to her sinovenous thrombosis. We plan to conduct comprehensive neuropsychiatric testing when the patient is older.

3 | DISCUSSION

CSVT is a rare but important and previously unreported complication associated with diarrhea-associated HUS. Seizure was the only neurologic manifestation associated with this patient's sinovenous

thrombosis, and to date she has no long-term gross clinical neurologic sequelae.

CSVT is estimated to occur in 0.67 of 100 000 children per year.⁴ Over half of all cases are reported in children <1 year of age, with the vast majority of these cases representing neonates.⁴ The most common presenting symptoms in children include headache and seizures, though more severe cases can be associated with mental status changes and encephalopathy.⁴ Risk factors include acute systemic illness, prothrombotic disorders, and dehydration.⁴ In fact, over half of patients with CSVT have an underlying prothrombotic defect, such as factor V Leiden, prothrombin G20210A variant, elevated serum lipoprotein(a), protein C deficiency, protein S deficiency, antithrombin deficiency, or antiphospholipid antibodies.⁵ The mechanism for development of CSVT in HUS is not entirely clear, though the cause is likely multifactorial.

CNS manifestations of HUS have been well documented; however, the common findings of seizures and altered mental status are often attributable to metabolic derangements caused by renal impairment.⁶ Hemorrhagic stroke has been reported as a cause of focal infarction in patients with HUS and may be related to underlying thrombocytopenia and provoked by concurrent hypertension.^{2,3}

At its core, HUS is a disorder of microangiopathy precipitated by endothelial injury leading to inflammation and formation of thrombi. While this provides a theoretical basis for development of thrombotic complications in large vessels, it does not explain why thrombotic complications in HUS generally tend to occur in the microvasculature rather than large vessels.^{1,7}

HUS is associated with elevations in prothrombotic coagulation factors, including factor VIII, which could contribute to an overall prothrombotic predisposition. For example, Shiga toxin promotes the release of thrombin and increases fibrin concentration.⁷ Shiga toxin has also been found to promote ultra-large von Willebrand factor multimers, which can contribute to a prothrombotic state,⁸ and HUS is also associated with elevations of the prothrombotic factor plasminogen activator inhibitor-1.⁹ These observations support the

TABLE 2 Nonhemorrhagic stroke in classic diarrheal HUS, literature review

Reference	Age	Stroke localization	Timing of symptom onset (days following admission)	Presenting sign/symptom	Antiepileptic administered?	Anticoagulation administered	Long-term sequelae
Our patient	17 mo	Superior sagittal sinus thrombosis	1	Generalized seizure	Yes	Unfractionated heparin followed by enoxaparin for 5.5 mo	Cerebral vasculature dilation; venous webbing
[3]	2 y	Right parieto-occipital nonhemorrhagic infarction (with concurrent hemorrhagic infarction)	8	Generalized seizure	Yes	NA	Severe neurologic impairment
[15]	3 y	Bilateral basal ganglia	2	Generalized seizure, altered mental status	Yes	Nafamostat mesilate, heparin	Left hemiparesis, dysphemia
[16]	2 y	Left parietal and frontal	12	Altered mental status progressing to right focal seizures	Yes	NA	Mild right hemiparesis
[17]	3 y	Bilateral internal carotid thrombosis with left ACA and MCA distribution infarction	2	Altered mental status, visual field defect, hemiplegia	NA	Aspirin	Died of cerebral herniation
[17]	4 y	Parietofrontal infarction	NA	Left hemiparesis, visual field defect	Yes	No	Died of cerebral herniation
[17]	3 y	Right ACA and MCA distribution infarction	NA	Left hemiparesis, visual field defect	Yes	No	Residual left hemiparesis, visual field defect, expressive aphasia, dyspraxia
[18]	4 y	Bilateral parietal, bilateral occipital, left frontal	7	Altered mental status, confusion, left hemiparesis, speech impairment	Yes	NA	Severe impairment with spasticity, seizures, dystonia
[19]	5 y	Right hemispheric (lacunar)	10	Left hemiparesis; progression to left facial droop	NA	NA	Involuntary movement disorder
[20]	4 y	Right basal ganglia	7	Slurred speech, left facial droop, left hemiparesis	NA	NA	Mild left upper extremity motor impairment; mild left leg weakness
[21]	11 mo	Frontotemporal (multiple), basal ganglia	NA	Seizure	Yes	NA	Died
[21]	3 y	Right middle cerebral artery distribution	NA	Coma, left hemiplegia, blindness			Died
[21]	4 y	Right posterior frontal, left parieto-occipital	NA	Left hemiplegia, left facial droop, blindness	NA	NA	Left hemiparesis, cortical blindness
[21]	11 y	Right parieto-temporal (associated with other, hemorrhagic, infarction)	3	Altered mental status progressing to coma	NA	NA	Died
[21]	14 y	Left cerebral hemisphere	NA	Right hemiparesis, aphasia, seizure	NA	NA	NA
[21]	15 y	Bilateral occipital	NA	Coma, seizure	NA	NA	Died
[22]	11 mo	Extensive bilateral frontal and parietal	1	Generalized seizure	Yes	NA	Severe impairment with decerebrate posturing and generalized rigidity

ACA, anterior cerebral artery; MCA, middle cerebral artery; NA, information not available.

role of a prothrombotic state to the development of microangiopathic disease and provide a plausible explanation for development of other thrombotic complications. The early onset of thrombosis in our patient and the observation of elevated procoagulant factors early in the disease course, even before clinical manifestations, suggest that the thrombotic event in our patient may be related to disease-specific alterations in the hemostatic system as opposed to other factors unrelated to HUS, such as prolonged immobility, hospitalization, or underlying thrombophilia.⁹ Furthermore, chronic kidney disease is associated with thromboembolic risk, which is postulated to be secondary to elevated factor VIII levels.¹⁰ Although factor VIII levels were not assessed, our patient's partial thromboplastin time was shortened, and it is plausible that a similar mechanism could have contributed to our patient's prothrombotic state.

In the context of Virchow's triad—venous stasis, vascular injury, and hypercoagulability—and the absence of other known risk factors, we hypothesize that a state of relative dehydration, along with Shiga toxin-associated endothelial damage and upregulation of prothrombotic factors created a nidus for thrombosis in our patient. However, establishing a direct causal link between HUS and the patient's CSVT is challenging, since laboratory testing will not reflect the contribution of endothelial damage to thrombosis. In this case, an extensive thrombophilia workup revealed no evidence of congenital or acquired thrombophilia. While a state of relative dehydration may lead to increased blood viscosity and heighten the risk for thrombosis in patients with HUS, the thrombotic risk associated with dehydration must be weighed against the risk of fluid overload in oliguric and anuric patients and the possibility of exacerbating electrolyte imbalance, such as hyponatremia. In retrospectively reviewing this case, it was difficult to confidently assess whether the patient was dehydrated (due to her diarrhea) or fluid overloaded (due to renal failure) at the time of her seizure.

We performed a review of the literature and identified a number of pediatric cases of nonhemorrhagic stroke, usually arterial in etiology, in patients with the classic diarrheal form of HUS (Table 2). The 16 other cases we reviewed revealed that stroke can be a presenting symptom of HUS or can present over 1 week after initial hospitalization. Patients generally presented with seizure, focal neurologic findings, or altered mental status. Strokes occurred in a variety of locations with no clear anatomic predilection. Strokes in major arterial vessel distributions were reported, in addition to lacunar strokes involving smaller arteries. Many patients developed multifocal infarctions, indicating widespread microangiopathy. Outcomes ranged from complete neurologic recovery to death.

Although rare, clinicians should keep cerebral thrombotic events in the differential diagnosis of patients with diarrhea-associated HUS with neurologic symptoms, even when such patients have severe electrolyte disturbances. The role of anticoagulation in the up-front management of patients with HUS who experience thrombotic complications and have active disease with ongoing vascular inflammation, renal compromise, and rapidly declining platelet counts presents a challenge for the practicing hematologist. In our patient, we were able to initiate therapeutic anticoagulation upon

stabilization of renal function and platelet counts. Although persistent dilation of cerebral venous vasculature developed as a sequela of her CSVT, fortunately, she has not developed any long-term gross neurologic complications to date. Optimal timing of initiation of anticoagulation in the setting of active HUS is unclear. Our case demonstrates that resolution of CSVT associated with HUS can occur, even when initiation of anticoagulation is delayed until the patient has been hemostatically stabilized. A multidisciplinary team approach is crucial for management of anticoagulation of CSVT in HUS with ongoing thrombocytopenia and requiring hemodialysis to ensure optimal neurologic, neurovascular, and renal outcomes. Although most children with CSVT do not develop long-term gross cognitive deficits, some children may develop deficits that can be detected using standardized assessments. Patients with sinovenous thrombosis may benefit from formal neuropsychiatric testing to detect subtle neurologic deficits and intervene early.¹¹⁻¹⁴

4 | CONCLUSION

CSVT is a rare neurologic sequela of HUS and should be considered in the differential diagnosis of patients who develop neurologic symptoms with or without accompanying electrolyte derangements. Initial management of anticoagulation is challenging and must be individualized based on the degree of thrombocytopenia, renal function, and the need for upcoming procedures. A multidisciplinary approach with hematology, nephrology, radiology, and neurology is critical.

RELATIONSHIP DISCLOSURE

The authors report nothing to disclose.

ORCID

Deepti M. Warad  <https://orcid.org/0000-0002-1899-5208>

TWITTER

Deepti M. Warad  @deepti_warad

REFERENCES

1. Zoja C, Buelli S, Morigi M. Shiga toxin triggers endothelial and podocyte injury: the role of complement activation. *Pediatr Nephrol*. 2019;34(3):379-88.
2. Jeong YK, Kim IO, Kim WS, Hwang YS, Choi Y, Yeon KM. Hemolytic uremic syndrome: MR findings of CNS complications. *Pediatr Radiol*. 1994;24(8):585-6.
3. Sherwood JW, Wagle WA. Hemolytic uremic syndrome: MR findings of CNS complications. *AJNR Am J Neuroradiol*. 1991;12(4):703-4.
4. deVeber G, Andrew M, Adams C, Bjornson B, Booth F, Buckley DJ, et al. Cerebral sinovenous thrombosis in children. *N Engl J Med*. 2001;345(6):417-23.
5. Heller C, Heinecke A, Junker R, Knofler R, Kosch A, Kurnik K, et al. Cerebral venous thrombosis in children: a multifactorial origin. *Circulation*. 2003;108(11):1362-7.
6. Bale JF Jr, Brasher C, Siegler RL. CNS manifestations of the hemolytic-uremic syndrome. Relationship to metabolic alterations and prognosis. *Am J Dis Child*. 1980;134(9):869-72.

7. Exeni RA, Fernandez-Brando RJ, Santiago AP, Fiorentino GA, Exeni AM, Ramos MV, et al. Pathogenic role of inflammatory response during Shiga toxin-associated hemolytic uremic syndrome (HUS). *Pediatr Nephrol*. 2018;33(11):2057-71.
8. Nolasco LH, Turner NA, Bernardo A, Tao Z, Cleary TG, Dong JF, et al. Hemolytic uremic syndrome-associated Shiga toxins promote endothelial-cell secretion and impair ADAMTS13 cleavage of unusually large von Willebrand factor multimers. *Blood*. 2005;106(13):4199-209.
9. Chandler WL, Jelacic S, Boster DR, Ciol MA, Williams GD, Watkins SL, et al. Prothrombotic coagulation abnormalities preceding the hemolytic-uremic syndrome. *N Engl J Med*. 2002;346(1):23-32.
10. Cheung KL, Bouchard BA, Cushman M. Venous thromboembolism, factor VIII and chronic kidney disease. *Thromb Res*. 2018;170:10-9.
11. Grunt S, Wingeier K, Wehrli E, Boltshauser E, Capone A, Fluss J, et al. Cerebral sinus venous thrombosis in Swiss children. *Dev Med Child Neurol*. 2010;52(12):1145-50.
12. Moharir MD, Shroff M, Stephens D, Pontigon AM, Chan A, MacGregor D, et al. Anticoagulants in pediatric cerebral sinovenous thrombosis: a safety and outcome study. *Ann Neurol*. 2010;67(5):590-9.
13. Hetherington R, Tuff L, Anderson P, Miles B, deVeber G. Short-term intellectual outcome after arterial ischemic stroke and sinovenous thrombosis in childhood and infancy. *J Child Neurol*. 2005;20(7):553-9.
14. De Schryver EL, Blom I, Braun KP, Kappelle LJ, Rinkel GJ, Peters AC, et al. Long-term prognosis of cerebral venous sinus thrombosis in childhood. *Dev Med Child Neurol*. 2004;46(8):514-9.
15. Nakahata T, Tanaka H, Tateyama T, Ueda T, Suzuki K, Osari S, et al. Thrombotic stroke in a child with diarrhea-associated hemolytic-uremic syndrome with a good recovery. *Tohoku J Exp Med*. 2001;193(1):73-7.
16. Steinberg A, Ish-Horowitz M, el-Peleg O, Mor J, Branski D. Stroke in a patient with hemolytic-uremic syndrome with a good outcome. *Brain Dev*. 1986;8(1):70-2.
17. Trevathan E, Dooling EC. Large thrombotic strokes in hemolytic-uremic syndrome. *J Pediatr*. 1987;111(6 Pt 1):863-6.
18. Keenswijk W, Dhont E, Raes A, Bael A, Vande Walle J. A devastating case of diarrhea-associated hemolytic uremic syndrome associated with extensive cerebral infarction; why we need to do better. *Acta Clin Belg*. 2018;73(2):151-5.
19. DiMario FJ Jr, Bronte-Stewart H, Sherbotie J, Turner ME. Lacunar infarction of the basal ganglia as a complication of hemolytic-uremic syndrome. MRI and clinical correlations. *Clin Pediatr (Phila)*. 1987;26(11):586-90.
20. Rasoulpour M, Leichtner A, San Jorge M, Hyams J. Cerebral vascular accident during the recovery phase of hemolytic uremic syndrome. *Int J Pediatr Nephrol*. 1985;6(4):287-8.
21. Hahn JS, Havens PL, Higgins JJ, O'Rourke PP, Estroff JA, Strand R. Neurological complications of hemolytic-uremic syndrome. *J Child Neurol*. 1989;4(2):108-13.
22. Mendelsohn DB, Hertzanu Y, Chaitowitz B, Cartwright JD. Cranial CT in the haemolytic uraemic syndrome. *J Neurol Neurosurg Psychiatry*. 1984;47(8):876-8.

How to cite this article: Wyatt KD, Rodriguez V, Youssef PE, Eckel LJ, Warad DM. Cerebral sinovenous thrombosis in pediatric hemolytic uremic syndrome. *Res Pract Thromb Haemost*. 2020;4:659-665. <https://doi.org/10.1002/rth2.12329>