

Diagnosis and management of cold urticaria in cryoablation of atrial fibrillation: a case report

Friederike Cordes ^{1*}, Christian Ellermann ², Jan Ehrchen ³,
Hansjoerg Ullerich¹, and Lars Eckardt²

¹Department of Medicine B, Gastroenterology and Hepatology, University Hospital Münster, Albert-Schweitzer-Campus 1, Gebäude A1, D-48149 Münster, Germany;

²Department of Cardiology II—Electrophysiology, University Hospital Münster, Albert-Schweitzer-Campus 1, Gebäude A1, D-48149 Münster, Germany; and ³Department of Dermatology, University Hospital Münster, Von-Esmarch-Strasse 58, D-48149 Münster, Germany

Received 10 June 2019; first decision 20 August 2019; accepted 19 November 2019; online publish-ahead-of-print 16 December 2019

Background

Cold-induced urticaria is triggered by exposure to local or environmental cold and manifests as localized or systemic pruritic papules, sometimes accompanied by angio-oedema and anaphylaxis representing a life-threatening condition. Therapy options of atrial fibrillation (AF) include catheter ablation with different energy sources, of which cryoenergy may be superior to other energy sources regarding safety and efficacy.

Case summary

We report the case of a 60-year-old man suffering from symptomatic paroxysmal AF. The patient had a history of cold-induced urticaria without occurrence of systemic reactions to date. After successful pulmonary vein isolation (PVI) using cryoenergy, post-interventional oesophagogastroduodenoscopy and endosonography revealed newly occurred oedema in the middle oesophagus with inclusion of all oesophageal wall layers. Due to missing peri-atrial lesions, activation of cold urticaria during cryoablation rather than procedure-associated alterations was diagnosed. The patient reported no systemic or gastrointestinal symptoms after PVI.

Discussion

We could demonstrate that cold urticaria can manifest as oesophageal angio-oedema in AF patients undergoing cryoablation. Therefore, these patients should be carefully considered for an alternative energy source for PVI or premedication with antihistamines when using cryoenergy.

Keywords

Case report • Cold urticaria • Cryoablation • Pulmonary vein isolation

Learning points

- Cold urticaria can manifest as oesophageal angio-oedema with oesophageal wall thickening and peri-oesophageal tissue oedema in atrial fibrillation patients undergoing cryoablation.
- Patients with cold urticaria should be carefully considered for an alternative energy source for pulmonary vein isolation or premedication with antihistamines when using cryoenergy.

Introduction

Cold-induced urticaria is a subtype of physical urticaria, which represents a rare disease with an incidence of 0.5% in Central Europe and higher incidence in regions with a colder climate.¹ Cold urticaria is triggered by exposure to local or environmental cold and manifests as localized or systemic pruritic papules, sometimes accompanied by angio-oedema and anaphylaxis representing a life-threatening condition. Lesions result from activation of skin mast cells, but the

* Corresponding author. Tel: +49 251 83 44881, Fax: +49 251 83 58104, Email: annafriederike.cordes@ukmuenster.de

Handling Editor: Habib Khan

Peer-reviewers: Philipp Sommer and Debrabrata Bera

Compliance Editor: Max Sayers

Supplementary Material Editor: Peregrine Green

© The Author(s) 2019. Published by Oxford University Press on behalf of the European Society of Cardiology.

This is an Open Access article distributed under the terms of the Creative Commons Attribution Non-Commercial License (<http://creativecommons.org/licenses/by-nc/4.0/>), which permits non-commercial re-use, distribution, and reproduction in any medium, provided the original work is properly cited. For commercial re-use, please contact journals.permissions@oup.com

underlying pathomechanism of mast cell activation due to physical stimuli is incompletely understood.² Triggering factors include exposure to cold objects, cold liquids, and cold air.³ Symptoms usually occur minutes after exposure but development of symptoms 24–48 h later is also described for delayed-type cold urticaria.² Wheals and angio-oedema are normally limited to areas exposed to cold triggers but extensive cold contact or contact to very low temperatures can induce a systemic reaction. Furthermore, contact of blood with hypothermia can be associated with systemic reactions like hypotension, laryngeal oedema, and cardiovascular failure.^{4–6}

Atrial fibrillation (AF) is the most common arrhythmia with a lifetime risk of 1:3.⁷ Atrial fibrillation is a major cause of morbidity and mortality and is associated with increasing risks of death, heart failure, and stroke.⁸ Besides medical treatment including control of heart rate and anticoagulation, definitive therapy includes catheter ablation with different energy sources, such as radiofrequency or cryoenergy, which has evolved to a curative treatment of AF in recent years.⁹ Recently, it has been demonstrated, that cryoablation for pulmonary vein isolation (PVI) is at least as effective and potentially even superior to radiofrequency ablation in regards to safety and efficacy in the treatment of AF.^{10,11}

We present the case of a 60-year-old man with therapy refractory AF and coincident cold urticaria who underwent cryoablation PVI.

Timeline

| Interventions and diagnostic findings | |
|---------------------------------------|--|
| Day 1 | Pre-interventional oesophagogastroduodenoscopy (OGD) and endoscopic ultrasound (EUS) without detection of oesophageal and peri-oesophageal pathologies |
| Day 1 | Pulmonary vein isolation using cryoenergy |
| Day 2 | Post-interventional OGD and EUS with detection of newly occurred oesophageal and peri-oesophageal mediastinal oedemas |
| Day 31 | Control OGD and EUS with complete remission of oesophageal and peri-oesophageal lesions |

Case presentation

A 60-year-old man presented to our institution with paroxysmal AF that was highly symptomatic and refractory to antiarrhythmic medication. The patient had a history of cold-induced urticaria (Figure 1) without occurrence of systemic reactions to date. The first onset of cold-induced urticaria occurred at the age of 40 years after contact with cold water and included localized wheals at the exposed areas. The wheals appeared minutes after exposure and resolved within hours. After first onset, the patient reported recurrent localized symptoms including wheals and angio-oedema at exposed areas after contact with cold water and cold air below 15°C. The patient reported no urticaria-associated hospitalization to date.

At physical examination, the patient presented in good physical condition. The blood pressure was 116/85 mmHg, basal oxygen saturation revealed 99%, and laboratory tests showed no pathologies. He reported no current gastrointestinal disorders or symptoms.

Oesophagogastroduodenoscopy (OGD) and endoscopic ultrasound (EUS) were performed directly prior and the day after PVI as part of the protocol for the MADE-PVI trial,¹² in which the patient was included. Pre-interventional OGD and EUS revealed no pathology of the oesophageal mucosa or the mediastinum. Pulmonary vein isolation was performed using Medtronic 2nd generation ArcticFront Cryoballoon guided by an Achieve mapping catheter. Pulmonary vein isolation was achieved in the left superior and inferior pulmonary veins employing a single freeze of 180 s per vein. Temperature was decreased during balloon cooling to -43°C and -42°C, respectively. Subsequent PVI of the right inferior pulmonary vein (RIPV) and the right superior pulmonary vein (RSPV) was performed. Balloon cooling was stopped in the RSPV after 124 s and in the RIPV after 149 s of cooling time due to low temperature of -60°C and -64°C, respectively. Pacing manoeuvres confirmed complete electrical isolation of both right pulmonary veins.

Post-interventional OGD, performed 18 h after PVI, revealed two longitudinal oedema with fissurated configuration in the middle oesophagus at 37–35 cm from the incisors (Figure 2A). Additional EUS demonstrated that each oesophageal oedema included all layers of the oesophageal wall and was accompanied by small mediastinal oedema, which was strictly restricted to peri-oesophageal tissue (Figure 2B). Hereby, the localization of the oedema correlated with the anatomical altitude of the posterior wall of the left atrium. No oedema could be detected in the pericardial tissue surrounding the pulmonary vein ostia. The patient reported no gastrointestinal or systemic symptoms after PVI. Aetiologically, due to missing peri-atrial lesions, activation of cold urticaria during cryoablation rather than direct procedure-associated complications was suspected.

Oesophagogastroduodenoscopy and EUS 4 weeks later revealed a complete remission of all lesions without evidence of residual oedema in the oesophagus or mediastinum. During 6 weeks, 3 and 6 month of follow-up, the patient reported neither gastrointestinal symptoms nor recurrence of AF.

Discussion

Here, we report the first case of oesophageal manifestation of cold-induced urticaria by cryoballoon ablation of AF. Cold urticaria represents a rare but potentially life-threatening condition, which ranges from mild localized symptoms like wheals and angio-oedema to severe systemic anaphylactic reactions and is triggered by contact to cold stimuli.^{4,5} Even though symptoms are usually limited to localized lesions, systemic reactions may occur in a subset of patients. Two studies, including children and adults, reported that nearly 30% of patients with diagnosed cold urticaria had a history of severe systemic reactions, hypotension, or respiratory compromise.^{1,13} Even though aquatic activity was the strongest risk factor for systemic reaction, 30% of the patients with systemic symptoms just had contact with a cold object in these two studies. Risk factors for systemic reactions include history of previous systemic response or history of oropharyngeal oedema, age less than 30 years at disease onset, high amount

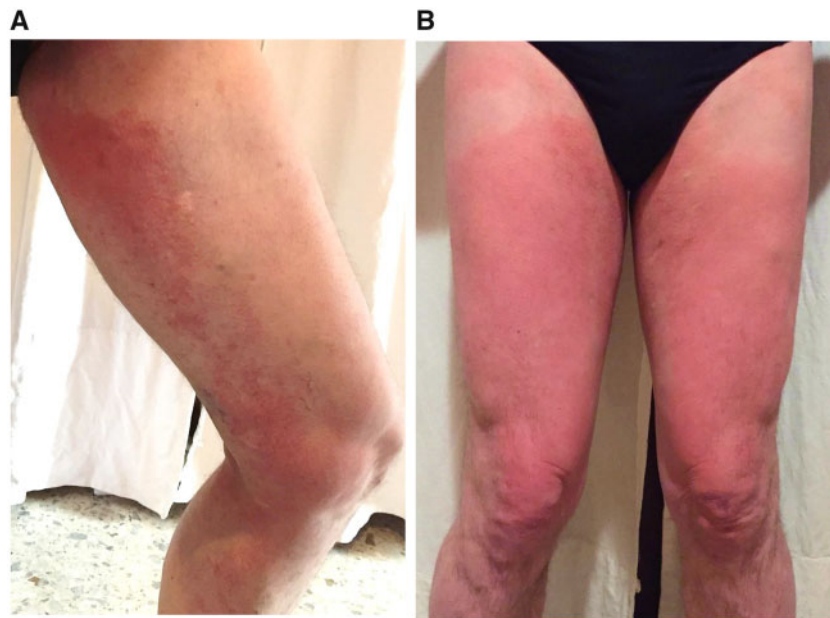


Figure 1 Previous manifestation of cold urticaria. Oedema and wheals developed immediately after contact to a cold trigger (A) and increased within the next hour (B).

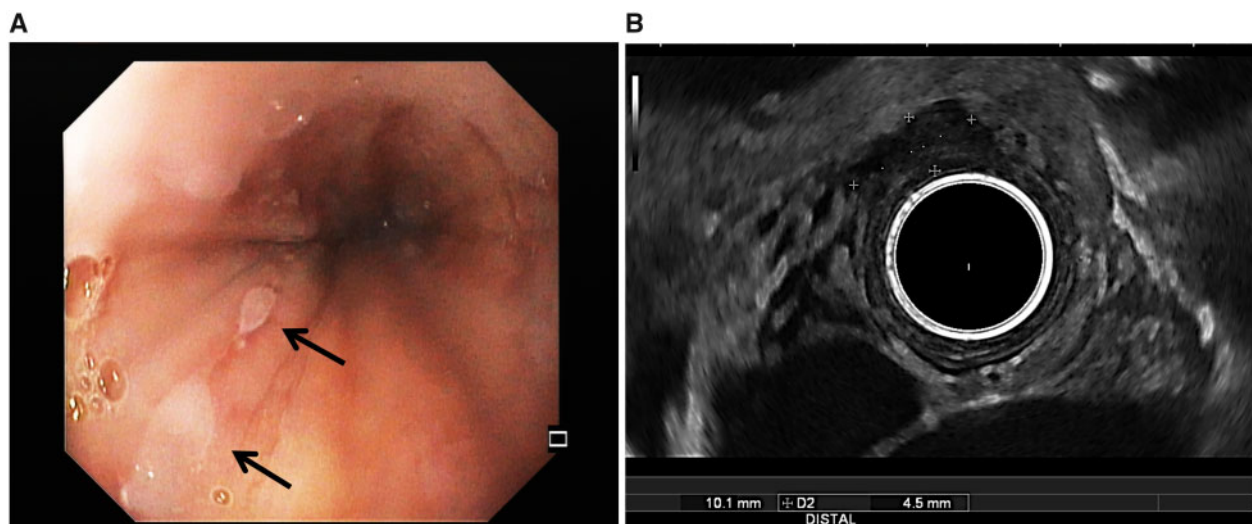


Figure 2 Manifestation of cold urticaria after cryoablation. Post-interventional oesophagogastroduodenoscopy revealed longitudinal oedemas (black arrows) with fissurated configuration in the middle oesophagus at 37–35 cm from the incisors (A). Additional endoscopic ultrasound demonstrated that each oesophageal oedema included all layers of the oesophageal wall and was accompanied by small mediastinal oedema, which was strictly restricted to peri-oesophageal tissue (B).

of surface exposed, exposure to cold temperatures, as well as long duration of exposure to cold stimuli.¹⁵

To our knowledge and according to a review of the literature, this is the first report of cold urticaria after cryoablation. The lesions distinctly differed from classical PVI-associated oesophageal lesions, which typically reveal signs of local thermal injury like erosions,

ulcerations, or necrosal lesions.¹² In this case, the detected lesions missed signs of thermal injury but revealed local angio-oedema of the oesophagus highly characteristic for physical urticaria-associated mucosal lesions. Besides, oesophageal wall thickening with reactive peri-oesophageal oedema, most probably due to the structural vicinity of the left atrium and the oesophagus was observed. Even though the

patient was diagnosed before with cold urticaria, symptoms were limited to local reactions without any history of systemic symptoms like anaphylaxis or generalized skin reaction. Prophylactic medication was not given in this case due to the lack of history of systemic involvement. Nevertheless, our observation of oesophageal angio-oedema in this case stresses the risk of disease activation in patients with cold urticaria by using cryoenergy possibly leading to an increased risk for PVI-associated complications. Ablation of AF targets the pulmonary veins by placing lesions around their ostia to isolate AF triggers from the left atrium. Collateral damage to adjacent structures has been described, in particular to the mediastinum and the oesophagus, caused by its vicinity to the posterior wall of the left atrium.¹⁴ Some studies, which have investigated mucosal changes of the oesophagus after AF ablation via oesophageal EUS, discovered structural changes of the mediastinum or the oesophagus in up to 27% of patients with radiofrequency energy.¹¹ In very rare cases (0.05%¹⁵), this may lead to formation of left atrial oesophageal fistulas with high mortality of up to 70%.¹⁶ These data may lead to the hypothesis of a possibly increased risk for patients with cold urticaria-associated oesophageal angio-oedema and associated oesophageal wall thickening to develop severe complications like oesophago-atrial fistulas. Furthermore, very cold temperatures used during cryoablation and blood contact with cold stimuli both increase the risk for systemic symptoms.^{4,5} Thus, our observations of activated cold urticaria by cryoablation support the consideration of prophylactic medication in patients with severe cold urticaria undergoing cryoablation, even with the lack of history of systemic reactions.


Primary preventive therapy comprises 2nd generation H1 antihistamines (e.g. cetirizine, loratadine, desloratadine, ebastine) as prophylactic therapy to reduce intensity or development of symptoms with less sedative side effects as compared to 1st generation antihistamines.¹⁷ Lancey et al.⁶ reported successful coronary bypass grafting including cold cardioplegia at 4°C in a patient with cold urticaria after receiving preoperative and postoperative prophylactic antihistamine therapy. Additionally, in patients with cold urticaria exposed to cold stimuli during surgery or interventions like cryoablation, the extent of symptoms and adequate prevention by antihistamines is not known and epinephrine should additionally be prepared as effective treatment for anaphylaxis.¹⁸

Further pharmacologic therapies with possible prophylactic effects include leukotriene receptor antagonists and biologics in a small series of cases. Systemic glucocorticoids have been shown to induce divergent responses. Prednisolone in an oral dose of 20–25 mg for 1–5 days was tested in a small series of six cases with acquired cold urticaria following cold challenge and was proven to completely or partially reduce pruritus, but did not decrease the incidence of erythema or oedema.¹⁹ Furthermore, Johnston et al.²⁰ described the case of a hypothermic cardiopulmonary bypass in a 47-year-old man with cold urticaria, in which prednisolone pre-treatment with 20 mg daily and preoperative hydrocortisone 100 mg could not prevent histamine release. In patients response to prednisolone therapy, improvement has been shown to be mostly only temporary.²¹ Thus, routine or preventive treatment of cold urticaria with glucocorticoids is not generally recommended.

Taken together, we have demonstrated in this case report that cold urticaria can manifest as oesophageal angio-oedema with

oesophageal wall thickening and peri-oesophageal tissue oedema in AF patients undergoing cryoablation. Since patients with cold urticaria may have a higher risk for developing systemic reaction, severe mediastino-oesophageal complications due to blood contact to very low temperatures and local angio-oedema in the vicinity of the cardio-circulatory system, these patients should be carefully considered for an alternative energy source for ablation or premedication with antihistamines when using cryoenergy.

Lead author biography



Dr Friederike Cordes graduated from the RWTH Aachen. She works in the University Hospital Münster and specialized in gastroenterology. Her interdisciplinary research interests focus on investigation of PVI-associated alterations of the upper gastrointestinal tract and the mediastinum.

Supplementary material

Supplementary material is available at *European Heart Journal - Case Reports* online.

Funding

The findings presented in this case report were detected during the MADE-PVI trial, which was supported by Medtronic by an unrestricted research grant (A 1351459).

Slide sets: A fully edited slide set detailing this case and suitable for local presentation is available online as [Supplementary data](#).

Consent: The author/s confirm that written consent for submission and publication of this case report including image(s) and associated text has been obtained from the patient in line with COPE guidance.

Conflict of interest: L.E. reported lecture honoraria from Medtronic. All other authors declared no conflict of interest related to this study.

References

1. Katsarou-Katsari A, Makris M, Lagogianni E, Gregoriou S, Theoharides T, Kalogeromitros D. Clinical features and natural history of acquired cold urticaria in a tertiary referral hospital: a 10-year prospective study. *J Eur Acad Dermatol Venereol* 2008;**22**:1405–1411.
2. Abajian M, Mlynek A, Maurer M. Physical urticaria. *Curr Allergy Asthma Rep* 2012; **12**:281–287.
3. Bentley B 2nd. Cold-induced urticaria and angioedema: diagnosis and management. *Am J Emerg Med* 1993;**11**:43–46.
4. Siebenhaar F, Weller K, Mlynek A, Magerl M, Altrichter S, Vieira dos Santos R, Maurer M, Zuberbier T. Acquired cold urticaria: clinical picture and update on diagnosis and treatment. *Clin Exp Dermatol* 2007;**32**:241–245.
5. Wanderer AA, Grandel KE, Wasserman SI, Farr RS. Clinical characteristics of cold-induced systemic reactions in acquired cold urticaria syndromes: recommendations for prevention of this complication and a proposal for a diagnostic classification of cold urticaria. *J Allergy Clin Immunol* 1986;**78**:417–423.

6. Lancey RA, Schaefer OP, McCormick MJ. Coronary artery bypass grafting and aortic valve replacement with cold cardioplegia in a patient with cold-induced urticaria. *Ann Allergy Asthma Immunol* 2004;**92**:273–275.
7. Lloyd-Jones DM, Wang TJ, Leip EP, Larson MG, Levy D, Vasan RS, D'Agostino RB, Massaro JM, Beiser A, Wolf PA, Benjamin EJ. Lifetime risk for development of atrial fibrillation: the Framingham Heart Study. *Circulation* 2004;**110**: 1042–1046.
8. Stewart S, Hart CL, Hole DJ, McMurray JJ. A population-based study of the long-term risks associated with atrial fibrillation: 20-year follow-up of the Renfrew/Paisley study. *Am J Med* 2002;**113**:359–364.
9. Fuster V, Rydén LE, Cannom DS, Crijns HJ, Curtis AB, Ellenbogen KA, Halperin JL, Kay GN, Le Huezey J-Y, Lowe JE, Olsson SB, Prystowsky EN, Tamargo JL, Wann LS. 2011 ACCF/AHA/HRS focused updates incorporated into the ACC/AHA/ESC 2006 Guidelines for the management of patients with atrial fibrillation: a report of the American College of Cardiology Foundation/American Heart Association Task Force on Practice Guidelines developed in partnership with the European Society of Cardiology and in collaboration with the European Heart Rhythm Association and the Heart Rhythm Society. *J Am Coll Cardiol* 2011;**57**: e101–e198.
10. Jiang J, Li J, Zhong G. Efficacy and safety of the second-generation cryoballoons versus radiofrequency ablation for the treatment of paroxysmal atrial fibrillation: a systematic review and meta-analysis. *J Interv Card Electrophysiol* 2017;**48**:69–79.
11. Zellerhoff S, Ullerich H, Lenze F, Meister T, Wasmer K, Mönning G, Köbe J, Milberg P, Bittner A, Domschke W, Breithardt G, Eckardt L. Damage to the esophagus after atrial fibrillation ablation: Just the tip of the iceberg? High prevalence of mediastinal changes diagnosed by endosonography. *Circ Arrhythm Electrophysiol* 2010;**3**:155–159.
12. Cordes F, Ellermann C, Decherer DG, Frommeyer G, Kochhäuser S, Lange PS, Pott C, Lenze F, Schmidt H, Ullerich H, Eckardt L. Time-to-isolation-guided cryoballoon ablation reduces oesophageal and mediastinal alterations detected by endoscopic ultrasound: results of the MADE-PVI trial. *Europace* 2019;**21**: 1325–1333.
13. Alangari AA, Twarog FJ, Shih MC, Schneider LC. Clinical features and anaphylaxis in children with cold urticaria. *Pediatrics* 2004;**113**:e313–e317.
14. Aupperle H, Doll N, Walther T, Kornherr P, Ullmann C, Schoon HA, Mohr FW. Ablation of atrial fibrillation and esophageal injury: effects of energy source and ablation technique. *J Thorac Cardiovasc Surg* 2005;**130**:1549–1554.
15. Barbhuiya CR, Kumar S, John RM, Tedrow UB, Koplan BA, Epstein LM, Stevenson WG, Michaud GF. Global survey of esophageal and gastric injury in atrial fibrillation ablation: incidence, time to presentation, and outcomes. *J Am Coll Cardiol* 2015;**65**:1377–1378.
16. Cappato R, Calkins H, Chen SA, Davies W, Iesaka Y, Kalman J, Kim YH, Klein G, Natale A, Packer D, Skanes A, Ambrogi F, Biganzoli E. Updated worldwide survey on the methods, efficacy, and safety of catheter ablation for human atrial fibrillation. *Circ Arrhythm Electrophysiol* 2010;**3**:32–38.
17. Siebenhaar F, Degener F, Zuberbier T, Martus P, Maurer M. High-dose desloratadine decreases wheal volume and improves cold provocation thresholds compared with standard-dose treatment in patients with acquired cold urticaria: a randomized, placebo-controlled, crossover study. *J Allergy Clin Immunol* 2009;**123**:672–679.
18. Bird JA, Burks W. Peanut allergy saves a patient with cold-induced hypotension and urticaria. *J Pediatr* 2010;**156**:687.
19. Black AK, Keahey TM, Eady RA, Greaves MW. Dissociation of histamine release and clinical improvement following treatment of acquired cold urticaria by prednisone. *Br J Clin Pharmacol* 1981;**12**:327–331.
20. Johnston WE, Moss J, Philbin DM, Guiney TE, Sisson JH, Buckley MJ, Lowenstein E. Management of cold urticaria during hypothermic cardiopulmonary bypass. *N Engl J Med* 1982;**306**:219–221.
21. Claudy A. Cold urticaria. *J Invest Dermatol Symp Proc* 2001;**6**:141–142.