

Diagnostic accuracy of dual energy CT in the assessment of traumatic bone marrow edema of lower limb and its correlation with MRI

Harsh Yadav, Sachin Khanduri, Poonam Yadav, Sushma Pandey, Vivek Kumar Yadav, Shahla Khan

Department of Radiodiagnosis, Era’s Lucknow Medical College and Hospital, Lucknow, Uttar Pradesh, India

Correspondence: Dr. Sachin Khanduri, Department of Radiodiagnosis, Era’s Lucknow Medical College, Sarfarazganj, Lucknow - 226 003, Uttar Pradesh, India. E-mail: drsachinrad@gmail.com

Abstract

Background: Bone marrow edema is assumed to be caused as a result of trabecular microfractures that are detected by MRI. As MRI is not widely available in countries like India, this study aims to encourage the use of DECT in detection of bone edema as evidence with comparable efficiency to MRI. **Aim:** To assess the diagnostic accuracy of dual-energy CT in detecting bone marrow edema in patients of trauma of lower limb and correlate it with MRI. **Setting and Design:** It is a cross-sectional study. **Materials and Methods:** The study included 40 patients of age 15–70 years irrespective of sex. All the patients of lower extremity trauma underwent DECT and MRI evaluation after clinical evaluation. All the images were postprocessed on a work station and were further evaluated by a radiologist. **Results:** Mean attenuation at fractured site observed by Dual energy CT was found to be significantly higher as compared to that at adjacent site (170.75 ± 33.99 vs. 19.73 ± 22.50 HU). The sensitivity and specificity of dual energy CT as compared to MRI in detecting bone marrow edema were 94.1% and 91.3%, respectively. Of the 40 cases enrolled in the study, agreement of MRI and Dual energy CT was observed in 37 (92.5%). **Conclusion:** Dual energy CT can be an effective alternative to MRI in the detection of bone marrow edema in patients of lower limb trauma. Dual energy CT can also be used in patients in whom MRI is contraindicated.

Key words: Bone marrow edema; DECT; lower limb; trauma

MeSH Terms: Bone marrow edema, lower limb trauma, MRI

Introduction

The terms “bone bruise,” “bone contusion,” or “bone marrow edema” are used synonymously but have important clinical issue among patients with traumatic injuries with recognition of its role as a significant pain generator.^[1,2] Bone marrow edema is assumed to be caused

as a result of trabecular microfractures. It is responsible for pain even in the absence of substantial soft-tissue injuries.^[3] Bone marrow edema remains undetected in radiographs. On MRI, marrow edema is seen as an area of signal loss

This is an open access journal, and articles are distributed under the terms of the Creative Commons Attribution-NonCommercial-ShareAlike 4.0 License, which allows others to remix, tweak, and build upon the work non-commercially, as long as appropriate credit is given and the new creations are licensed under the identical terms.

For reprints contact: reprints@medknow.com

Cite this article as: Yadav H, Khanduri S, Yadav P, Pandey S, Yadav VK, Khan S. Diagnostic accuracy of dual energy CT in the assessment of traumatic bone marrow edema of lower limb and its correlation with MRI. Indian J Radiol Imaging 2020;30:59-63.

Received: 07-Mar-2019

Revised: 16-Sep-2019

Accepted: 28-Jan-2020

Published: 30-Mar-2020

Access this article online	
Quick Response Code:	Website: www.ijri.org
	DOI: 10.4103/ijri.IJRI_59_19

on T1-weighted images involving the bone with increased signal intensity on T2 weighted and STIR images.^[4] Despite MRI being the most widely known technique for assessment of bone marrow edema, in conditions where MRI is contraindicated, bone marrow edema remained undetected and undiagnosed for years interfering with overall healing and rehabilitation of patient. Fortunately, DECT has emerged as a viable alternative in such situations as DECT makes attenuation measurements at tube voltages of 80 and 140 kV that can be subjected to three material decomposition, allowing for mathematic subtraction of substances with a relevant photograph-electric effect, such as iodine or calcium. The same technique is used to calculate a virtual noncalcium image from an unenhanced image, which would make bone marrow accessible for CT diagnosis.^[5]

Despite the promising role of DECT in the assessment of bone marrow edema, in general and traumatic bone edema in particular, there have been limited clinical studies evaluating its usefulness. Considering this gap, we planned our study to assess the diagnostic accuracy of DECT in detecting bone marrow edema in patients of trauma of lower limb and correlate it with MRI.

Materials and Methods

A cross-sectional study was conducted on 40 patients over a period of 18 months. Patients, irrespective of sex aged 18–70 years with lower extremity trauma and suspected fracture were included in the study. Pregnant females, patients with metallic implants were excluded from this study.

For all patients with lower extremity trauma, CT examinations were conducted using a dual-energy CT system (384 slice Somatom Force; Siemens Healthcare, Erlangen, Germany)

equipped with two X-ray tubes (tubes A and B with two different voltages, 80 and 140 kv). Acquisitions of the injured knee joint and ankle joint images were performed with a dual-energy protocol. The dual-energy CT examination parameters used were as follows: tube A: tube voltage of 80 kV, reference current time product of 250 mAs; tube B: Sn140 kV, where Sn indicates the use of an integrated tin filter; reference current time product of 150 mAs, 1280.6 mm collimation, 0.6 pitch, 0.5 seconds rotation time. Intravenous contrast material was not used in each patient.

All the images were postprocessed on a workstation using *Syngo Via* software that allowed analysis of images using three material decomposition. It acquires the attenuation measurements from two different kV settings and calculates a virtual noncalcium (VNCa) image, using the three-material decomposition method. To further improve the assessment

of the marrow space, a special filter technique, the Selective Photon Shield, is also applied. VNCa images were present in the form of color-coded images (bone marrow setting in *Syngo Dual Energy*). Axial, sagittal, and coronal multiplanar color-coded reformations were all created for further assessment and analysis.

The information was color-coded with a color lookup table which codes bone marrow and edema in shades of green-yellow to orange-red (parallelly to the progressive increase of density); 3D volume rendering maps coding bone marrow edema in shades of green and normal bone in blue were used.

After initial CT, MRI of the affected part was performed. The examinations were performed with an MRI system (Hitachi, Aperto), 0.4 T using the dedicated coil for knee and ankle. The site was evaluated with T1-weighted (at TR = 600 ms, TE = 11 ms), PD/T2-weighted (at TR = 3000 ms, TE = 33 ms) images (FoV = 160 mm, matrix = 320 mm × 320 mm, thickness = 3 mm) and STIR images. All images were analyzed on a workstation using a software that allowed for three-dimensional reconstructions and measurements. Bone edema was identified as per the protocol described by Pache *et al.*^[5] Upon DECT Image analysis, dual-energy color-coded region were evaluated whether edema existed in the bone marrow or not. If edema existed in the bone marrow, it displayed in green or yellow on the dual energy color-coded images; then the circular regions of interest (ROIs) over each region on the dual-energy color-coded images and in the adjacent region. The ROIs were placed at the location of highest edema intensity, which was green or yellow on the color-coded images, to obtain attenuation values. MRI findings were considered as final. On analysis of the MRI images, the diagnosis of BME was based on signal intensity increase in the STIR and T2 images with a signal decay at T1-weighted imaging. All the observations were made by three observers. Final observation was made when there was agreement of two or more observers.

Results

In our study, 40 patients with lower limb trauma and suspected fracture were analyzed. In majority of the cases, we encountered trauma and fracture around knee joints and the time gap between injury and DECT ranged from 6 to 24 days.

In the present study, three patients (7.5%) had ankle injury while remaining 37 (92.5%) had knee injury as shown in Table 1. Incidentally, knee injuries were predominant.

In this study, mean attenuation at fractured site was observed as 170.75 ± 33.99 HU while the same at adjacent site was observed as 19.73 ± 22.50 HU as shown in Table 2.

The difference in attenuation at fractured site and adjacent site among the patients enrolled in the study was found to be 151.03 ± 35.03 , which was considered statistically significant. Subjective interpretation by DECT based on attenuation found bone marrow edema in 45.0% cases [Figures 1, 2A, 2B, 3A and 3B] while in rest of the cases no edema was found [55.0%; Table 3].

On MRI evaluation, bone marrow edema was found to be present in 42.5% cases only [Figures 2C And 3C] while in rest of the cases (57.5%) edema was not found [Table 4].

Both DECT and MRI indicated presence of edema in 16/17 cases whereas DECT indicated edema in 2 cases that were not indicated by MRI [Table 5].

Sensitivity, specificity, PPV, and NPV of DECT against MRI for detection of bone marrow edema was found to be 94.1%, 91.3%, 88.9%, and 95.5%, respectively. Diagnostic accuracy of DECT against MRI was found to be 92.5%. Among the 17 cases in which MRI indicated the presence of edema, the attenuation of DECT was higher (152.47 ± 33.16 HU); as compared to 23 cases where MRI indicated no edema [149.96 ± 37.03 HU; Table 6].

Difference in attenuation among cases where MRI indicated edema or no edema was not found to be statistically significant.

Discussion

Traumatic bone injuries are not just limited to bone fractures and soft tissue injuries, but they have an impact on bone

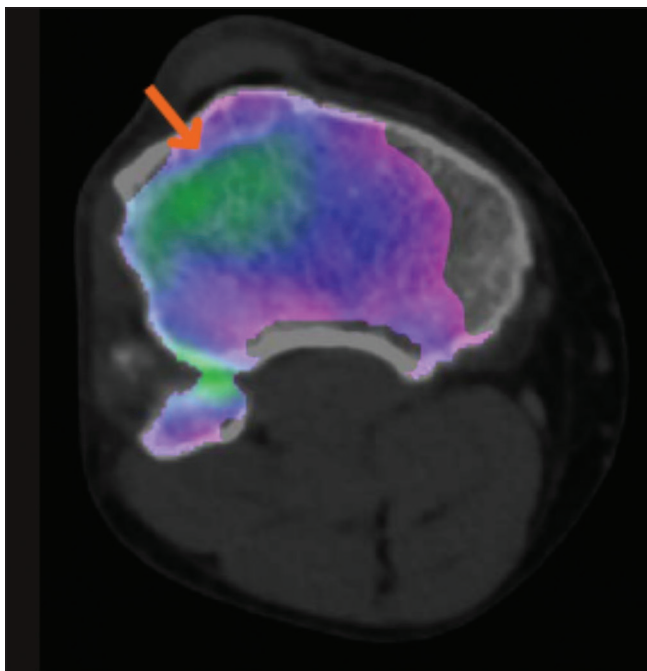


Figure 1: An axial DE VNCa image depicts bone marrow edema (arrow) on the lateral aspect of the upper right tibia

marrow too. The bone marrow edema pattern represents a “footprint” of the injury mechanism and improves diagnostic confidence in the detection of concomitant injuries.^[6]

In recent years, Dual Energy Computed Tomography has emerged as a promising alternative for assessment of posttraumatic bone marrow edema with encouraging accuracy.^[5,7-17] In this study, we used the dual-energy CT virtual noncalcium technique to assess bone marrow with MR imaging serving as a standard of reference. Because of the ability of DECT to subtract calcium from cancellous bone, it was able to depict bone marrow edema.

Table 1: Distribution of Study Population according to Affected Site

Site of fracture	Number of patients	Percentage
Ankle	3	7.5
Knee	37	92.5

Table 2: Comparison of DECT attenuation readings (HU) for Fractured and Adjacent site

Site	No. of cases	Min.	Max.	Median	Mean	S.D.
Fractured site	40	100	245	172.50	170.75	33.99
Adjacent site	40	-15	58	22.50	19.73	22.50
Difference	40	81	220	150.00	151.03	35.03

Fractured site vs Adjacent site $t=27.270$; $P<0.001$ (Paired t test)

Table 3: Distribution of Study Population according to DECT Subjective Interpretation

DECT Subjective Interpretation	Number of patients	Percentage
Edema	18	45.0
No edema	22	55.0

Table 4: Distribution of Study Population according to MRI Findings

MRI Interpretation	Number of patients	Percentage
Edema	17	42.5
No edema	23	57.5

Table 5: Diagnostic Accuracy of DECT as compared to MRI for detecting bone marrow edema in trauma case

DECT Finding	MRI Findings		Total
	Edema	No Edema	
Edema	16	2	18
No Edema	1	21	22
Total	17	23	40

$k=0.848$; $P<0.001$ (Substantial agreement)

Table 6: Association of difference in DECT attenuation (HU) findings and MRI Interpretation

MRI Interpretation	Number of patients	Mean difference	SD
Edema	17	152.47	33.16
No edema	23	149.96	37.03

$t=0.222$; $P=0.826$ (NS)

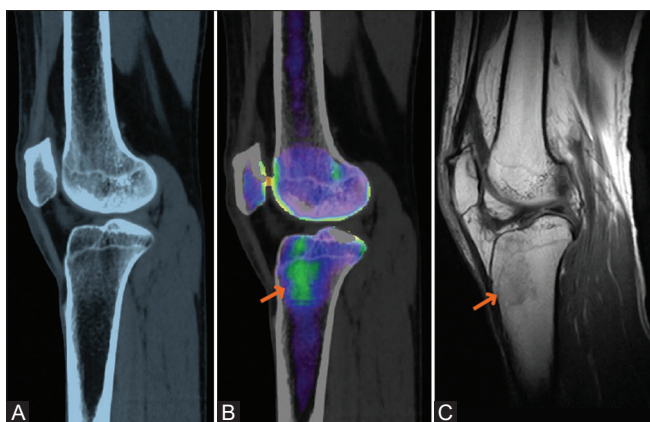


Figure 2 (A-C): (A) Sagittal views of a CT image of the right knee joint of a patient with bone marrow edema on the lateral aspect of the proximal tibia. (B) Sagittal views of a DE VNCa image of the right knee joint show bone marrow edema (arrows) on the lateral aspect of the proximal tibia. (C) Sagittal views of a T1-weighted MR [C] image of the right knee joint show bone marrow edema (arrows) on the lateral aspect of the proximal tibia

In present study, a significant difference in mean HU units was observed between fracture site and adjacent site, thus reflecting a possibility of bone marrow edema. Similar to findings of present study, Ai *et al.*^[10] a significant difference of ~55.8 HU was seen in CT numbers (HU) with higher CT numbers at fracture site compared to adjacent normal tissue. In their study, they also compared the fracture site with contralateral side and found a significant difference between two sites. In the present study, though we did not include the contralateral side and found that the differences between fracture site and adjacent normal tissues reflected the possibility of bone marrow edema. Wang *et al.*^[9], in line with our study, found a significant difference in the mean CT number of the affected site and adjacent normal tissue. Similar observations were reported by Pache *et al.*^[5] in their pioneering study too.

In the present study, out of 40 patients, 18 (45%) were found to have bone marrow edema by DECT whereas bone marrow edema was detected in 17 (42.5%) cases by MRI. The findings suggested that DECT had a higher positivity rate as compared to MRI. Similar to the findings of present study, Guggenberger *et al.* also reported a higher positivity rate for DECT (23.3% and 24.3% for observer 1 and observer 2) as compared to MRI (17.8%). However, Seo *et al.*^[8] in their study reported a lower positivity rate for DECT (15.9% and 20.6% for observer 1 and observer 2) as compared to MRI (22.3%). Ali *et al.*^[17] while evaluating traumatic acute wrist fracture bone marrow edema reported the positivity rate for DECT to be 16.1% as compared to 15.6% for MRI. In the present study, we had included both knee and ankle fractures.

As far as diagnostic efficacy of DECT against MRI was concerned, the present study found DECT to be 94.1% sensitive and 91.3% specific. They reported a positive

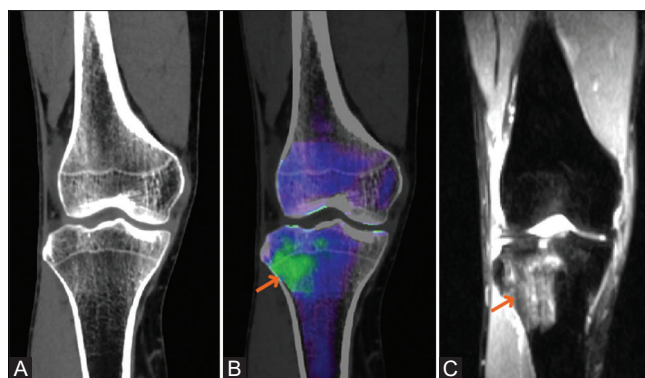


Figure 3 (A-C): (A) Coronal views of a CT image of the right knee joint of a patient with bone marrow edema on the lateral aspect of the proximal tibia. (B) Coronal views of a DE VNCa image of the right knee joint show bone marrow edema (arrows) on the lateral aspect of the proximal tibia. (C) Coronal views of a STIR MR image of the right knee joint show bone marrow edema (arrows) on the lateral aspect of the proximal tibia

predictive and negative predictive value of DECT as 88.9% and 95.5%, respectively. There was a substantial agreement between DECT and MRI ($\kappa = 0.848$). In their pioneering assessment, Pache *et al.*^[5] also reported >80% and >90% sensitivity and specificity of DECT in the detection of bone marrow edema. Guggenberger *et al.*^[7] in their study reported that the sensitivity and specificity of DECT were 90% and 80.5% by one observer and 90% and 81.6%, respectively, as compared to MRI. However, Seo *et al.*^[8] in their study reported that the sensitivity, specificity, positive predictive value, and negative predictive value of DECT for bone bruises were 65.4%, 98.2%, 91.4%, and 90.8%, respectively, for Reader 1 and 70.3%, 93.6%, 76.0%, and 91.7%, respectively, for Reader 2. In the present study, though we included three observers and took the observation made by two or more observers as the final observation, we achieved a more objective assessment which proved out to be more sensitive and specific. Karaca *et al.*^[13] upon using MRI as the reference standard, DECT had a sensitivity, specificity, positive-predictive value, and negative-predictive value and accuracy of 89.3, 98.7, 95.4, 96.9 and 96.6%, respectively, for assessment of bone marrow edema in vertebral fractures. The findings of the present study emulated them. Ai *et al.*^[10] reported even a higher sensitivity and specificity of DECT (100% sensitive and 99.5% specific) upon evaluating bone marrow edema in wrist fractures.

Conclusion

The present study showed that DECT is a useful method for evaluation of traumatic lower extremity fractures for the presence of bone marrow edema. The findings of the present study endorsed the findings of previous studies that have also shown that DECT can be used as an alternative to MRI for evaluation of traumatic injuries suspected from bone marrow edema. Addition of DECT as an alternative will help in providing an additional tool, where MRI facility is contraindicated and could reduce the long-term burden of

bone marrow edema. Further studies to validate the findings of the present study are recommended.

Financial support and sponsorship

Nil.

Conflicts of interest

There are no conflicts of interest.

References

1. Eustace S, Keogh C, Blake M, Ward RJ, Oder PD, Dimasi M. MR imaging of bone oedema: Mechanisms and interpretation. *Clin Radiol* 2001;56:4-12.
2. Hofmann S, Kramer J, Vakil-Adli A, Aigner N, Breitenseher M. Painful bone marrow edema of the knee: Differential diagnosis and therapeutic concepts. *OrthopClin N Am* 2004;35(3):321-33.
3. Boks SS, Vroegindeweyj D, Koes BW, Hunink MG, Bierma-Zeinstra SM. Follow-up of occult bone lesions detected at MR imaging: Systematic review. *Radiology* 2006;238:853-62.
4. Vincken PW, Ter Braak BP, van Erkel AR, Coerkamp EG, Mallens WM, Bloem JL. Clinical consequences of bone bruise around the knee. *Eur Radiol* 2006;16:97-107.
5. Pache G, Krauss B, Strohm P, Saueressig U, Blanke P, Bulla S, *et al.* Dual-energy CT virtual noncalcium technique: Detecting posttraumatic bone marrow lesions--feasibility study. *Radiology* 2010;256:617-24.
6. Sanders TG, Medynski MA, Feller JF, Lawhorn KW. Bone contusion patterns of the knee at MR imaging: Footprint of the mechanism of injury. *Radiographics* 2000;20:S135-51.
7. Guggenberger R, Gnannt R, Hodler J, Krauss B, Wanner GA, Csuka E, *et al.* Diagnostic performance of dual-energy CT for the detection of traumatic bone marrow lesions in the ankle: Comparison with MR imaging. *Radiology* 2012;264:164-73.
8. Seo SH, Sohn YJ, Lee CH, Park SH, Kim HW, Juhng SK. Dual-energy CT for detection of traumatic bone bruises in the knee joint. *J Korean Soc Radiol* 2013;69:487-94.
9. Wang CK, Tsai JM, Chuang MT, Wang MT, Huang KY, Lin RM. Bone marrow edema in vertebral compression fractures: Detection with dual-energy CT. *Radiology* 2013;269:525-33.
10. Ai S, Qu M, Glazebrook KN, Liu Y, Rhee PC, Leng S, *et al.* Use of dual-energy CT and virtual non-calcium techniques to evaluate post-traumatic bone bruises in knees in the subacute setting. *Skeletal Radiol* 2014;43, 1289-95.
11. Reddy T, McLaughlin PD, Mallinson PI, Reagan AC, Munk PL, Nicolaou S, *et al.* Detection of occult, undisplaced hip fractures with a dual-energy CT algorithm targeted to detection of bone marrow edema. *Emerg Radiol* 2015;22:25-9.
12. Kaup M, Wichmann JL, Scholtz JE, Beerers M, Kromen W, Albrecht MH, *et al.* Dual-energy CT-based display of bone marrow edema in osteoporotic vertebral compression fractures: Impact on diagnostic accuracy of radiologists with varying levels of experience in correlation to MR imaging. *Radiology* 2016;280:510-9.
13. Karaca L, Yuceler Z, Kantarci M, Çakır M, Sade R, Calıkoglu C, *et al.* The feasibility of dual-energy CT in differentiation of vertebral compression fractures. *Br J Radiol* 2016;89:20150300.
14. Dareez NM, Dahlslett KH, Engesland E, Lindland ES. Scaphoid fracture: Bone marrow edema detected with dual-energy CT virtual non-calcium images and confirmed with MRI. *Skeletal Radiol* 2017;46:1753-6.
15. Petritsch B, Kosmala A, Weng AM, Krauss B, Heidemeier A, Wagner R, *et al.* Vertebral compression fractures: Third-generation dual-energy CT for detection of bone marrow edema at visual and quantitative analyses. *Radiology* 2017;284:161-8.
16. Kellock TT, Nicolaou S, Kim SSY, Al-Busaidi S, Louis LJ, O'Connell TW, *et al.* Detection of bone marrow edema in nondisplaced hip fractures: Utility of a virtual unenhanced dual-energy CT application. *Radiology* 2017;284:798-805.
17. Ali IT, Wong WD, Liang T, Khosa F, Mian M, Jalal S, *et al.* Clinical utility of dual-energy CT analysis of bone marrow edema in acute wrist fractures. *Am J Roentgenol* 2018;210:842-7.