

Technique for Fixation of Semitendinosus to the Patella in Patellar Tendon Reconstruction



Ahmed Abdel-Aziz, M.Sc., M.D.,
Begad Hesham Mostafa Zaky Abdelrazek, M.Sc., M.D., F.R.C.S.,
Mohammed Refaat Waly, M.Sc., M.D., Mahmoud Ahmed Abdel-Aziz, M.Sc., M.D., and
Mohammed Mamdouh Salah El Din Sheriff, M.Sc.

Abstract: Chronic patellar tendon injuries are rare yet challenging to treat. Timing of surgery and graft choices are debatable. Many techniques and methods of fixation have been described with pros and cons. Functional impairment of the extensor mechanism and postoperative complications triggers the quest for finding the ideal technique. In this Technical Note, we use distally based semitendinosus (ST) looped over 2 ETHIBOND sutures. The ETHIBOND is passed through 2 vertical tunnels in the patella and retrieved proximally, docking the ST in a blind tunnel created in the lower pole of the patella. The whip-stitched free ST end is passed through a tunnel behind the tibial tubercle and sutured back to its base. A polyester tape is used to augment the repair in a circumferential manner. Postoperatively full weight bearing is allowed as tolerated in a hinged knee brace locked in extension with only passive range of motion of 0-90° allowed for 6 weeks.

Chronic patellar tendon injuries are not frequently seen in practice; however, they pose a great challenge to treatment. Direct primary repair is usually not feasible and reconstruction using tendon graft is almost always necessary. Some acute injuries are severe, with pathologic tendons and remnants not healthy for a direct primary repair.¹ There is no consensus in the literature on the duration since injury that defines a rupture as being chronic. However, the timing of surgery is very crucial, as we know from the literature that formation of adhesions, muscle contractures, and retraction of the extensor mechanism with proximal migration of the

patella increase over time from the time of injury and all add up to the complexity of these injuries and the difficulty faced by both the surgeon intraoperatively on one hand and the patient and the rehabilitation team postoperatively on the other.²⁻⁵

Postoperative complications include but are not limited to intraoperative fractures, limited range of motion (ROM), including flexion and/or extension, weak quadriceps and anterior giving way, wound dehiscence, and breakdown. Other less-serious problems include significant anterior knee pain, implant irritation, and donor-site morbidity.^{6,7} Many surgical techniques have been described using different types of grafts and different methods of fixation. Some authors have also described a 2-stage technique.⁸

From the Faculty of Medicine (A.A.A., B.H.M.A.Z., M.R.W.) and Faculty of Student Hospital (M.A.A.A.), Cairo University Kasr-Alainy; and El Sahel Teaching Hospital (M.M.S.E.D.S.), Cairo, Egypt.

The authors report that they have no conflicts of interest in the authorship and publication of this article. Full ICMJE author disclosure forms are available for this article online, as [supplementary material](#).

Received April 25, 2020; accepted August 28, 2020.

Address correspondence to Begad Hesham Mostafa Zaky Abdelrazek, M.Sc., M.D., F.R.C.S., Trauma and Orthopedics, Lecturer of Trauma and Orthopaedics Faculty of Medicine, Cairo University, Kasr-Alainy, Mathaf El-Manial St, Cairo, Egypt, 11553. E-mail: begad.hesham@kasralainy.edu.eg or begadhasham.abdelrazek@nhs.uk

© 2020 by the Arthroscopy Association of North America. Published by Elsevier. This is an open access article under the CC BY-NC-ND license (<http://creativecommons.org/licenses/by-nc-nd/4.0/>).

2212-6287/20782

<https://doi.org/10.1016/j.eats.2020.08.034>

Surgical Technique (With Video Illustration)

Informed consent was obtained from all patients. The procedure is performed under tourniquet control with the patient in the supine position under general or spinal anesthesia, and a selective nerve block is used in all cases for postoperative pain control. Examination under anesthesia is performed, and the ROM is documented.

Preoperative Planning

Plain radiographs of both knees, anteroposterior, lateral, and skyline views, are obtained. Magnetic

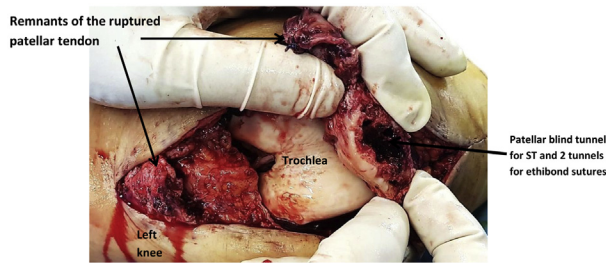


Fig 1. Shown is the defect in a left knee, the lower pole of the patella after preparation, and the tendon remnants. (ST, semitendinosus tendon.)

resonance imaging (MRI) of the injured knee is done confirming the injury and defining the exact site of rupture. Radiologic indices are plotted on the lateral radiographs of both knees to template for the injured knee using the sound side.

Intraoperatively

All procedures are done under a tourniquet with the patient in the supine position. A digital cuffed pneumatic tourniquet is used, which is inflated to 200 mm Hg above systolic blood pressure. A 10-cm long incision is then made, starting from above the proximal pole of the patella and extending distally to the tibial tubercle (TT). Then, subcutaneous dissection is continued in the same plane, exposing the patellar tendon with its proximal and distal attachments. The tear is identified; scar and fibrous tissue are removed from the site. The patella is then mobilized so that the lower pole can reach just above the joint line with the knee in some degree of flexion. To aid in that, the quadriceps is mobilized by subperiosteal dissection from the anterior femoral cortex.

A 3.5-mm drill bit is used to drill 2 vertical tunnels in the patella. With the help of a bone ronguer; a deep blind tunnel is created in the lower pole of the patella (Fig 1). The semitendinosus (ST) graft is harvested from the same incision using a closed tendon stripper (Concept 8750; ConMed Linvatec, Largo, FL) and is left distally-based (Fig 2A). The ST is cleaned of muscle and soft-tissue. It is then whip-stitched using VICRYL no. 2 or ETHIBOND no. 2 (both Ethicon, Somerville, NJ) (Fig 2B). It is then passed through a transverse tunnel behind the TT. Sometimes, it is docked first into the blind patellar tunnel then the free limb is passed in the tunnel behind the TT (Video 1).

Two ETHIBOND sutures are shuttled through the tunnels in the patella and are retrieved proximally (Fig 3). The ST is passed through the looped ETHIBOND ends and then folded back on itself (Fig 4A). The ETHIBOND sutures are then pulled proximally (Fig 4B), and this docks the ST into the trough in the lower pole of the patella (Fig 4C) (Video 1).

Polyester or FiberTape (Arthrex, Naples, FL) is used to augment the construct. It is passed through a transverse

tunnel in the TT (Fig 5A). It is then passed circumferentially around the patella. The tension is adjusted, monitoring the patellar height with the help of image intensifier and the ROM (Fig 5B). The polyester or FiberTape is then tightened and tied (Fig 5C). The knee is then brought to extension to check the stability of the construct, then the ETHIBOND is tightened (Fig 5D) (Video 1).

The ETHIBOND is tied proximally over a bone bridge and the free end of the ST is pulled to the correct tension and sutured to itself using ETHIBOND no. 2 (Fig 6). The remnants of the patellar tendon are sutured to the ST limbs and the final construct is seen in (Fig 7) (Video 1).

The field is then irrigated copiously. The paratenon is closed as a separate layer, followed by closure in layers and injection of local anesthetic in the wound.

Postoperatively

Postoperatively, full weight-bearing is allowed with a hinged knee brace locked in full extension for 6 weeks. Passive ROM 0-90° is allowed out of the brace. At 6 weeks, the brace is discarded indoors and used only when outdoors for 2 more weeks, and active assisted exercises are commenced for 6 weeks. The brace is completely discarded at 8 weeks and muscle strengthening begins at 3 months.

Discussion

Patellar tendon rupture is not uncommon; however, it is sometimes very challenging to treat. This is partly because of the complex anatomy of the extensor apparatus and partly because that despite the rising importance with attention and light being shed on the patellofemoral joint, a full understanding of the anatomy (with its variations) and the biomechanics of that peculiar joint is still lacking.⁹ The patellar height has shown variabilities related to sex, race, body habitus, and even with individuals of the same population and comparable demographics.¹⁰

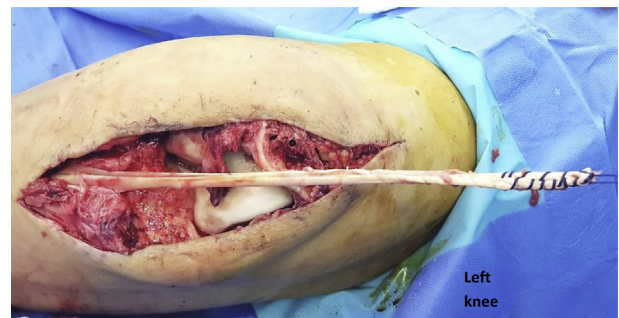


Fig 2. Shown is the harvested semitendinosus tendon in a left knee after being pulled into the main incision and the free end whip stitched.

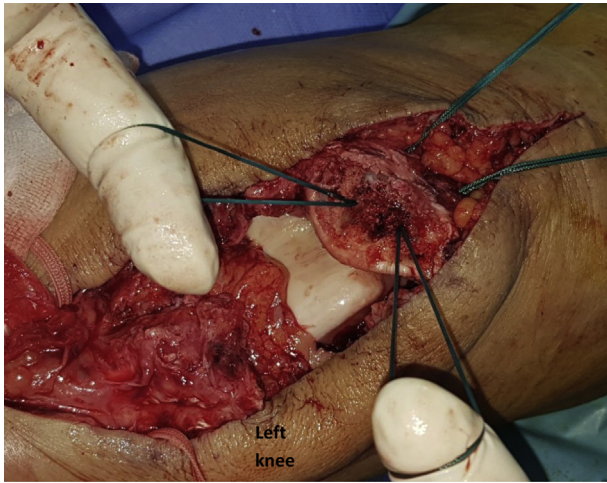


Fig 3. Looped ETHIBOND sutures are shuttled through the tunnels in the patella in a left knee and retrieved proximally, leaving behind 2 looped sutures.

Several well-known authors studied and defined patellar height in terms of indices interpreted from plain radiographs.¹¹⁻¹³ Others attempted to apply those indices to sagittal MRI scans and studied their reliability, reporting that a tendon length/patellar length of >1.50 is considered patella alta and <0.74 is baja.¹⁴ Patellar

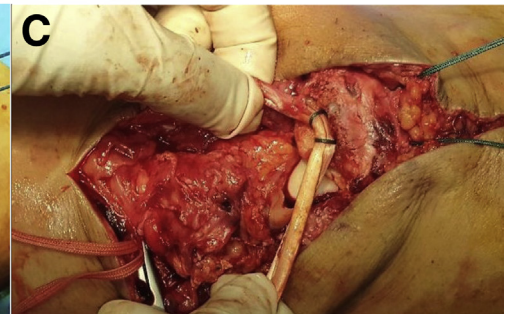
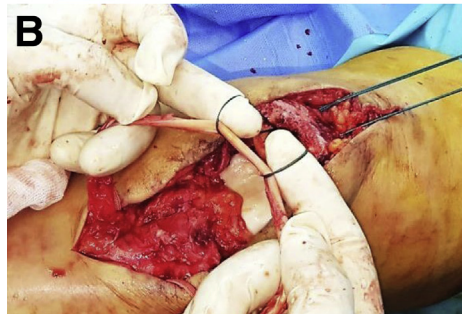
height is therefore like a fingerprint, and restoring it is crucial in achieving good functional outcomes; hence, it poses a great challenge.

Furthermore, time from injury to diagnosis and treatment is a very important factor, not only because it affects the complexity of the injury, but because it also impacts surgical options and outcomes. There is a lot of debate regarding what is the cutoff that defines acute versus chronic patellar tendon injuries.^{1,7} A high index of suspicion coupled with the use of the correct investigative tools, whether MRI or ultrasound coupled with plain radiographs, should establish the diagnosis early. However, many cases are either missed or neglected and are only discovered when they have become chronic. Many authors have different definitions regarding chronic injuries. Values from range from 4 weeks up to 3 months across the literature²; however, in this study we refer to chronic when the injury is ≥ 4 weeks old. Reconstruction of the patellar tendon and restoring extensor mechanism function is challenging, let alone the greater complexity created by chronicity. We also performed the technique in some acute cases, with very poor native remaining tissues where primary direct repair is not possible.

Surgeons treating this type injury aim to restore the function of the extensor mechanism, quadriceps

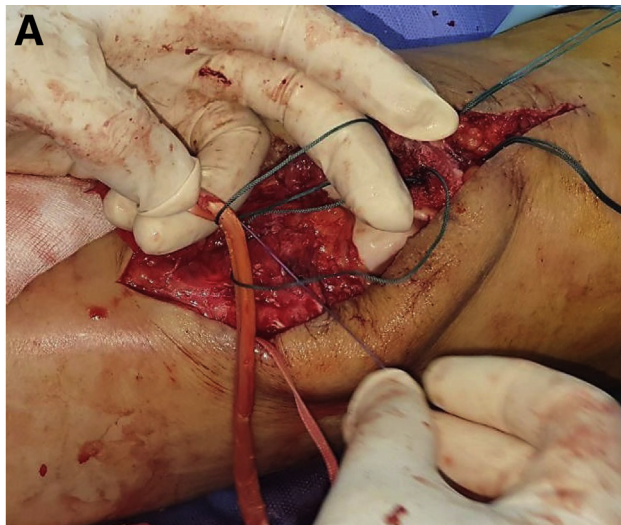

Fig 4. Left knee. (A) The ST looped around no. 2 ETHIBOND suture, (B) which are then pulled and (C) used to dock the graft in the trough at the lower pole of the patella. (ST, semitendinosus tendon.)



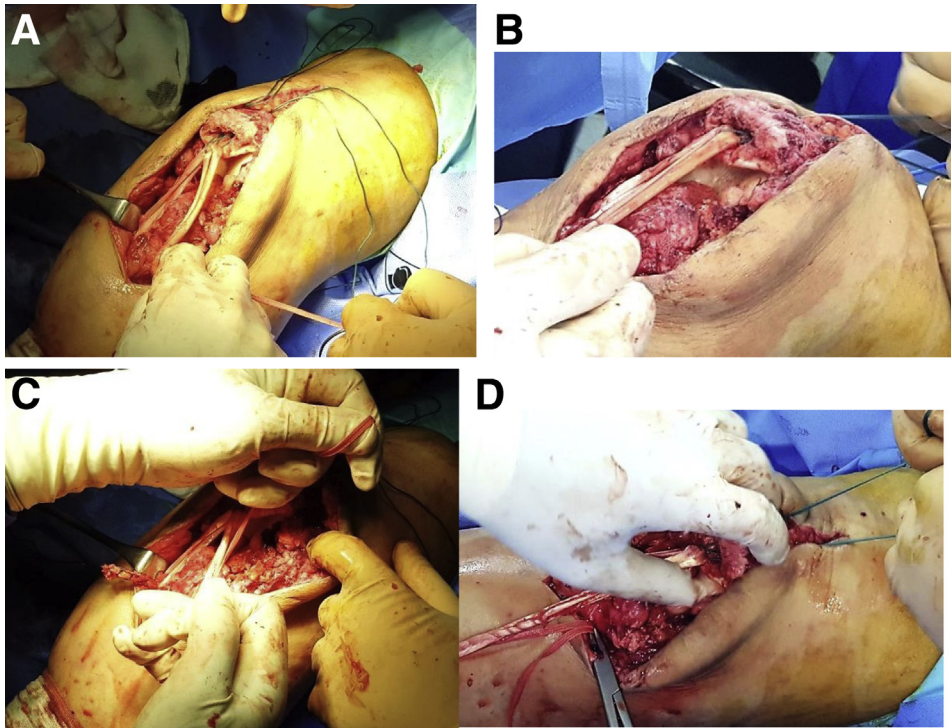


Fig 5. After shuttling of the ETHIBOND through the bone tunnels, polyester tape is used in a circumferential manner in a left knee to augment the construct. (A) Polyester tape passed through the tibial tubercle tunnel. (B) Adjusting patellar height in 30° flexion before tying the polyester tape. (C) Tying of the polyester tape in 30° flexion. (D) ETHIBOND sutures tightened after polyester tape was tied.

strength, and ROM of the knee.^{3,7} With that in mind, several surgical techniques have been described using various types of graft; hamstring, quadriceps autografts, allografts, and synthetic grafts. None of these graft types resemble the anatomy and mechanical properties of the native patellar tendon.^{2,15-17} Other authors have made use of contralateral patellar tendon.^{3,9}

The technique has the advantages of using an autograft and hence eliminates the risk of graft reaction,

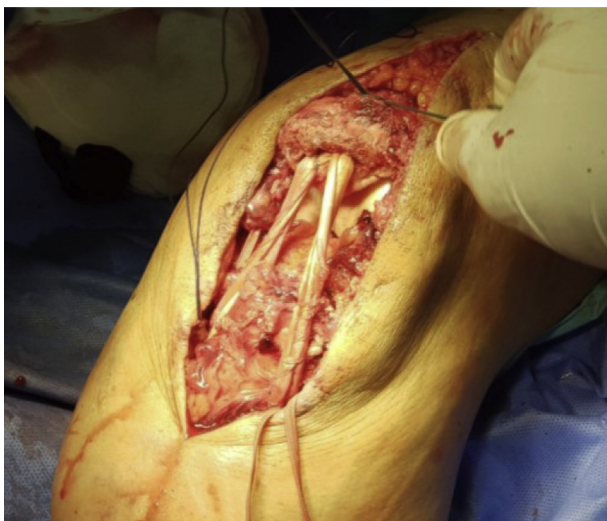

Fig 6. Tying the ETHIBOND sutures over bony bridge on the proximal pole of the patella in a left knee and the ST is passed through the tibial bone tunnel and tied over itself. (ST, semitendinosus tendon.)

rejection, and disease transmission. Hamstring tendons are widely harvested as graft material for anterior cruciate ligament reconstructions. It is economic, as no allograft is required, which is both expensive and scarce. It avoids harvesting graft from the contralateral limb. It avoids the complications and downside of the contralateral patella bone–tendon–bone graft, such as anterior knee pain, quadriceps weakness, and intraoperative fractures. The technique has its disadvantages, which include consuming the ST, which may be useful if the patient injures their anterior cruciate ligament and requires reconstruction. Using ST to reconstruct the patellar tendon is challenging to restore the patellar height. It is a non-anatomic reconstruction¹⁸ (Table 1).

Ecker et al.¹⁹ were the first to describe the use of hamstring tendon autograft in reconstruction of chronic patellar tendon injuries. In their technique, they drilled 2 patellar and 2 tibial tunnels in a horizontal fashion, i.e., separate tunnels for the ST and gracilis. We believe this poses a high risk of intraoperative patellar or tibial fractures. There is also the risk of breaching the patellar articular cartilage.

In their technique, Nguene-Nyemb et al.²⁰ used the ST only and passed it in a single 6-mm horizontal patellar tunnel. They created another patellar tunnel through which they passed sutures for additional fixation. They did not use a tibial tunnel and argue that it allows their technique to be used for skeletally immature subjects. They simply sutured the ST graft to the

Table 1. Advantages and Disadvantages of the Technique

Advantages	Disadvantages
Economic (no implants required)	Consumes ST, which may be needed in the future for ACL reconstruction.
Vertical blind tunnel carries less risk of patellar fracture	Difficult to adjust the patellar height, requires referencing from the contralateral limb with image intensifier guidance
Polyester tape used to augment the construct (less complications as compared to cerclage)	ST has different microanatomy as compared with the patellar tendon, hence different biomechanical properties.
Ipsilateral distally based graft (avoids harvesting from the sound knee).	Non-anatomic reconstruction
Autograft: economic, available not immunogenic and no risk of disease transmission	Ligament to bone healing
ST is familiar to harvest	Tunnels created in the patella carry risk of intraoperative fracture

ACL, anterior cruciate ligament; ST, semitendinosus.

remnants of the patellar tendon.²⁰ In our view, the remaining tissue may be insufficient to support this repair. Furthermore, the reconstruction is not anatomic and the tension on the limbs of the ST is not equal. We believe this may cause patellar overload and/or mal-tracking. In our technique, we drill smaller patellar tunnels (3.5 mm), which lessens the risk of fracture. We rely on 2 points of fixation on the tibial side, which better restores the anatomy and biomechanics of the patellar tendon and hence the extensor mechanism.

Another factor that could affect the outcome is the method of fixation. The extensor apparatus is subcutaneous, with risk of hardware prominence and metalwork irritation, which in turn is could be responsible for low functional outcomes and a great deal of patient dissatisfaction. Biomechanical studies have shown that during knee flexion the loads on the patellofemoral joint increase and are up to 3 times body weight during climbing stairs. Similarly, the loads applied to the quadriceps and patellar tendons are greater during knee flexion and exercise.²¹ This highlights the need for robust fixation. Postoperative immobilization allows adequate healing; however, if too long, it will adversely affect ROM. There is a trade-off between immobilization and robust fixation on one side and achieving good ROM and hardware prominence on the other.

This technique provides sound robust fixation with no metal hardware insertion. It relies on soft-tissue reconstruction fixed with sutures tied on a bony bridge. We trust the strength of the fixation and allow early ROM exercises. Hamstring tendons are kept distally attached; this has several benefits. It provides a secure natural strong anchor point. It saves the cost of using an implant and is considered biological, as it preserves the neurovascular supply of the tendons.²

In their series, Temponi et al.⁹ used cerclage wire to augment the construct. They reported one case of breakage and irritation by the wire. They also reported Tegner activity scores lower than preinjury levels despite of restoring patellar height. We believe this is the result of the use of cerclage wires. Polyester tape is gaining popularity and is increasingly being used by sports surgeons in repairing or reconstructing injured ligaments. We rely on it as a substitute to cerclage wires. It provides adequate strength yet avoids hardware irritation and carries less problems if it breaks. Polyester/fiber tape does not necessitate removal on the contrary to cerclage wires which need to be removed.²² This is different from what Kasten et al.²³ reported in their study; they only removed the cerclage if it was causing pain, irritation, or was broken. They compared the use of cerclage to polydioxanone suture in augmentation of patellar tendon repairs and found no

Table 2. Pearls and Pitfalls of the Technique

Pearls	Pitfalls
Harvest the ST from the same wound. Minimizes incisions, less risk of injury of infra-patellar branch of saphenous nerve.	Tunnel collision at the proximal pole of the patella, so there is no bony bridge to tie on. This may be avoided by making the tunnels slightly divergent.
Adjust the patellar height in 30° of flexion, then maintain this height with the help of polyester tape before final tightening of the ETHIBOND and suturing of the ST to itself.	Inadequate patellar height; alta/baja. Care should be taken while adjusting the height. An image intensifier should be used and the contralateral knee should be used for referencing.
Use all remaining patellar tissues to sutures to the final construct. This protects and augments the repair, provides vascularity and proprioception.	Harvesting of gracilis instead of ST.
	Premature rupture of the ST during harvest.

ST, semitendinosus.

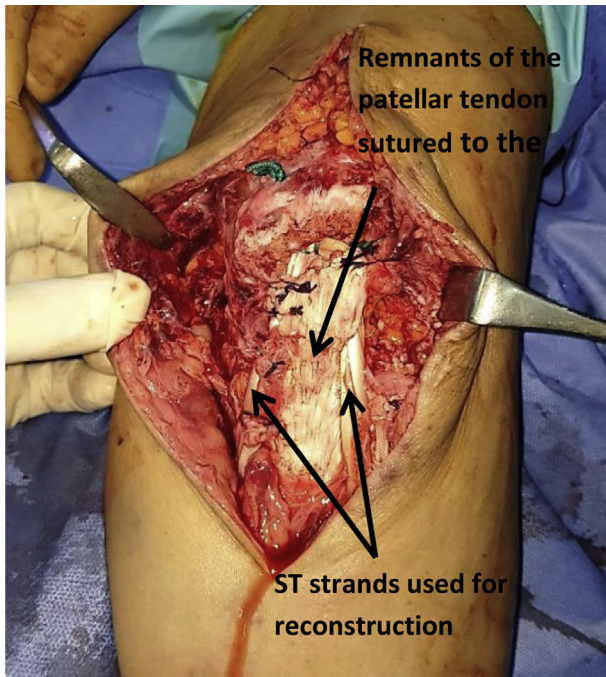


Fig 7. Final construct in a left knee after suturing the remnants of the patellar tendon to the semitendinosus limbs.

statistically significant difference between both groups. However, in the polydioxanone suture group there was a greater rate of postoperative infection. Tsitskaris et al.⁴ in their series used FiberWire to supplement the reconstruction. It allows a robust secure construct, yet does not require removal of metalwork and does not limit the degree of flexion as opposed to the use of cerclage wire described in other series.^{2,9}

The most difficult and challenging step faced is mobilizing the upward retracted high riding patella.⁴ Tsitskaris et al.⁴ advocate quadriceps tendon V-Y plasty and suggest that it must always be discussed with the patient and be added to the consent form. They, however, reported that it was not required in any of the patients in their series. We believe this is because their definition of chronic is ≥ 4 weeks, which is considered relatively fresh. We agree with them, and in our technique we are prepared to perform a quadriceps tendon lengthening V-Y advancement if required.

They also performed the procedure without a tourniquet; they believe that the tourniquet may tether the quadriceps and compromise successful mobilization of the patella.²⁵ This comes with an expense of a bloody operative field. We adopted a different approach where we use a tourniquet for a bloodless field and release the tourniquet on demand if we thought it was tethering the quadriceps.

Mandelbaum et al.²⁴ recommended Z lengthening of the quadriceps tendon and Z shortening of the patellar tendon. In their series; Nguene-Nyemb et al.²⁰ reported that they did not need to perform any release since they

did not encounter difficulties in mobilizing the patella. Dejour et al.³ suggest a sequential approach that involves resection of the patellar retinaculum, arthrolysis of the suprapatellar pouch. If this is insufficient, the upper part of the rectus femoris could be divided. A different technique was described by Jain et al.²⁵; they relied initially on arthroscopic arthrolysis of the suprapatellar pouch. When further mobilization of the patella was still required; pie-crusting of the quadriceps tendon was performed. This involved percutaneous stabs in the quad tendon.

Once mobilized, different authors described using different instruments to bring the patella downwards. Some use a Steinmann pin or cerclage wires through a transverse tunnel,^{2,19} and others use FiberWire passed transversely.⁴ We believe this is an additional tunnel that increases the risk of the patellar fracture. We relied on a pointed reduction towel applied on the medial and lateral borders of the patella for manipulation. However, most authors agreed to adjust the patellar height in 30° of flexion with help of an intraoperative image intensifier using the contralateral sound side as a reference. We adhered to that as well in our technique.

In all the techniques described,^{2-4,9,19,23} a large incision is made extending from the proximal pole of the patella to the TT. Extensive soft-tissue dissection coupled with bringing the patella downwards and in some series and using cerclage wires all may contribute to the limitation in the ROM and lower Tegner activity scores as compared with preinjury levels. Jain et al.²⁵ in their series performed percutaneous patellar tendon reconstruction using ST. They relied on scopic release and pie-crusting of the quad tendon to mobilize the patella. Their technique is less traumatic to the tissues and leads to more preservation of the soft tissues that envelop the extensor apparatus that are vital for blood supply and proprioception. This has led to better flexion and overall ROM in their patients as compared with other series.²⁷ They reported 80% return in quadriceps function²⁵ as compared with the series of Falconiero and Pallis,²⁶ who only achieved 60%.

To our knowledge, our study is the only one that describes harvesting of the ST through the main incision without making a separate one. We believe this lowers the risk of injury of the infrapatellar branch of saphenous and the subsequent postoperative numbness in its distribution. It involves less morbidity and avoids risk of a narrow skin island between both wounds which may slough and breakdown.

Only one author²⁷ raised the issue of operating with the patient under general anesthesia to allow better relaxation of the quadriceps muscles. Most other authors, however, used spinal anesthesia. We believe that the type of the anesthetic used should be greatly the choice of the anesthetist and the patient, mainly dependent on patient factors. Muscle relaxation could still be

achieved if spinal anesthesia is used. We added selective nerve block for adequate postoperative pain control. This allowed early passive ROM.

Conclusions

The technique described in this paper has advantages and disadvantages, which are outlined in Table 1. There are a number of pearls and pitfalls that are outlined in Table 2. It is a reliable, reproducible economic technique that provides robust secure fixation.

References

- Greis PE, Lahav A, Holmstrom MC. Surgical treatment options for patella tendon rupture, part II: Chronic. *Orthopedics* 2005;28:765-769.
- Chen B, Li R, Zhang S. Reconstruction and restoration of neglected ruptured patellar tendon using semitendinosus and gracilis tendons with preserved distal insertions: two case reports. *Knee* 2012;19:508-512.
- Dejour H, Denjean S, Neyret P. Treatment of old or recurrent ruptures of the patellar ligament by contralateral autograft. *Rev Chir Orthop Reparatrice Appar Mot* 1992;78:58-62 [in French].
- Tsitskaris K, Subramanian P, Crone D. Neglected patellar tendon rupture. Reconstruction using semitendinosus-gracilis tendon grafts and FiberWire augmentation. *JRSM Short Rep* 2013;4:2042533313490286.
- Shelbourne KD, Darmelio MP, Klootwyk TE. Patellar tendon rupture repair using Dall-Miles cable. *Am J Knee Surg* 2001;14:17-20.
- Mittal R, Singh DP, Kapoor A. Neglected patellar tendon rupture: Preserve the fat pad. *Orthopedics* 2011;34:134.
- Gilmore JH, Clayton-Smith ZJ, Aguilar M, Pneumaticos SG, Giannoudis PV. Reconstruction techniques and clinical results of patellar tendon ruptures: Evidence today. *Knee* 2015;22:148-155.
- Isiklar ZU, Varner KE, Lindsey RW, Bocell JR, Lintner DM. Late reconstruction of patellar ligament ruptures using Ilizarov external fixation. *Clin Orthop Rel Res* 1996;322:174-178.
- Temponi EF, Camelo N, Tuteja S, et al. Reconstruction of chronic patellar tendon rupture with contralateral bone-tendon-bone autograft. *Knee Surg Sports Traumatol Arthrosc* 2017;25:2468-2473.
- Bidmos MA, Steinberg N, Kuykendall KL. Patella measurements of South African whites as sex assessors. *Homo* 2005;56:69-74.
- Insall J, Salvati E. Patella position in the normal knee joint. *Radiology* 1971;101:101-104.
- Caton J, Deschamps G, Chambat P, Lerat JL, Dejour H. Les rotules basses: A propos de 128 observations. *Rev Chir Orthop Reparatrice Appar Mot* 1982;68:317-325 [in French].
- Blackburne JS, Peel TE. A new method of measuring patellar height. *J Bone Joint Surg Br* 1977;59:241-242.
- Dejour D, Ferrua P, Ntangiopoulos PG, et al. The introduction of a new MRI index to evaluate sagittal patellofemoral engagement. *Orthop Traumatol Surg Res* 2013;99:S391-S398.
- Takazawa Y, Ikeda H, Ishijima M, et al. Reconstruction of a ruptured patellar tendon using ipsilateral semitendinosus and gracilis tendons with preserved distal insertions: Two case reports. *BMC Res Notes* 2013;6:361.
- Sundararajan SR, Srikanth KP, Rajasekaran S. Neglected patellar tendon ruptures—a simple modified reconstruction using hamstrings tendon graft. *Int Orthop* 2013;37:2159-2164.
- Milankov MZ, Miljkovic N, Stankovic M. Reconstruction of chronic patellar tendon rupture with contralateral BTB autograft: A case report. *Knee Surg Sports Traumatol Arthrosc* 2007;15:1445-1448.
- Naim S, Gougoulias N, Griffiths D. Patellar tendon reconstruction using LARS ligament: surgical technique and case report. *Strateg Trauma Limb Reconstr* 2011;6:39-41.
- Ecker ML, Lotke PA, Glazer RM. Late reconstruction of the patellar tendon. *J Bone Joint Surg Am* 1979;61:884-886.
- Nguene-Nyemb AG, Hutten D, Ropars M. Chronic patellar tendon rupture reconstruction with a semitendinosus autograft. *Orthop Traumatol Surg Res* 2011;97:447-450.
- Reilly DT, Martens M. Experimental analysis of the quadriceps muscle force and patello-femoral joint reaction force for various activities. *Acta Orthop Scand* 1972;43:126-137.
- McNally PD, Marcelli EA. Achilles tendon allograft of a chronic patellar tendon rupture. *Arthroscopy* 1998;14:340-344.
- Kasten P, Schewe B, Maurer F, Gösling T, Krettek C, Weise K. Rupture of the patellar tendon: A review of 68 cases and a retrospective study of 29 ruptures comparing two methods of augmentation. *Arch Orthop Trauma Surg* 2001;121:578-582.
- Mandelbaum BR, Bartolozzi AR, Carney BR. A systematic approach to reconstruction of neglected tears of the patellar tendon. A case report. *Clin Orthop Rel Res* 1988;235:268-271.
- Jain JK, Vidyasagar JV, Chabra R. Percutaneous reconstruction of patellar tendon using semitendinosus tendon in chronic patellar tendon injury—case series and outcome. *Knee* 2014;21:726-730.
- Falconiero RP, Pallis MP. Chronic rupture of a patellar tendon: a technique for reconstruction with Achilles allograft. *Arthroscopy* 1996;12:623-626.
- Abdou YE. Reconstruction of a chronic patellar tendon rupture with semitendinosus autograft. *Arch Orthop Trauma Surg* 2014;134:1717-1721.