

Review Article

Reverse shoulder arthroplasty in acute fractures of the proximal humerus: A systematic review

Stig Brorson, Jeppe V. Rasmussen, Bo S. Olsen, Lars H. Frich¹, Steen L. Jensen², Asbjørn Hróbjartsson³

ABSTRACT

The indications for surgical intervention in complex fractures of the proximal humerus are disputed. In elderly patients with poor bone stock it may be impossible to obtain satisfactory fixation of the tuberosities to a hemiarthroplasty (HA). In such cases primary insertion of a reverse shoulder arthroplasty (RSA) has been suggested. We aimed to review clinical studies reporting benefits and harms of RSA in acute fractures. A systematic review. We included 18 studies containing 430 RSA in acute fractures. We found no randomized clinical trials. Four studies compared outcome after RSA with a historical control group of HA. The median constant score was 58 (range 44-68) which is comparable to previous reviews of HA in 4-part fractures. Complications included dislocation, infection, hematoma, instability, neurological injury, reflex sympathetic dystrophy, intraoperative fractures, periprosthetic fractures, and baseplate failure. Scapular notching was reported in 11 studies with a median value of 25% (range 0-94). Heterogeneity of study designs and lack of primary data precluded statistical pooling of data. No high quality evidence was identified. Based on the available evidence the use of RSA in acute fractures is questionable. The complication rate was high and the clinical implications of long term scapular notching are worrying. Randomized studies with long term follow up using the latest techniques of tubercular reinsertion in RSA toward HA should be encouraged.

Key words: Proximal humeral fractures, proximal humerus fractures, reverse shoulder arthroplasty, reverse shoulder prosthesis, tuberosity fixation

INTRODUCTION

The indications for surgical intervention in complex fractures of the proximal humerus are controversial.^[1-3] In most centers the treatment of choice for displaced 4-part fractures, fracture-dislocations, and head-splitting fractures is primary hemiarthroplasty (HA). Acceptable pain relief has been reported in primary HA but so has marked limitation in function^[4] and results are often compromised by secondary displacement of the tuberosities.^[5] In elderly patients with poor bone stock it may be impossible to obtain satisfactory fixation and healing of the tuberosities. In such cases primary insertion of a reverse shoulder arthroplasty (RSA) has been suggested

as an effective and safe treatment option.^[6-10]

The modern concept of RSA was developed by Grammont in 1985 based on prior experiences with constrained designs.^[11-13] However, the design did not appear in the scientific literature until the paper by Grammont and Baulot in 1993.^[14] Initially, it was developed for arthritic shoulders with severe destruction of the rotator cuff. However, Grammont himself used RSA for acute fractures and fracture sequelae in an unpublished series of 22 cases from 1989 to 1993.^[15] Clinical series of RSA for acute fractures were initiated in France in 1993^[16] and in 2003 the RSA was approved by the American Food and Drug Administration for use in severe cuff arthropathy, failed HA,

Access this article online

Website:

www.internationalshoulderjournal.org

DOI:

10.4103/0973-6042.114225

Quick Response Code:



Departments of Orthopaedic Surgery, Herlev University Hospital, Herlev, ¹Odense University Hospital, ²Aalborg University Hospital, ³The Nordic Cochrane Centre, Rigshospitalet, Denmark

Address for correspondence:

Dr. Stig Brorson,
Department of Orthopaedic
Surgery, Herlev University Hospital,
Herlev Ringvej 75, 2730 Herlev, Denmark.
E-mail: sbrorson@hotmail.com

Please cite this article as: Brorson S, Rasmussen JV, Olsen BS, Frich LH, Jensen SL, Hróbjartsson A. Reverse shoulder arthroplasty in acute fractures of the proximal humerus: A systematic review. Int J Shoulder Surg 2013;7:70-8.

osteoarthritis, and irreducible 3- and 4-part fractures of the proximal humerus.^[17]

In RSA the deltoid muscle is utilized as a compensation for the deficient rotator cuff by creating a stable center of rotation in the glenoid allowing for active flexion and abduction of the arm. The deltoid function is enhanced by moving the center of rotation distally and medially increasing the tension of the deltoid fibers and decreasing the mechanical torque at the glenoid component.^[18] In displaced 4-part fractures and fracture-dislocations some forward elevation can be obtained even if the tuberosities do not heal. However, in such cases poor rotation can be expected. New techniques of tuberosity fixation have been proposed and results have been encouraging.^[19-23]

Short term pain relief and early mobilization after RSA in acute fractures has been reported,^[7,10,24,25] but only few long-term results have been published.^[16,22] Long operator learning curves for RSA in shoulder arthritis have been reported,^[26,27] and revision surgery is challenging.^[28,29] Reported complications to RSA include dislocation, infection, hematoma, instability, loss of rotation, neurological injury, reflex sympathetic dystrophy, intraoperative fractures, peri-prosthetic fractures, baseplate failure and scapular notching.^[18,29-33]

In France and the U.S., RSA is commonly used for complex fractures of the proximal humerus and RSA is considered a useful option worldwide. Thus, the overall balance of the benefits and harms of this fairly new surgical procedure in proximal humeral fractures is unclear. We have been unable to identify any systematic review studying outcome after RSA in acute fractures. We therefore decided to systematically search and review clinical studies reporting benefits and harms of RSA in acute fractures of the proximal humerus.

METHODS

We included randomized clinical trials, observational studies, and case series having included at least 10 acute fractures treated with RSA. We included studies without language restriction. All patients should be followed up for at least 6 months. We excluded studies evaluating results after RSA for other indications (cuff arthropathy, revision surgery, delayed fracture management, tumor surgery). We searched Pubmed and Cochrane Library (November 7th 2011) using the search terms:

(inverse* OR reverse* OR delta* OR grammont* OR inverted*) AND ((shoulder* OR humer*) AND (fractu* OR broken* OR break*) OR ("Shoulder Fractures"[Mesh])).

We further searched Embase, Web of Science, and abstracts and posters from the annual meetings of SECEC (Société Européenne de Chirurgie de l'Epaule et du Coude) from 2009 to 2011.

One author conducted the literature search and scanned all references for eligibility. Articles that could not clearly be excluded were retrieved in full text and read independently by two authors who decided independently on eligibility. Disagreements were resolved by discussion. Study characteristics and results were extracted independently by two authors using pre-tested forms. In cases of discrepancies between data in abstract and text we extracted data from the most comprehensive source. In cases of multiple publication of data from identical patients at different follow-up we summarized the temporal development and included data from the most recent follow-up only. We did not contact the authors for primary patient data. Data were summarized in a table organized according to the study design.

The risk of bias in observational studies was assessed according to pre-defined criteria: (1) cohort clearly defined at baseline, (2) cohort consecutively or randomly sampled, (3) number of drop-outs or loss to follow-up accounted for, (4) outcome blindly assessed, and (5) conflicts of interests declared.^[34-36]

RESULTS

We identified 190 articles by the internet search, 64 were clearly not relevant, 126 were reviewed in full text [Figure 1]. One hundred and eight of those did not comply with the inclusion criteria. Thus, we included 18 clinical studies containing 430 RSA in acute fractures [Table 1]. There were no randomized clinical trials, four retrospective cohort studies with historical control groups,^[22,24,37,38] four prospective cohort studies,^[8,9,39,40] six retrospective cohort studies,^[7,10,19,21,23,41] and four cohort studies with unclear designs.^[6,16,42,43] Ten studies

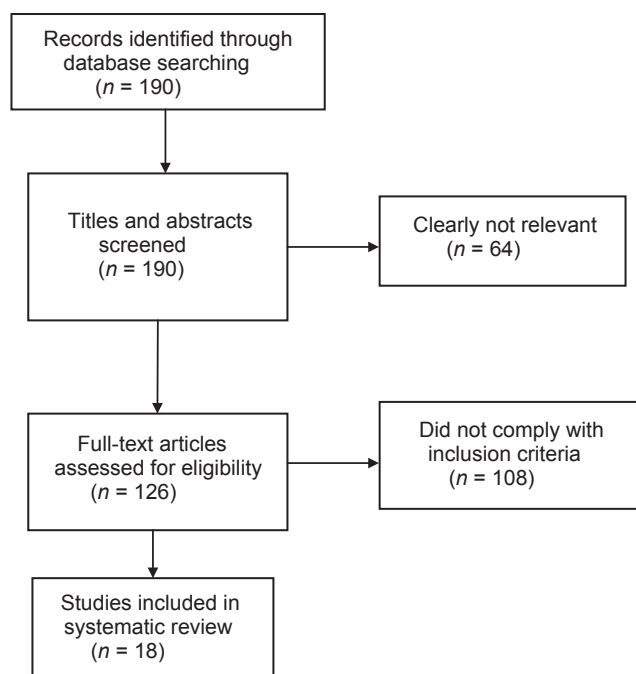


Figure 1: Flow diagram of studies included in the systematic review

Table 1: Results

Study	Fractures (n)	Age (mean and range)	Sex (f/m)	Follow-up time (months, mean and range)	Loss to follow-up	Outcome (mean and range)	Complications (number, types) radiographic diagnoses in brackets	Authors' conclusions
Comparative studies								
Cohort studies with historical control								
Gallinet (2009) ^[24]	RSA: 16 HA: 17	RSA: 74 (58-83) HA: 74 (49-95)	RSA: 13/3 HA: 15/2	RSA: 12 (6-18) HA: 17 (6-55)	RSA: 3 out of 19 HA: 4 out of 21	RSA: 53 (34-76) ¹ HA: 39 (19-61) ¹	RSA: 1 deep infection 1 superficial infection 1 reflex sympathetic dystrophy (15 scapular notching) HA: 1 superficial infection 2 reflex sympathetic dystrophy 1 transitory axillary nerve palsy (3 abnormal tuberosity fixations)	RSA: rapid recovery Good active mobility Predictable results but impaired rotation HA: outcome depends on tuberosity union Prolonged immobilization
Reitman (2011) ^[37]	RSA: 13 HA: 122	RSA: 70 (58-90) HA: 72	RSA: 8/5	RSA: 29 (8-46)	Ns	RSA: 67 (45-77) ¹ HA: 84 ¹	2 axillary nerve palsy 1 radial nerve palsy 1 haematoma (3 scapular notching)	Reverse prosthesis should be considered a salvage procedure for elderly patients
Sirveaux (2006) ^[22]	RSA: 11 HA: 139	RSA: 78 (69-91) HA: 77 (70-88)	RSA: 13/2 HA: 129/10	46 (24-109)	4 out of 15	RSA: 55 (31-73) ¹ 81 (45-106) ² HA: 511 76 ²	1 dislocation (1 glenoid migration) (4 non-union of greater tuberosity) (6 non-union of lesser tuberosity)	RSA in fractures is a challenge, and long term results are needed
Young (2010) ^[36]	RSA: 10 HA: 10	RSA: 77 HA: 75	RSA: 10/0 HA: 8/2	RSA: 22 HA: 44	Ns	RSA: 65 (40-88) ³ HA: 67 (26-100) ³ RSA: 29 (15-56) ⁴ HA: 22 (12-34) ⁴	2 revisions in HA group (2 scapular notching)	RSA should remain guarded
Descriptive studies								
Prospective cohort studies								
Dordain (2011) ^[39]	20	80	20/0	16 (12-32)	2 out of 22	58 ¹ 91 ²	(5 tuberosity malunions) (4 tuberosity non-unions) (2 tuberosity osteolysis) (6 scapular notching)	RSA promising in 3-and 4-part fractures in elderly Long term results remain to be evaluated
Klein (2008) ^[8]	20	75 (67-85)	14/6	33 (24-52)	Ns	68 ¹ (47-98) 68 ³ (50-90) 47 ⁵ (6-63)	1 dislocation 2 infections	Good functional outcome Rotation better than expected
Reuther (2011) ^[9]	44	80 (63-96)	38/6	14 (5-28)	7 out of 51	58 ¹ 69 ³	1 clavicle fracture 1 acromion fracture (no scapular notching)	Good solution in elderly Very good clinical and subjective results
Terragnoli (2007) ^[40]	13	75 (69-87)	16/2	6	5 out of 18	59 ¹	Ns	Results good with regard to pain and good/sufficient with regard to function Active mobilization the day after surgery. Most humeral tuberosities can be sacrificed

(contd)

Table 1: Contd/-

Retrospective cohort studies								
Gallinet (2011) ^[19]	40	76	Ns	23	Ns	CS and DASH score, data not reported	Ns (70% had scapular notching)	Tuberosities should be reinserted. Excision not recommended
Grisch (2011) ^[7]	24	80 (67-90)	Ns	23 (12-60)	6 out of 30	66 (34-83) ¹ 98 (52-139) ²	3 reoperations: 2 hematoma 1 periprosthetic fracture	Very satisfactory procedure Rapid postoperative recovery
Hubert (2004) ^[41]	14	80 (71-98)	14/0	14	Ns	80% ²	2 capsulitis (1 scapular notching)	Good short-term outcome
Lenarz (2011) ^[10]	30	77 (65-94)	27/3	23 (12-36)	2 out of 32	78 (36-98) ³	1 preoperative brachial plexopathy (1 scapular notching)	In short term, RSA relieved pain and improved function
Russo (2011) ^[21]	16	74 (68-95)	Ns	14	18 out of 34	68 ¹ 90 ¹ (new tuberosity fixation)	Ns	New tuberosity fixation technique can improve outcome in RSA
Sirveaux (2011) ^[23]	47	79	Ns	30	15 out of 62	55 ¹ 57 ¹ (with greater tuberosity healing) 41 ¹ (without greater tuberosity healing)	1 acromial fracture 1 shaft fracture 1 infection (1 glenoid loosening)	Healing of the greater tuberosity is necessary for recovery of active external rotation
Prospective or retrospective cohort studies (unclear design)								
Bufquin (2007) ^[42]	41	78 (65-97)	41/2	22 (6-58)	2 out of 43	44 ¹ (16-69) 66 ² (25-97) 9 ³ (0-19) 44 ⁵ (0-92)	1 intraoperative glenoid fracture 3 reflex sympathetic dystrophy 5 neurological complications 1 dislocation 1 acromial fracture 1 deltoid muscle flap (19 tuberosity displacements) (10 scapular notching)	Satisfactory mobility despite tuberosity migration Pain relief Long-term results required
Cazeneuve (2011) ^[16]	35	75 (58-92)	33/2	86 (12-204)	14 out of 49	53 ¹ 68 ²	8 (4 reoperations) 2 regional pain syndrome 1 infection 4 dislocations (1 aseptic loosening of glenoid) (49% abnormal radiographs)	Results clinically disappointing and radiographically worrying. We cannot validate the use of RSA in recent trauma
Emily (2009) ^[43]	15	78	Ns	18	Ns	45 ² (no active rotation) 98 ² (active rotation)	no complications (24% non-union or osteolysis)	Strong fixation and healing of greater tuberosity are important
George (2009) ^[6]	19	81	14/5	36	Ns	58 ¹	(57% scapular notching)	No influence of approach on CS or scapular notch RSA provides good results in fragile patients 85% kept autonomy

¹Constant score, non-adjusted; ²Constant score, age- and sex-adjusted; ³ASES score; ⁴Oxford shoulder score; ⁵DASH score; ASES = American Shoulder and Elbow Surgeons; DASH = Disability of the Arm; Shoulder and Hand RSA = Reverse shoulder arthroplasty; HA = Hemiarthroplasty

were conducted in France.

The studies were reported as conference abstracts,^[19,21,41,44] posters,^[6,7,9,39,43] and full articles.^[8,10,16,24,37-40,42] The median number of patients included per study was 20 (range 10-47). Fourteen studies reported outcome as non-adjusted constant score (CS), two studies^[41,43] used adjusted CS only, and two studies^[10,38] used other outcome measures. The median non-adjusted CS was 58 (range 44-68). Two studies^[22,37] did not report complication data. The quality of the studies was generally low. Only one study^[42] complied with all five pre-defined items. Two studies^[16,24] complied with four out of five items. Six studies did not comply with any of the five pre-defined items.^[6-8,21,23,43]

Cohort studies with historical control

Gallinet *et al.*^[24] retrospectively followed a cohort of 16 patients with 3- and 4-part fractures for 6-18 months (mean age 74). Outcome was compared with a control group of 17 patients treated with HA (mean age of 74) and a follow-up of 6-55 months. One patient underwent tuberosity reattachment. Mean CS was 53 (range 34-76) in the RSA group compared to 39 (range 19-61) in the HA group. The difference was statistically significant ($P = 0.005$). Complications in the RSA group included one deep infection and one reflex sympathetic dystrophobia. Scapular notching was found in 15 radiographs.

Reitman and Kerzhner^[37] retrospectively followed a cohort of 13 patients with 3- and 4-part fractures (including six fracture-dislocations) for 8-46 months (mean age 70). Five patients underwent tuberosity reattachment. Outcome was compared with a historical control group of 112 HA from three studies on fractures of "equivalent severity." Mean CS was 67 (range 45-77) in the RSA group compared to 84 in the HA group. Statistically testing was not reported. Complications in the RSA group included two axillary nerve palsies, one radial nerve palsy, and one hematoma. Scapular notching was found in three radiographs.

Sirveaux *et al.*^[22] retrospectively followed a cohort of 11 3- and 4-part fractures for 46 months (range 24-109). Mean age was 78 years. All patients underwent tuberosity reattachment. Outcome was compared to a historical control group of 139 HA from a multicenter study. Mean CS was 55 (range 31-73) in the RSA group compared to 51 in the HA group. The difference was reported as not statistically significant. Complications in the RSA group included one dislocation, one glenoid migration, four non-unions of the greater tuberosity, and six non-unions of the lesser tuberosity. Scapular notching was not reported.

Young *et al.*^[38] retrospectively compared 10 RSA in patients with 3- and 4-part fractures (mean age 77) to 10 HA (mean age 75) with a follow-up of 22-44 months. Five patients underwent reattachment of both tuberosities, four underwent greater tuberosity reattachment, and both

tuberosities were excised in one patient. ASES (American Shoulder and Elbow Surgeons) score was 65 (range 40-88) in the RSA group and 67 (26-100) in the HA group. Oxford shoulder score was 29 (range 15-56) and 22 (range 12-34) respectively. Statistically testing was not reported and no complications were reported in the RSA group. Scapular notching was found in two radiographs.

Prospective cohort studies

Klein *et al.*^[8] followed a cohort of 20 AO (Arbeitsgemeinschaft für Osteosynthesefragen) type B and C fractures for 33 months (range 24-52). Mean age was 75 years and mean CS was 68 (range 47-98). Dordain *et al.*^[39] followed a consecutive cohort of 20 3- and 4-part fractures for 17 months (range 12-32). Mean age was 80 years and mean CS was 59 (range 47-98). Reuther *et al.*^[9] followed a consecutive cohort of 44 3- and 4-part fractures for 14 months (range 5-28). Mean age was 80 years and mean CS was 58. Terragnoli *et al.*^[40] followed a cohort of 18 3- and 4-part fractures for 6 months. Mean age was 75 years. Mean CS was 59.

Retrospective cohort studies

Gallinet *et al.*^[19] retrospectively reviewed a cohort of 40 patients for 23 months. Mean age was 76. CS was used, but the values were not reported. Grisch *et al.*^[45] retrospectively reviewed a cohort of 24 3- and 4-part fractures for 23 months (range 12-60). Mean age was 80, and mean CS was 66 (34-83). Hubert *et al.*^[41] retrospectively reviewed a cohort of 14 3- and 4-part fractures for 14 months. Mean age was 80 and weighted CS was 80%. Lenarz *et al.*^[10] retrospectively reviewed 30 patients with 3- and 4-part fractures for 23 (12-36) months. Mean age was 77. Mean ASES score was 78 (36-98). Russo *et al.*^[21] retrospectively followed a cohort of 16 3- and 4-part fractures for 14 months. Mean age was 74 years. A new tuberosity fixation technique was used in nine out of the 16 cases. CS was 68 in usual tuberosity fixation compared to 90 in the new tuberosity fixation group (statistically testing not reported). Sirveaux *et al.*^[23] retrospectively followed a cohort of 47 fractures for 30 months. Mean age was 79, and mean CS was 55. They reported that healing of the greater tuberosity affected CS (57 compared to 41, statistical testing not reported).

Prospective or retrospective cohort studies (design unclear)

Bufquin *et al.*^[42] reviewed a consecutive series of 43 3- and 4-part fractures for 22 months (range 6-58). Mean age was 78, and mean CS was 44 (range 16-69). Emily *et al.*^[43] reviewed a consecutive series of 15 3- and 4-part fractures for a mean of 18 months. Mean age was 78, and mean adjusted CS was 45 in patients with no external rotation compared to mean adjusted CS of 98 in patients with at least 10° of external rotation (statistical testing not reported). George *et al.*^[6] reviewed a consecutive series of 19 fractures (Duparc type 3 or 4) for 36 months. Mean age was 81, and mean CS was 58. The

cohort by Cazeneuve and Cristofari [Table 2] was established in 1993 and the most recent follow-up was in 2011.^[16] Outcome has been reported in several publications^[16,46-51] and the cohort has been continuously enlarged. Data from the most recent follow-up were included. They reviewed 35 patients with RSA (24 fractures and 11 fracture-dislocations) for 1-17 years. Mean CS was 53. Limited rotation preventing eating, dressing, and body hygiene was reported. 60% had abnormal radiographs after 7 years.

DISCUSSION

We included 18 clinical studies with a high risk of bias and no randomized clinical studies. Mean CS after RSA in comparative studies ranged from mean CS 53-67 compared to 39-84 in HA. Numerous complications after RSA were reported including dislocation, infection, hematoma, instability, neurological injury, reflex sympathetic dystrophy, intraoperative fractures, periprosthetic fractures, and baseplate failure. Scapular notching was reported in 11 out of 18 studies with a median value of 25% (range 0-94) [Table 3].

We conducted an iterative search in several databases and identified more studies than any previous reviews. The

weakness of our study is the lack of high quality evidence precluding pooling of outcome data.

We have been unable to identify any previous systematic reviews of outcome after RSA in acute fractures of the proximal humerus. A narrative review by Spencer and Voloshin^[52] included four short-term studies that reported an active elevation of 97° to 122° and a complication rate of 15%-28%. Four studies included in our review compared outcome after RSA with outcome from a historical control group of HA. The reported outcome was comparable to previous systematic reviews of outcome after HA in 4-part fractures. Thus, den Hartog *et al.*^[53] reported a mean CS of 55 (SD = 9.6) in 258 HA. Kontakis *et al.*^[4] reported a mean CS of 57 (range 11-98) in 560 primary HA. The heterogeneity of study designs and lack of primary patient data precluded a prudent pooling of data. Three descriptive studies,^[6,42,43] but no comparative studies, reported individual patient data.

Selection bias may occur if patients with the most severe pathology are selected for RSA. Several authors did not clearly report their criteria for using RSA, and baseline characteristics may differ between the studies. The cohort was clearly defined at baseline in eight studies.^[10,16,22,24,37,38,41,42] Only three

Table 2: The Cazeneuve and Cristofari cohort

Publication	Cases (n)	Follow-up (months)	Follow-up (patients)	Mean age (years)	Constant score	Complications	Authors' conclusions
2006 ^[46]	23	86 (5-12 years)	16 (7 died)	75	60	1 infection 1 dislocation 2 reflex dystrophy 1 glenoid loosening 11 scapular notching	Good functional outcome except for rotation in patients where tubercle fixation cannot be obtained
2008a ^[47]	36	71	25 (9 died, 2 moved)	75	59	1 aseptic glenoid loosening; 2 sympathetic dystrophies, 1 infection, 14 inferior scapular notching	Good functional outcome except for rotation in patients where tubercle fixation cannot be obtained, worrying scapular notching
2008b ^[48]	41	78 (1-14 years)	30 (9 died, 2 moved)	75	59	1 aseptic glenoid loosening, 1 septic humeral loosening, 17 inferior scapular notches	Delta III is a possible alternative with reliable functional outcome. Rotation remains low
2008c ^[49]	41	78 (1-14 years)	30 (9 died, 2 moved)	ns	59	1 aseptic glenoid loosening 2 sympathetic dystrophies, 3 ant. dislocations, 1 infection	A possible alternative with reliable functional outcome
2009 ^[50]	41	78	30	75	59	1 septic humeral loosening; 1 aseptic loosening of glenoid comp.; 1 disloc; 2 regional pain, unsatisfactory images in 70% of cases, 17 inferior scapular notches	An attractive alternative for acute complex fractures in elderly when refixation of the tuberosities appears compromised
2010 ^[51]	47	79 (1-16 years)	36 (9 died, 2 moved)	75	53	23 (63%) radiographical loosening of glenoid, 1 aseptic loosening of glenoid, 1 septic humeral loosening	Reduction of CS and further development of scapular notching worrying
2011 ^[16]	49	86 (1-17 years)	35 (12 died, 2 moved)	75	53	2 regional pain syndromes, 4 dislocations, 1 deep infection, 1 aseptic loosening of glenoid; 6 (17%) reoperations, 57% notches	Results clinically disappointing and radiographically worrying, CS lower in scapular notching (41 compared to 57)

CS = Constant score

studies reported a cohort consecutively or randomly sampled suggesting a high-risk of selection bias.^[16,24,42] To eliminate selection bias clinical trials including, randomization and concealment of allocation are warranted.

Follow-up time for RSA in comparative studies ranged from 6 months to 109 months compared with follow up for HA ranging from 6 months to 70 months. Mean follow-up time was longer for HA compared with RSA in three out of four comparative studies. In the fourth study, follow-up time was matched.^[37] A statistically significant difference in follow-up time was reported in one study.^[23] Short follow-up for RSA may lead to overestimation of outcome as long-term complications may occur.

In only five studies outcome was assessed by an independent observer. Poolman *et al.*^[54] reported that in orthopedic studies with continuous outcome measures, un-blinded outcomes assessment was associated with significantly larger treatment effects than blinded outcomes assessment (standardized mean difference, 0.76 compared with 0.25; $P = 0.01$). In studies with dichotomous outcomes, un-blinded outcomes assessments were associated with significantly greater treatment effects than blinded outcomes assessments (odds ratio, 0.13 compared with 0.42; $P < 0.001$). Similarly, we have reported that non-blinded assessors of subjective binary outcomes generate substantially biased effect estimates in randomized clinical trials, exaggerating odds ratios by 36%.^[55]

A change in surgical procedure has taken place in the included studies. RSA was originally used in cases when reconstruction of the tuberosities was impossible. However, reconstruction of the tuberosities seems to improve stability, and good functional outcome has been reported in cases where tuberosity fixation in RSA was performed.^[21,23,43,56] Sirveaux *et al.*^[23] reported a mean CS of 57 if the greater tuberosity was healed compared to 41 if the greater tuberosity was not healed. Emily *et al.*^[43] reported a mean adjusted CS of 45 in patients with no external rotation compared to 98 in patients with at least 10° of external rotation. They concluded that fixation of the greater tuberosity is essential for restoring external rotation. The mean active external rotation values were reported in nine studies [Table 4]. The median value was 20° (range 9-49). If, however, tuberosity fixation is possible, a conventional prosthesis may represent a less expensive solution.

The surgical approaches reported were superolateral or lateral deltosplit in eight studies, anterosuperior in one study, and deltopectoral in six studies. In three studies, the surgical approach was unclear. Three studies used more than one approach. It was not possible to correlate the clinical outcome to the surgical approach from the published data. Only three studies provided data on the surgeons' experience and it was not possible to compare clinical outcome with the surgeons' experience from the published data. No data on the number of RSA performed at each center were available.

Recently published data on learning curve in RSA have suggested that 18 RSA should be inserted by high volume surgeons before the operation time stabilizes.^[26] However, no data on the clinical implications of learning curve for the patient was reported.

Most authors do not recommend the use of RSA in younger patients. However, a closer look at the 12 studies reporting range of age reveals that three studies included patients younger than 60 and eight studies included patients younger than 70. Reporting of non-adjusted CS was preferred whenever possible because age- and sex-adjusted CS seems to favor outcome in the very elderly.

Reflex sympathetic dystrophy was reported in 6 cases; neurological complications in 9 cases; intraoperative fractures in 5 cases; dislocations in 7 cases; infections in 5 cases, and intraoperative fractures in 5 out of the 430 cases. The complications rates, however, were likely underreported

Table 3: Scapular notching after reverse shoulder arthroplasty in acute fractures

Study	Follow-up, mean and range (months)	Scapular notching %
Young ^[38]	22 (16-37)	20 (2 out of 10)
Klein ^[8]	33 (24-52)	5 (1 out of 20)
Lenarz ^[10]	23 (12-36)	3 (1 out of 30)
George ^[6]	36 range ns	57 (11 out of 19)
Bufquin ^[42]	22 (6-58)	25 (10 out of 41)
Reitman ^[37]	Mean ns (8-46)	23 (3 out of 13)
Gallinet ^[24]	12 (6-18)	94 (15 out of 16)
Cazeneuve ^[16]	86 (12-204)	57 (20 out of 35)
Dordain ^[39]	16 (12-32)	30 (6 out of 20)
Reuther ^[9]	14 (5-28)	0 (0 out of 44)
Gallinet ^[19]	23 range ns	70 (28 out of 40)

Table 4: External rotation

Study	Active external rotation (mean and range)
Young ^[38]	49 (5-105)
Gallinet ^[24]	9 (0-80)
Reitman ^[37]	Ns
Sirveaux ^[22]	10 (-10±30)
Dordain ^[39]	13 (0-50)
Klein ^[8]	25 (10-35)
Reuther ^[9]	Ns
Terragnoli ^[40]	Ns
Gallinet ^[19]	Ns
Grisch ^[7]	20 (-30±70)
Hubert ^[41]	Ns
Lenarz ^[10]	27 (0-45)
Russo ^[21]	Mean ns
Sirveaux ^[23]	Mean ns
Bufquin ^[42]	25 range ns
Emily ^[43]	13 (0-50)
George ^[6]	Unclear
Cazeneuve ^[16]	Unclear

as several studies surprisingly reported no complications at all after RSA. Scapular notching is a complication unique to RSA. It may occur in adduction if the polyethylene component of the humeral part collides with the inferior glenoid, eventually leading to implant loosening. However, the clinical implications of radiological scapular notching are not fully understood. The percentage of scapular notching after RSA in acute fractures was reported in 11 studies with a median value of 25 [Table 3]. In the study with the longest follow-up 49% of radiographic images were considered abnormal. They reported limited rotation preventing eating, dressing, and body hygiene. Unfortunately, the authors did not report any difference in functional outcome between patients with radiographical scapular notching and patients without such changes. Two systematic reviews have studied the incidence and clinical implications of scapular notching. Nicholson *et al.*^[57] included 24 studies and found that scapular notching appeared between 6 and 14 months postoperatively, with an incidence of 44-96%. Sadoghi *et al.*^[58] included data from five studies and found no correlation between scapular notching and clinical outcome after 24-42 months. At 60 months or more scapular notching was positively correlated with CS pain score and active range of motion. Because of the short follow-up we cannot expect to detect the clinical implications of scapular notching in the vast majority of studies.

Randomized studies with long-term follow-up using the latest techniques of tubercular reinsertion in RSA toward HA are needed. We are in the planning stage of a randomized clinical trial comparing outcome after RSA with HA in complex proximal humeral fractures. It would furthermore be interesting to study possible associations between: (1) The length of follow-up and scapular notching, (2) scapular notching and altered functional outcome, (3) tuberosity fixation techniques and outcome.

CONCLUSIONS

The included clinical studies had a high risk of bias. The level of functional outcome after RSA in acute fractures is so far not clearly superior to HA. However, high complication rates were reported after RSA, and at least 60 months of follow-up seems necessary to study the clinical implications of scapular notching. Based on the available evidence the use of RSA in acute fractures of the proximal humerus is questionable, and we cannot recommend the use of RSA for such fractures outside clinical protocols.

REFERENCES

- Bhandari M, Matthys G, McKee MD, Evidence-Based Orthopaedic Trauma Working Group. Four part fractures of the proximal humerus. *J Orthop Trauma* 2004;18:126-7.
- Handoll HH, Ollivere BJ. Interventions for treating proximal humeral fractures in adults. *Cochrane Database Syst Rev* 2012;12:CD000434.
- Misra A, Kapur R, Maffulli N. Complex proximal humeral fractures in adults: A systematic review of management. *Injury* 2001;32:363-72.
- Kontakis G, Koutras C, Tosounidis T, Giannoudis P. Early management of proximal humeral fractures with hemiarthroplasty: A systematic review. *J Bone Joint Surg Br* 2008;90:1407-13.
- Boileau P, Krishnan SG, Tinsi L, Walch G, Coste JS, Molé D. Tuberosity malposition and migration: Reasons for poor outcomes after hemiarthroplasty for displaced fractures of the proximal humerus. *J Shoulder Elbow Surg* 2002;11:401-12.
- George T, Dederichs A, Bellan D, Chaumont PL, Charvet R, Coudane H. Reversed prosthesis for management of complex proximal humeral fractures: a prospective monocenter study. Madrid: 22nd Congress of SECEC; 2009 [poster].
- Grisch D, Riede U, Gerber C, Jost B. Inverse total shoulder arthroplasty as primary treatment for complex proximal humerus fractures in the elderly. Lyon: 23rd Congress of SECEC; 2011 [poster].
- Klein M, Juschka M, Hinkenjann B, Scherger B, Ostermann PA. Treatment of comminuted fractures of the proximal humerus in elderly patients with the Delta III reverse shoulder prosthesis. *J Orthop Trauma* 2008;22:698-704.
- Reuther F, Proust J, Kohut G, Nijs S. Specially designed inverse shoulder prosthesis for the treatment of complex proximal humeral fractures. Lyon: 23rd Congress of SECEC; 2011 [poster].
- Lenarz C, Shishani Y, McCrum C, Nowinski RJ, Edwards TB, Gobezie R. Is reverse shoulder arthroplasty appropriate for the treatment of fractures in the older patient? Early observations. *Clin Orthop Relat Res* 2011;469:3324-31.
- Baulot E, Sirveaux F, Boileau P. Grammont's idea: The story of Paul Grammont's functional surgery concept and the development of the reverse principle. *Clin Orthop Relat Res* 2011;469:2425-31.
- Flatow EL, Harrison AK. A history of reverse total shoulder arthroplasty. *Clin Orthop Relat Res* 2011;469:2432-9.
- Katz D, O'Toole G, Cogswell L, Sauzieres P, Valenti P. A history of reverse shoulder prosthesis. *Int J Shoulder Surg* 2007;1:108-13.
- Grammont PM, Baulot E. Delta shoulder prosthesis for rotator cuff rupture. *Orthopedics* 1993;16:65-8.
- Sirveaux F, Navez G, Roche O, Molé D, Williams MD. Reverse prosthesis for proximal humerus fracture, technique and results. *Tech Should Surg* 2008;9:15-22.
- Cazeneuve JF, Cristofari DJ. Long term functional outcome following reverse shoulder arthroplasty in the elderly. *Orthop Traumatol Surg Res* 2011;97:583-9.
- Nam D, Kepler CK, Neviasser AS, Jones KJ, Wright TM, Craig EV, et al. Reverse total shoulder arthroplasty: Current concepts, results, and component wear analysis. *J Bone Joint Surg Am* 2010;92:23-35.
- Zumstein MA, Pinedo M, Old J, Boileau P. Problems, complications, reoperations, and revisions in reverse total shoulder arthroplasty: A systematic review. *J Shoulder Elbow Surg* 2011;20:146-57.
- Gallinet D, Adam A, Gasse N, Rochet S, Obert L. Interest of the tuberosities reinsertion in complex shoulder fractures treated by reverse prosthesis. Lyon: 23rd Congress of SECEC; 2011 [abstract].
- Levy JC, Badman B. Reverse shoulder prosthesis for acute four-part fracture: Tuberosity fixation using a horseshoe graft. *J Orthop Trauma* 2011;25:318-24.
- Russo R, Cautiero F, Ciccirelli M, Pizzi G, Rotonda GD. The 'Bone Collar-And-Tie' (bCAT) technique: a new solution to restore tuberosity position and cuff tension in reverse shoulder prosthesis for complex proximal humeral fractures. Lyon: 23rd Congress of SECEC; 2011 [abstract].
- Sirveaux F, Navez G, Favard L, Boileau P, Walch G, Mole D. Reverse prosthesis for acute proximal humerus fracture, the multicentric study. In: Walch G, Boileau P, Mole D, Favard L, Levigne C, Sirveaux F, editors. *Reverse Shoulder Arthroplasty*. Montpellier: Sauramps Médical; 2006. p. 73-80.

23. Sirveaux F, Wein-Remy F, Block D, Sedaghatien J, Roche O, Molé D. Early functional results of the reversed prosthesis for acute fractures in elderly are improved by tuberosity healing. Lyon: 23rd Congress of SECEC; 2011 [abstract].
24. Gallinet D, Clappaz P, Garbuio P, Tropet Y, Obert L. Three or four parts complex proximal humerus fractures: Hemiarthroplasty versus reverse prosthesis: A comparative study of 40 cases. *Orthop Traumatol Surg Res* 2009;95:48-55.
25. Kontakis G, Tosounidis T, Galanakis I, Megas P. Prosthetic replacement for proximal humeral fractures. *Injury* 2008;39:1345-58.
26. Riedel BB, Mildren ME, Jobe CM, Wongworawat MD, Phipatanakul WP. Evaluation of the learning curve for reverse shoulder arthroplasty. *Orthopedics* 2010;16:237-41.
27. Rockwood CA, Jr. The reverse total shoulder prosthesis. The new kid on the block. *J Bone Joint Surg Am* 2007;89:233-5.
28. Boileau P, Watkinson D, Hatzidakis AM, Hovorka I, Neer Award 2005: The Grammont reverse shoulder prosthesis: Results in cuff tear arthritis, fracture sequelae, and revision arthroplasty. *J Shoulder Elbow Surg* 2006;15:527-40.
29. Gerber C. Complications and revisions of reverse total shoulder replacements. *Nice Shoulder Course* 2006:315-7.
30. Cheung E, Willis M, Walker M, Clark R, Frankle MA. Complications in reverse total shoulder arthroplasty. *J Am Acad Orthop Surg* 2011;19:439-49.
31. Farshad M, Gerber C. Reverse total shoulder arthroplasty-from the most to the least common complication. *Int Orthop* 2010;34:1075-82.
32. Trappey GJ 4th, O'Connor DP, Edwards TB. What are the instability and infection rates after reverse shoulder arthroplasty? *Clin Orthop Relat Res* 2011;469:2505-11.
33. Wierks C, Skolasky RL, Ji JH, McFarland EG. Reverse total shoulder replacement: Intraoperative and early postoperative complications. *Clin Orthop Relat Res* 2009;467:225-34.
34. Norris SL, Atkins D. Challenges in using nonrandomized studies in systematic reviews of treatment interventions. *Ann Intern Med* 2005;142:1112-9.
35. Audigé L, Bhandari M, Griffin D, Middleton P, Reeves BC. Systematic reviews of nonrandomized clinical studies in the orthopaedic literature. *Clin Orthop Relat Res* 2004;427:249-57.
36. Deeks JJ, Dinnes J, D'Amico R, Sowden AJ, Sakarovitch C, Song F, et al. Evaluating non-randomized intervention studies. *Health Technol Assess* 2003;7:iii-x, 1-173.
37. Reitman RD, Kerzhner E. Reverse shoulder arthroplasty as treatment for comminuted proximal humeral fractures in elderly patients. *Am J Orthop (Belle Mead NJ)* 2011;40:458-61.
38. Young SW, Segal BS, Turner PC, Poon PC. Comparison of functional outcomes of reverse shoulder arthroplasty versus hemiarthroplasty in the primary treatment of acute proximal humerus fracture. *ANZ J Surg* 2010;80:789-93.
39. Dordain F, Emily S, Lebel B, Hulet C, Vielpeau C. The reverse shoulder arthroplasty for proximal humerus fracture patients over 70 years old. Lyon: 23rd Congress of SECEC; 2011 [poster].
40. Terragnoli F, Zattoni G, Damiani L, Cabrioli A, Li Bassi G. Treatment of proximal humeral fractures with reverse prostheses in elderly patients. *J Orthop Traumatol* 2007;8:71-6.
41. Hubert L, Lahogue J-F, Hersan A, Gournay A, Massin P. Reverse Delta prosthesis in shoulder trauma: preliminary results. *Rev Chir Orthop Reparatrice Appar Mot* 2004;90:116. [Abstract].
42. Bufquin T, Hersan A, Hubert L, Massin P. Reverse shoulder arthroplasty for the treatment of three-and four-part fractures of the proximal humerus in the elderly: A prospective review of 43 cases with a short-term follow-up. *J Bone Joint Surg Br* 2007;89:516-20.
43. Emily S, Dordain F, Lebel B, Hulet C, Vielpeau C. Influence of restoration of the external rotation in proximal humeral fracture treated with reverse shoulder arthroplasty. Lyon: 23rd Congress of SECEC; 2011. [Poster].
44. Sirveaux F, Wein-Remy F, Block D, Sedaghatien J, Mole D. Reverse TSR-does it improve the results in acute fracture arthroplasty? Lyon: 23rd Congress of SECEC; 2011. [Abstract].
45. Grisch D, Helmy N, Riede U. Inverse total shoulder arthroplasty as primary treatment for complex proximal humerus fractures in elderly people. *Swiss Med Wkly* 2010;140:26S.
46. Cazeneuve JF, Cristofari DJ. Grammont reversed prosthesis for acute complex fracture of the proximal humerus in an elderly population with 5-12 years follow-up. *Rev Chir Orthop Reparatrice Appar Mot* 2006;92:543-8.
47. Cazeneuve JF, Hassan Y, Kermad F, Brunel A. Delta III reverse-ball-and-socket total shoulder prosthesis for acute complex fractures of the proximal humerus in elderly population. *Eur J Orthop Surg Traumatol* 2008;18:81-6.
48. Cazeneuve JF. Delta III prosthesis for acute fractures in elderly population with a 1- to 14-year follow-up. *J Clin Rehabil Tissue Eng Res* 2008;12:10201-4.
49. Cazeneuve JF. Reverse shoulder arthroplasty for acute fractures: retrospective long term outcomes. In: Boileau P, Mole D, Favard L, Levigne C, Sirveaux F, editors. *Shoulder Concepts*. Montpellier: Sauramps Médical; 2008. p. 163-72.
50. Cazeneuve JF, Cristofari DJ. Delta III reverse shoulder arthroplasty: Radiological outcome for acute complex fractures of the proximal humerus in elderly patients. *Orthop Traumatol Surg Res* 2009;95:325-9.
51. Cazeneuve JF, Cristofari DJ. The reverse shoulder prosthesis in the treatment of fractures of the proximal humerus in the elderly. *J Bone Joint Surg Br* 2010;92:535-9.
52. Spencer JS, Voloshin I. Reverse shoulder arthroplasty for acute proximal humeral fractures in the geriatric patient: a review of the literature. *Geriatr Orthop Surg Rehabil* 2011;2:181.
53. den Hartog D, de Haan J, Schep NW, Tuinebreijer WE. Primary shoulder arthroplasty versus conservative treatment for comminuted proximal humeral fractures: A systematic literature review. *Open Orthop J* 2010;4:87-92.
54. Poolman RW, Struijs PA, Krips R, Sierevelt IN, Marti RK, Farrokhyar F, et al. Reporting of outcomes in orthopaedic randomized trials: Does blinding of outcome assessors matter? *J Bone Joint Surg Am* 2007;89:550-8.
55. Hróbjartsson A, Thomsen AS, Emanuelsson F, Tendal B, Hilden J, Boutron I, et al. Observer bias in randomized clinical trials with binary outcomes: Systematic review of trials with both blinded and non-blinded outcome assessors. *BMJ* 2012;344:e1119.
56. Sirveaux F, Adam A, Gasse N, Rochet S, Obert L. Interest of the tuberosities reinsertion in complex shoulder fractures treated by reversed prosthesis. Lyon: 23rd Congress of SECEC; 2011. [Abstract].
57. Nicholson GP, Strauss EJ, Sherman SL. Scapular notching: Recognition and strategies to minimize clinical impact. *Clin Orthop Relat Res* 2011;469:2521-30.
58. Sadoghi P, Leithner A, Vavken P, Hölzer A, Hochreiter J, Weber G, et al. Infraglenoidal scapular notching in reverse total shoulder replacement: A prospective series of 60 cases and systematic review of the literature. *BMC Musculoskelet Disord* 2011;12:101.

Source of Support: The first author was supported by a grant from The Danish Agency for Science, Technology, and Innovation,
Conflict of Interest: None declared.