

The development and impact of heterotopic ossification in burns: a review of four decades of research

Rachel Kornhaber^{1,6*}, Nichola Foster^{2*}, Dale Edgar^{3,4,5},
 Denis Visentin¹, Elad Ofir^{6,7}, Josef Haik^{6,7} and Moti Harats^{6,7}

Abstract

Introduction: Heterotopic ossification (HO) is the formation of lamellar bone within connective and other tissue where bone should not form and is a rare complication after burn injury. However, it leads to severe pain and distress, marked reduction in joint range of motion (ROM), impaired function and increased hospital length of stay. The pathophysiology, incidence and risk factors of HO remain poorly understood in burns and other traumas and the management, controversial. The aim of this comprehensive review, therefore, was to synthesise the available evidence on the development and treatment of HO after acute burn injury.

Methods: The review was based on a systematic search of five electronic databases PubMed, EMBASE, CINAHL, LILACS and Scopus.

Results: Synthesis and analysis of the data highlighted that, despite the passage of time, little translatable evidence is available to guide any prevention, screening, diagnostic or pharmacological or physical management protocols.

Discussion: Causes of HO remain confounded, therefore prevention is difficult. Although spontaneous resolution is possible, surgical resection remains the recommended treatment when ROM and activities of daily living are severely affected.

Conclusion: The findings from this review indicate that multicentre data pooling is needed to understand the optimum pathway to prevention, identification and treatment of HO in acute burn patients.

Keywords

Activities of daily living, bisphosphonate, burns, elbow, etidronate disodium, heterotopic ossification, HO, range of motion, review, surgical resection, trauma, ulnar nerve entrapment

¹Faculty of Health, School of Health Sciences, University of Tasmania, Australia

²Sir Charles Gairdner Hospital, Nedlands, WA, Australia

³Burn Injury Research Node, The University of Notre Dame Australia

⁴State Adult Burn Unit, Fiona Stanley Hospital

⁵Fiona Wood Foundation, Australia

⁶Department of Plastic and Reconstructive Surgery, Sheba Medical Center, Tel Hashomer, Israel

⁷Sackler School of Medicine, Tel Aviv University, Tel Aviv, Israel

*These authors contributed equally to this work.

Corresponding author:

Rachel Kornhaber, Faculty of Health, School of Health Sciences, University of Tasmania, Sydney campus, Locked Bag 5052, Alexandria NSW, 2015, Australia.

Email: rachel.kornhaber@utas.edu.au



Lay Summary

Background to this subject: Heterotopic ossification (HO) is the formation of bone within the tissue where bone should not form and is a rare complication after burn injury. However, it leads to severe pain and distress, marked reduction in joint range of motion (ROM), impaired function and increased hospital length of stay. The pathophysiology, incidence and risk factors of HO remain poorly understood in burns and other traumas and the management, controversial.

Question being asked or issue explored: The aim of this comprehensive review was to synthesise the available evidence on the development and treatment of HO after acute burn injury.

Details of how the work was conducted: The review was based on a systematic search of medical electronic databases to identify relevant published literature.

What we did and did not learn from this study: Synthesis and analysis of the data highlighted that, despite the passage of time, little translatable evidence is available to guide any prevention, screening, diagnostic or pharmacological or physical management protocols. Causes of HO remain confounded, therefore prevention is difficult. Although spontaneous resolution is possible, surgical resection remains the recommended treatment when ROM and activities of daily living are severely affected. The findings from this review indicate that multicentre data pooling is needed to understand the optimum pathway to prevention, identification and treatment of HO in acute burn patients.

Introduction

Heterotopic ossification (HO) is a relatively rare complication after burn injury. However, it remains a problematic issue for burn survivors as it causes significant long-term disorders including reduced range of movement (ROM) and function,¹ extreme pain,² and nerve entrapment.³ The etymologic roots of the term HO derive from Greek origins, *heteros topos*, meaning different place and the Latin *ossificatio*, meaning bone formation. Therefore, the literal translation is 'bone formation in another place'.⁴ HO is the development of lamellar bone in non-osseous soft tissue.⁴ It is reported to develop in those with genetic disorders, orthopaedic trauma, traumatic brain and spinal cord injury (SCI), electrocution and burn injuries.^{5,6} Therefore, it is not surprising that the incidence of HO in military patients is reported to be higher than that in civilians⁷ and polytrauma.⁴

Initially described in children in 1692 by Patin,⁸ HO was first reported within the burns literature in 1957.⁹ The prevalence of HO was reported prior to the 1990s as 1.2% but is in the range of 0.2–4%^{1,10–12} with the incidence increasing in larger mean total body surface area (TBSA) cohorts with increasing survival.¹³ However, both Orchard et al.¹⁴ and Hunt et al.¹⁵ highlight discrepancies in the prevalence of HO in burns, with those from a retrospective design demonstrating a lower incidence and a prospective

design reporting a significantly higher incidence of HO. By far the most common sites affected are the elbows resulting in marked reduction in ROM and function, often associated with ulnar nerve compression.¹⁰ Involvement of other joints including shoulders, hips, knees, forearms¹⁵ and the temporomandibular joints (TMJ)¹⁶ have been documented.

Due to the challenge of studying mechanistic pathways with such a low incidence problem in humans, our knowledge of the pathophysiology of HO is primarily informed by animal studies and observations of other patient populations with a relatively greater incidence (orthopaedic, traumatic brain and SCI).¹⁷ The cellular pathways that are most implicated in the formation of pathological ectopic tissue, and the definitive mechanism driving HO deposition, have not yet been established.¹⁸ Current understanding of the pathophysiology of HO implicates the inflammatory process and systemic responses to trauma as contributors to HO, particularly in burns.¹⁷ Burn injury initiates the primary component identified for HO formation: the inflammatory and immune cascade. Inflammation in the affected tissue attracts myeloid cells and lymphocytes that catalyse the release of cytokines.¹⁷ In their study of hip arthroplasty patients, Amar et al.¹⁸ proposed that the cells responsible for triggering HO development were the mesenchymal stem cells (MSC).

Bone morphogenic protein 2 (BMP2) released due to tissue trauma mediates an increase in inflammatory markers, substance P (SP) and calcitonin gene-related protein and causes MSC migration and response to unknown stimuli which in turn results in anomalous differentiation.¹⁸ The recruitment of immune cells provokes local tissue disturbance and results in inflammatory signals that are proposed to increase osteogenic differentiation of MSCs, potentially resulting in heterotopic bone deposition.¹⁸ The disease may include pericapsular calcification, predominantly overlying tendons and in the planes of ligaments. New bone formation may also include osteophyte formation adjacent to joints, periosteal new bone formation and intra-articular or extra-articular ankyloses.¹⁹ Presumably due to the lack of clarity about the pathophysiology of HO in burn patients, treatment options and timing are also a controversial area.^{20,21} Given the impact that HO has on burn survivors, their families and health professionals, burns and rehabilitation clinicians including surgeons, intensivists nurses, allied health professionals, social workers/psychologists/psychiatrists and rehabilitation specialists need to collectively address these significant issues of HO. Furthermore, other professionals such as bio-engineers and bio-scientists, also need to collectively collaborate in an attempt to understand the pathophysiology of this condition. Therefore, the purpose of this comprehensive review was to critically appraise and synthesise the available literature on the development, treatment and impact of HO in burn survivors.

Methods

A systematic and rigorous search across the electronic health databases PubMed, EMBASE, CINAHL, LILACS and Scopus was conducted in May 2016. The databases utilised encompass a wide-ranging and multidisciplinary span of research across the healthcare domain. Boolean connectors AND, OR and NOT were used to combine search/MeSH terms and keywords including burn*, thermal injury, heterotopic ossification, HO. The reference lists of all included papers were examined to identify any potential papers not captured through the initial search strategy and full text articles were retrieved when possible.

Inclusion and exclusion criteria

The search criteria for this comprehensive review incorporated peer-reviewed primary research published in English that identified the development

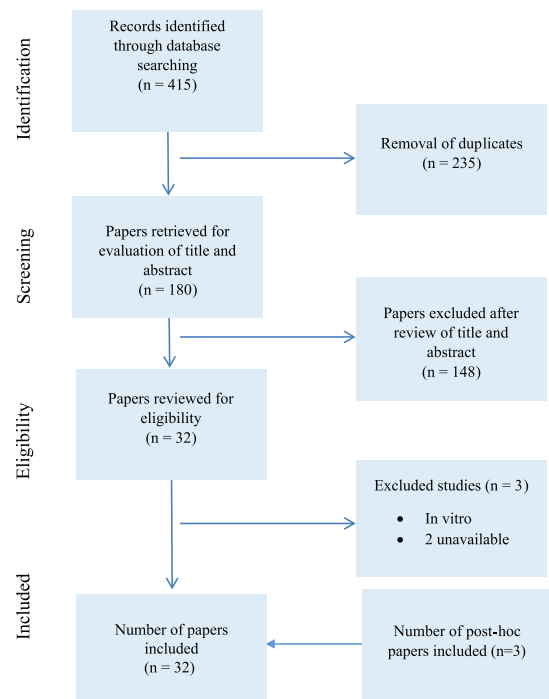


Figure 1. Decision trail of included studies.

and treatment of HO. No parameters concerning year of publication were imposed so as to capture the depth and breadth of data. Animal studies, reviews, conference proceedings and editorials were excluded. Higher level evidence was summarised and synthesised. In the absence of higher level evidence, case studies and case series were included.

Data evaluation and extraction

A total of 415 references were downloaded into EndNote X8. After duplicates were removed, the search strategy identified 180 prospective papers (Figure 1). Authors EO and RK identified 32 potential papers through the evaluation of titles and abstracts. A further study was identified via searching the reference lists of included papers. Based on the inclusion criteria, authors RK, DV and EO independently reviewed the relevant papers. Any disparities were determined by collaborative discussion until consensus was reached. Through this systematic and rigorous process, three studies were subsequently removed. Authors DE and NF reviewed the included studies and assimilated the 'Results', 'Discussion' and 'Conclusion'.

A total of 32 papers were systematically summarised and synthesised. Findings from the studies were analysed and developed into key domains as to enable the recognition of recurring relationships across data. Data extracted

included author(s), year of publication, country of origin, design, purpose of study, sample and study population, data collection and analysis and significant findings/outcomes (Table 1), and case series and reports were tabled separately (Table 2).

Results and discussion

Study report and pooled sample characteristics

The clinical sample amassed in this comprehensive review included 545 burns patients diagnosed with HO of which the majority were men. Of the 32 studies, 14 were retrospective cohort, 14 were case series or case reports, two case control studies, one prospective study and one registry-based study were included in the review. This comprehensive review did not identify any meta-analyses or randomised control trials. Thus, the evidence available regarding HO in burns was low (level III–IV) with only one study, comparing HO excision surgery outcomes, identified at level II.

Studies captured spanned four decades from 1972 to 2015, with nine studies and five case reports documented in the last 16 years and nine studies and nine case reports prior to the year 2000 emphasising the dearth of literature in the domain of HO and humans with burn trauma. Excluding the case reports, the pooled study sample of 412 patients (82% men) had a mean age of 37 years (age range, 8–62) and mean TBSA of 48% (range, 8–95%) (Table 3). The studies had a range of 7–98 participants. Studies mainly emanated from the USA; however, other study reports arose from Israel, Canada, South Africa, Australia, New Zealand, France, Germany, Spain, India, and China and Taiwan (Table 1). The included studies did not consistently report all required data, including mean values and standard deviations, gender of subjects and the size of the sample population, limiting the ability to pool data.

While the case series and reports described in more detail the burn patient with HO, 18 studies investigated several domains including pathogenesis of HO, incidence and risk factors in the formation of HO, diagnosis, therapeutic management, surgical outcomes and function post removal of HO and delayed wound closure and HO formation.

Case series and reports

Case series/reports allow the identification of rare clinical conditions and provide a thorough

review on important topics.²² Of the 14 case series and reports included in this review (Table 2), ten were single-participant case reports and four were case series with two to four participants. Patients represented in the case series/reports were predominately men with only one woman identified. In contrast to the group-wise data, the case reports included a child of 12 months and an older adult of 68 years. As a cohort, the case report patients remained within the same TBSA range (30–86%) and depth of burn as in the pooled sample. The case reports identified the elbow as the most commonly involved joint but also described diagnosed HO in shoulders, knees, hips, hands, temporomandibular joint and more obscure areas such as the chin and vocal cords. Pre-surgical complications included significantly limited ROM, pain and one case of ulnar nerve entrapment. ICU admission was stated in six reports with three involving ventilation and three reporting sepsis. However, despite the depth and the size of the burn, ICU was not stated in several reports which may indicate omissions in reporting. Serum alkaline phosphate was reported within normal limits in some reports and elevated in others. Confirmed diagnosis of HO, in 1–4.5 months, was established by X-ray, bone scan and CT. Surgical intervention was described in seven of the reports with physiotherapy active and passive movement and static splinting the most common postoperative regime. Time to follow-up was in the range of 4 months–4 years in the cases where this was reported. Studies reported post-intervention ROM ranged from no improvement to the return of full ROM.

Risk factors for the development of HO

The studies identified an HO incidence in the range of 0.15–4.7% but repeatedly noted as 1.2% before 2000^{23–26} and $\geq 3.5\%$ in later years.^{6,17} The overall prevalence from the pooled sample was 2.0% (Table 3). The reviewed literature consistently identified severity of injury as a risk factor with the most strongly implicated markers being: TBSA (13% increase risk per % surface area); full thickness or deep dermal burn; ICU stay and/or mechanical ventilation; and inhalation injury. In more recent studies with enhanced statistical analysis methods, greater risk of HO was associated with: increased time to wound closure (8% increased risk per day); delayed grafting; and number of surgical episodes. These factors interact with delayed time to commencing physiotherapy and active ROM, immobilisation timeframes and contracture which have also

Table 1. Summary of included studies.

Author/s, year and country	Design	Purpose	Sample and study population	Data collection method	Method of analysis	Significant findings and outcomes
Chen et al. (2009) Taiwan	Retrospective cohort	To evaluate treatment and outcomes of HO	n = 12 burn patients (10 men; 2 women); mean age was 43 ± 9 years (range, 30–59 years); mean TBSA was 39 ± 28% (range, 8–90%); 9 were admitted to ICU; 6 mechanical ventilation; mean ICU stay 82 ± 76 days (range, 26–240 days); 75% flame burn; 8% scald burn; 8% contact burn; 8% high voltage electrical injury	Medical records of burn patients diagnosed HO between June 2000 and September 2007	Descriptive statistics	Elbow most affected joint (n = 11; 92%) with pre-op ROM range 0–75°; knee (n = 1; 8%); HO diagnosed via examination and X-ray; CT used pre-op to confirm anatomical location; ALP, calcium and phosphorous no significant elevation; burn to diagnosis range 3–24 months with a mean of 10 ± 6 months; mean ROM before surgery 31 ± 27° (range, 0–75°); mean ROM after surgery was 99 ± 15° (range, 70–115°); mean gain of ROM 68 ± 25 (range, 35–115°); one patient experience reoccurrence of HO 3 months post operatively; the incidence of HO reported to be 0.15%; mean ICU stay = 82 ± 76 days (range, 26–240 days); if neuropathy or < ROM impacted ADLs surgical resection indicated; delayed wound healing and presence of HO
Crawford et al. (1986) USA	Retrospective cohort	To document the incidence and effect of routine therapeutic exercise, both active and passive, during the recovery period	n = 12 (11 men; 1 woman); 13 joints; posterior around elbow joint; mean age, 35 years (range, 21–53 years); TBSA mean 49% (range, 20–85%); sudden decrease in ROM with concurrent joint pain during movement and approximation; 10 flame burns, 1 electrical, 1 scald; 8 given daily passive ROM; 4 active or passive ROM; arms in full extension with forearms in supination; once HO clinically diagnosed, continuation of daily active ROM within pain-free range	10-year review of medical records and X-rays of 1066 burn patients	Descriptive statistics	All HO formed posterior around elbow joint; conservative management resulted in positive outcomes in 6 patients; bone scans showed increase activity around elbow when X-rays were negative; clinical diagnosis of HO 4–32 weeks post burn; time from burn to positive X-ray 5–56 weeks; average time of onset 12 weeks; loss of ROM 40–135°; diagnosis was via X-ray; depth around elbow full thickness in 11/12 patients; 6 required surgery; diagnosis to surgical excision 4–22 months (mean, 11 months); surgical intervention based on: 1. decreased ROM causing functional loss; 2. maturation of new bone confirmation; 3. no acute inflammation; 4. healing of skin around HO; significant improvement in ROM and function post-surgical removal; entrapment of ulnar nerve complication; the incidence of HO reported to be 1.2%; EMG confirmed ulnar entrapment in 2 patients

(Continued)

Table 1. (Continued)

Author/s, year and country	Design	Purpose	Sample and study population	Data collection method	Method of analysis	Significant findings and outcomes
Dias (1982) India	Retrospective cohort	To review heterotopic para-articular ossification of the elbow with soft-tissue contracture in burns	n = 9 (women); mean age 25.4 years (range, 18–40 years); mean TBSA 28.3% full thickness (range 20–45%); 11 elbows (2 cases bilateral); 6 cases had no movement fixed at 90–100° flexion; 3 cases had only 5° movement	Medical records of burn patients diagnosed with HO in 1971–1974	Descriptive statistics	X-ray confirmed; 6 cases were operated 4–6 months post burn; 3 cases were operated 2–3 years post burn; bone fully consolidated with matured scars; follow-up 2–6 years; 7 cases regained full movement with all experiencing no reoccurrence of bone
Djurickovic et al. (1996) Canada	Retrospective cohort with long-term follow-up	To review the results of surgical management of HO about the elbow in burned patients	n = 8 (5 men; 3 women) burn patients with HO of the elbow (11 elbows); all elbows were approached by a posterior incision and exposure of the ulnar nerve; 5 men and 3 women had long-term follow-up; mean age 39 years (range, 24–55); mean TBSA 48% (range, 23–75%); mean time to excision post burn 12 months (range, 2–23 months)	Medical records of burn patients diagnosed HO between 1 January 1982 and 31 December 1993 of 1855 burn patients	Descriptive statistics	Mean maximum flexion pre-op $69 \pm 8^\circ$ compared with post-op $126 \pm 7^\circ$, $P < 0.001$; mean maximum extension pre-op $58 \pm 7^\circ$ compared with post-op $38 \pm 8^\circ$, $P = 0.07$; mean ROM pre-op $11 \pm 5^\circ$ compared with post-op $89 \pm 12^\circ$, $P < 0.001$; mean ROM forearm rotation pre-op $126 \pm 20^\circ$ compared with post-op $164 \pm 5^\circ$, $P = 0.1$; incidence of HO 1.2%
Elledge et al. (1988) USA	Retrospective cohort	To review the incidence diagnostic methods and therapeutic approaches regarding HO	n = 63 (60 men; 3 women); average age 31.6 years; mean burn size 44.6%; TBSA range 12–81%; average TBSA 44.6%; full thickness burn range 0–73%; average full thickness 21.1%; average LOS 148.6 days	Medical records review during 1967–1985 of 5031 burn patients	Descriptive statistics	97 sites of HO; HO presented with decreased ROM; X-ray confirmation of HO; 1.2% incidence; elbow is the most frequent site for formation of HBF (82.5%); HO in full thickness in 59%; HO in partial thickness 31%; HO in 71% of grafted joints; initial treatment physical therapy; 20 joints surgically excised; HO is more likely to occur in the area of burn due to immobilisation and contracture secondary to pain; HO occurred mostly in areas grafted late after burn injury

Table 1. (Continued)

Author/s, year and country	Design	Purpose	Sample and study population	Data collection method	Method of analysis	Significant findings and outcomes
Gaur et al. (2003) USA	Retrospective cohort	To review elbow function following excision of severe HO around elbow in children	n = 7 children (9 elbows); 4 elbows fused; average age 12.5 years (range, 9–15 years); 1 sustained high voltage electrical burn; all full thickness burns; average TBSA 72% (range, 44–85%); pre-op ROM 12° (range, 0–30°) with 4 elbows with no ROM; excision of HO if limitation of function and movement restricted to arc of motion < 50° post-op treatment continuous passive motion, alternating splinting; active assisted ROM exercises; diagnosis via physical examination and X-ray and CT; pain used as an indicator of the maturity of the bony lesion	Medical records review during January 1985–December; 1996 of 3245 paediatric burn patients	Descriptive statistics	HO found in the medial aspect, posterior to the medial epicondyle and extending into the medial olecranon fossa; surgical intervention performed at 17.3 months (range, 8–32 months; follow-up average 56 months (range, 3–10 years) with improved ROM (average increase of 57°); HO did not recur post removal
Hoffer et al. (1978) USA	Retrospective cohort	To review excision of HO about elbows in patients with thermal injury	n = 12; range, 8–52 years (9 in third and fourth decade); 5–75% full thickness; 15 elbows; 3 shoulders; 3 hips; 2 hands; either pericapsular / periarticular/across a bony bridge only two sites occurred in locations distant from the burn	Medical records of burn patients diagnosed HO during 1972–1975 of 175 burn patients	Descriptive statistics	X-ray; recognition of HO range of 3 months to 7 years; 15 joints treated by physiotherapy alone active and resting splints in flexion and extension; 8 elbows surgical excision with ulnar nerve lesions; follow-up range 11–52 months; no significant reoccurrence of excised bone; marked improvement in upper extremity function; 7 reached maximum ROM at 4 months post-op; burns scar and healed grafts; 3 ulnar nerve lesions
Holguin et al. (1996) Spain	Retrospective cohort	To review elbow ankyloses due to HO in burn injured patients	n = 6 (3 women; 3 men); mean age 34.7 years (range, 24–45); mean TBSA 51%; mean deep dermal full thickness 45%; 2 ventilated; long periods of immobilisation; passive and active joint movement; average 8.6 months from burn to complete elbow ankyloses; block of ROM range 30–95° of flexion; calcification seen on X-ray on posterior	Medical records review during 1970–1994 of 2280 patients	Descriptive statistics	3 patients with ulnar entrapment; follow-up range 6 months–22 years; complete resection of HO led to a very good outcome in 5 patients (6 elbows) average relative gain of 73.6%

(Continued)

Table 1. (Continued)

Author/s, year and country	Design	Purpose	Sample and study population	Data collection method	Method of analysis	Significant findings and outcomes
Hunt et al. (2006) USA	Retrospective cohort	To review the results of surgical treatment of patients with HO including diagnosis, timing of surgery and technique and outcomes	42 patients; mean age was 38 ± 14 years (range, 22–62 years); mean TBSA was 55 ± 23% (range, 10–95%); mean third degree burn 37 ± 25%; elbow most frequent site (>90%); 44% bilateral elbows; 34 patients received ventilation; 86% admitted to ICU; mean ventilated days 58 ± 47; mean ICU days 79 ± 56; mean total LOS 89 days (range, 26–349 days); 90% flash/flame; 3% scald; 7% high electrical burn	Medical records review for ABA verified burn centre over 21 years containing 9874 acutely burn patients	Descriptive statistics	< ROM; painful joint, localised swelling and nerve deficit; X-ray to confirm diagnosis; majority of burns overlaying with HO associated with prolong wound closure, depth of injury, wound infection or graft loss; mean day of diagnosis was 71 days (range, 12–134 days); mean elbow arc motion pre-op 52° and post-op 119°; 70% elbows ankylosed; CPM device post-op; maintaining ROM difficult in 75% of patients; reoccurrence in 4 elbows and 1 forearm
Klein et al. (2007) USA	A matched case-control study	To examine the relationship between delay in elbow wound closure and the development of HO	n = 45 adult burn patients (84% men, 16% women); average age of 37 ± 14.2 years; partial or full thickness upper extremity burns; 53% had bilateral HO of the elbow; average TBSA 44.6 ± 15.2%; 82% were right hand dominance; average of 50 days for diagnosis of HO after admission (SD 21; range, 5–106); time to wound closure	Medical records review during 1980–2005 of 5868 burn patients	Paired student's t-test for continuous variables; χ^2 for discrete variables	Wound closure appeared after 48.7 ± 24.7 days in the HO group vs. 24.7 ± 2.4 days in the control group with adjusted OR of 1.08 (95% CI 1.04–1.12, $P < 0.01$); 97% of the HO group were grafted vs. 88% from the non-HO group; higher regrafting rate was noticed in the HO group compared with the non-HO group (85% vs. 22%, $P < 0.01$); all HO patients had deep, partial or full thickness upper extremity burns; formation of HO was diagnosed after 50 ± 21 days and 64% of wounds were open at the time of diagnosis; each day wound remained open, the adjusted odds of developing HO > by 8% (OR 1.08; 95% CI 1.14–1.12); HO incidence = 0.8%
Levi et al. (2015) USA	Retrospective case control study	To evaluate the incidence and risk factors related to HO and burn injury to predict patients at risk	n = 98 (81 men; 17 women); mean age 42.4 ± 13.3; mean age of men 42.4 years; mean age of women 44.8 years; median TBSA 47% (IQR 28%) 85% flame; 3% chemical; 2% scald; 1% contact with hot object; 3% chemical; 74 mean days; 73.5% white; 7.1% black; Hispanic 11.2%; Asian 3.1%; 97% had arm burns; 96% had arm graft	Data from 6 burn centres during October 5 1993–June 30 2013 from 4137 eligible adult burn patients	Continuous variables; mean (SD), median and IQRs, sample distribution with unpaired t-test; Kolmogorov–Smirnov test used to assess distribution of categorical variables; univariate analysis; multivariate logistic regression	3.5% developed HO; larger TBSA (adjusted OR 1.07 per 1% increase in TBSA $P < 0.001$, (especially > 30% [OR 11.5, $P < 0.001$]), days on ventilator (OR 1.04, $P < 0.001$) joint contractures (OR 41.2, $P < 0.001$), exposed bone, inhalation injury (OR 4.6, $P < 0.001$), contracture, burns requiring skin grafts (OR 96.4, $P = 0.04$) and the number of visits in the operating room (OR 1.32, $P < 0.001$) are all risk factors for HO formation

Table 1. (Continued)

Author/s, year and country	Design	Purpose	Sample and study population	Data collection method	Method of analysis	Significant findings and outcomes
Medina et al. (2014) Canada	Retrospective cohort	To review the incidence of HO, diagnostic methods, therapeutic approaches including surgical timing and techniques	n = 17 (14 men; 3 women); mean age 33.6 ± 3.4 years (range, 10–59 years); flame burn (88.2%); high voltage electrical burn (11.8%); mean TBSA 60.1 ± 4.1% (range, 20–90%) 46.9% full-thickness TBSA (range, 10–85%); mean hospitalisation time 128.8 ± 14.5 days (range, 63–312 days); ventilated dependent (88.2%); graft loss (76.5%); sepsis (64.7%); wound infection (47.1%); multiple surgeries (7.9 ± 3.5) average pre-op ROM was 45.6 ± 10.5°; HO suspected > ROM with locking sensation, swelling and localised pain	Medical records review during the years 1982–2012	Two-tailed paired t-test	Elbow most frequent joint involved (62.8%); shoulder (9.3); forearm (6.9%); knee (6.9%); some sites distant from the burn injury; 23.5% received EDHP 400–800 mg daily for 3 months; a total of 10 lesions were surgically excised; surgical excision performed 1.5–16 months post injury; physiotherapy post-op including passive and active ROM; follow-up for at least 2 years (mean 80.1 ± 16.7 months); average post-op ROM 45.6 ± 10.5° reaching 110 ± 8.7° after 3 months post-op; surgical intervention added an average of 64.9 ± 6.8%; local reoccurrence of 30%; X-ray, bone scan (47%), CT (12%), MRI (12%) confirm HO; mean LOS 128 ± 14.5 days
Munster et al. (1972) USA	A prospective study	To re-evaluate pathogenesis factors of HO	n = 12 burn patients; 18 upper limbs; TBSA 9–65%; mean TBSA 39.3%; (smallest TBSA developed HO 14%)	Survey 180 limb in 100 patients during 1969–1970	Statistical analysis (unpaired t-test)	18 limbs in 12 patients developed HO – 13.6% arms and 11.25% upper limbs; 13/18 limbs spontaneously resolved to normal ROM; remaining 5 limbs required surgical intervention; 16 (22%) developed HO in full thickness limbs; only 2/87 (2.4%) limbs without full thickness burns developed HO ($\chi^2 = 12, P < 0.01$); development of bilateral elbow calcification in unburned limbs; loss of ROM mean time of 43 days post burn; first noted roentgenological evidence at a mean of 48 days post burn; early signs – loss of active ROM 7 (18%) developed HO with immobilisation > 2 weeks with routine physical therapy; 5 (10%) developed HO who were not immobilised (not statistically significant $\chi^2 = 69, P > 0.5$); mean serum Ca 8.63 mg/100 mL and 8.08 mg/100 mL in those without HO ($t = 2.10, P < 0.05$); mean alkaline phosphate 14.02 K-A units HO patients and 18.48 K-A units without HO ($t = 2.11, P < 0.05$)

(Continued)

Table 1. (Continued)

Author/s, year and country	Design	Purpose	Sample and study population	Data collection method	Method of analysis	Significant findings and outcomes
Orchard et al. (2015) Australia	Retrospective matched case-control	To identify the risk factors for developing HO in patients with burns injuries; to review the outcomes associated with disodium etidronate treatment	n = 16; mean age 43 years (range, 32–48 years); mean TBSA 46% (range, 37–65%); inhalation burn 10 (53%); 18 (95%) ICU admission; ICU LOS 22 days (range, 15–34 days); 18 (95%) ventilated; length of ventilation 24 days (range, 13–33 days); 10 (53%) escharotomies; number of surgeries 9 (range, 5–11); 19 (100%) grafted; 19 (100%) HO to grafted limb; 19 (100%) sepsis	Medical records review during September 2002–September 2007 of 337 burn patients	Mann–Whitney U-test for comparison on continuous variables; categorical data Fisher's exact test or Chi-square; multivariate analysis	HO developed clinically and radiologically after a median time of 37 days and 49 days, respectively; HO associated with > TBSA; inhalation injury, use of mechanical ventilation, number of surgeries, sepsis and longer period to active ROM; severity of burn (Belgium Outcome in Burn Injury Score) – time to active ROM was recognised as an independent risk factor for HO (OR 1.48; 95% CI 1.09–2.01)
Peterson et al. (1989) USA	Retrospective cohort	To improve recognition and management of HO	n = 18 (15 men; 3 women); mean age 37 years (range, 21–61 years); 17 elbows; 1 shoulder; mean TBSA 43% (range, 8–85%);	Medical records review from 1478 consecutive admissions of burn patients	Descriptive statistics	Incidence of HO 1.2%; presented with > localised joint pain and < ROM then progressed to functional limitations; 17 presented with HO in elbow; 1 HO presented in shoulder; average ROM pre-therapy 46° and post-therapy 124° (10 patients); pre-op ROM 6° and post-op ROM 110° diagnosis average 10 weeks (range, 4–32 weeks); time between clinical and radiographic diagnosis mean 14.7 weeks; prior to diagnosis treated with active and active-assisted ROM; 2 cases of ulnar nerve entrapment; lag time between clinical diagnosis and surgery 4–22 months; average follow-up after surgery was 35 months with no reoccurrence
Shafer et al. (2008) USA	Retrospective cohort	To assess the efficacy of etidronate disodium (EDHP) in preventing HO	n = 57 burn patients 28 EHDP group; 29 non-EHDP group (23 men, 5 women); mean TBSA 49.2 ± 18.5; non-EHDP group TBSA 36.2 ± 13.0; treated with 300 mg twice daily	Charts of all adult patients with 25% or greater TBSA burns for a 3-year period; identified patients who received EDHP and compared with group who did not receive EDHP	Logic regression analysis	HO developed in 13 (46.4%) of EHDP group; HO developed in 4 (13.8%) of the non-EHDP group; HO developed in elbows; duration of EDHP treatment 30.0 ± 24.5 days; EHDP group longer hospital stay; mean EHDP treatment 39 days

Table 1. (Continued)

Author/s, year and country	Design	Purpose	Sample and study population	Data collection method	Method of analysis	Significant findings and outcomes
Vanlaeken et al. (1989) Canada	Retrospective cohort	To assess the contributing factors that predispose burns to HO	n = 7 burns patients; smoke inhalation; mean age 35.7 ± 23.4 years; mean TBSA% 49.7 ± 13.2 ; TBSA full thickness $30.9 \pm 15.0\%$; intubation and ventilator support 34.1 ± 23.4 days; passive ROM to all joints every 4–6 h; splinting with elbows extended and shoulders abducted; 4 patients requiring sedation for extreme agitation; nasogastric feeding immobile 7 days post grafting; bone scans 3 weeks after upper extremities burns	Medical records review from January 1984 to December 1985; 25 ventilated patients	Student's <i>t</i> -test; Fisher exact probability to compare incidence; multivariate statistical analysis with Cox's logistic regression	57% of developing HO with agitation; 94% chance to not develop HO if agitation absent ($P \leq 0.05$); diagnosis X-ray; bone scan false positive of 61%; bone scan sensitive but not specific; the average level of serum protein was higher in the HO group; the level of the serum albumin, calcium; phosphate, magnesium and zinc were equal in HO and non-HO groups
Tsionos et al. (2004) France	Retrospective cohort	To describe the outcome of early excision of HO around the elbow	n = 28 (19 men; 9 women); 35 elbows; mean was 42 years (range, 17–59); average TBSA% was 49% (range, 12–83%); average pre-op range in flexion–extension was 22.5% and in pronation/supination was 94%; the mean delay between burn to excision 12 months (range, 4–43.5 months); median delay 9.5 months; waited until wound heal in elbow region prior to excision; 26 intubated from 2–14 weeks; average follow-up was 21 months	Medical records review from 1992 to 2001	Single or paired <i>t</i> -test according to the groups compared; non-quantitative data were compared using Chi-squared test; level of significance set at 0.05	11 (31%) elbows associated with signs and symptoms of ulnar nerve entrapment; X-ray and CT; mean pre-op ROM 22° in flexion/extension; 94°; in pronation/supination; post-op mean ROM 123° in flexion/extension; 160° in pronation/supination; clinical evidence of reoccurrence in 4 patients within first 2 months after excision

Table 2. Available case reports and case series of HO in burns trauma.

Author/s, year and country	Total number of patients/gender	Age of patients	TBSA (%) and depth of burn	Joint affected	ROM	Diagnosis and treatment	Follow-up	Outcome
Bozkurt et al. (2010) Germany	1 man	29 years	60% deep partial/full thickness burns	Left knee	Daily physiotherapy; local swelling of knee, pain joint stiffness and limited ROM	High voltage electrical burn; escharotomies; X-ray at day 40 revealed ossification of medial part of both quadriceps muscle distally; confirmed by CT bilateral knees; electromyography and nerve conduction revealed an incomplete lesion of the left common peroneal nerve; delay in surgery; indomethacin 50 mg 3 times daily for 30 days; 1 day prior to surgery 7 Gy to knees HO surgically removed	4 months	Recovery of dorsiflexion strength; full ROM with sensory re-innervation recovery in dorsum foot
Coons and Godleski (2013) USA	1 man; 1 woman	23 years; 37 years	72% full thickness; 82% full thickness	Bilateral elbows 3 and 6 months after injury	Unable to perform elbow flexion past 90–100°	X-ray female non-surgical; male etidronate 12 weeks and bilateral excision; ICU admission; prolonged ventilation; clinical diagnosis 2 months post burn	3 years; 4 years	ROM full flexion bilaterally with exception of 10% of terminal extension for both cases
Engber and Reynen (1994) USA	4 patients	Average 41.5 years (range, 25–64 years)	Not reported	6 elbows (2 bilateral)	Pain and stiffness; 4 elbows ankylosed 35–50°; 3 elbows ROM 35–135%	X-rays; clinical examinations; interviews; surgical intervention at an average of 8.3 months	Average 79 months; follow-up range, 27–126 months	Average active ROM improved from 6° to over 90° post-op during the first 6 months then plateaued; all elbows obtained at least 100° of active motion with the average 121°
Jay et al. (1981) USA	1 boy	12 months	38% partial thickness	Bilateral shoulders; left elbow; left hip	15° loss of flexion and abduction of shoulders; 45° loss of flexion to left elbow; 30° flexion contracture left hip limitations abduction and internal rotation	X-ray 2 months after burn injury	Not reported	Not reported

Table 2. (Continued)

Author/s, year and country	Total number of patients/ gender	Age of patients	TBSA (%) and depth of burn	Joint affected	ROM	Diagnosis and treatment	Follow-up	Outcome
Koch et al. (1992) USA	2 boys	5–6.5 years	85–86%	Bilateral elbows; shoulders; knees; hands; ankles	Severe limitations in ROM; pain	Bone scan; > serum alkaline phosphatase; anti-inflammatory; etidonate sodium; physiotherapy; occupational therapy; splinting; casting; garments	Not reported	Returned to school; awaited heterotopic bone to matured prior to surgical intervention
Lippen et al. (1994) Israel	1 man	38 years	45%; (22% partial 23% full thickness); smoke inhalation	Vocal cords and bilateral ankles (no burns to ankles)	Pain and limitation of movement of bilateral ankles; limited mobility of both vocal cords	Ventilated; sepsis; ankles (not burned) extraarticular ossifications; technetium 99 scan increased uptake cricoid cartilage, bilateral ankle joints and left elbow; CT ossifications around cricoarytenoid joint and treated with diphosphonate 2 mg/kg/day period 1 month and 10 mg/kg/day thereafter	Lost to follow-up 6 months later	Not reported
Nassabi et al. (1996) Germany	1 man	55 years	50% full thickness	Bilateral shoulders; elbows; knee joints; hands	Pain and significant reduction in ROM	ICU admission; long-term ventilation; sepsis; X-ray and CT 4.5 months after injury; extensive but gentle physiotherapy; poor health status not suitable for surgical intervention	Not reported	No significant change in ROM
Price et al. (2010) South Africa	1 boy	13 years	71% full thickness	Bilateral elbows	Weeping synovial fluid with graft loss; ROM not stated	X-ray; CT; ICU admission; sepsis; intubation; surgical excision	Follow-up stated no time frame given	Significant improvement following surgical excision
Richards and Klaassen (1997) New Zealand	3 men	21, 30 and 55 years	40%, 75% and 80%; depth not reported	Elbows; shoulders; knees	Swelling; stiffness; decreased ROM	ICU admission, multiple surgeries; clinical diagnosis post burn 1–2 months; > alkaline phosphatase X-rays; planned capsular excision	Not reported	Await planned capsular excision

(Continued)

Table 2. (Continued)

Author/s, year and country	Total number of patients/ gender	Age of patients	TBSA (%) and depth of burn	Joint affected	ROM	Diagnosis and treatment	Follow-up	Outcome
Rubin and Cozzi (1986) USA	1 boy	17 years	30% partial and full thickness	TMJ	Complete inability to open mouth	X-ray; wound sepsis; bilateral anthroplasty with interpositional placement of silastic secured to ramal stumps with bone screws followed by oral physiotherapy; 4 years later further surgical treatment and a further 3 years on surgical treatment followed by radiation therapy 2 Gy 5 days	Initially lost to follow-up; presented 4 years later then again 3 years later	Initially regained ROM then presented 4 years later with inability to open mouth (non-compliant post-surgery); 3 years further on new bone formation identified; poor outcome 1 cm opening of mouth achieved
Tepperman et al. (1984) Canada	1 man	37 years	Full thickness between 45%	Bilateral elbows and shoulders	Pain; right elbow fused 100°; left elbow ROM 85–95%	Bone scan and X-ray; sepsis; > alkaline phosphatase and ESR; physiotherapy; splinting; surgical intervention; etidronate disodium	Follow-up bone scans and X-ray at 3-month intervals up to 1 year post burn	Acceptable ROM with physiotherapy
Vorenkamp et al. (1987) USA	1 man	65 years	30% full thickness	Right elbow	Pain and stiffness about the elbow, weakness of hand, numbness of ulnar innervated digits; elbow flexed to 60°; lacked 15° of full extension; full pronation; 30° lack full supination	X-ray; nerve conduction studies; surgical intervention	18 months post surgery	Further loss of ROM post-op flexing and extending from 65° to 80°; no pain; ulnar nerve sensitivity returned
Zaman (2012) Australia	1 man	19 years	61% partial/ deep and full thickness	Bilateral elbows	Limited ROM 5 weeks post injury stiffness and pain	X-ray anti-inflammatory and etidronate 1800 mg daily 3 months	To be followed up in 12–18 months	Awaiting surgical intervention; continued reduced ROM
Zou et al. (2011) China	1 man	68 years (burnt at the age of 20 years)	Not declared; extensive scarring of skin and subcutaneous tissue over facial area	Skin graft in a post burn scar of the chin	Chin arising within skin graft	CT; rectangular calcification under an ulcer of the lower jaw	Not reported	No post-op reoccurrence

Table 3. Summary of descriptive studies.

	n	Age (years)					TBSA (%)					Prevalence (%)		
		Total	Male	Female	Mean	Min	Max	SD	Mean	Min	Max	SD		
Chen et al. (2009)	12	10	2	43	30	59	9.0	39	8	90	28	0.15		
Crawford (1986)	12	11	1	35	21	53	-	49	20	85	-	1.20		
Dias (1982)	9	0	9	25.4	18	40	6.8		20	45	-	0.30		
Djurkovic et al. (1996)	8	5	3	39	22	55	9.7	48	23	75	16.3	1.29		
Elledge et al. (1988)	63	60	3	31.6	-	-	-	44.6	12	81	-	1.20		
Gaur et al. (2003)	7	-	-	12.5	9.9	15.9	-	72	44	85	-	-		
Hoffer et al. (1978)	12	-	-	-	8	52	-	-	-	-	-	6.86		
Holguin et al. (1996)	6	3	3	34.7	24	45	9.0	51	30	60	12.5	0.26		
Hunt et al. (2006)	42	-	-	38	22	62	14.0	55	10	95	23	0.43		
Klein et al. (2007)	45	38	7	37	-	-	14.2	44.6	-	-	15.2	0.80		
Levi et al. (2015)	98	81	17	42.4	-	-	13.3	47	-	-	28	3.50		
Medina et al. (2014)	17	14	3	33.6	10	59	3.4	60.1	20	90	4.1	-		
Munster et al. (1972)	12	-	-	-	-	-	-	-	9	65	-	-		
Orchard et al. (2015)	16	16	0	43	32	48	-	46	37	65	-	4.75		
Peterson et al. (1989)	18	15	3	36.9	21	61	10.9	45.8	8	85	22	1.22		
Vanlaeken et al. (1989)	7	-	-	35.7	-	-	23.4	49.7	-	-	13.2	-		
Tsionos (2004)	28	19	9	42	17	59	-	49	12	83	-	-		
Summary	412	272	60	37	8	62		48	8	95		2.0		

*Results for Shafer et al. (2008) are not included in this table as the study did not report data for HO and non-HO separately.

been implicated in recent studies. There were exceptions to these high-risk categories. For instance, HO was reported in non-burned elbows.²⁸ Schneider et al.,¹⁷ using data from the same database as the Levi et al.¹² study, established a validated risk-scoring system for HO. Location of grafts and percentage of TBSA were found to impact HO risk while other variables were not found to increase the risk of HO.¹⁷ The percentage of TBSA had the greatest impact on HO risk in this study with an increase of 10% in TBSA providing an increase of 1 point in their risk scale. Furthermore, graft location at the arm, head/neck or trunk providing 1 point in the risk scale, although other graft and burn areas in general were not associated with an increased risk.¹⁷ Site of burns, grafts and HO are not consistently reported in the surveyed case-control studies and hence do not allow pooled data to be generated for these important measures. Burn aetiology, age and gender were not found to be predictors of HO risk in their analysis.

Anti-contracture positioning and splinting is commenced immediately in most burn services. Prolonged pressure on high HO risk areas during immobilisation has been implicated as a potential predictive factor in the development of the complication.²⁷ In addition, the intubated patient is unable to communicate to health professionals, so there may be unrecognised, excessive pressure on the posterior aspect of the elbow joint.¹⁹ Munster et al.²⁸ described the most common occurrence of HO as just posterior to the distal end of the humeral shaft, in the olecranon fossa, and anterior to the insertion of the triceps muscle. They further note that calcification often then spreads to the medial epicondyle of the humerus and occasionally in the lateral structures as well. Levi¹² noted that certain anatomical aspects of the elbow joint, including the superficial ulnar nerve may increase risk of HO through a pathway of neurogenic inflammation. Further supporting mechanical compression as a contributor to risk is the frequent use of the elbow for leverage and the constant pressure on the elbow in immobilised patients which is commonly positioned with the arm in extension and forearm supinated.²⁷ Lastly, anatomically, the elbow joint is an articulation of two joints in one capsule permitting 2° of freedom for the upper limb.²³ In contrast to most other joints, even in sedentary individuals, the elbow is accustomed to frequent, large arc movements.²³

Given that the pathophysiology of HO is linked to an imbalance of factors leading to abnormal calcium phosphate deposition in tissues, some have tried to isolate whether serum

calcium, phosphorus and alkaline phosphate levels can be interpreted to reliably diagnose HO or identify those at risk.¹² To date, the studies have been conflicting in their outcome.^{6,11,12} The primary issue is that these values are often abnormal in burn patients due to co-morbid factors such as hypermetabolism, electrolyte imbalance or sepsis. Thus, at present, there is a lack of valid screening or laboratory tests for HO.

Onset and differential symptomology

The principle signs and symptoms of HO include: decreased ROM with associated joint stiffness; localised swelling; a painful joint; and possible nerve palsy.²⁵ At the elbow in particular, ulnar nerve palsy with intrinsic muscle weakness is a relatively common presentation. A consistent early sign of developing HO is a loss of active ROM, or the need for assistance to achieve a ROM that had previously been reached by active motion alone.²⁸ The 'locking sign' can aid differentiation of HO from elbow scar contracture.¹¹ HO pain was described as 'sharp' and 'stabbing', a symptom that was distinguishable from the pain experience of burn injury alone.² Early clinical signs of HO have been reported at means of 37–43 days post burn injury^{14,28} though diagnosis is reported as early as 12 days post injury.¹⁵ This preceded radiological confirmation by a mean of at least five days to several weeks.^{14,25} The unique time frame and specificity of the symptoms paints a picture that will differentiate HO from restrictions related to early scar contracture, which typically develops at four to eight weeks after injury.²⁹ The symptoms of acute ulnar nerve entrapment are present in ~12% of cohorts with HO.²³ The symptoms of neuropathic pain and marked motor and sensory deficits of the ulnar nerve are diagnostic for HO though are often not the initial signs complained of by patients.

Detection and diagnosis

Widely used diagnostic techniques have low sensitivity or specificity to incremental progression of mineralisation at early time points in HO development.³⁰ Yeh et al.³¹ reported that ectopic bone formation generally does not show on plain film until four to eight weeks after the initial symptoms. Without accurate and reliable early diagnosis, there is little chance of early intervention, and late detection fails to limit unabated progression of HO which often results in joint contractures, nerve entrapment and marked pain. Expensive and time-consuming radiographic

techniques, including CT and MRI, provide high-resolution visualisation of late stage HO and 3D CT reconstruction can show the exact anatomic location of HO and is thus helpful for preoperative evaluation.¹¹ Three-phase bone scintigraphy (SPECT) has been proposed as a method for early detection and may serve as an index for following up on HO maturity.³¹ However, the presence of inflammation in burn wound healing may generate false positives when HO is not present.³⁰

As proposed by Chen et al.,¹¹ a solution to provide early differential diagnosis of HO was documented in a stroke patient.³¹ The case report indicated that serial ultrasonography (US) provided earlier and more specific diagnosis of a hip muscle HO lesion than did X-ray or MRI, the latter indicated necrotising fasciitis initially.³¹ Ultrasonography depicted clear disease progression, with calcification visible on day 15 after onset of first symptoms.³¹ Similarly, in the orthopaedic patients, US has high sensitivity and specificity for early HO diagnosis one week after total hip arthroplasty.¹⁸ Further, evidence of HO on US was detected up to 10–14 days prior to when radiographic evidence appeared.¹⁸ In contrast, Perovsky et al.³⁰ stated that although US can detect HO sooner than conventional radiography, it cannot distinguish new bone formation from less mineralised mature bone. All told, due to accessibility, low relative cost and lack of radiation, US is a feasible and safe screening tool for early diagnosis of HO in the burn population.^{11,31}

Lastly, it is worth noting emergent technology, suggested in a study of non-invasive near infra-red (NIR) imaging to diagnose and monitor the progression of HO in vivo in a mouse model.³⁰ NIR detected HO from the first assessment on day 5 and revealed a temporal response in HO formation and heterotopic bone turnover when using NIR contrast agents. Thus, NIR may provide a sensitive and reliable approach for following up dynamic disease processes in the future.

Treatment

Mobilisation and activity. Controversy continues to surround the role of exercise therapy and stretching exercises in the diagnosis and treatment of HO.¹³ Active and passive range of motion exercise and minimisation of immobilisation are widely applied principles to mitigate burn contracture.³² Shafer et al.³ proposed that the combination of immobilisation, an active inflammatory state (burn wound healing and surgery) and local trauma from early aggressive exercise therapy was implicated in the development of HO. The

review results showed that specific prescription of movement therapies and effect on joint trauma and HO progression remains unclear.¹² Little evidence exists to confirm whether stretching should be limited to the arc of tolerable pain and resistance free ROM, or if aggressive range maintenance and stretching techniques can be advocated to optimise post-HO functional outcomes. In addition, it is unclear if, or how exercise therapies should change with clinical suspicion prior to confirmed diagnosis of HO.

The results of this review indicate that patients who have prolonged immobilisation, as well as patients who receive aggressive physical therapy, are both at greater risk for the development of HO.^{11,23,33} Case reports and animal studies suggest that forceful passive manipulation beyond pain-free ROM during re-establishment of joint range after immobilisation, the density and volume of calcification increases.^{34–36}

In a prospective study conducted in the SCI population, Stover et al.³⁷ compared aggressive passive ROM (stretching) and active ROM therapy groups and the rate of development of HO. No significant or clinical difference was evident. In patients with established HO, aggressive stretch therapy into pain and resistance, increased independence and ROM, negating the need for surgery in one case.¹³ Little scientific evidence exists to aid the prescription of the physical therapy program when HO is confirmed or when it is suspected.³⁸ This may suggest that immobilisation should be minimised and both active and passive ROM exercises should be continued despite developing or evident HO. The optimal force applied, and acceptable levels of pain, during movement therapies remain unknown. Caution is warranted as potential risks of skin and graft failure, nerve injury and bony fracture increase with the aggressiveness of therapy.

Pharmacotherapy. Indication for drug therapy varies with the stage of the disease and studies have included prophylactic measures to prevent the formation of ectopic bone.^{34,39} Etidronate disodium (EHDP), a bisphosphonate, has been shown to inhibit hydroxyapatite crystal formation, osteoclast function and bone formation, and therefore theoretically may diminish the incidence or severity of HO.³ In spinal cord and head injury and orthopaedic surgery populations, EDHP was purported to prevent the development and progression of HO.⁴⁰ Yet, other studies suggest that EHDP is ineffective or that its inhibitory effect is transitional and clinical manifestations and radiographic evidence eventually return with discontinuation of the drug.^{41–43} In burns, Shafer

et al.³ showed EHDP did not demonstrate clinical efficacy in treatment of HO and further, when used prophylactically, HO incidence increased (46.4% with EHDP 600 mg/day versus 13.8% without). Garland et al.⁴⁴ found that low dose EHDP (10 mg/kg/d) did not prevent progression of HO.

Non-steroidal anti-inflammatory drugs (NSAIDs) are believed to prevent the formation of HO by inhibiting cyclooxygenase (COX).^{11,15} After orthopaedic hip surgery in patients, non-selective (COX-1) and selective (COX-2) NSAIDs significantly prevented HO formation more than placebo.⁴⁵ Further, their review concluded that COX-1 NSAIDs were significantly more likely to cause more gastrointestinal side effects and be discontinued than COX-2 NSAIDs or placebo.⁴⁵ In a randomised, prospective, double-blind, placebo-controlled clinical trial conducted in the SCI population, Rofecoxib (COX-2 NSAID) prevented HO.⁴⁶ While promising, the review did not discover any trials exploring COX-1 or COX-2 inhibitors in prevention or treatment of HO in burn patients. It would appear prudent to conclude that COX-1 NSAIDs are not recommended in burns due to their side effect profile, including major bleeding and negative influence on wound healing and graft take.¹¹ Further research is warranted as to the use of COX-2 NSAIDs in the prevention and treatment of HO in burn patients.

Surgery. Surgical resection of HO is indicated in patients with limited ROM after non-surgical treatment. A delay of 12–24 months, to ensure bone maturation and reduce the risk of HO recurrence, is recommended.⁴⁷ However, such delay in release surgery has been associated with up to 30% of patients with permanent loss of ROM (>25% of normal range),^{48,49} and up to 25% postoperative iatrogenic or persistent ulnar nerve lesions.⁵⁰ Long-standing dysfunction of the elbow is compounded by secondary scar and soft-tissue contracture, joint arthrosis from ligament and joint capsule fibrosis; muscle atrophy and articular cartilage degeneration.^{47,51} Further, in a qualitative study, HO and loss of ROM was associated with poorer functional outcomes and negative impact on participation and return to normal social roles.² In a neurological trauma population, delayed surgery did not correlate with clinical necessity of resection.⁵²

Thus, earlier excision of HO has been explored. Chen et al.⁴⁷ suggested early excision simplified the operative procedure and reduced the risk of damage to structures that are important for elbow stability. These authors retrospectively reviewed 164 HO patients to compare recurrence

and elbow function between early (mean, 6.1 months) and late excision.⁴⁷ No significant difference was found in terms of HO recurrence between the groups with a low recurrence rate and the establishment of a functional ROM for both. Similarly, Medina et al.⁶ performed early excision of HO (mean 5.35 ± 1.46 months post diagnosis). These authors concluded that the approach reduced long-term and postoperative complications and re-established adequate ROM, which was improved significantly when combined with physiotherapy within pain-free range. However, a local HO recurrence rate of 30% was reported, necessitating a second surgical episode.⁶

Radiation therapy. It must be noted that surgical resection is often associated with complications and a high risk of recurrence.⁵³ Radiologically, the recurrence rate of HO is 82–100% and 17–58% clinically.⁵³ As such, preventing the recurrence of HO is crucial in this high-risk population. However, the literature in the burn population is limited and remains controversial with many clinicians expressing concern about the long-term side effects of local radiation such as the development of secondary malignancies.^{6,54} In the SCI population, Sautter-Bihl et al.⁵⁵ concluded that irradiation is an effective neoadjuvant and adjuvant treatment option. The results of this study demonstrated progressive bone formation was prevented in 50 out of 70 hips.⁵⁵ Further, a meta-analysis of randomised trials demonstrated that prophylactic irradiation is slightly more effective than NSAIDs in preventing clinically significant HO after major hip procedures.⁵⁶ In the burns population, Maender et al.⁵⁴ recommend the use of perioperative radiation therapy routinely in conjunction with surgery to reduce recurrence rates. However, this case series is limited by the retrospective nature of the study, small cohort and lack of long-term follow-up. Therefore, multicentre trials with larger cohorts are required to establish the role of prophylactic radiation therapy in the burn population.

Limitations. While it is undeniable that surgical excision of HO remains an integral treatment to restore function, research is required to confirm the optimal timing of resection to balance the competing challenges of inflammatory ankyloses of soft tissues, nerve compromise, risk of recurrence and patient habitual and mental health responses and burden due to reduced ROM.

This review did not include studies published in languages other than English. Thus, studies with larger numbers and better research design may have been missed. The majority of studies

found were retrospective with small sample sizes, or were case series or reports. The study types and level of evidence affordable to such research is almost certainly due to the low incidence of major burn injury, the confounding factors presented by acute burns and the even smaller numbers who suffer HO after burn.

Conclusion

There remains little translatable evidence to drive clinical change in the prevention or treatment of HO in burn patients, despite this review spanning 45 years of research. Given the dearth of high level evidence, burn clinicians urgently need more purposeful multicentre data pooling for detailed exploration of the specific risk factors of HO and the development of cost-effective screening and early physical and pharmacological interventions to prevent and/or ameliorate this devastating complication which adds insult after burn injury. While selective NSAIDs hold promise for prevention and treatment, surgery continues to be the best and recommended treatment for established HO when ROM and activities of daily living are significantly affected. While clinicians may uncover treatment options which exacerbate, or prevent HO, bio-scientists need to identify the mechanism and engineers need to focus on the biomechanics of this phenomenon. HO will only be solved by collaboration between disciplines and, therefore, it is essential that disciplines from all fields need to collaborate to improve both the understanding and treatment of HO.

Acknowledgments

Thank you to the Katie Piper Foundation for supporting the open access publication fees for this paper.

Declaration of conflicting interests

The authors declared no potential conflicts of interest with respect to the research, authorship, and/or publication of this article.

Funding

This research received no specific grant from any funding body in the public, commercial, or non-profit sector.

References

- Klein MB, Logsetty S, Costa B, et al. Extended time to wound closure is associated with increased risk of heterotopic ossification of the elbow. *J Burn Care Res* 2007; 28: 447–450.
- Foster N, Kornhaber R, McGarry S, et al. Heterotopic Ossification in adults following a burn injury: A phenomenological analysis. *Burns* 2017; In press.
- Shafer DM, Bay C, Caruso DM, et al. The use of eidronate disodium in the prevention of heterotopic ossification in burn patients. *Burns* 2008; 34: 355–360.
- Potter BK, Forsberg JA, Davis TA, et al. Heterotopic ossification following combat-related trauma. *J Bone Joint Surg Am* 2010; 92: 74–89.
- Kaplan FS, Glaser DL, Hebela N, et al. Heterotopic ossification. *J Am Acad Orthop Surg* 2004; 12: 116–125.
- Medina A, Shankowsky H, Savaryn B, et al. Characterization of heterotopic ossification in burn patients. *J Burn Care Res* 2014; 35: 251–256.
- Forsberg JA, Pepek JM, Wagner S, et al. Heterotopic ossification in high-energy wartime extremity injuries: prevalence and risk factors. *J Bone Joint Surg Am* 2009; 91: 1084–1091.
- Zaman SR. Heterotopic ossification of the elbows in a major petrol burn. *BMJ Case Rep* 2012; 2012: 1–3.
- Johnson JT. Atypical myositis ossificans. *J Bone Joint Surg Am* 1957; 39-a: 189–193.
- Tsionos I, Leclercq C and Rochet JM. Heterotopic ossification of the elbow in patients with burns. Results after early excision. *J Bone Joint Surg Br* 2004; 86: 396–403.
- Chen HC, Yang JY, Chuang SS, et al. Heterotopic ossification in burns: Our experience and literature reviews. *Burns* 2009; 35: 857–862.
- Levi B, Jayakumar P, Giladi A, et al. Risk factors for the development of heterotopic ossification in seriously burned adults: A National Institute on Disability, Independent Living and Rehabilitation Research burn model system database analysis. *J Trauma Acute Care Surg* 2015; 79: 870–876.
- Coons D and Godleski M. Range of motion exercises in the setting of burn-associated heterotopic ossification at the elbow: Case series and discussion. *Burns* 2013; 39: e34–e38.
- Orchard GR, Paratz JD, Blot S, et al. Risk factors in hospitalized patients with burn injuries for developing heterotopic ossification—a retrospective analysis. *J Burn Care Res* 2015; 36: 465–470.
- Hunt JL, Arnoldo BD, Kowalske K, et al. Heterotopic ossification revisited: A 21-year surgical experience. *J Burn Care Res* 2006; 27: 535–540.
- Rubin MM and Cozzi GM. Heterotopic ossification of the temporomandibular joint in a burn patient. *J Oral Maxillofac Surg* 1986; 44: 897–899.
- Schneider JC, Simko LC, Goldstein R, et al. Predicting heterotopic ossification early after burn injuries: a risk scoring system. *Ann Surg* 2016; [Epub ahead of print].
- Amar E, Sharfman ZT and Rath E. Heterotopic ossification after hip arthroscopy. *J Hip Preserv Surg* 2015; 2: 355–363.
- VanLaeken N, Snelling CFT, Meek RN, et al. Heterotopic bone formation in the patient with burn injuries. A retrospective assessment of contributing factors and methods of investigation. *J Burn Care Rehabil* 1989; 10: 331–335.
- Medina A, Ma Z, Varkey M, et al. Fibrocytes participate in the development of heterotopic ossification. *J Burn Care Res* 2015; 36: 394–404.
- Sakellariou VI, Grigoriou E, Mavrogenis AF, et al. Heterotopic ossification following traumatic brain injury and spinal cord injury: insight into the etiology and pathophysiology. *J Musculoskelet Neuronal Interact* 2012; 12: 230–240.
- Carleton HA and Webb ML. The case report in context. *Yale J Biol Med* 2012; 85: 93–96.
- Crawford CM, Varghese G, Mani MM, et al. Heterotopic ossification: Are range of motion exercises contraindicated? *J Burn Care Rehabil* 1986; 7: 323–327.
- Scott Elledge E, Smith AA, McManus WF, et al. Heterotopic bone formation in burned patients. *J Trauma* 1988; 28: 684–687.
- Peterson SL, Mani MM, Crawford CM, et al. Postburn heterotopic ossification: Insights for management decision making. *J Trauma* 1989; 29: 365–369.

26. Djurickovic S, Meek RN, Snelling CFT, et al. Range of motion and complications after postburn heterotopic bone excision about the elbow. *J Trauma* 1996; 41: 825–830.
27. Jackson D. Destructive burns: Some orthopaedic complications. *Burns* 1980; 7: 105–122.
28. Munster AM, Bruck HM, Johns LA, et al. Heterotopic calcification following burns: a prospective study. *J Trauma* 1972; 12: 1071–1074.
29. Gauglitz GG, Korting HC, Pavicic T, et al. Hypertrophic scarring and keloids: pathomechanisms and current and emerging treatment strategies. *Mol Med* 2011; 17: 113–125.
30. Perosky JE, Peterson JR, Eboda ON, et al. Early detection of heterotopic ossification using near-infrared optical imaging reveals dynamic turnover and progression of mineralization following Achilles tenotomy and burn injury. *J Orthop Res* 2014; 32: 1416–1423.
31. Yeh T-S, Wu C-H, Chen W-S, et al. Serial ultrasonography for early detection and follow-up of heterotopic ossification in stroke. *J Med Ultrasound* 2012; 20: 119–124.
32. ISBI Practice Guidelines Committee. ISBI Practice Guidelines for Burn Care. *Burns* 2016; 42: 953–1021.
33. Richards AM and Klaassen MF. Heterotopic ossification after severe burns: A report of three cases and review of the literature. *Burns* 1997; 23: 64–68.
34. Salazar D, Goltz A, Israel H, et al. Heterotopic ossification of the elbow treated with surgical resection: Risk factors, bony ankylosis, and complications. *Clin Orthop Relat Res* 2014; 472: 2269–2275.
35. Scalzitti DA. Because of the risk of developing heterotopic ossification, are passive range of motion exercises contraindicated following traumatic injuries? *Phys Ther* 2003; 83: 659–657.
36. Summerfield SL, DiGiovanni C and Weiss AP. Heterotopic ossification of the elbow. *J Shoulder Elbow Surg* 1997; 6: 321–332.
37. Stover SL, Hataway CJ and Zeiger HE. Heterotopic ossification in spinal cord-injured patients. *Arch Phys Med Rehabil* 1975; 56: 199–204.
38. Casavant AM and Hastings H. Heterotopic ossification about the elbow: a therapist's guide to evaluation and management. *J Hand Ther* 2006; 19: 255–266.
39. Shehab D, Elgazzar AH and Collier BD. Heterotopic ossification. *J Nucl Med* 2002; 43: 346–353.
40. Finerman GA and Stover SL. Heterotopic ossification following hip replacement or spinal cord injury. Two clinical studies with EHDP. *Metab Bone Dis Relat Res* 1981; 3: 337–342.
41. Thomas BJ and Amstutz HC. Prevention of heterotopic bone formation: clinical experience with diphosphonates. *Hip* 1987: 59–69.
42. Hu HP, Kuipers W, Slooff TJ, et al. The effect of biphosphonate on induced heterotopic bone. *Clin Orthop Relat Res* 1991; 272: 259–267.
43. Hu H, Slooff T and Van Horn J. Heterotopic ossification following total hip arthroplasty: a review. *Acta Orthop Belg* 1991; 57: 169–182.
44. Garland DE, Alday B, Venos KG, et al. Diphosphonate treatment for heterotopic ossification in spinal cord injury patients. *Clin Orthop Relat Res* 1983; 176: 197–200.
45. Kan S-L, Yang B, Ning G-Z, et al. Nonsteroidal anti-inflammatory drugs as prophylaxis for heterotopic ossification after total hip arthroplasty: a systematic review and meta-analysis. *Medicine* 2015; 94: 1–14.
46. Banovac K, Williams J, Patrick L, et al. Prevention of heterotopic ossification after spinal cord injury with COX-2 selective inhibitor (rofecoxib). *Spinal Cord* 2004; 42: 707–710.
47. Chen S, Yu S-y, Yan H, et al. The time point in surgical excision of heterotopic ossification of post-traumatic stiff elbow: recommendation for early excision followed by early exercise. *J Shoulder Elbow Surg* 2015; 24: 1165–1171.
48. Dias DA. Heterotopic para-articular ossification of the elbow with soft tissue contracture in burns. *Burns Incl Therm Inj* 1982; 9: 128–134.
49. Holguin PH, Rico AA, Garcia JP, et al. Elbow ankylosis due to postburn heterotopic ossification. *J Burn Care Rehabil* 1996; 17: 150–154.
50. Hoffer MM, Brody G and Ferlic F. Excision of heterotopic ossification about elbows in patients with thermal injury. *J Trauma* 1978; 18: 667–670.
51. Gallucci G, Gallucci J, De Carli P, et al. Abordaje lateral para el tratamiento de las rigideces del codo. *Rev Asoc Argent Ortop Traumatol* 2003; 68: 27–32.
52. Sullivan MP, Torres SJ, Mehta S, et al. Heterotopic ossification after central nervous system trauma: A current review. *Bone Joint Res* 2013; 2: 51–57.
53. Bossche LV and Vanderstraeten G. Heterotopic ossification: a review. *J Rehabil Med* 2005; 37: 129–136.
54. Maender C, Sahajpal D and Wright TW. Treatment of heterotopic ossification of the elbow following burn injury: recommendations for surgical excision and perioperative prophylaxis using radiation therapy. *J Shoulder Elbow Surg* 2010; 19: 1269–1275.
55. Sautter-Bihl M, Liebermeister E and Nanassy A. Radiotherapy as a local treatment option for heterotopic ossifications in patients with spinal cord injury. *Spinal Cord* 2000; 38: 33–36.
56. Pakos EE and Ioannidis JP. Radiotherapy vs. nonsteroidal anti-inflammatory drugs for the prevention of heterotopic ossification after major hip procedures: a meta-analysis of randomized trials. *Int J Radiat Oncol Biol Phys* 2004; 60: 888–895.

How to cite this article

Kornhaber R, Foster N, Edgar D, et al. The development and impact of heterotopic ossification in burns: a review of four decades of research. *Scars, Burns & Healing*, Volume 3, 2017. DOI: 10.1177/2059513117695659.