

Repair of Iatrogenic Large Colon Perforation Using Laparoscopic Methods.

Case Report and Review of the Literature

S Nazari^{*1, 2, 3}, SM Khosroshahi¹, H Khedmat⁴, F Azhie⁴

1. Department of Surgery, Erfan Hospital, Tehran, Iran
2. Department of Surgery, Milad Hospital, Tehran, Iran
3. Department of Surgery, Madaen Hospital, Tehran, Iran
4. Department of Gastroenterology, Erfan Hospital, Tehran, Iran

***Corresponding Author:**

Shahram Nazari, MD
36, Afarin Clinic, Afarin St., Alvand Ave.,
Argentina Sq., Tehran, 1516636111, Iran
Tel: +98 21 88884610
Fax: +98 21 88678159
E-mail: dsnazari@hotmail.com
Received: 10 May 2010
Accepted: 14 August 2010

ABSTRACT

Iatrogenic perforation of the colon during elective colonoscopy is a serious complication. Surgical treatment remains the standard of care. We report a patient with a large colonic perforation that occurred during a screening colonoscopy, successfully repaired with laparoscopic methods. Although the safety and efficacy of this approach is not entirely established, laparoscopy can be used to treat iatrogenic colonic perforation when the defect is readily recognized, easily accessible for closure and the bowel preparation is excellent. A laparoscopic approach to treat iatrogenic colon perforation results in decreased morbidity and hospital stay, in addition to a shorter incision length compared to an open method. In those cases where it is feasible and the surgical skill exists, a laparoscopic attempt at colon repair should probably be the initial clinical approach..

KEYWORDS

Colonoscopy; Laparoscopy; Perforation; Complications

INTRODUCTION

Colonic perforation is the most serious complication of colonoscopy, with an incidence of 0.35%¹ to 3% during therapeutic endoscopy.² Treatment of iatrogenic colon perforation using laparoscopic methods is a novel approach, would result in equal therapeutic efficacy, less perioperative morbidity, smaller incisions and decreased length of hospital stay, and an overall better short-term outcome compared to open methods.²

In this report, we describe successful laparoscopic closure of a large perforation of the sigmoid colon sustained during a screening colonoscopy.

CASE REPORT

A 66 year-old woman who sustained a colonic perforation during colonoscopy was treated successfully by laparoscopic repair. She underwent an outpatient screening colonoscopy due to a positive fecal occult blood test. According to the endoscopic report, the colonoscopy preparation was excellent, with small

amounts of clear fluid in the colon. A large perforation of the sigmoid colon resulted during maneuvering of the endoscope through a sharply angulated sigmoid colon. Colon perforation was recognized during the colonoscopy (Fig. 1).

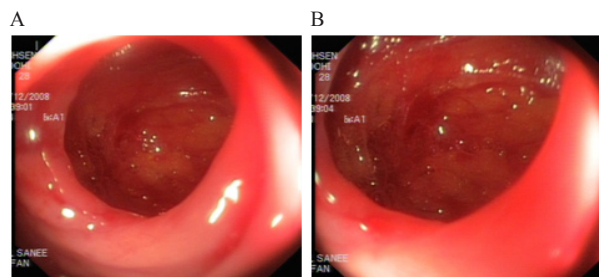


Fig 1: A large perforation of the sigmoid colon in mesocolic side induced by the colonoscope.

During the colonoscope withdrawal, luminal fluid and air were aspirated; no other abnormalities were noted. Inspection and palpation of the abdomen revealed mild abdominal distension and tenderness. The abdominal radiograph demonstrated pneumoperitoneum and retroperitoneal air around the right kidney. (Figs. 2A, B, C).

Laparoscopy was performed three h after colonoscopy. Trocar placement was performed. No fecal matter was identified in the peritoneal cavity. Local peritonitis was mild. After appropriate laparoscopic mobilization of the affected portion of the colon, the perforation site was located and inspected. The insufflated mesosigmoid over the laceration was opened and a 2 cm colon perforation was recognized. (Fig. 3) We performed a two-layer closure, beginning with a running 3-0 absorbable suture. Next, an outer layer of interrupted seromuscular 3-0 silk sutures was placed using an intracorporeal laparoscopic knot technique. The perforation was closed successfully with laparoscopic intracorporeal suturing.

Then, the proximal bowel was cross-clamped and air insufflated into the rectum with the repair underwater to ensure the absence of any leak.

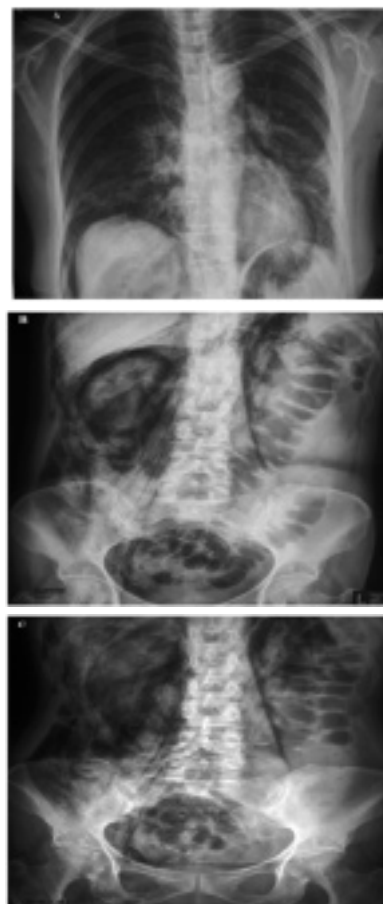


Fig 2: (A) Chest X-ray, confirming pneumoperitoneum. (B, C) Abdominal X-rays, demonstrating the air in the retroperitoneum (Supine & Up-right).

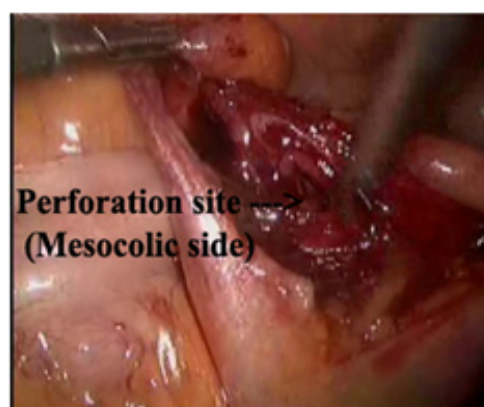

Fig 3: A colon perforation in mesocolic side.

The patient was hospitalized and was kept nil by mouth. She was treated with intravenous fluids and antibiotics. Except for slight

abdominal pain during the first 24 h, there were no signs of peritonitis or abdominal distension. The initial white blood cell count was $14,200/\text{mm}^3$ (normal $4,600\text{--}10,500/\text{mm}^3$) and declined to $10,200/\text{mm}^3$ after 48 h. Abdominal pain resolved by day two, her oral feeding was resumed by day three and she was discharged from the hospital by day five.

DISCUSSION

Since the introduction of flexible fiber-optic colonoscopy at the Beth Israel Medical Center by Wolff and Shinya in June of 1969, there have been numerous reports on the safety, cost-effectiveness, and low morbidity and mortality rates of diagnostic and therapeutic colonoscopy.³ Even though colonoscopy has become progressively more refined, it is an invasive procedure with major complications, such as haemorrhage and perforation.^{4, 5} Perforation is a significant and well-recognized, although rare^{4, 6} complication of fiber-optic colonoscopy. Its frequency is estimated to be between 0.35%¹ to 3% during therapeutic endoscopy^{2, 5, 7, 8} in various published literature. This wide variation in the incidence of perforation is best explained, most probably, by the expertise of the individual endoscopist and by how meticulously medical centers search for and report postcolonoscopy perforations.³

However, it has to be mentioned that there may be patients with perforations not recognized due to remaining subclinical and spontaneous healing⁸ or perforations that presented late in a different hospital and, thus, were missed in the follow-up and not included in the above rates. Subclinical perforations described as localized abdominal tenderness and short-lived pyrexia at presentation have proven to be “sealed perforations” at subsequent laparotomy for other reasons.⁸

Perforations can result from three principal mechanisms: (I) mechanical perforation by colonoscope’s tip or shaft-induced lacera-

tions (loop), (II) barotrauma from overinsufflation and (III) therapeutic procedures such as electrocoagulation for polypectomy and laser or argon plasma coagulation due to thermal injury.^{1, 5, 8, 9}

Colonoscope shaft-induced lacerations may result from any of the following: direct mechanical penetration of the tip of the colonoscope in the bowel wall, especially when visualization is poor; bowing of a loop of the scope which may cause sufficient lateral pressure to perforate the colonic wall making the perforation invisible from the tip of the instrument; perforating along a pathologic area of the colon, such as stricture, diverticulum, or tumor, from aggressive air insufflation that may cause colon overdistention and rupture; and perforating during a snare polypectomy or with direct thermal injury to the bowel wall (Fig. 4-7 respectively)³. The sigmoid colon is the area at greatest risk for perforation.^{3, 8, 10} Immediate operative management, preferably primary repair and sometimes resection, appears to be a good strategy for most patients.^{1, 3, 7, 8}

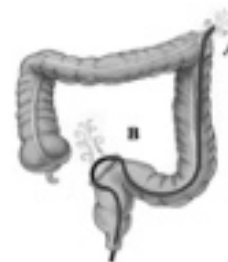


Fig 4: (A) Direct mechanical penetration of the tip of the colonoscope in the bowel wall. (B) Bowing of a loop of the scope causing perforation of the colonic wall.

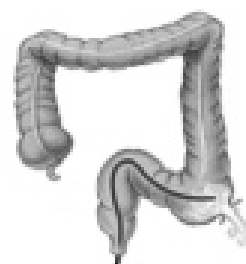

Fig 5: Aggressive air insufflation and colonic wall rupture.

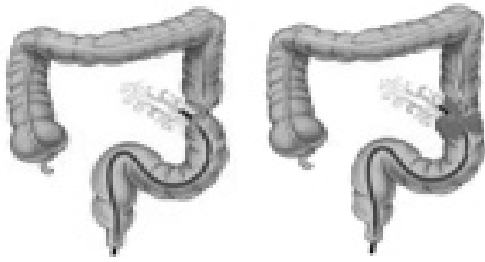


Fig 6: Perforation in a pathologic site, such as stricture, diverticulum, or tumor.

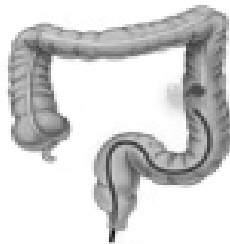


Fig 7: Perforation during a snare polypectomy or direct thermal injury.

Concern over iatrogenic perforation of the gastrointestinal tract during instrumentation relates to the potential spillage of enteric contents into the abdominal cavity, resulting in peritonitis, possible sepsis and even death if there is undue delay in diagnosis and treatment.^{7,9} Most fatalities involved patients with serious comorbidities.⁸

Radiology often establishes diagnosis. Plain films of the abdomen and an upright chest x-ray may reveal extravasated air confined to the bowel wall, free intraperitoneal air, retroperitoneal air, subcutaneous emphysema, or even a pneumothorax (Fig. 2)^{5,11}.

The management of colonoscopic perforations remains controversial^{4,9} since there are no specific guidelines⁸. Traditionally, iatrogenic colon perforations were treated with prompt open laparotomy, colonic repair, resection or both, and peritoneal lavage.^{9,12} Surgery is the standard therapy for endoscopic perforations of the colon^{1,3,4}, but it has a negative psychological and physical impact on a patient referred for a diagnostic test. More recently, there have been reports of successful laparoscopic repairs^{7,13,14}, endoluminal and transluminal surgery

(i.e., by metallic endoclipping)^{1,4,15-17} or non-operative management^{3,4,7,8} in highly selected patients who do not exhibit signs of peritoneal contamination or abdominal sepsis.^{4,5} Surgery is most definitely indicated in the presence of a large perforation demonstrated either colonoscopically or radiographically, in the setting of generalized peritonitis or ongoing sepsis, with concomitant pathology at time of colonoscopic perforation such as a large sessile polyp likely to be a carcinoma, unremitting colitis, or in perforation proximal to a nearly obstructing distal colonic lesion. Finally, in the patient who deteriorates with conservative management, one should proceed with surgery.⁵

The surgeon should communicate closely with the endoscopist when deciding upon appropriate patient management.⁵ The endoscopist can provide important information about the quality of the patient's bowel preparation and often a description of the endoscopically visualized injury. Visualization of the peritoneal cavity by the endoscopist and the development of signs of peritoneal irritation are absolute indications for surgery.^{5,9} Endoscopic closure of the iatrogenic colonic perforation is manageable if the diameter of the lesion is smaller than the opened branches of the Endo-Clips (11 mm).^{4,15} On the other hand, endoclips creates successful mucosal and submucosal apposition, while apposition of muscularis propria and serosa are not possible.⁴ These patients require further conservative treatment with no oral intake and intravenous broad-spectrum antibiotics and careful assessment during the observation period following the procedure. Bowel preparation, diagnostic versus therapeutic colonoscopy, interventions performed, underlying disease process, clinical patient history, and clinical status after the perforation, radiologic studies and laboratory data, and timing of recognition of the perforation are some of the variables that have to be taken into account when selecting the op-

timal treatment modality.³ Treatment using laparoscopic methods is a novel approach, only described in the recent literature. Laparoscopic surgery has decreased trauma and improved results of surgery in postoperative pain control, less perioperative morbidity, smaller incisions, decreased length of hospital stay, rapid return to activity and work, patient satisfaction and cosmetic results.¹² Despite this, there have only been small case series which compare laparoscopy to open techniques.^{7, 9} If a colonoscopic perforation is to be repaired laparoscopically instead of diverted, the same conditions should be met as during open surgery. The elapsed time between the injury and intervention should be as short as possible. The abdomen should be relatively clean and free of fecal soilage and inflammation, and there should also be no residual pathology. The operating surgeon and team should be comfortable with laparoscopic techniques, such as mobilization of the colon and intracorporeal suturing.⁹ The defect size and the condition of the bowel to be repaired and the level of contamination and inflammation present are important factors to choosing type of repair.⁹ Both sutured and stapled laparoscopic repair techniques may be used.⁹ The method of closure is based on surgeon preference but should be comparable to open techniques.

In those cases where it is feasible and the surgical skills exist, Laparoscopic treatment of iatrogenic colon perforation would result in equal therapeutic efficacy to open surgery and should probably be the initial clinical approach. Extensive inflammation or fecal soilage may require colonic diversion. In difficult or complicated situations with inability to laparoscopically localize the area of perforation and in cases with any doubt regarding the security of the repair, conversion to an open procedure should be performed. For small perforations, clipping can result in mucosal and submucosal healing, preventing fecal soiling

of the peritoneal cavity and could be a helpful adjunct to conservative treatment, thus lowering the need for surgical intervention with its risks. Conservative treatment is reserved for carefully selected patients only.

CONFLICT OF INTEREST

The author declare no conflict of interest related to this work.

REFERENCES

1. Albuquerque W, Moreira E, Arantes V, Bittencourt P, Queiroz F. Endoscopic repair of a large colonoscopic perforation with clips. *Surg Endosc* 2008;**22**:2072-4.
2. Bleier JI, Moon V, Feingold D, Whelan RL, Arnell T, Sonoda T, et al. Initial repair of iatrogenic colon perforation using laparoscopic methods. *Surg Endosc* 2008;**22**:646-9.
3. Avgerinos DV, Llaguna OH, Lo AY, Leitman IM. Evolving management of colonoscopic perforations. *J Gastrointest Surg* 2008;**12**:1783-9.
4. Magdeburg R, Collet P, Post S, Kaehler G. Endoclipping of iatrogenic colonic perforation to avoid surgery. *Surg Endosc* 2008;**22**:1500-4.
5. Damore LJ 2nd, Rantis PC, Vernava AM 3rd, Longo WE. Colonoscopic perforations. Etiology, diagnosis, and management. *Dis Colon Rectum* 1996;**39**:1308-14.
6. Forde KA. Colonoscopic screening for colon cancer. *Surg Endosc* 2006;**20**:S471-4.
7. Bleier JI, Moon V, Feingold D, Whelan RL, Arnell T, Sonoda T, et al. Initial repair of iatrogenic colon perforation using laparoscopic methods. *Surg Endosc* 2008;**22**:646-9.
8. Lüning TH, Keemers-Gels ME, Barendregt WB, Tan AC, Rosman C. Colonoscopic perforations: a review of 30,366 patients. *Surg Endosc* 2007;**21**:994-7.
9. Hansen AJ, Tessier DJ, Anderson ML, Schlinkert RT. Laparoscopic repair of colonoscopic perforations: indications and guidelines. *J Gastrointest Surg* 2007;**11**:655-9.
10. Coffey JC, Winter DC, Sookhai S, Cusack SP, Kirwan WO. Non-iatrogenic perforation of the colon due to acute barotrauma. *Int J Colorectal Dis* 2007;**22**:561-2.
11. Ignjatović M, Jović J. Tension pneumothorax, pneumoretroperitoneum, and subcutaneous emphysema after colonoscopic polypectomy: a case report and review of the literature. *Langenbecks Arch Surg* 2009;**394**:185-9.
12. Cleary RK, Pomerantz RA, Lampman RM. Colon and rectal injuries. *Dis Colon Rectum* 2006;**49**:1203-22.
13. Miyahara M, Kitano S, Shimoda K, Bandoh T, Chikuba K, Maeo S, et al. Laparoscopic repair of a colonic perforation sustained during colonoscopy. *Surg Endosc* 1996;**10**:352-3.

14. Kirshtein B, Roy-Shapira A, Lantsberg L, Mandel S, Avinoach E, Mizrahi S. The use of laparoscopy in abdominal emergencies. *Surg Endosc* 2003;**17**:1118-24.
15. Trecca A, Gaj F, Gagliardi G. Our experience with endoscopic repair of large colonoscopic perforations and review of the literature. *Tech Coloproctol* 2008;**12**:315-21.
16. Malik A, Mellinger JD, Hazey JW, Dunkin BJ, MacFadyen BV Jr et al. Endoluminal and transluminal surgery: current status and future possibilities. *Surg Endosc* 2006;**20**:1179-92.
17. Wullstein C, Köppen M, Gross E. Laparoscopic treatment of colonic perforations related to colonoscopy. *Surg Endosc* 1999;**13**:484-7.