

Idiopathic intracranial hypertension presenting as postpartum headache

Mariam Mathew, FRCOG, FRCPI, Ayesha Salabuddin, MBBS, MRCOG, Namitha R. Mathew, MBBS, Ramachandiran Nandhagopal, MBBS, DM.

ABSTRACT

الصداع بعد الولادة يوصف على أنه صداع وألم في الرقبة أو الكتف خلال الأسابيع الست الأولى بعد الولادة. الأسباب الشائعة للصداع خلال فترة النفاس هي الصداع النصفي وصداع التوتر. وتشمل الأسباب الأخرى ما قبل تسمم الحمل/تسمم الحمل، صداع بعد ثقب الجافية، وختار الأوردة الدماغية، ونزيف تحت العنكبوتية، ومتلازمة اعتلال بيضاء الدماغ الخلفي القابل للعكس، أورام المخ، نقص التروية الدماغية، التهاب السحايا، الخ. ارتفاع الضغط داخل القحف مجهول السبب هو سبب نادر من للصداع بعد الولادة. ويرتبط هذا المرض عادة بوذمة الخليمة البصرية، والصداع، وارتفاع الضغط داخل الجمجمة دون أي خلل عصبي بؤري في الأشخاص الأصحاء. وهو أكثر شيوعاً في النساء البدينات من الفئة العمرية الإنجابية ولكنها نادرة أثناء الحمل وفترة النفاس. نقدم حالة من ارتفاع الضغط داخل القحف مجهول السبب الذي قدم لنا بعد 18 يوماً من الجراحة القيصرية مع صداع شديد وتم علاجه بالطريقة الصحيحة.

Postpartum headache is described as headache and neck or shoulder pain during the first 6 weeks after delivery. Common causes of headache in the puerperium are migraine headache and tension headache; other causes include pre-eclampsia/eclampsia, post-dural puncture headache, cortical vein thrombosis, subarachnoid hemorrhage, posterior reversible leukoencephalopathy syndrome, brain tumor, cerebral ischemia, meningitis, and so forth. Idiopathic intracranial hypertension (IIH) is a rare cause of postpartum headache. It is usually associated with papilledema, headache, and elevated intracranial pressure without any focal neurologic abnormality in an otherwise healthy person. It is more commonly seen in obese women of reproductive age group, but rare during pregnancy and postpartum. We present a case of IIH who presented to us 18 days after cesarean section with severe headache and was successfully managed.

*Neurosciences 2016; Vol. 21 (1): 52-55
doi:10.17712/nsj.2016.1.20150304*

From the Departments of Obstetrics & Gynecology (Mathew M, Salaludin), Medicine (Nandhagopal), Sultan Qaboos University Hospital, Muscat, Oman, and Department of Medicine (Mathew N), Kasturba Medical College, Manipal, India.

Received 27th April 2015. Accepted 21st October 2015.

Address correspondence and reprint request to: Dr. Mariam Mathew, Department of Obstetrics & Gynecology, Sultan Qaboos University Hospital, Muscat, Oman. E-mail: mariamm1762@gmail.com

Postpartum headache (PH) is described as headache with or without neck or shoulder pain experienced during the first 6 weeks after delivery.¹ Postpartum headache has a reported incidence of 39% in the first week of postpartum,² and the most common cause is pre-existing primary headache, such as migraine or tension headache with transient exacerbation. However, in the setting of progressive PH, it is essential to consider secondary causes, such as pre-eclampsia/eclampsia, post-dural puncture headache, cortical vein thrombosis, arterial dissection, subarachnoid hemorrhage, posterior reversible leukoencephalopathy syndrome, brain tumor, cerebral ischemia, meningitis, and so forth.³ Idiopathic intracranial hypertension (IIH) may present as postpartum headache. It is usually characterized by headache with or without papilledema and elevated cerebrospinal fluid pressure without any focal neurologic abnormality with normal CSF glucose, protein, cell count, and microbiological examination in an otherwise healthy person. The IIH is more commonly seen in obese women of the reproductive age group (19.3/100,000), but rare during pregnancy.⁴ The most commonly used criteria for diagnosis is the Modified Dandy Criteria reviewed and updated by Friedman and Jacobson.⁵ The diagnosis is made when lumbar CSF opening pressure is >250 mm of water. We report a rare case of IIH who presented to us with severe PH 18 days after cesarean section and was successfully managed. Our aim in presenting this particular case is to improve recognition of peripartum IIH, and to stimulate interest into IIH among clinicians.

Disclosure. Authors have no conflict of interest, and the work was not supported or funded by any drug company.

Case Report. A 32-year-old primigravida, underwent cesarean section for prolonged second stage of labor with deflexed fetal head under spinal anesthesia. On the second post-operative day, she developed fever and productive cough due to right lower lobe consolidation. Sputum culture was negative for bacteria. She was successfully treated with cefuroxime (GlaxoSmithKline, Dublin, Ireland) for a total of 14 days and azithromycin (Pfizer, Quebec, Canada) for 5 days, and discharged home in good condition. Fifteen days after cesarean section, she developed continuous severe holocranial headache without any associated fever, vomiting, photophobia or phonophobia, visual loss, diplopia, tinnitus, or convulsions. Three days after the onset of progressive PH (day eighteenth of cesarean section), she was re-admitted for evaluation. She reported no exacerbation of headache with postural change, Valsalva maneuver (during straining for micturition or defecation), coughing or sneezing, and there was no intake of vitamin A, tetracycline, steroid or hormonal pills, or episodes of arterial or venous thromboembolism. In the past, she experienced infrequent non-specific headache (without migrainous features) with prompt pain relief upon intake of acetaminophen when necessary. There was no family history of migraine, and she denied any history of depression, stress, or cat scratch.

On examination she was afebrile, and her blood pressure was 126/74 mm Hg. There was no anemia, lymphadenopathy, skin rash, polyarthrititis, nasal sinus tenderness, pericranial tenderness, otitis media, mastoiditis, foul smelling lochia, significant pedal

edema, or calf muscle tenderness. Her body mass index was 27 kg/m². She was conscious, oriented to time, place, and person. Oculi fundi revealed bilateral papilledema (Frisen scale Grade 1); her visual acuity, visual field, color vision, and extraocular movements were unremarkable. Neurologically there were no focal neurological deficits and signs of meningeal irritation. Her complete blood counts, serum urea, creatinine, electrolytes, uric acid, liver function tests, C-reactive protein, anti nuclear antibody, anti-nuclear cytoplasmic antibody, and anticardiolipin antibodies were all within normal reference range. Her thrombophilia work up (protein C, S, and anti thrombin III) was negative.

The initial cranial CT scan was normal, and her brain MRI did not reveal any parenchymal lesion, dural sinus occlusion, or pituitary lesion. The magnetic resonance venography showed normal major dural venous sinuses (Figure 1). After informed consent, she underwent lumbar puncture that showed clear CSF with raised opening pressure of more than 40 cm of H₂O. Her CSF glucose was 3.1 mmol/L, protein 0.25g/L with no cells or organisms. The CSF polymerase chain reaction for ebstein barr virus and Cytomegalovirus DNA, gram stain, bacterial culture, and cryptococcal antigen were negative. Considering the clinical feature of progressive isolated headache with papilledema and elevated CSF opening pressure, and the normal CSF finding, and normal cerebral sino-venous system, and brain parenchyma on neuroimaging, a diagnosis of IIH was made and she was placed on salt restricted diet and oral acetazolamide (Mercury Pharmaceuticals, Washington, DC, USA) 250 mg twice a day. However,

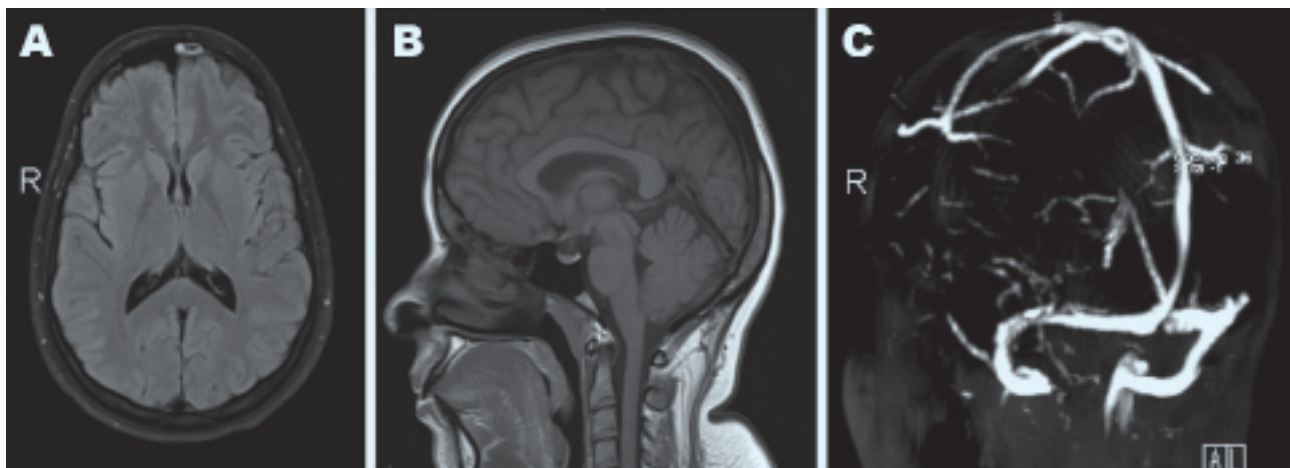


Figure 1 - Magnetic resonance imaging of brain (axial fluid attenuated inversion recovery image [A] and sagittal T1 weighted image [B]) showing normal brain parenchyma (no evidence of vasogenic edema of eclamptic encephalopathy or posterior reversible encephalopathy syndrome in the bilateral occipital region, or intra- or extra-axial brain tumor) and cerebral venogram (time of flight image [C]) showing normal major dural venous sinuses. AL - anterolateral, R - right

she stopped acetazolamide on her own after 6 weeks as her symptoms improved. During follow-up after 3 months of her symptom onset, she had no visual impairment, papilledema had resolved, and her neurological examination was unremarkable. A written consent from the patient was obtained for publication of the case.

Discussion. Idiopathic intracranial hypertension - formerly known as pseudotumor cerebri- may be a cause of postpartum headache, and is usually diagnosed by excluding other common causes of headache.¹⁻⁴ The exact etiology of IIH is not known, detailed investigations have revealed a high incidence of venous outflow abnormalities/cerebral perfusion changes in IIH patients. It has been observed that the increased venous pressure in IIH may be caused by the elevated intracranial pressure.⁶ Primary mechanisms for the development of increased CSF pressure in IIH supported by experimental data are vasogenic extracellular brain edema and a low conductance of CSF outflow at the arachnoid villi.⁷ Recent interest has been focused on lateral sino-venous stenosis with a potential improvement with stenting.⁸ However, dural sinus stenosis is not a universal finding, and was also not observed in our patient's MRI cerebral venogram.

Obesity is one of the risk factors for IIH especially in females. Obesity raises intra-abdominal pressure, which increases pleural pressure and cardiac filling pressures, which in turn, impedes venous return from the brain and leads to increased intracranial venous pressure and intracranial pressure.⁹ It has also been speculated that polycystic ovarian disease (PCOS) associated with obesity and extreme obesity itself can promote IIH; none of these risk factors were present in our case.¹⁰

Both pregnancy and exogenous estrogens are found to promote or worsen IIH. The prevalence of IIH amongst pregnant women varies between 2% and 12%, but there is no adverse effect on the fetus reported. 'Even at early presentation there is no increase in the rate of spontaneous abortion or fetal wastage, so limiting disease progression by therapeutic abortion is not indicated'.¹¹ Furthermore, subsequent pregnancies do not increase the risk of recurrence although, recurrent IIH in successive pregnancies have been reported in the literature.¹² Our patient was asymptomatic during pregnancy and presented for the first time after delivery.

The aim of the treatment is to relieve pain and to prevent visual loss, as blindness may occur in up to 10% of women presenting with IIH.⁴ Drugs including glucocorticoids, carbonic-anhydrase inhibitors (acetazolamide), and

diuretics have been shown to lower intracranial tension. Serial lumbar punctures are helpful and can be safely carried out in these patients as the uniform brain swelling and the natural position of the cerebellar tonsils prevents herniation and compression of the brain stem during the procedure. In fact, lumbar punctures in IIH patients are beneficial because it reduces CSF pressure by allowing CSF drainage.^{7,9} All these treatment regimens can be used safely during pregnancy.⁴

Regarding medical treatment, a recent randomized study¹³ has endorsed the role of oral acetazolamide in improving visual prognosis in IIH. However, it was the observation of one of the authors that Asian patients hardly tolerate doses of oral acetazolamide beyond 500 mg/day or so, due to side-effects such as circum-oral, or limb paresthesias, and weight gain. Our present case also experienced similar problems with the medication. The exact duration of acetazolamide use is not established and is often guided by the course of visual problems, especially visual symptoms and signs, papilledema, and headache. There is no convincing evidence that either mode of delivery is advantageous in cases of IIH. Vaginal delivery is usually the choice, and cesarean delivery is reserved for obstetric indications. However, uterine contractions cause increased blood pressure and consequently, increased CSF pressure. 'These exacerbations of CSF pressure superimposed on pre-existing papilledema may result in untoward visual effects sometimes resulting in permanent loss of vision'.¹⁴ Our patient was asymptomatic during pregnancy and underwent cesarean section for obstetric indications.

In pregnant IIH patients, if vaginal delivery is planned, adequate labor analgesia is recommended as uterine contractions are associated with increased CSF pressure. Narcotic analgesics are not recommended as they are respiratory depressants resulting in raised partial pressure of carbon dioxide level affecting cerebral blood flow and intracranial pressure. Epidural analgesia is a good choice as it is associated with minimal hemodynamic changes during contractions.¹² The Second stage of labor can be shortened by instrumental delivery to prevent increase in CSF pressure during bearing-down efforts.¹⁴ For cesarean delivery, regional anesthesia is a better choice as general anesthesia may be associated with a rise in CSF pressure. Post-lumbar puncture headache seen after spinal anesthesia does not occur in IIH patients; in fact, the CSF drainage is beneficial in this population. The spread of anesthetic agent, as well as the regression of anesthesia in patients with IIH have been found to be similar to that seen in normal patients.¹⁵

In conclusion, idiopathic intracranial hypertension should be considered as one of the differential diagnoses of postpartum headache. Fundoscopic examination should be performed in all cases of new onset headaches especially in women. Early recognition and prompt management is crucial to avoid loss of vision in this vision threatening disease.

References

1. Macarthur A. Postpartum headache. In: Chestnut DH, Polley LS, Tsen LC, Wong CA, editors. *Chestnut's Obstetrics Anesthesia Principles and Practice*. 4th ed. Philadelphia (PA): Mosby Elsevier; 2009. p. 677-700.
2. Goldszmidt E, Kern R, Chaput A, Macarthur A. The incidence and etiology of postpartum headaches: a prospective cohort study. *Can J Anaesth* 2005; 52: 971-977.
3. Stella CL, Jodicke CD, How HY, Harkness UF, Sibai BM. Postpartum headache: is your work-up complete? *Am J Obstet Gynecol* 2007; 196: 318.e1-e7.
4. Huna-Baron R, Kupersmith MJ. Idiopathic intracranial hypertension in pregnancy. *J Neurol* 2002; 249: 1078-1081.
5. Friedman DI, Jacobson DM. Diagnostic criteria for idiopathic intracranial hypertension. *Neurology* 2002; 59: 1492-1495.
6. Brazis PW. Pseudotumor cerebri. *Curr Neurol Neurosci Rep* 2004; 4: 111-116.
7. Radhakrishnan K, Ahlskog JE, Garrity JA, Kurland LT. Idiopathic intracranial hypertension. *Mayo Clin Proc* 1994; 69: 169-180.
8. Dykhuizen MJ, Hall J. Cerebral venous sinus system and stenting in pseudotumor cerebri. *Curr Opin Ophthalmol* 2011; 22: 458-462.
9. Bagga R, Jain V, Das CP, Gupta KR, Gopalan S, Malhotra S. Choice of therapy and mode of delivery in idiopathic intracranial hypertension during pregnancy. *MedGenMed* 2005; 7: 42.
10. Glueck CJ, Aregawi D, Goldenberg N, Golnik KC, Sieve L, Wang P. Idiopathic intracranial hypertension, polycystic-ovary syndrome, and thrombophilia. *J Lab Clin Med* 2005; 145: 72-82.
11. Tang RA, Dorotheo EU, Schiffman JS, Bahrani HM. Medical and surgical management of idiopathic intracranial hypertension in pregnancy. *Curr Neurol Neurosci Rep* 2004; 4: 398-409.
12. Gumma AD. Recurrent benign intracranial hypertension in pregnancy. *Eur J Obstet Gynecol Reprod Biol* 2004; 115: 244.
13. NORDIC Idiopathic Intracranial Hypertension Study Group Writing Committee, Wall M, McDermott MP, Kiebertz KD, Corbett JJ, Feldon SE, et al. Effect of acetazolamide on visual function in patients with idiopathic intracranial hypertension and mild visual loss: the idiopathic intracranial hypertension treatment trial. *JAMA* 2014; 311: 1641-1651.
14. Koontz WL, Herbert WN, Cefalo RC. Pseudotumor cerebri in pregnancy. *Obstet Gynecol* 1983; 62: 324-327.
15. Karmanioliou I, Petropoulos G, Theodoraki K. Management of idiopathic intracranial hypertension in parturients: anesthetic considerations. *Can J Anaesth* 2011; 58: 650-657.

SUPPLEMENTS

- * Supplements will be considered for work including proceedings of conferences or subject matter covering an important topic.
- * Material can be in the form of original work or abstracts.
- * Material in supplements will be for the purpose of teaching rather than research.
- * The Guest Editor will ensure that the financial cost of production of the supplement is covered.
- * Supplements will be distributed with the regular issue of the journal but further copies can be ordered upon request.
- * Material will be made available on the Neurosciences website (www.neurosciencesjournal.org)