



Bioceramic Cements: Supporting in Remineralization of Osteolytic Lesions in Endodontic-periodontal Diseases: A Report of Two Cases

Key Fabiano Souza Pereira ^{a*} , Samara Ortiz da Silva ^a , Hugo José Santos Bastos ^b , Luiz Fernando Tomazinho ^c , Vanessa Rodrigues do Nascimento ^c , Lia Beatriz Junqueira-Verardo ^d , Alex Yoshiharu Otani ^e

^a Department of Endodontics, Federal University of Mato Grosso do Sul, Brazil; ^b Private Practice, Barreiras, Brazil; ^c Department of Endodontics, University of Paraná, Brazil; ^d Private Practice, Campo Grande, Brazil; ^e Department of Endodontics, Paulista University, Brazil

Article Type: Case Report

Received: 08 Jun 2023

Revised: 23 Jul 2023

Accepted: 25 Aug 2023

Doi: 10.22037/iej.v18i4.41437

*Corresponding author: Key Fabiano Souza Pereira, Senador Filinto Muller Avenue, School of Dentistry, Federal University of Mato Grosso do Sul, Cidade Universitaria, s/n, Zip Code: 79070-900, Campo Grande, MS, Brazil.

E-mail: key.pereira@ufms.br

Bioceramic cements used for filling root canals in cases of endo-perio lesion of endodontic origin seem to be promising due to having the potential of promoting faster and more predictable healing of the periapical lesion as they stimulate osteogenesis. An effective treatment plan depends on the precise diagnosis of endo-perio lesions. The origin of an infection, being exclusive to the root canal, from the periodontium, or both, is extremely important for devising the treatment plan. In both cases, no clinical evidence of periodontal disease (bleeding, calculus, etc.) was found; however, primary endodontic lesions with the possibility of drainage through the gingival crevice were present. In addition to the disinfection strategies used during the root canal treatments, the bioceramics Bio C Sealer, Bio C Repair and Bio Root RCS were used to fill in the root canals. Both cases presented an impressive bone gain within 8 months for case 1 and 5 months for case 2. Regarding case 1, in the palatal root canal an apical plug with a bioceramic repair cement was used. Based on the literature studied, it can be concluded that after adequate disinfection of the root canals, using bioceramic cements in filling the root canals shows the potential of supporting capabilities in remineralization of osteolytic lesions in endo-perio diseases.

Keywords: Calcium Silicate; Endodontics; Endodontic-periodontal Lesion; Periodontics

Introduction

The first description of an *Endodontic-Periodontal Lesion* (EPL) was released in 1964 [1]. This pathology is a lesion in a tooth which involves pulpal and periodontal tissues at the same time. The two tissues are interconnected through structures such as dentinal tubules, lateral and accessory canals and the apical foramen, the latter being the main connection [2, 3].

Among the classifications of EPLs, the most commonly used is Simon's which classifies the lesions as: primary endodontic lesions, primary endodontic lesions with secondary periodontal involvement, primary periodontal lesions, primary periodontal lesions with secondary endodontic involvement and true combined lesions [4].

A precise diagnosis of EPL is necessary in order to apply a correct treatment. The origin of an infection being exclusive to the root canal system or from the periodontium or both is extremely important for devising the treatment plan. A successful management of EPL depends on eradicating both disease processes [5]. In order to facilitate adequate periapical and periodontium healing, a period of 1 to 3 months has been suggested during endodontic and periodontal treatments, regardless of the presence or absence of any communication between the two lesions [6-10].

The development of new materials and techniques has improved the results of endodontic and periodontal treatments. In the endodontic treatment of an EPL, an efficient disinfection of the root canal system and its complete sealing are essential factors



affecting the periapical lesion's healing [11]. These factors can guarantee a successful periodontal treatment [7].

Sealing capability, antimicrobial activity and biocompatibility are essential properties of a filling material. Bioceramic sealers used in filling root canals have shown significant results regarding their physicochemical properties, biocompatibility and bioactivity. Bioceramics can induce higher secretion of angiogenic and osteogenic growth factors compared to zinc oxide and eugenol-based cements [12].

According to the classification of the American Association of Endodontists (AAE, Endodontic Case Difficulty Assessment Form and Guidelines), EPLs are assorted as cases of high difficulty in endodontic therapy that represent a clinical scenario requiring a complex treatment plan, and consequently impacting the predictability of the treatment outcomes. In view of this, endodontic sealers with the potential to promote faster healing of periapical lesions may present important indications for obtaining a successful treatment for EPLs.

The aim of this study was to describe and discuss two case reports of EPLs in which the bioceramics Bio C Sealer, Bio C Repair (Angelus, Londrina, Brazil) and Bio Root RCS (Septodont, St Maur-des-Fossés, France) were used to fill the root canals.

Case Reports

This study presents two descriptive case reports. Informed written consent was obtained from the patients before the treatments. This study was performed in accordance with all ethical procedures corresponding to case reports. The authors declare that they followed the national research committee ethical standards and the 1964 Helsinki Declaration.

Case 1

A 58-year-old male with ASA 1 status (Classification of the American Society of Anesthesiologists) was referred to a private dental clinic for endodontic evaluation of tooth #26. The patient reported a throbbing pain that reached the left region of his face as chief complaint. Additionally, the patient reported experiencing pain while chewing and the symptoms persisting for 3 days in the previous week. In the clinical examination the patient was precise in identifying the target tooth (tooth #26) and at the time of the consultation, he did not appear to experience any pain. The patient's gingival tissue was normal, with no bleeding or exudation from the gingival sulcus and no sinus tracts were present (Figure 1B,

1C). Periodontal probing showed a deep pocket (6 mm) on the buccal and distal surfaces of tooth #26. On percussion and palpation tests, the patient showed no sensitivity. The periapical radiograph revealed an unsatisfactory endodontic treatment due to wrong apical limit of working length and filling failures (Figure 1A). The presence of a periapical lesion was not detected on the radiograph, and alveolar crest bone loss between teeth #26, #27 was observed. Cone-beam computed tomography (CBCT) was requested to assist diagnosis. The CBCT acquisition was carried out in high resolution and small field-of-view (FOV). The radiograph was dynamically analyzed in the CS 8100 set's software (Carestream, Trophy, France). The analysis of the axial, sagittal and coronal planes revealed extensive bone loss in the distobuccal root and distal interproximal region extending to the furcation area. Furthermore, a big periapical lesion was observed in the apical region of palatal roots of both #26, #27 teeth. The communication between the periapical lesion and bone loss area in the distal region resulted in an EPL diagnosis (Figures 3A, 3B, 3C, 3G). Another concern was regarding the diagnostic hypothesis that tooth #27 had pulp necrosis. This hypothesis was rejected due to the positive response from the cold test performed on tooth #27 that revealed pulp vitality. It led us to indicate only the follow-up of the tooth. After the final diagnosis the treatment plan was presented to the patient.

The treatment was performed in two sessions. On the first visit the filling materials were removed from the root canal with a Reciproc R25 file (VDW, Munich, Germany) and Clearsonic, Flatsonic, and Irrisonic ultrasonic tips (Helse Dental Technology, Santa Rosa de Viterbo, Brazil) (Figure 1D). A second canal (mb2) was located and treated in the mesiobuccal root. A 5.25% sodium hypochlorite (NaOCl) irrigation solution was used in an approximate volume of 30 mL per root canal. NaOCl was activated in each root canal 5 times in cycles of 20 sec with an Easyclean device (Easy, Brazil) driven at maximum speed of the micromotor. Irrigation procedures were equally performed in both sessions. Calcium hydroxide (Ultracal/Ultradent, Indaiatuba, Brazil) was inserted into the root canals at the end of the first session and remained for 14 days.

In the second session the calcium hydroxide was removed from the root canals by NaOCl irrigation and its activation was performed with Easyclean files (Easy, Brazil). The filling procedure was performed by the single cone technique with the bioceramic Bio C Sealer (Angelus, Brazil). The Bio C was injected into the canal through a specific tip that is part of the

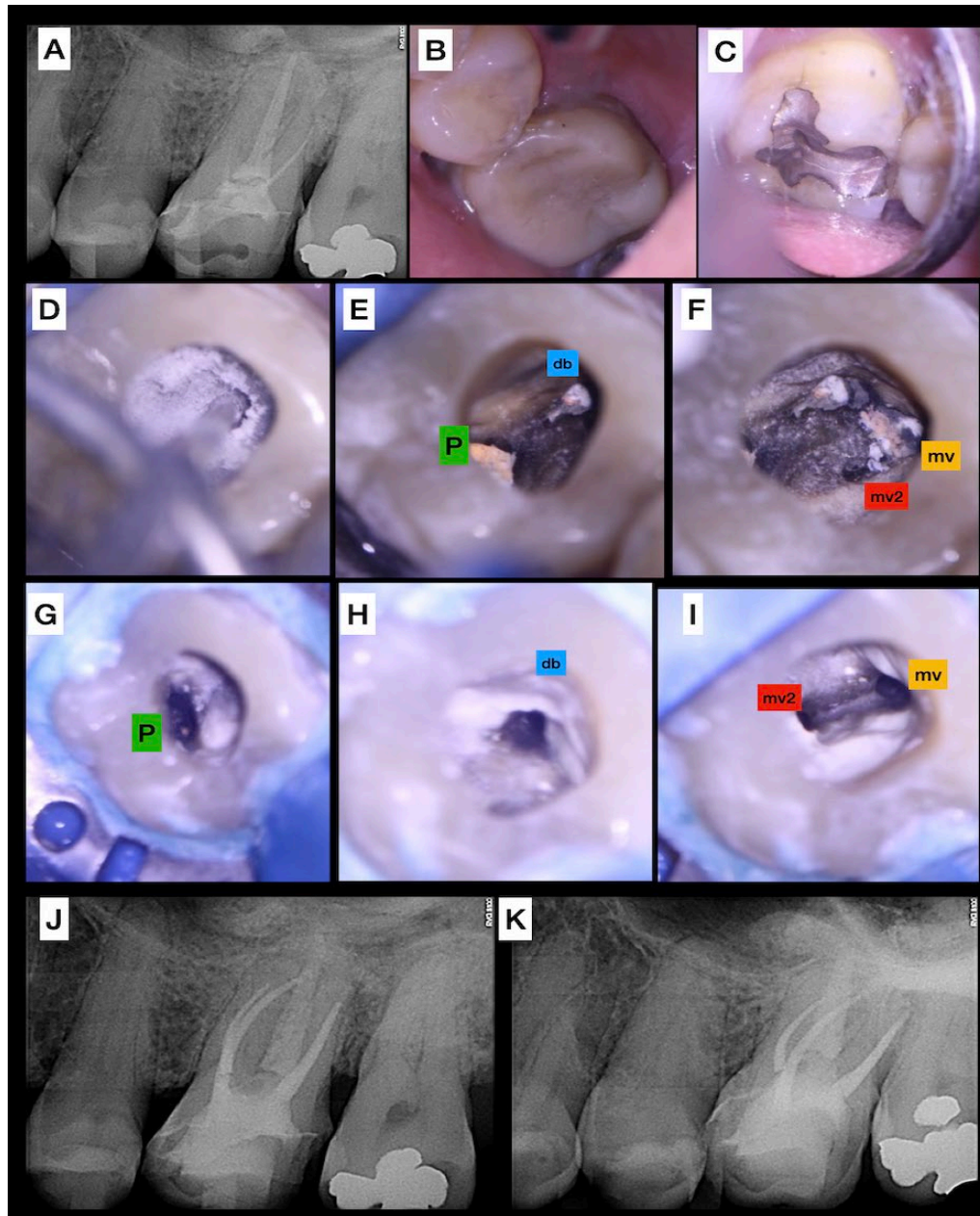


Figure 1. Treatment of case 1, A) Preoperative periapical radiograph; B, C) Preoperative clinical aspects of teeth #26 and #27; D) Ultrasonic tip cleaning the pulp chamber; E, F) the four root canals located; G, H, I) The four root canals cleaned; J, K) Immediate postoperative periapical radiographs; Abbreviations of root canals: mv, mesio-buccal 1; mv2, mesio-buccal 2; db, distobuccal; and P, palatal

sealer kit. Due to the presence of a very wide foramen (final file size #60 tip) in the palatine canal, we made the decision to use a 2 mm apical plug with the Bio C Repair (Angelus, Brazil) prior to the obturation as described above. After the radiographic verification of the filling's quality, the tooth was restored with composite resin (Figures 1J, K) and the patient was instructed to undergo an evaluation with a periodontist. The patient was also instructed to return to the endodontist in 6 months for follow-up of the case. The sequence of the treatment can be seen in Figure 1.

Case 2

A 70-year-old male with ASA 2 status was referred to a private dental clinic for an endodontic evaluation. The patient's chief complaint was a chronic chewing pain in tooth #47. The patient's gingival tissue was normal with no bleeding or exudation from the gingival sulcus, and a sinus tract was present (Figure 2A). Periodontal probing was not performed. The patient showed positive response to percussion and palpation tests. The periapical radiograph revealed the presence of a periapical lesion in the

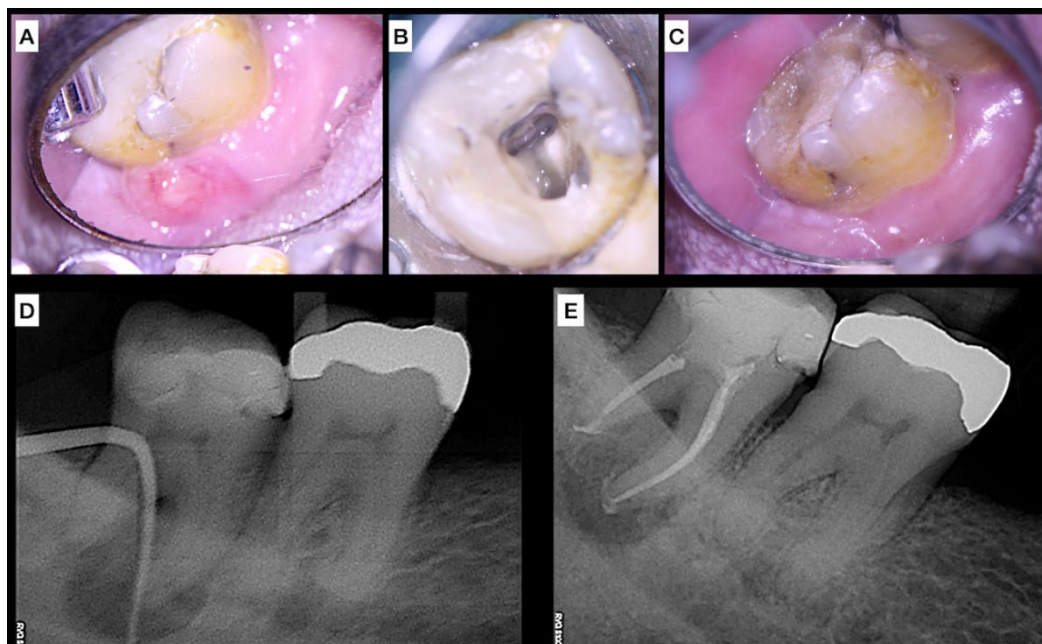


Figure 2. Treatment of case 2, A) Preoperative clinical aspect (sinus tract); B) Access Cavity; C) Absence of the sinus tract 14 days after the first session; D) Preoperative periapical radiograph; E) Immediate postoperative periapical radiograph

mesial root as well as in the furcation area (Figure 2D). The CBCT acquisition and evaluation was carried out similar to Case 1. The analysis of the axial, sagittal and coronal planes revealed extensive bone loss in both roots extending to the furcation area. Furthermore, an extensive bone loss was observed at the lingual cortical plate and the communication between the apical lesion, the furcation area and the cortical lingual plate resulted in an EPL diagnosis (Figures 4C, 4E). After the final diagnosis, the treatment plan was presented to the patient and the treatment was initiated.

The treatment was carried out in two sessions. On the first visit, the pulp chamber was accessed and the root canals were prepared with rotary files (Easy, Brazil) up to file 35.03 (mesial root canals) and file 40.03 (distal root canal). A 5.25% NaOCl irrigation solution was used in an approximate volume of 30 mL per root canal. NaOCl was activated in each root canal 5 times in cycles of 20 sec with an Easyclean device (Easy Dental Equipment, Belo Horizonte, Brazil) driven at maximum speed of the micromotor. The irrigation procedures were equally performed in both sessions. Some calcium hydroxide (Ultracal/Ultradent, Brazil) was inserted into the root canals at the end of the first session and remained for 14 days.

In the second session, the absence of the sinus tract was confirmed (Figure 2C). The calcium hydroxide was removed from the root canals by NaOCl irrigation and its activation was performed with Easyclean files (Easy, Brazil). The filling procedure was performed by the single cone technique with the bioceramic Bio Root RCS (Septodont, St Maur-des-Fossés, France). The Bio

Root RCS was inserted into the canal through a Past Carrier (FKG Dentaire SA, La Chaux-de-Fonds, Switzerland) tip #25. Afterwards, the master gutta-percha cone was placed in the canal with a circular movement to reach the working length. After the radiographic verification of the filling's quality, the tooth was restored with composite resin (Figure 2E) and the patient was instructed to undergo an evaluation with a periodontist. The patient was also instructed to return to the endodontist in 6 months for follow-up of the case. The sequence of the treatment can be seen in Figure 2.

Discussion

The major EPL cases provide a challenging level of complexity for the team of professionals involved in the treatment [13, 14]. These teeth are usually diagnosed with a rapid and extensive destruction of the apical and lateral periodontium's tissues. As EPL teeth are generally assigned a low prognosis, many dentists have made the decision for extraction and subsequent placement of implants. However, it is important to evaluate the consequences of a dental extraction in cases of EPLs. In most cases "bone volume gain techniques" in the alveolus of the involved tooth are required [9]. The level of difficulty in the solution of these cases as technical and biological complications does not exempt risks in the option of treatments that allow the replacement of a tooth by an implant, especially in medically compromised patients [15-17].

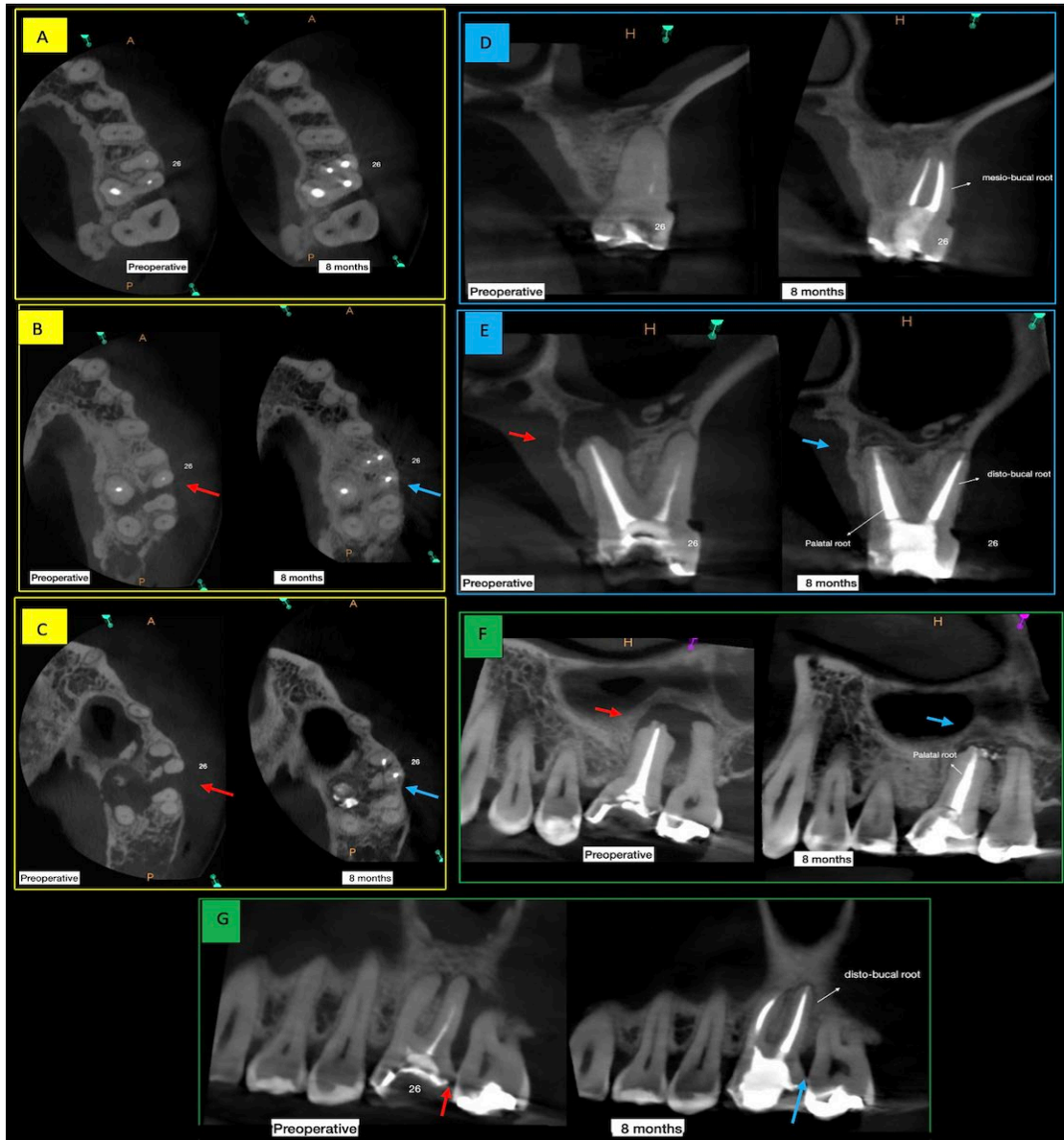


Figure 3. Comparative CBCT images of case 1 (preoperative and after 8 months), A, B, C) Axial sections at cervical, middle and apical thirds, respectively; D, E) Sagittal images; F, G) Coronal images; The red arrows indicate the osteolytic lesion (preoperative) and the blue arrows the bone recovery (postoperative, 8 months after)

The development of new equipment, materials and techniques have improved the success rate of endodontic treatments. Technologies such as operating microscope, ultrasonic, mechanized instrumentation, cone beam tomography have enabled a substantial improvement in the prognosis of complex cases in endodontics [18]. Such technologies used in the presented cases helped us to reassure that the use of these tools provided the success in the endodontic treatments. In addition to all the disinfection strategies used during the root canal treatment, the root canal filling stage is equally important to ensure the treatment's success.

Consequently, the choice of a bioceramic cement for filling root canals in cases of EPLs seems to be promising due to scientific evidences showing that these materials have the potential to promote faster and more predictable healing of the periapical lesion as they stimulate osteogenesis [12, 19-21]. Both cases presented an impressive bone gain within 8 months for case 1 and 5 months for case 2 (Figures 3 and 4). Regarding case 1, in the palatine root canal, because of a large amplitude of the apical foramen we made the decision to use an apical plug with a bioceramic repair cement (Bio C Repair; Angelus, Londrina, Brazil). The Bio C Repair can provide the same benefits as the Bio

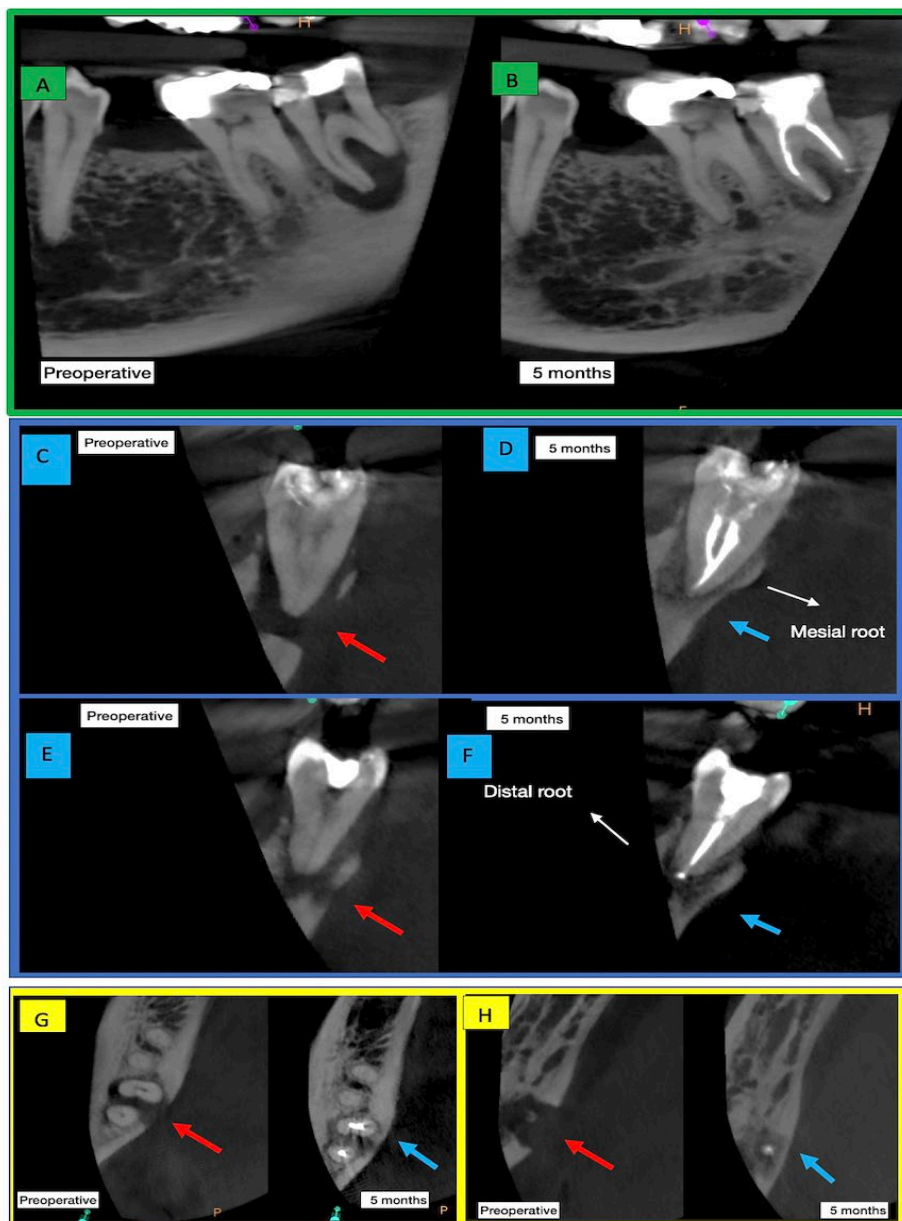


Figure 4. Comparative CBCT images of case 2 (preoperative and after 5 months); A, B) Sagittal images; C, D, E, F) Coronal images; G, H) Axial images at cervical and apical thirds respectively; The red arrows indicate the osteolytic lesion (preoperative) and the blue arrows the bone recovery (postoperative 5 months after)

C Sealer. The main difference is in the Bio C Repair's consistency which is more suitable for handling and inserting inside large apical foramens. The use of Bio C Repair as an apical plug allowed the material to be adapted and condensed without the risk of not flowing too much to the periapical region which could cause filling failures in the apical critical zone of the root canal.

Despite being advised to undergo a periodontal evaluation with a periodontist, the patients did not attend the consultation with the professional. After 5 months (case 2) and 8 months (case 1) of the final sessions of endodontic interventions, they

returned to the endodontist's office and a new CBCT was requested to evaluate the bone recoveries. The CBCT depicted an expressive apical bone recovery in both cases (Figures 3 and 4). Analyzing the bone healings, we can suggest that the diagnosis of both cases was EPLs with primary endodontic lesions and secondary periodontal involvements. Some authors recommend the periodontal treatment of EPLs be applied 1 to 3 months after the completion of an endodontic treatment to wait for the beginning of the periapical repairing process [6-10]. Although it is suggested that the endodontic treatment should

be performed prior to periodontal treatment, it is not possible to determine the best treatment sequence for endodontic-periodontal lesions [22]. However, in cases where the origin of the EPL is from endodontics, the success of endodontic treatment alone can lead to a satisfactory resolution of the EPL case [14]. In both cases, there was a primary endodontic lesion that could be draining through the gingival crevice with no clinical features of periodontal disease (bleeding, calculus *etc*) present. Considering this, the successful endodontic treatment alone may have led to the resolution of the cases. Knowing that we will not always be able to decide the correct origin of the EPL (Endodontics or Periodontics), and that an endodontic treatment should always be the first approach, it is very important to choose endodontic sealers with recognized potential to promote a faster tissue healing process. Therefore, bioceramic sealers should be indicated as first option as root canal filling materials in endodontic treatments of EPL cases.

To this day, we have observed the contribution of bioceramic materials providing an increase in the success levels of complex cases in endodontics. However, more studies must be carried out to validate the bioceramic cements as the first-choice material for filling root canals in teeth affected with EPLs.

Conclusion

Based on the literature studied and the two cases reported, we can conclude that after adequate disinfection of the root canals, the use of bioceramic cements in filling the root canals show the potential of supporting capabilities in the remineralization of osteolytic lesions in EPLs.

Conflict of Interest: 'None declared'.

References

1. Simring M, Goldberg M. The Pulpal Pocket Approach: Retrograde Periodontitis J Periodont. 1964;35(1):22-48.
2. Al-Fouzan KS. A new classification of endodontic-periodontal lesions. Int J Dent. 2014;2014:919173.
3. Alshawwa H, Wang JF, Liu M, Sun SF. Successful management of a tooth with endodontic-periodontal lesion: A case report. World J Clin Cases. 2020;8(20):5049-56.
4. Simon JH, Glick DH, Frank AL. The relationship of endodontic-periodontic lesions. J Periodontol. 1972;43(4):202-8.
5. Rotstein I, Simon JH. Diagnosis, prognosis and decision-making in the treatment of combined periodontal-endodontic lesions. Periodontol 2000. 2004;34:165-203.
6. Abbott PV, Salgado JC. Strategies for the endodontic management of concurrent endodontic and periodontal diseases. Aust Dent J. 2009;54 Suppl 1:S70-85.
7. Aksel H, Serper A. A case series associated with different kinds of endo-perio lesions. J Clin Exp Dent. 2014;6(1):e91-5.
8. Oh SL, Fouad AF, Park SH. Treatment strategy for guided tissue regeneration in combined endodontic-periodontal lesions: case report and review. J Endod. 2009;35(10):1331-6.
9. Pico-Blanco A, Castelo-Baz P, Caneiro-Queija L, Linares-Gonzalez A, Martin-Lancharro P, Blanco-Carrion J. Saving Single-rooted Teeth with Combined Endodontic-periodontal Lesions. J Endod. 2016;42(12):1859-64.
10. Raheja J, Tewari S, Tewari S, Duhan J. Evaluation of efficacy of chlorhexidine intracanal medicament on the periodontal healing of concomitant endodontic-periodontal lesions without communication: an interventional study. J Periodontol. 2014;85(8):1019-26.
11. Narang S, Narang A, Gupta R. A sequential approach in treatment of perio-endo lesion. J Indian Soc Periodontol. 2011;15(2):177-80.
12. Camps J, Jeanneau C, El Ayachi I, Laurent P, About I. Bioactivity of a Calcium Silicate-based Endodontic Cement (BioRoot RCS): Interactions with Human Periodontal Ligament Cells In Vitro. J Endod. 2015;41(9):1469-73.
13. Khojaste M, Navabi S, Shiezadeh F. Treatment of a Hopeless Tooth with Combined Endodontic-periodontal Lesion Using Guided Tissue Regeneration: A Case Report with One Year Follow-up. Iran Endod J. 2022;17(4):212-5.
14. Sonde N, Edwards M. Perio-Endo Lesions: A Guide to Diagnosis and Clinical Management. Prim Dent J. 2020;9(4):45-51.
15. Akbarzadeh Baghban A, Dehghani A, Ghanavati F, Zayeri F, Ghanavati F. Comparing alveolar bone regeneration using Bio-Oss and autogenous bone grafts in humans: a systematic review and meta-analysis. Iran Endod J. 2009;4(4):125-30.
16. Jiang X, Zhu Y, Liu Z, Tian Z, Zhu S. Association between diabetes and dental implant complications: a systematic review and meta-analysis. Acta Odontol Scand. 2021;79(1):9-18.
17. Moy PK, Aghaloo T. Risk factors in bone augmentation procedures. Periodontol 2000. 2019;81(1):76-90.
18. Pereira KFS, Turatto TH, Junqueira-Verardo LB, Limoeiro AGS, Gaetti-Jardim EC. The impact of cone beam computed tomography in diagnosis and endodontic treatment planning decisions case reports. Research, Society and Development. 2021 18 2023; 10(2):[1-10 pp.].
19. Giacomino CM, Wealleans JA, Kuhn N, Diogenes A. Comparative Biocompatibility and Osteogenic Potential of Two Bioceramic Sealers. J Endod. 2019;45(1):51-6.
20. Hajizadeh N, Madani ZS, Zabihi E, Golpour M, Zahedpasha A, Mohammadnia M. Effect of MTA and CEM on mineralization-associated gene expression in stem cells derived from apical papilla. Iran Endod J. 2018;13(1):94-101.
21. Lee BN, Hong JU, Kim SM, Jang JH, Chang HS, Hwang YC, Hwang IN, Oh WM. Anti-inflammatory and Osteogenic Effects of Calcium Silicate-based Root Canal Sealers. J Endod. 2019;45(1):73-8.
22. Friedrich F, Scalabrin SA, Weissheimer T, Rosing CK, So GB, da Rosa RA, So MVR. Influence of the timing of periodontal intervention on periapical/periodontal repair in endodontic-periodontal lesions: a systematic review. Clin Oral Investig. 2023;27(3):933-42.

Please cite this paper as: Pereira KFS, da Silva SO, Bastos HJS, Tomazinho LF, do Nascimento VR, Verardo LBJ, Otani AY. Bioceramic Cements: Supporting in Remineralization of Osteolytic Lesions in Endodontic-periodontal Diseases: A Report of Two Cases. Iran Endod J. 2023;18(4): 264-70. Doi: 10.22037/iej.v18i4.41437.