

# Removal of a Retroperitoneal Foreign Body by Laparoscopic Surgery

Saeki Shinichiro, Yu Wakimoto\*, Hidetake Kamei, Atsushi Fukui, Hiroaki Shibahara

Department of Obstetrics and Gynecology, Hyogo College of Medicine, Nishinomiya, Hyogo, Japan

## Abstract

Migration of intrauterine devices (IUDs) into the abdominal cavity is rare. In this report, we describe a patient in whom a levonorgestrel intrauterine system (LNG-IUS) device was initially misplaced outside of the uterus, likely due to stenosis of the cervix following a conization procedure for carcinoma *in situ*. The patient presented with persistent abdominal pain and vaginal bleeding. The LNG-IUS was not visible on physical examination and ultrasound imaging, requiring intraoperative abdominal radiography and postoperative computed tomography for localization. Once localized, we proceeded with the removal of the foreign body in the retroperitoneal space by laparoscopy. Misplacement of an IUD such as LNG-IUS outside of the uterus after a conization procedure should be suspected in women with persisting symptoms, and this possibility should be diligently assessed.

**Keywords:** Contraceptive device, intrauterine device, intrauterine system, levonorgestrel, perforation

## INTRODUCTION

In Japan, the levonorgestrel intrauterine system (LNG-IUS) was included in the public insurance plan for the treatment of hypermenorrhea and dysmenorrhea in 2014.<sup>[1]</sup> Migration of an intrauterine device (IUD) into the peritoneal cavity is rare, with an incidence rate of 0%–0.28%.<sup>[2]</sup> In this report, we describe a case in which the LNG-IUS was misplaced outside of the uterine cavity, which required removal from the retroperitoneal cavity using a laparoscopic approach.

## CLINICAL IMAGE

A 29-year-old female, gravida 3, para 1, had previously undergone cervical conization, for the treatment of carcinoma *in situ* of the uterine cervix, at the age of 22 years. An LNG-IUS was inserted into the uterus for the treatment of dysmenorrhea and to prevent cervical stenosis at the local clinic at the age of 24 years.

The patient visited our hospital after surgery with persisting abdominal pain and was admitted for investigation. On speculum examination, the LNG-IUS thread was visible; however, due to the previous conization procedure, the location of the uterine cervical canal was difficult to confirm. The foreign body could not be located during vaginal examination. For evacuation of the hematoma, we proceeded the dilation using a 14-Fr catheter, and we attempted to locate and remove the misplaced LNG-IUS [Figure 1]. As we were unable to locate the LNG-IUS, intraoperative radiography was performed, with the device visible outside of the uterine cavity [Figure 2].

Two months after the transcervical procedure, we performed a laparoscopic procedure to remove the foreign body. We inserted a 12-mm trocar through the umbilicus and two 5-mm trocars at both lateral regions and the lower abdomen. After confirmation of the position of the device in the left side retroperitoneal space near ureter [Figure 3], we confirmed

**Address for correspondence:** Dr. Yu Wakimoto,  
Department of Obstetrics and Gynecology, Hyogo College of  
Medicine, 1-1 Mukogawa-Cho, Nishinomiya, Hyogo 663-8501, Japan.  
E-mail: yuwakimoto@gmail.com

### Article History:

Received 31 August 2018

Received in revised form 19 October 2018

Accepted 26 November 2018

Available online 29 April 2019

### Access this article online

#### Quick Response Code:



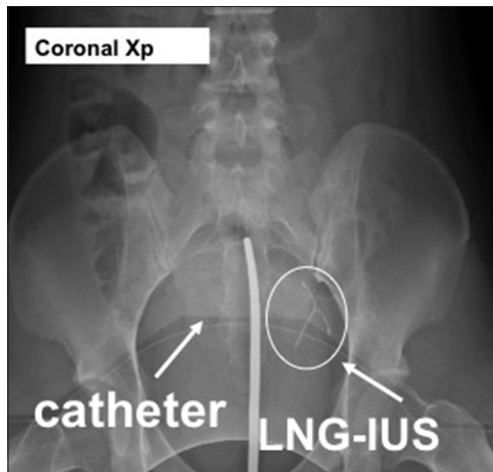
**Website:**  
www.e-gmit.com

**DOI:**  
10.4103/GMIT.GMIT\_84\_18

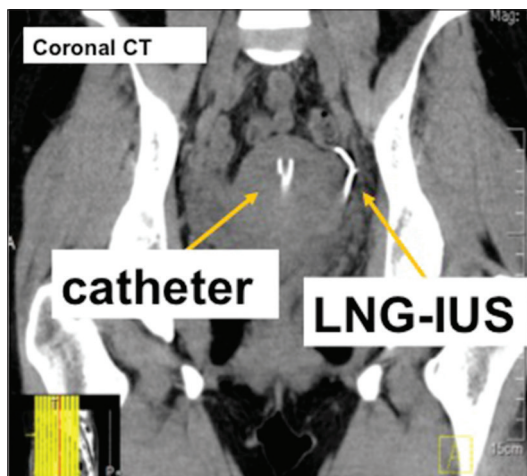
This is an open access journal, and articles are distributed under the terms of the Creative Commons Attribution-NonCommercial-ShareAlike 4.0 License, which allows others to remix, tweak, and build upon the work non-commercially, as long as appropriate credit is given and the new creations are licensed under the identical terms.

**For reprints contact:** reprints@medknow.com

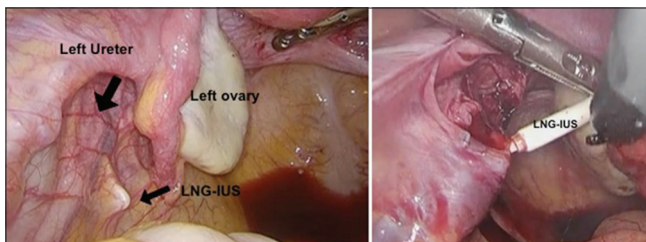
**How to cite this article:** Shinichiro S, Wakimoto Y, Kamei H, Fukui A, Shibahara H. Removal of a retroperitoneal foreign body by laparoscopic surgery. *Gynecol Minim Invasive Ther* 2019;8:86-8.



**Figure 1:** Intraoperative abdominal radiograph at dilation and curettage point showing the location of the levonorgestrel intrauterine system outside of the uterine cavity



**Figure 2:** Postoperative at dilation and curettage point computed tomography confirming the location of the levonorgestrel intrauterine system in the retroperitoneal space. The catheter was implanted during initial dilation and curettage to prevent restenosis



**Figure 3:** Localization of the levonorgestrel intrauterine system under the left ovary in the pelvic peritoneum

the absence of perforation or adhesions to adjacent organs by laparoscopic observation.

The ureters were noted to have bilateral peristalsis transperitoneally. A 1.5-cm linear incision was made in the long axis of the device using monopolar electrical scalpel.

The device was coherent at the retroperitoneal space, and it was removed carefully. The chromotubation was successfully performed to confirm the tubal patency. The retroperitoneal wound was carefully covered with an adhesion barrier (Seprafilm, Kaken Pharmaceutical Co., Ltd. Tokyo, Japan).

The operation time was 1 h 21 min, with minimal blood loss. Abdominal pain resolved completely after surgery.

## DISCUSSION

In our case, the LNG-IUS was incorrectly placed in the retroperitoneum at the time of initial insertion. A previous review of women with a misplaced LNG-IUS indicated that 50% were asymptomatic, 28.7% became pregnant, 17.8% reported abdominal pain, and 4.7% presented with irregular vaginal bleeding.<sup>[3]</sup> The patient in our case was admitted due to persisting lower abdominal pain and vaginal bleeding, both of which were initially considered as resulting from an intrauterine hematoma.

Certainly, there is no need for the removal of an intra-abdominal LNG-IUS in asymptomatic cases,<sup>[4]</sup> except for the purpose of planning a pregnancy, which would require removal to lower the plasma levels of LNG to permit ovulation.<sup>[5]</sup>

In our case, we suspected that the LNG-IUS was incorrectly placed into the retroperitoneum, through the posterior vaginal vault, and did not migrate from the uterus into the peritoneal cavity due to uterine perforation.<sup>[6]</sup> Certainly, IUD migration can cause serious complications, including bowel and bladder perforation, ileus, abdominal abscess, and fistula formation.<sup>[7]</sup> Kno *et al.* reported that an abnormal uterine orientation, such as retroversion or acute reflection, increases the risk of perforation, with 42% of uterine perforation occurring in patients with a retroverted uterus, with the incidence rate of uterine retroversion estimated at 20%–25%.<sup>[8]</sup> Although 43% of women in Kno's case series (16 of 37 cases) did not experience symptoms associated with a perforation of the uterus, the authors did still advocate for the prompt localization and removal of the IUD in these cases to prevent complications and limit the need for a more extensive procedure later. Based on our experience, we propose that it is important to be cognizant of the possibility of IUD migration and therefore to obtain at a minimum upper and lower abdominal radiographs. It would also be advisable to clearly explain the possible complications to patients and stress the importance of annual examinations and regular removal of the IUD.

## CONCLUSION

We describe a case of IUD misplacement in the retroperitoneal space that required removal using a laparoscopic technique. Misplacement of an IUD outside of the uterus after a conization procedure should be suspected in women with persisting symptoms, and this possibility diligently assessed.

### Declaration of patient consent

The authors certify that they have obtained all appropriate patient consent forms. In the form, the patient has given her consent for her images and other clinical information to be reported in the journal. The patient understands that her name and initial will not be published and due efforts will be made to conceal her identity, but anonymity cannot be guaranteed.

### Financial support and sponsorship

Nil.

### Conflicts of interest

There are no conflicts of interest.

### REFERENCES

1. Suzuki A, Imai T. A case of laparoscopic removal of intrauterine contraceptive device perforated to the intraabdominal cavity. *Adv Obstet Gynecol* 2017;69:277-81.
2. Heartwell SF, Schlesselman S. Risk of uterine perforation among users of intrauterine devices. *Obstet Gynecol* 1983;61:31-6.
3. Mosley FR, Shahi N, Kurer MA. Elective surgical removal of migrated intrauterine contraceptive devices from within the peritoneal cavity: A comparison between open and laparoscopic removal. *JSLs*. 2012;16:236-41.
4. Uçar MG, Şanlıkan F, İlhan TT, Göçmen A, Çelik Ç. Management of intra-abdominally translocated contraceptive devices, is surgery the only way to treat this problem? *J Obstet Gynaecol*. 2017;37:480-6.
5. Haimov-Kochman R, Amsalem H, Adoni A, Lavy Y, Spitz IM. Management of a perforated levonorgestrel-medicated intrauterine device--a pharmacokinetic study: case report. *Hum Reprod* 2003;18:1231-3.
6. Goldstuck ND, Wildemeersch D. Role of uterine forces in intrauterine device embedment, perforation, and expulsion. *Int J Women's Health*. 2014;7:735-44.
7. Derrick BJ, Jafri FN, Saul T, Lewiss RE. Perforated uterus with displacement of intrauterine device. *J Emerg Med* 2013;44:1144-5.
8. Kno KA, Chamsy DJ. Perforated intraperitoneal contraceptive devices: Diagnosis, management, and clinical outcomes. *GMIT* 2014;21:596-601.