

Intermittent Internal Fixation With a Locking Plate to Preserve Epiphyseal Growth Function During Limb-Salvage Surgery in a Child With Osteosarcoma of the Distal Femur

A Case Report

Jiong Mei, MD, Ming Ni, MD, Guang-Yao Jia, MD, Yan-Xi Chen, MD, and Xiao-Zhong Zhu, MD

Abstract: Limb shortening is a problem associated with surgery for osteosarcoma of the lower extremity in adolescents, as the tumors frequently occur near the epiphysis. Herein we report the use of a less invasive stabilization system (LISS) and an intermittent fixation method to preserve the growth function of epiphysis in an 11-year-old patient with an osteosarcoma of the distal femur.

The 11-year-old male presented with left knee enlargement and pain for 2 weeks, and magnetic resonance imaging (MRI) and biopsy were consistent with osteosarcoma of the left distal femur. After preoperative chemotherapy, en bloc tumor resection was performed with margins based on MRI findings preserving the epiphyseal growth plate, the tumor cavity was filled with inactivated bone and bone cement, and a LISS was used to stabilize the femur. Aggressive postoperative chemotherapy was given. Approximately 105 weeks after surgery radiography showed that the distal end of the plate had moved superior to the epiphysis along with bone growth. Locking screws were placed in the distal part of the LISS plate to stabilize the re-implanted bone, and external fixation was not needed.

The patient was able to walk with the crutches 1 week postoperatively, and bear weight on the extremity 6 weeks postoperatively. At 6 years after surgery, the patient's height had increased 52 cm, shortening of the affected limb was only 1 cm, and the circumference of the affected limb was 2 cm smaller than that of the contralateral limb. There was no significant discomfort in the affected limb, and there was no gait abnormality. The patient could jump and run, and could participate in sports including basketball and badminton to the same degree as his peers.

In summary, the novel method of bone reconstruction and fixation provided good results in a child with an osteosarcoma of the distal femur. This fixation method preserves the osteogenic function of the epiphysis and restored bone integrity simultaneously, and provides good functional recovery.

(*Medicine* 94(20):e830)

Editor: Holger Cramer.

Received: December 1, 2014; revised: March 20, 2015; accepted: April 8, 2015.

Department of Orthopaedics, Tongji Hospital of Tongji University, Shanghai, China.

Correspondence: Jiong Mei, MD, Department of Orthopaedics, Tongji Hospital of Tongji University, 389 Rd.Xincun, Shanghai 200065, China (e-mail: meijiong@tongji.edu.cn).

The authors declare that there is no conflict of interest exist.

Copyright © 2015 Wolters Kluwer Health, Inc. All rights reserved.

This is an open access article distributed under the Creative Commons Attribution-NonCommercial-NoDerivatives License 4.0, where it is permissible to download, share and reproduce the work in any medium, provided it is properly cited. The work cannot be changed in any way or used commercially.

ISSN: 0025-7974

DOI: 10.1097/MD.0000000000000830

Key Words: epiphyseal preservation, epiphysis, limb salvage, limb shortening, osteosarcoma.

Abbreviations: AO = Arbeitsgemeinschaft für Osteosynthesefragen, LISS = less invasive stabilization system, MRI = magnetic resonance imaging, MSTs = Musculoskeletal Tumor Society, MTX = methotrexate, NA = not available.

INTRODUCTION

Osteosarcoma is most commonly seen in adolescents, and typically occurs during the first 2 decades of life.¹ Though rare, osteosarcoma is the most common primary bone malignancy and accounts for approximately 3.4% of childhood cancers.¹ Tumors often occur in the metaphysis of the distal femur or proximal tibia, and tumor destruction or tumor resection usually damages the epiphysis, which affects bone growth.²⁻⁴ Thus, limb shortening is a significant problem in the management of osteosarcomas in adolescents. While in the past the primary treatment was amputation, currently 80% to 90% of cases can be treated with limb-salvage procedures.²⁻⁴ Limb-salvage surgery, however, has to be individualized and takes into account the tumor stage and location, as well as the presence of metastasis and suitability for chemotherapy.

At present, the primary limb-salvage procedures for patients with malignant bone tumors include artificial prosthesis replacement, allograft implantation, and replantation of the tumor-containing bone after inactivation, all of which have their own unique benefits and drawbacks.²⁻⁴ The less invasive stabilization system (LISS) is an internal fixation system for the distal femur that provides multiple, fixed-angle, proximal and distal locking screws, and is widely used for fixation of distal femoral and proximal tibial fractures.⁵⁻⁷ However, its use in the management of limb-salvage for osteosarcomas of the knee has not been reported.

The purpose of this report is to present the use of an intermittent fixation method using the LISS for preserving the growth function of epiphysis in an 11-year-old male with an osteosarcoma of the distal femur, and briefly review the topic of epiphyseal preservation in cases of bone tumors.

CASE REPORT

Because the case report involved a retrospective analysis of only one patient, the approval of an institutional review board is not required. But this report was prepared in accordance with the Health Insurance Portability and Accountability Act (HIPAA) regulations. The patient's parents/legal guardians provided informed consent for the case data to be published. An 11-year-old male was seen on June 6, 2007 with the complaint of progressive enlargement of the left knee with

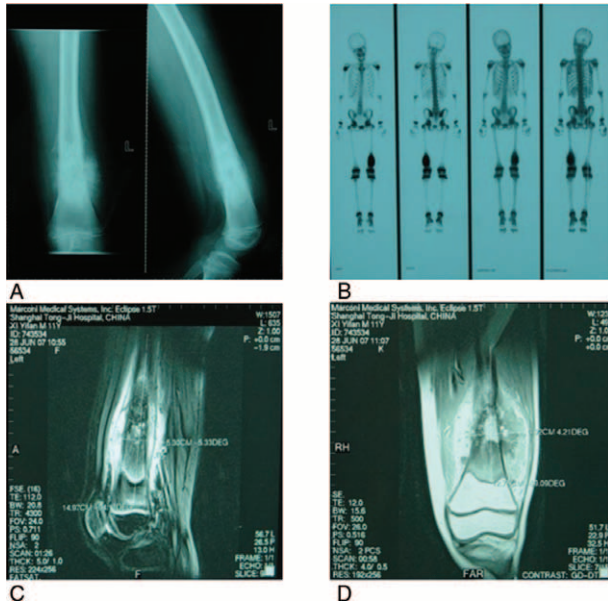


FIGURE 1. (A) Radiography, (B) bone scan, and (C, D) magnetic resonance imaging (MRI) were consistent with an osteosarcoma of the left distal femur.

pain for 2 weeks. Radiography, bone scan, and magnetic resonance imaging (MRI) were consistent with an osteosarcoma of the left distal femur (Figure 1). Biopsy of the lesion confirmed a diagnosis of osteosarcoma.

Six courses of neoadjuvant chemotherapy were planned; however, his parents rejected this because the patient was the only child in the family and they were very concerned about side effects and wanted surgery performed as soon as possible. For these reasons, the chemotherapy plan was changed to 2 courses of methotrexate (MTX) 8.0 g + vincristine (VCR) 2 mg (given concomitantly), 1 course of cisplatin 100 mg, and 1 course of adriamycin 60 mg. The response to the first course of MTX+VCR (given on June 11) was remarkable in that the size of the tumor shrank significantly, and his pain was also markedly relieved, so only 1 additional course of MTX+VCR was given on June 19.

En bloc tumor resection was performed on July 3, 2007 with margins of 3 cm and 2.5 cm from the proximal and distal edge, respectively, of the tumor based on preoperative MRI findings. The resection margin was 3–5 mm superior to the epiphyseal plate in the femoral condyle. After resection, the surgical field was soaked with a nitrogen mustard solution for 5 minutes. The tumor-containing bone was soaked in 95% alcohol for 45 minutes after removing all macroscopic areas of tumor, and then soaked in 100°C water for 10 minutes. To maximize function of the affected limb, a space was reserved in the distal part of the replanted bone after the tumor was removed and cancellous bone particles were placed in it to facilitate rapid bone ingrowth and maintain the stability of the stump. Approximately 2 cm of space was reserved in the medullary cavity for placing cancellous bone particles when filling the proximal part of the tumor shell with bone cement. The cut end was enveloped with the reserved sleeve-shaped periosteum. *In situ* replantation of the inactivated bone was carried out after reinforcement with bone cement and a Kirschner wire. An AO LISS plate was used for fixation. Locking screws were fixed on the epiphysis across

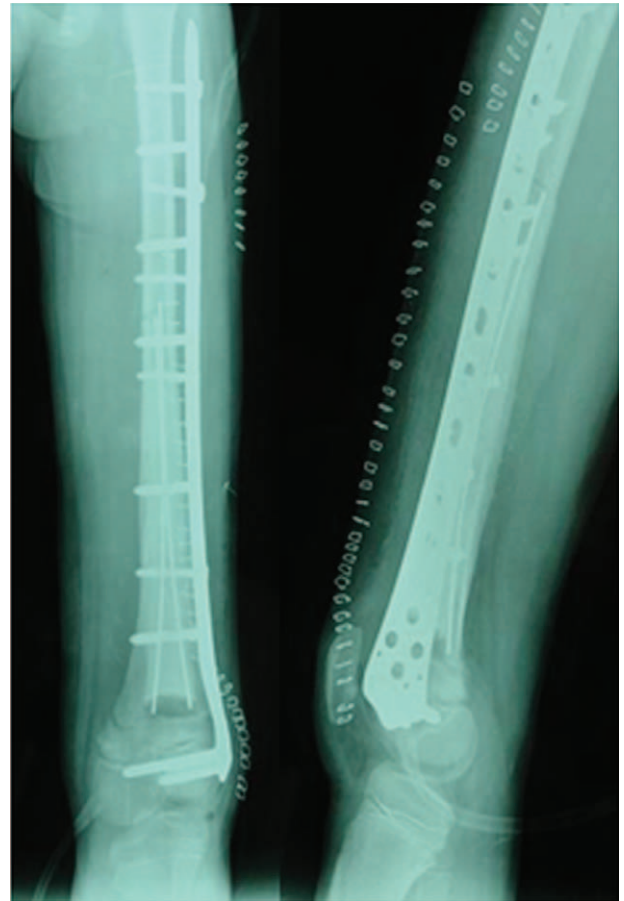


FIGURE 2. Postoperative radiograph of the femur with internal fixation.

the epiphyseal plate in the distal end, and the proximal end of the plate was fixed on the femoral diaphysis (Figure 2).

Aggressive chemotherapy was performed postoperatively (Table 1). At 14 weeks after surgery, callus formation was observed at the end of the osteotomy, and the fixation screws

TABLE 1. Postoperative Chemotherapy Schedule

Week Postoperatively	Chemotherapy
1	Cisplatin 80 mg iv infusion over 48 h
5	Methotrexate 8.0 g iv infusion 4–6 h
6	Methotrexate 8.0 g
8	Epirubicin 60 mg iv infusion
11	Methotrexate 8.0 g
12	Methotrexate 8.0 g
15	Cisplatin 100 mg iv infusion over 48 h
18	Methotrexate 8.0 g
21	Epirubicin 60 mg
24	Methotrexate 8.0 g
25	Methotrexate 8.0 g
47	Methotrexate 8.0 g
58	Methotrexate 8.0 g
80	Cisplatin 100 mg iv infusion over 48 h
106	Epirubicin 100 mg

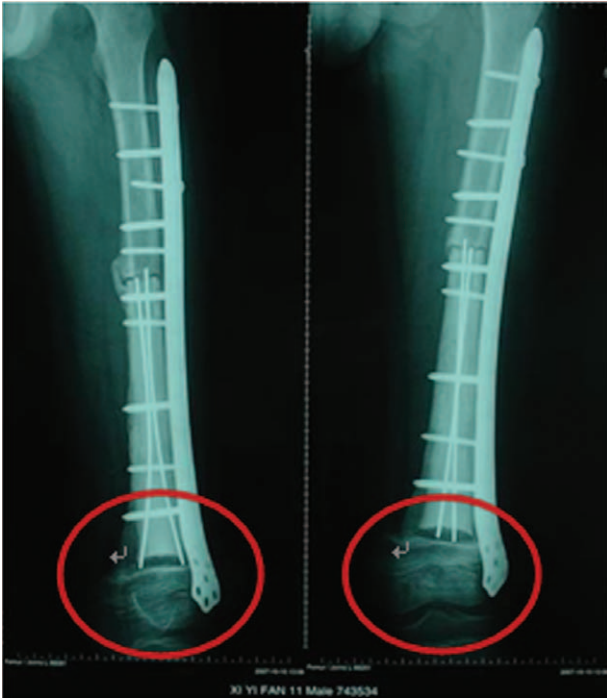

FIGURE 3. At 14 weeks after surgery, callus formation was observed at the end of the osteotomy, and the fixation screws were removed from the epiphysis.

were removed from the epiphysis (Figure 3). On July 9, 2009 (approximately 105 weeks after surgery) radiography showed that the distal end of the plate had moved superior to the epiphysis along with bone growth. Locking screws were placed in the distal part of the LISS plate to stabilize the re-implanted bone (Figure 4), and external fixation was not needed. The patient was able to walk with the crutches 1 week postoperatively, and bear weight on the extremity 6 weeks postoperatively.

Comprehensive examinations performed in 2011, 2012, and on March 12, 2013 showed no tumor recurrence. The

examination in March of 2013 showed that the patient’s height had increased 52 cm during 6 years, shortening of the affected limb was only 1 cm, and the circumference of the affected limb was 2 cm smaller than that of the contralateral limb. There was no significant discomfort in the affected limb, and there was no gait abnormality. The patient could jump and run, and could participate in sports including basketball and badminton to the same degree as his peers.

DISCUSSION

We have reported a good outcome in an 11-year-old male with an osteosarcoma of the distal femur managed with replantation of inactivated bone after removal of the tumor, and stabilization of the reconstructed femur with an LISS. At 6 years of follow-up there was no evidence of recurrence, the affected limb was only 1 cm shorter than the contralateral limb, and the patient can walk and engage in sports without difficulty.

The main limb-salvage procedures for the patients with malignant bone tumors are artificial prosthesis replacement, allograft implantation, and replantation of the tumor-containing bone after inactivation, and each procedure has its own unique advantages and disadvantages.^{8–13} For example, prosthesis reconstruction offers more rapid functional recovery, but is associated with a relatively high long-term failure rate, whereas allografts and autograft replantation are associated with slower functional recovery and early complications, but low long-term failure rates. Expandable prostheses have also shown encouraging results,^{14–16} and the use of physeal distraction prior to tumor resection to preserve the epiphysis has been reported.¹⁷ Regardless of the reconstruction method, if the epiphysis is sacrificed in growing children a length discrepancy will result. However, epiphyseal preservation is not appropriate if the tumor has invaded or is close to the epiphyseal growth plate as complete resection of the tumor is the foundation of surgical treatment. In our case, the possibility of epiphyseal preservation was based on the extent of the tumor determined by preoperative MRI, and the tumor was resected 3–5 mm superior to the epiphyseal plate to preserve the osteogenic function of the epiphysis.¹⁸

In our review of the literature, we found 5 retrospective studies that examined epiphysis preservation surgery in children with lower limb osteosarcoma.^{19–23} Autograft bone was used

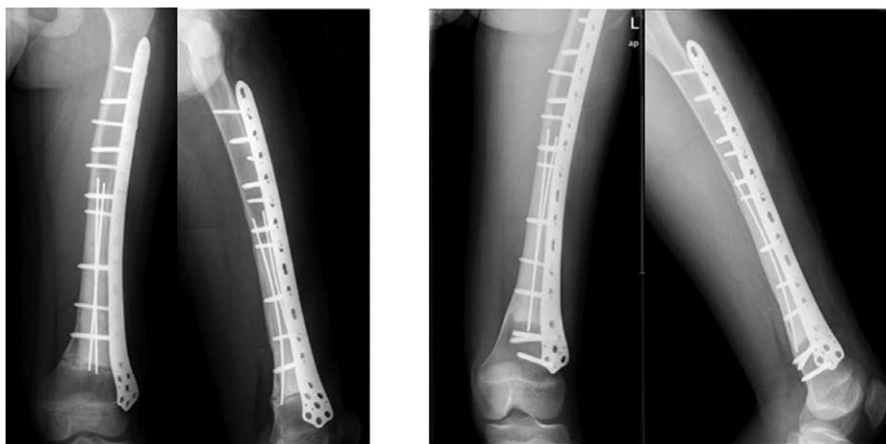

FIGURE 4. (A) Approximately 105 weeks after surgery radiography showed that the distal end of the plate had moved superior to the epiphysis along with bone growth. (B) Locking screws were placed in the distal part of the LISS plate to stabilize the re-implanted bone.

for reconstruction in 13 cases, and allograft bone in the other cases. Methods of fixation included intramedullary nails, intramedullary rods, plates and screws, and the Ilizarov frame. There were 5 deaths of the 58 patients, and in the surviving patients outcomes were generally good with the greatest limb length discrepancy being 3 cm. Cañadell et al.²³ treated 20 patients with epiphyseal preservation, and reported metastasis and mortality rates of 15%. However, the report was from 1994 and imaging and surgical techniques at that time were not as mature as they are currently and malignant tissue may have been left behind. Yu et al.²¹ and Kiss et al.¹⁹ both reported a post-operative fracture rate of 60% with epiphyseal preservation and bone reconstruction; Yu et al. used autograft and intramedullary nails and screws for fixation and Kiss et al. used allograft and Ilizarov frame fixations.

The biomechanical strength of inactivated bone is less than that of the normal bone.²⁴ Although filling the medullary cavity with bone cement can immediately provide stability and strength to the inactivated bone, the bone cement will never degrade and be replaced by new bone. Though evidence of reactivation was observed in the inactivated bone during the later follow-up visits of our patient, thickening of the cortical bone was not obvious.

In this case, the preoperative chemotherapy plan was revised because the patient's response to the first course of MTX+VCR was so remarkable, and because of the parents' wishes. Such a good response to MTX+VCR was quite rare among our osteosarcoma patients. It should also be noted that adjuvant chemotherapy agents are typically based on the percentage of tumor necrosis determined pathologically. However, at the time when this case occurred (7 years ago) our hospital did not have the equipment and expertise to perform an evaluation of percentage of tumor necrosis. For this reason, our evaluation of the tumor response to chemotherapy was based on a combination of patient symptoms, the change in tumor size and diameter (measured by palpation), observed edematous changes around the tumor during surgery, and MRI findings before and after preoperative chemotherapy. Given these limitations, we were fortunate to have a successful outcome in this case.

In summary, we reported a novel method of bone reconstruction and fixation that provided good results in a child with an osteosarcoma of the distal femur. This fixation method preserved the osteogenic function of the epiphysis and restored bone integrity simultaneously, and provides good functional recovery.

REFERENCES

- Geller DS, Gorlick R. Osteosarcoma: a review of diagnosis, management, and treatment strategies. *Clin Adv Hematol Oncol*. 2010;8:705–718.
- Abed R, Grimer R. Surgical modalities in the treatment of bone sarcoma in children. *Cancer Treat Rev*. 2010;36:342–347.
- Caudill JS, Arndt CA. Diagnosis and management of bone malignancy in adolescence. *Adolesc Med State Art Rev*. 2007;18:62–78ix.
- Meyer JS, Mackenzie W. Malignant bone tumors and limb-salvage surgery in children. *Pediatr Radiol*. 2004;34:606–613.
- Devkota P, Manandhar HK, Khadka PB, et al. Less invasive stabilization system for the management of proximal tibia fractures. *Eur J Orthop Surg Traumatol*. 2014;24:993–998. 2013 Nov 20. [Epub ahead of print.]
- Hailer YD, Hoffmann R. Management of a nonunion of the distal femur in osteoporotic bone with the internal fixation system LISS (less invasive stabilization system). *Arch Orthop Trauma Surg*. 2006;126:350–353.
- Schandelmaier P, Partenheimer A, Koenemann B, et al. Distal femoral fractures and LISS stabilization. *Injury*. 2001;32(Suppl 3):SC55–SC63.
- Niimi R, Matsumine A, Hamaguchi T, et al. Prosthetic limb salvage surgery for bone and soft tissue tumors around the knee. *Oncol Rep*. 2012;28:1984–1990.
- Foo LS, Harges J, Henrichs M, et al. Surgical difficulties encountered with use of modular endoprosthesis for limb preserving salvage of failed allograft reconstruction after malignant tumor resection. *J Arthroplasty*. 2011;26:744–750.
- Gosheger G, Gebert C, Ahrens H, et al. Endoprosthetic reconstruction in 250 patients with sarcoma. *Clin Orthop Relat Res*. 2006;450:164–171.
- Hahn SB, Choi YR, Kang HJ, et al. Segmental resection and replantation have a role for selected advanced sarcomas in the upper limb. *Clin Orthop Relat Res*. 2009;467:2918–2924.
- Abdel Rahman M, Bassiony A, Shalaby H. Reimplantation of the resected tumour-bearing segment after recycling using liquid nitrogen for osteosarcoma. *Int Orthop*. 2009;33:1365–1370.
- Siegel HJ, Pressey JG. Current concepts on the surgical and medical management of osteosarcoma. *Expert Rev Anticancer Ther*. 2008;8:1257–1269.
- Schinhan M, Funovics P, Dominkus M, et al. Growing prostheses for reconstruction of lower limb defects in children. *Oper Orthop Traumatol*. 2012;24:235–245.
- Saghieh S, Abboud MR, Muwakkit SA, et al. Seven-year experience of using Repiphysis expandable prosthesis in children with bone tumors. *Pediatr Blood Cancer*. 2010;55:457–463.
- Nystrom LM, Morcuende JA. Expanding endoprosthesis for pediatric musculoskeletal malignancy: current concepts and results. *Iowa Orthop J*. 2010;30:141–149.
- Betz M, Dumont CE, Fuchs B, et al. Physeal distraction for joint preservation in malignant metaphyseal bone tumors in children. *Clin Orthop Relat Res*. 2012;470:1749–1754.
- Kim JH, Kang HG, Kim HS. MRI-guided navigation surgery with temporary implantable bone markers in limb salvage for sarcoma. *Clin Orthop Relat Res*. 2010;468:2211–2217.
- Kiss S, Terebessy T, Szöke G, et al. Epiphysis preserving resection of malignant proximal tibial tumours. *Int Orthop*. 2013;37:99–104.
- Weitao Y, Qiqing C, Songtao G, et al. Epiphysis preserving operations for the treatment of lower limb malignant bone tumors. *Eur J Surg Oncol*. 2012;38:1165–1170.
- Yu XC, Xu M, Xu SF, et al. Long-term outcomes of epiphyseal preservation and reconstruction with inactivated bone for distal femoral osteosarcoma of children. *Orthop Surg*. 2012;4:21–27.
- Muscolo DL, Ayerza MA, Aponte-Tinao LA, et al. Partial epiphysal preservation and intercalary allograft reconstruction in high-grade metaphyseal osteosarcoma of the knee. *J Bone Joint Surg Am*. 2004;86-A:2686–2693.
- Cañadell J, Forriol F, Cara JA. Removal of metaphyseal bone tumours with preservation of the epiphysis. Physeal distraction before excision. *J Bone Joint Surg Br*. 1994;76:127–132.
- Yamamoto N, Tsuchiya H, Nojima T, et al. Histological and radiological analysis of autoclaved bone 2 years after extirpation. *J Orthop Sci*. 2003;8:16–19.