

Late-onset cytomegalovirus pneumonitis successfully treated by cytomegalovirus immunoglobulin in heart transplant patient with renal failure

SAGE Open Medical Case Reports
Volume 9: 1–3
© The Author(s) 2021
Article reuse guidelines:
sagepub.com/journals-permissions
DOI: 10.1177/2050313X21989496
journals.sagepub.com/home/sco



Sandra Jaksic Jurinjak^{1,2} , Vanja Hulak¹
and Mario Udovicic^{1,2}

Abstract

Cytomegalovirus infection is one of the most serious pathogens affecting solid organ transplant recipients. Cytomegalovirus has been identified as a risk factor for graft rejection, cardiac allograft vasculopathy and is associated with increased morbidity and mortality. Viral clearance is not achieved in all patients despite standard antiviral therapy; therefore, there is great interest in prevention and treatment strategies, as use of specific cytomegalovirus immunoglobulin, to avoid progression to organ involvement. Dose regimen of specific cytomegalovirus immunoglobulin is not well studied, especially in cytomegalovirus disease. We present the case of late onset of tissue invasive disease, pneumonitis, in young female patient after heart transplantation with acute renal failure, successfully treated with frequent intermittent cytomegalovirus immunoglobulin followed by renal dosed ganciclovir.

Keywords

Cytomegalovirus, pneumonitis, heart transplantation, cytomegalovirus immunoglobulin

Date received: 24 September 2020; accepted: 4 January 2021

Introduction

Standard treatment of cytomegalovirus (CMV) infection or CMV disease after solid organ transplantation is intravenous ganciclovir and oral valganciclovir, but even when exposure to standard antiviral drugs is adequate, viral clearance is not always achieved.^{1–3} In some cases, underexposure or discontinuation of standard antiviral drugs is required, leading to other treatments, as CMV immunoglobulin (CMVIG), which can be used in the treatment of CMV infection or disease in solid organ transplant recipients (SOTRs).^{3–5} There is lack of data especially of effective dose regimen.^{4,5} We present the case of late-onset CMV pneumonitis successfully treated by CMVIG followed by renal dosed ganciclovir in heart transplant patient with renal failure.

Case report

A 40-year-old female, who received heart transplantation in January 2019, developed in June 2019 fatigue, mild dyspnoea and fever. She was treated for non-Hodgkin lymphoma in 2008 and 2014 for relapse. In November 2014, she developed overt

congestive heart failure, leading to left ventricular assist device (LVAD) implantation and temporary right ventricular assist support (RVAD). In the course of next 3 years, she developed pneumonia, sepsis and successfully treated pump thrombosis. At the time of heart transplantation, donor was seropositive for CMV and she was CMV-negative (D+/R–), defined as high-risk serostatus. Initial anti-CMV prophylaxis was ganciclovir I.V., switched to valganciclovir (standard dose) for 24 weeks after heart transplantation. Post-transplant CMV viral load was undetectable during prophylaxis period. The induction therapy at transplantation comprised thymoglobulin and maintenance therapy of mycophenolate mofetil, prednisolone and cyclosporine. At admission, in June 2019, severe chronic renal failure (glomerular filtration rate: 32 mL/min) was attributed to

¹Institute for Cardiovascular Diseases, Clinical Hospital Dubrava, Zagreb, Croatia

²School of Medicine, University of Zagreb, Zagreb, Croatia

Corresponding Author:

Sandra Jaksic Jurinjak, University Hospital Centre Zagreb, Department of Cardiovascular Diseases, Kispaticeva 12, 10000 Zagreb, Croatia.
Email: sjaksicj@gmail.com; sandra.jaksic.jurinjak@kbc-zagreb.hr



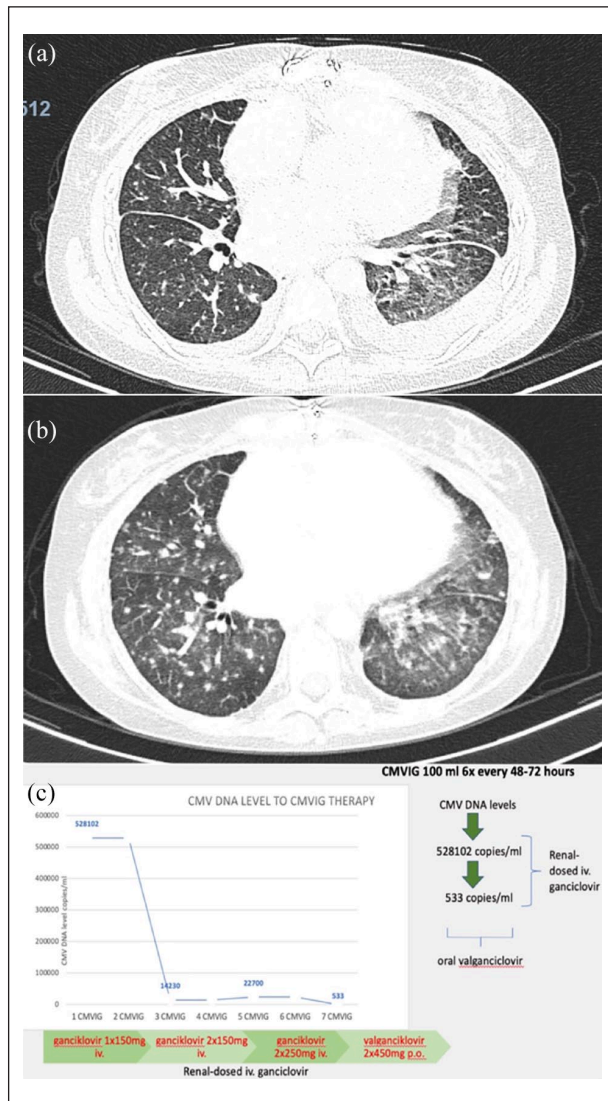


Figure 1. (a) MSCT thorax in 40-year-old female after heart transplant revealed bilateral pneumonitis as bilateral ground-glass opacification (GGO) with some diffuse consolidation and (b) partial regression of bilateral pneumonitis after 4 weeks of combined antiviral therapy with ganciclovir and CMV immunoglobulin therapy. (c) CMV DNA level in 100 mL (2 mL/kg) every 48–72 h regimen in addition to renal dosed ganciclovir (started at 150 mg I.V. and gradually raised). Drop of CMV DNA level from up to 528,102 copies/mL to 533 copies/mL. CMVIG: cytomegalovirus immunoglobulin.

immunosuppressive treatment and pre-renal origin. Other findings were not remarkable, except for elevated NT-pro-BNP levels. There was no sign of hypogammaglobulinemia. Chest X-ray was inconclusive and led to multi-slice computed tomography (MSCT) of the thorax which revealed bilateral pneumonitis with ground-glass opacification and diffuse consolidation (Figure 1(a)). CMV viral load at admission was elevated up to 528,102 UI/mL (Cobas AmpliPrep/Cobas Taqman CMV). Bronchoalveolar lavage proved polymerase chain reaction (PCR) positive for CMV and negative for other known

pathogens, as well as serum. Because of acute renal failure at admission, underexposure to standard antiviral agent, ganciclovir I.V., was necessary and led to decision to start treatment with CMVIG. Treatment of CMVIG was defined as “intensive” regimen of 2 mg/kg (100 mL I.V.) given every 48–72 h for a total of six doses and additional doses weekly after initial regimen. Renal dosed ganciclovir I.V. was subsequently added during the period of first week. Mycophenolate mofetil and tacrolimus levels were at lower dose for 3 weeks, and prednisone dosage was increased. Myocardial biopsy procedure samples revealed mild graft rejection-grade ISHLT (*International Society for Heart and Lung Transplantation*), ACR (acute cellular rejection) 1R (1B) and AMR (antibody-mediated rejection) grade 0. Echocardiography showed no significant signs of graft rejection. CMV viral load consistently lowered with combined therapy (Figure 1(c)) and became undetectable after 6 weeks of therapy (<150 CMV DNA copies/mL). CMV viral load remains undetectable in the follow-up. The patient made a complete clinical recovery and was discharged with maintenance renal dosed valganciclovir therapy and immunosuppression (Figure 1(b)). She has no signs of rejection on repeated graft myocardial biopsy.

Discussion

The highest rates of both CMV infection and disease in SOTR are seen in lung and heart–lung transplant patients, up to approximately 40%.^{1,2} CMV is a risk factor for graft rejection, cardiac allograft vasculopathy and is associated with increased morbidity and mortality; standard intravenous ganciclovir and oral valganciclovir are used for CMV prophylaxis, infection and disease.^{3–5} Pre-transplant testing of CMV serostatus of donor and recipient (D/R) are key predictors of the risk of CMV involvement after transplant and guide decisions on antiviral prophylaxis or preemptive treatment, high risk defined as donor positive and recipient negative serostatus (D+/R–).^{5,6} Available data suggest that CMVIG is beneficial prophylactic treatment in preventing CMV disease, particularly in high risk, (D+/R–) heart and lung transplant patients, but prophylaxis with CMVIG alone is not advisable.^{5–8} Dose regimen of specific CMVIG is not well studied and most of the data, especially in use other than prophylaxis as late-onset CMV infiltrative disease, are drawn from few published cases.^{5–7} Late-onset CMV disease is defined as disease occurring after prophylaxis discontinuation, as in our patient.⁵ Post-transplant CMV disease can occur because of transmission from the transplanted organ, reactivation of latent infection or in seronegative transplant patients after a primary infection.^{5,6} Transplant-specific “indirect effects” of CMV as higher rates of all types of infection can also occur.⁵ There is an increased risk of complications in case of short course of antiviral prophylaxis compared with extended antiviral prophylaxis, but prolonged therapy of ganciclovir may lead to severe toxicity, most dangerous being bone marrow toxicity with severe cytopenia.⁹ Late onset of CMV disease is of particular concern. If invasive disease develops or ganciclovir

resistance emerges, a drug with significant nephrotoxicity, fos-carnet, can be used. Available data suggest that CMVIG as addition to standard antiviral therapy, may provide an additional benefit in preventing CMV disease or chronic rejection in thoracic transplant recipients.¹⁰ CMVIG has favorable safety profile compared with other antiviral agents, therefore, can be safely used as therapy in patients with leucopenia due to ganciclovir, in patients who are under intense immunosuppression or in patients who are intolerant to antiviral agents or need renal adjusted doses.¹⁰ Most of the data support prophylactic use of CMVIG in addition to standard antiviral drugs, but dose and efficacy primarily for the treatment of CMV disease are yet to be proven. A retrospective study by Valantine et al.¹¹ of D+/R- transplant patients found that the rate of CMV disease was significantly lower and survival increased in the group that received the combination of CMVIG and ganciclovir-combined therapy. Zamora et al.¹² found that CMV disease was significantly lower in high-risk (D+/R-) lung transplant recipients receiving valganciclovir/ganciclovir and CMVIG, requiring length of valganciclovir prophylaxis at least 180 days. All studies highlighted the issues of further investigation and possible assessment of effective dosing of CMVIG. Adequately sized prospective studies of CMV infection and disease treatment in SOTR and investigation of immunomodulatory effect of CMVIG that could partially explain some of the benefits observed with CMVIG are lacking. Use of CMVIG is up to expert consensus in specific transplant centers, mainly adding CMVIG to standard antiviral therapy for high-risk patients.¹² Data supporting particular approach in treatment of CMV disease in SOTR are limited. In our case, we successfully used CMVIG 2mg/kg I.V., every 48–72h as intense intermittent treatment, followed by renal dosed ganciclovir in the treatment of CMV pneumonitis in heart transplant patient.

Conclusion

We suggest that CMVIG therapy and proposed “intense” regimen of specific dosages, along with titration of immunosuppressants can be safely used as treatment of late-onset infiltrative CMV disease in transplant patients who need reduced dose of standard antiviral drugs as in our case. Considering the era of new viral pathogens, control of CMV by adopted therapy protocols so that graft loss in transplant patients does not occur is paramount.

Author contributions

All authors listed have made a substantial, direct and intellectual contribution to the work and approved it for publication.

Declaration of conflicting interests

The author(s) declared no potential conflicts of interest with respect to the research, authorship and/or publication of this article.

Ethical approval

Our institution does not require ethical approval for reporting individual cases or case series.

Funding

The author(s) received no financial support for the research, authorship and/or publication of this article.

Informed consent

Written informed consent was obtained from the patient for their anonymized information to be published in this article.

ORCID iD

Sandra Jaksic Jurinjak  <https://orcid.org/0000-0002-7349-6137>

References

- Potena L, Grigioni F, Magnani G, et al. Prophylaxis versus preemptive anti-cytomegalovirus approach for prevention of allograft vasculopathy in heart transplant recipients. *J Heart Lung Transplant* 2009; 28(5): 461–467.
- McDevitt LM. Etiology and impact of cytomegalovirus disease on solid organ transplant recipients. *Am J Health Syst Pharm* 2006; 63(19 Suppl. 5): S3–S9.
- Perrotet N, Manuel O, Lamoth F, et al. Variable viral clearance despite adequate ganciclovir plasma levels during valganciclovir treatment for cytomegalovirus disease in D+/R- transplant recipients. *BMC Infect Dis* 2010; 10: 2.
- Fellay J, Venetz JP, Aubert JD, et al. Treatment of cytomegalovirus infection or disease in solid organ transplant recipients with valganciclovir. *Transplant Proc* 2005; 37: 949–951.
- Kotton CN, Kumar D, Caliendo AM, et al. The third international consensus guidelines on the management of cytomegalovirus in solid-organ transplantation. *Transplantation* 2018; 102(6): 900–931.
- Singh N. Preemptive therapy versus universal prophylaxis with ganciclovir for cytomegalovirus in solid organ transplant recipients. *Clin Infect Dis off Publ Infect Dis Soc Am* 2001; 32: 742–751.
- Boeckh M and Geballe AP. Cytomegalovirus: pathogen, paradigm, and puzzle. *J Clin Invest* 2011; 121(5): 1673–1680.
- Gandhi MK and Khanna R. Human cytomegalovirus: clinical aspects, immune regulation, and emerging treatments. *Lancet Infect Dis* 2004; 4(12): 725–738.
- Humar A, Lebranchu Y, Vincenti F, et al. The efficacy and safety of 200 days valganciclovir cytomegalovirus prophylaxis in high-risk kidney transplant recipients. *Am J Transplant* 2010; 10: 1228–1237.
- Aguado JM, Gomez-Sanchez MA, Lumbreras C, et al. Prospective randomized trial of efficacy of ganciclovir versus that of anti-cytomegalovirus (CMV) immunoglobulin to prevent CMV disease in CMV-seropositive heart transplant recipients treated with OKT3. *Antimicrob Agents Chemother* 1995; 39(7): 1643–1645.
- Valantine HA, Luikart H, Doyle R, et al. Impact of cytomegalovirus hyperimmune globulin on outcome after cardiothoracic transplantation: a comparative study of combined prophylaxis with CMV hyperimmune globulin plus ganciclovir versus ganciclovir alone. *Transplantation* 2001; 72: 1647–1652.
- Zamora MR, Nicolls MR, Hodges TN, et al. Following universal prophylaxis with intravenous ganciclovir and cytomegalovirus immune globulin, valganciclovir is safe and effective for prevention of CMV infection following lung transplantation. *Am J Transplant* 2004; 4(10): 1635–1642.