

Original paper

Corona mortis variant of the obturator artery: a systematic study of 300 hemipelvises by means of computed tomography angiography

Simone Perandini^{A,B,C,D,E,F}, Alessio Perandini^{A,E,F}, Gino Puntel^{A,B,C,E,F}, Giovanni Puppini^{A,D}, Stefania Montemezzi^{A,D,E}

Azienda Ospedaliera Universitaria Integrata Verona (AOUI), Verona, Italy

Abstract

Purpose: The purpose of the present study is to systematically assess the prevalence and characteristics of the *corona mortis* (CM) variant of the obturator artery by means of computerised tomography angiography (CTA).

Material and methods: A total of 150 consecutive patients (112 males, average age 73 years) referred to CTA for lower limb arterial evaluation were included in this retrospective study. Patient demographics, anastomosis incidence, artery diameter, distance from the symphysis pubis, Kellgren-Lawrence score, and pelvic size were evaluated.

Results: In this study 40.6% of patients presented at least one competent CM arterial anastomosis. In the 300 evaluated arteries, 90 arterial anastomoses were found (30%), 40 on the right side (average diameter 1.63 mm) and 50 on the left side (1.78 mm). In 32 cases there was only one anastomosis, while in 29 cases the CM was bilateral. No anastomoses were detected in 89 patients. Mean distance from the symphysis was 50 mm. No relevant association with hip osteoarthritis was found for CM. Mean pelvic size was 213 mm.

Conclusions: The evidence from this study suggests that CM is a common variant that needs to be acknowledged before pelvic intervention.

Key words: *corona mortis*, computerised tomography angiography, variant anatomy.

Introduction

The obturator artery is a small vessel that provides vascular supply to the pelvis and proximal lower limb. It usually arises from the anterior branch of the internal iliac artery, travelling along the pelvic sidewall, between the obturator nerve and vein, reaching the obturator foramen. It supplies the muscles along its course, part of the head of the femur, and also provides vascular supply to the knee. One variant of the obturator artery is known as *corona mortis* (CM, literally “crown of death”), because of the life-threatening surgical implications derived from its misrecognition. In the CM variant the obturator artery receives its vascular supply from the deep inferior epigastric artery, which typically arises from the external iliac artery. In this condition an artery crosses the pubic ramus and runs in the retropubic space, predisposing to injury

during various surgical interventions, such as hernia repair, lymph node dissection, and anterior approach to the acetabulum among many others. Several cadaveric studies have reported its incidence to be between 19% and 43% of the cases [1-5].

Furthermore, computed tomography angiography (CTA) can depict small arterial vessels *in vivo* in a comparable fashion to conventional catheter angiography (Figure 1). Small radiographic studies have been performed to assess the prevalence of the CM variant on CTA, yielding a variable prevalence between 28.5 and 33% of the cases [6,7].

More recently a wider computed tomography (CT) study [8] reported arterial anastomosis in 66 (33%) out of 200 of the evaluated arteries, with an average distance of 55.2 mm from the symphysis pubis.

The most common clinical presentation of CM injuries is haemorrhage, often in the form of retro-pubic

Correspondence address:

Dr. Simone Perandini, AOUI Verona, Piazzale Aristide Stefani 1, 37124 Verona, Italy, e-mail: mail@simoneperandini.com

Authors' contribution:

A Study design · B Data collection · C Statistical analysis · D Data interpretation · E Manuscript preparation · F Literature search · G Funds collection

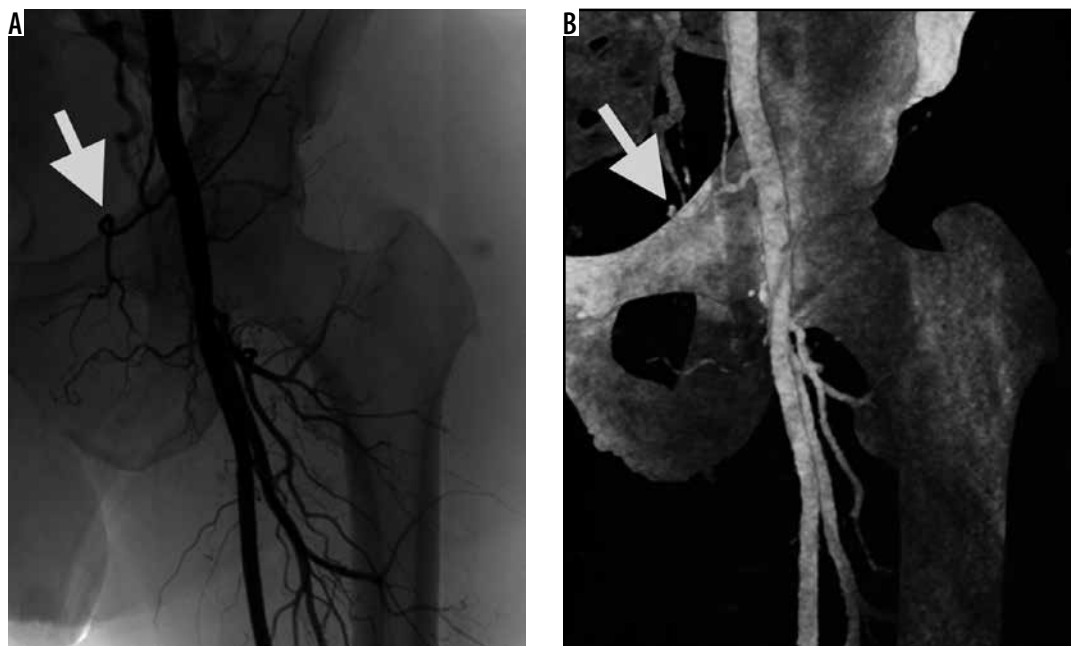


Figure 1. Angiographic run-off (A) and shaded surface rendering of a vascular CT study (B) showing the presence of the arterial corona mortis variant on the left side (arrowheads), with a large-calibre artery arising from the left external iliac artery and coursing above the pubic bone

haematoma. Besides the surgical setting, there is also the chance of a direct traumatic damage in pelvic fractures, especially from high-energy trauma.

If technically feasible, direct endovascular catheterisation and subsequent embolisation is the therapy of choice.

The scope of this article is to provide an accurate assessment of the prevalence and characteristics of the CM arterial variant by analysing the largest set of consecutive data published to date. Additionally, we aim to evaluate for possible correlation with hip osteoarthritis and demographic data by using a homogeneous, reproducible, and technically updated CTA technique.

We believe the radiologist should be aware that providing this information to the surgeon can lead to a substantial decrease in the risk of surgical procedures that involve the pubic area.

Material and methods

Patient gender, age, BMI, arterial CM incidence, vessel diameter and distance from the pelvic symphysis, inter-acetabular distance, as well as Kellgren-Lawrence score for each coxofemoral articulation, were collected in a subset of 150 consecutive patients who were previously enrolled in a vascular CT investigation and were deemed fit to retrospectively evaluate the required parameters.

All CTAs were acquired using a 256-slice multi-detector row CT (Philips iCT).

Scan parameters for the contrast-enhanced phase were: slice thickness 1 mm, increment 0.5 mm, DoseRight Z-DOM, 100 kV, FOV 350 mm, IRT iDose 5, sharp filter, and matrix size 512 × 512. Injector parameters were as follows: 100 ml of iodinated material (350 mgI/ml), 4.0 ml/s

infusion, starting 17 seconds after adequate ROI opacification.

All examinations were performed by a narrow group of CT technicians (four specialised CT technicians with at least five years of service each), who were instructed and trained to perform the examination. CTAs were performed between May 2015 and May 2016. These scans had all been performed for the evaluation and staging of peripheral occlusive arterial disease and were not scheduled for the purpose of this study.

Gender, age, and BMI were already stored in a database and were easily extracted.

Arterial CM incidence was evaluated by analysing the hemipelvises included in the CT dataset on a professional workstation (Figure 2).

Vessel diameter was assessed by semi-automatic segmentation of lumen on the same workframe. In the case of conic or irregular arteries the diameter was collected at the height of the superior pubic ramus.

Distance from the pelvic symphysis was assessed by measuring the length of the upper profile of the superior pubic ramus from the articular cartilage to the position of the variant artery on coronal images.

Inter-acetabular distance was defined as the distance of the centres of the acetabulums, as previously reported [8].

Kellgren-Lawrence score was used to evaluate hip osteoarthritis, as follows:

- grade 0 (normal): no features of hip osteoarthritis;
- grade 1 (Doubtful): minute osteophytes;
- grade 2 (Mild): definite osteophytes with preserved joint space;
- grade 3 (Moderate): definite osteophytes along with moderate joint space narrowing (articular space < 2 mm);

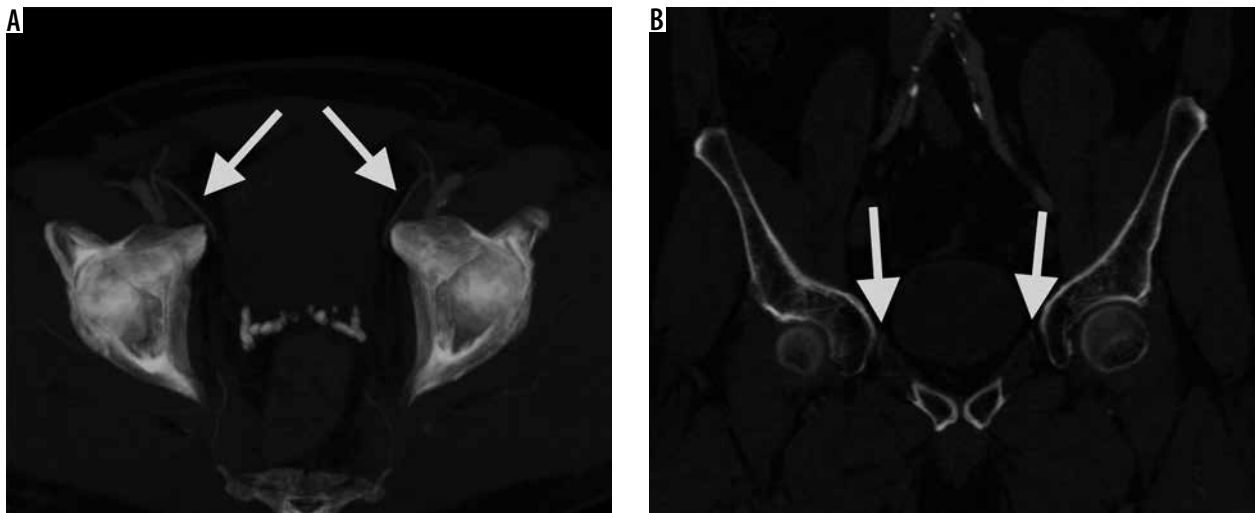


Figure 2. Bilateral presence of arterial *corona mortis* (arrowheads) as depicted in an axial 20-mm-thick MIP reconstruction (A) highlighting the origins of the arteries and in a coronal view (B) as they course above the pubic ramus

- grade 4 (Severe): definite osteophytes along with severe joint space narrowing and subchondral sclerosis [9].

The method described by Turmezei [10] was deemed complicated and far beyond the scope of providing evidence of correlation between CM presence and osteoarthritis.

All statistical analyses were performed using (Med-Calc Software bvba, Ostend, Belgium).

This study was approved by the Ethics Committee of Azienda Ospedaliera Universitaria Integrata Verona and was performed analysing retrospectively acquired data (CT-A and demographics).

Results

Three hundred hemipelvises from 150 consecutive patients were assessed. The population consisted in 38 females and

112 males. Average age was 73 years, ranging from 22 to 95 years.

All data were collected from 150 CTA run-offs in patients referred for peripheral arterial occlusive disease.

A total of 90 (30%) arterial CMs were found, from 300 evaluated arteries, 40 on the right side and 50 on the left side. The anastomosis was unilateral in 32 patients (21.33%) and bilateral in 29 patients (19.33%) (Figure 3).

No anastomosis was detected in 89 patients (59.33%). At least one arterial CM was detected in 61 (40.67%) patients.

The average vessel calibre was 1.7 mm, ranging from 0.8 to 3.2 mm. A slightly larger, but statistically unreliable ($p > 0.05$), average size of arteries on the left size was noted (right 1.63 mm, left 1.78 mm).

Distance from the symphysis to the artery was 50 mm (right 50.5 mm, left 49.6 mm), ranging from 42 to 72 mm.

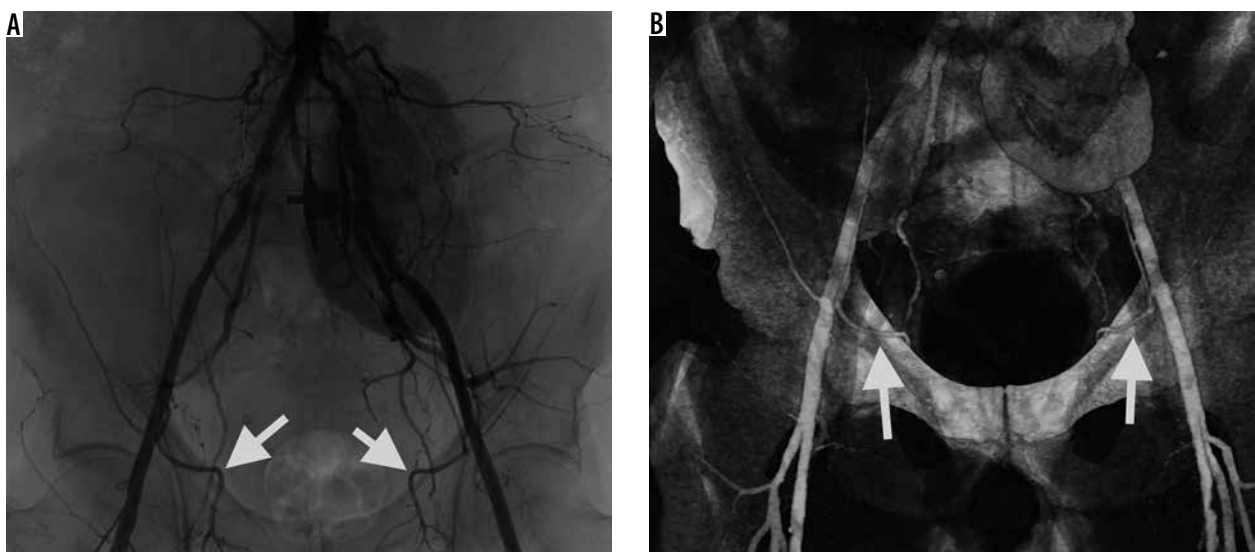


Figure 3. Bilateral presence of arterial *corona mortis* (arrowheads) in a kidney-transplanted patient. The angiographic run (A) as well as the volume rendering reconstruction (B) show *corona mortis* vessels

The average inter-acetabular distance was 213 mm, ranging from 196 to 251 mm. Eleven arterial CMs were found in the 22 patients, with an interacetabular distance inferior to 205 mm.

Average BMI was 25.24 (range 13.84-36.32).

Average Kellgren-Lawrence score was 1.73 (right 1.77, left 1.68).

No significant correlation was found between BMI and prevalence of CM ($r = 0.02839$, $p = 0.7302$), age and prevalence of CM ($r = 0.1031$, $p = 0.2140$), interacetabular distance and prevalence of CM ($r = 0.03175$, $p = 0.6997$), Kellgren-Lawrence score of the right hip and prevalence of CM on the right side ($r = -0.04888$, $p = 0.5552$), and Kellgren-Lawrence score of the left hip and prevalence of CM on the left side ($r = -0.01883$, $p = 0.8222$).

Discussion

Corona mortis variant of the obturator artery is a well-known threat in the surgical theatre in procedures that affect the pubic area. It has been reported as a source of potential bleeding in trauma, orthopaedic, urological, and gynaecological procedures [11-15].

Corona mortis is of particular interest in many oncological surgeries that require systematic pelvic lymphadenectomy and wide opening of the paravesical and obturator spaces. Dissection of the distal part of the pelvic side wall parallel to the external iliac artery requires awareness and expertise due to the frequent presence of CM anastomotic vessels perpendicularly crossing above the obturator nerve from its lateral to its medial aspects. In the last decades development of minimally invasive surgery helped surgeons to recognise anatomical variations thanks to laparoscopic or robotic high-quality images, so dramatic events during this kind of procedure are rare if done by skilled professionals. Urologists and urogynaecologist surgeons have developed a number of scarless procedures in the last few years, for the treatment of incontinence and pelvic organ prolapse, which use vaginal access and the obturator membrane as an anchorage point, or its transfixion for mesh support. Even if uncommon, surgeons should be aware that arteriosus CM damage at this level could result in dramatic bleeding and a potentially life-threatening situation that may be hard to manage. In such cases endovascular embolisation is often the first-line treatment requested.

There is, on the other hand, a lesser degree of awareness among radiologists, despite the life-threatening consequences of a misdiagnosis. For this reason, we believe that radiologists, and to a greater extent those who deal with vascular and emergency CT scans, should be familiar with this common variation of origin of the obturator artery, allowing for safer planning of surgical procedures.

This aim of the study was to overcome the limitations of the published literature regarding CM imaging to date, which consisted of small cohort of patients imaged for different reasons, with multiple and older CT scanners and with heterogeneous acquisition protocols.

We planned to achieve this by providing a large and consistent set of patients who were imaged specifically for arterial evaluation, with a single and recent CT scanner and using the same study protocol.

The evaluation of the prevalence of CM by means of CT-A instead of cadaveric studies offers the chance to assess actual vessel patency instead of its mere presence.

In our analysis CM was found in 30% (90 out of 300) of the assessed hemipelvises, a number which are in substantial agreement with previous reports [1-3,5,6,8].

Average artery diameter in this study was found to be slightly smaller than in previous reports (1.7 mm in this study, 2.32 mm in the study of Steinberg *et al.* and 2.6 mm in the study of Darmanis *et al.*), a finding that we believe to be attributable to the different parameters of the CT scans. As a matter of fact, measurements were made on a high-end scanner with dedicated vascular protocol, and they may have depicted smaller patent arteries than in previous studies.

The average distance from the CM to the pubic symphysis in our study was 50 mm, which again is a finding in substantial agreement with a recent report from Steinberg *et al.*

Average inter-acetabular distance was found to be 213 mm.

As for the interesting hypothesis posed by Steinberg *et al.* regarding the absence of the CM variant in patients with smaller pelvic size, we were not able to confirm this finding. However, we did recognise the arterial CM variant even in smaller pelvises.

This study suffers from a few limitations. As for all the published studies to date we were not able to compare our findings with actual dissection of the hemipelvises. This was beyond the scope of the present research and could be addressed in future studies.

Finally, this contribution has been able to refine knowledge of the arterial CM variant of the obturator artery, by adopting a robust cohort of patients who were imaged in a consistent fashion by means of contemporary technology. Many of the current findings are in substantial agreement with those previously reported in the literature. In contrast to earlier findings, however, no evidence of the absence of the CM variant in smaller pelvises was detected, and smaller calibre arterial vessels were recognised.

Conflict of interest

The authors report no conflict of interest.

References

1. Darmanis S, Lewis A, Mansoor A, et al. Corona mortis: an anatomical study with clinical implications in approaches to the pelvis and acetabulum. *Clin Anat* 2007; 20: 433-439.
2. Okcu G, Erkan S, Yercan HS, et al. The incidence and location of corona mortis: a study on 75 cadavers. *Acta Orthop Scand* 2004; 75: 53-55.
3. Rusu MC, Cergan R, Motoc AGM, et al. Anatomical consideration on the corona mortis. *Surg Radiol Anat* 2010; 32: 17-24.
4. Teague DC, Graney DO, Routt MLC Jr. Retropubic vascular hazards of the ilioinguinal exposure: a cadaveric and clinical study. *J Orthop Trauma* 1996; 10: 156-159.
5. Tornetta P 3rd, Hockwald N, Levine R. Corona mortis. Incidence and location. *Clin Orthop Relat Res* 1996; 329: 97-101.
6. Karakurt L, Karaca I, Yilmaz E, et al. Corona mortis: incidence and location. *Arch Orthop Trauma Surg* 2002; 122: 163-164.
7. Smith JC, Gregorius JC, Breazeale BH, et al. The corona mortis, a frequent vascular variant susceptible to blunt pelvic trauma: identification at routine multidetector CT. *J Vasc Interv Radiol* 2009; 20: 455-460.
8. Steinberg EL, Ben-Tov T, Aviram G, et al. Corona mortis anastomosis: a three-dimensional computerized tomographic angiographic study. *Emerg Radiol* 2017; 24: 519-523.
9. Kellgren JH, Lawrence JS. Radiological assessment of osteo-arthrosis. *Ann Rheum Dis* 1957; 16: 494-502.
10. Turmezei T, Fotiadou A, Lolmas DJ, et al. A new CT grading system for hip osteoarthritis. *Osteoarthritis Cartilage* 2014; 22: 1360-1366.
11. Rehder P, Glodny B, Pichler R, et al. Massive retropubic hematoma after minimal invasive mid-urethral sling procedure in a patient with a corona mortis. *Indian J Urol* 2010; 26: 577-579.
12. Gobrecht U, Kuhn A, Fellman B. Injury of the corona mortis during vaginal tape insertion (TVT-Secur™ using the U-approach). *Int Urogynecol* 2011; 22: 443-445.
13. Garrido-Gómez J, Pena-Rodríguez C, Martín-Noguerol T, et al. Corona mortis artery avulsion due to a stable pubic ramus fracture. *Orthopedics* 2002; 35: e80-e82.
14. Mahadevan V, Niranjana NS. Sexual differences in the pelvis; chapter 79: pelvic girdle and lower limb: overview and surface anatomy. In: Standring S (ed.). *Gray's anatomy*. 40 ed. Churchill Livingstone Elsevier, Edinburgh 2009; 1359-1560.
15. Larsson PG, Teleman P, Persson J. A serious bleeding complication with injury of the corona mortis with the TVT-Secur procedure. *Int Urogynecol J* 2010; 21: 1175-1177.