

# True aneurysm of superficial temporal artery accompanying multiple intracranial aneurysm

Emre Delen, Emre Ozkara<sup>1</sup>, Hasan Emre Aydin<sup>2</sup>, Zuhtu Ozbek<sup>1</sup>

Department of Neurosurgery, Edirne State Hospital, Edirne, <sup>1</sup>Department of Neurosurgery, Eskişehir Osmangazi University, <sup>2</sup>Department of Neurosurgery, Eskişehir Yunus Emre State Hospital, Eskişehir, Turkey

## ABSTRACT

Superficial temporal artery (STA) aneurysms are very infrequent. Moreover, true aneurysms, which are not pseudoaneurysms associated with trauma or previous surgery are even rarer. With this manuscript, authors present a case of a 79-year-old woman suffering from subarachnoid hemorrhage whose radiological examinations revealed multiple intracranial aneurysms along with an STA aneurysm. This very rare case, to the best of our knowledge, the second case reported so far, might contribute to the literature and lead further investigations toward the rare association between intracranial aneurysms and STA aneurysms.

**Key words:** Intracranial aneurysm, subarachnoid hemorrhage, superficial temporal artery, true aneurysm

## Introduction

True aneurysms of superficial temporal artery (STA) are rare vascular pathologies. Most of the reported cases associated with STA are pseudoaneurysms. In the literature, the relationship between the true STA aneurysm and the intracranial aneurysm could not be demonstrated clearly. Here, we presented an STA aneurysm associated with multiple intracranial aneurysms identified incidentally while examinations are carried out after subarachnoid hemorrhage.

## Case Report

A 79-year-old female patient was referred to the emergency department due to subarachnoid hemorrhage. Arterial hypertension was present at the patient's medical history. In the neurological examination, consciousness was determined as confused, motor deficits were not observed. In the patient's brain computed tomography (CT), an image consistent with extensive subarachnoid hemorrhage on the left sylvian cistern

was detected [Figure 1]. Three-dimensional (3D) brain CT angiography (3D CTA) revealed the diagnosis of Hunt-Hess grade 3 subarachnoid hemorrhage. In CTA, multilobulated broad-based, posterior-oriented aneurysmal filling reaching about 7 mm in diameter at the level of both carotis interna posterior communicant artery origin and aneurysmal dilatation on the left STA, about 5 mm in size were detected [Figure 2]. The patients underwent an emergent operation; the intracranial aneurysms are clipped, and the STA aneurysm is closed by ligation [Figure 3]. The patient is discharged with a Glasgow Outcome Scale of 2.

## Discussion

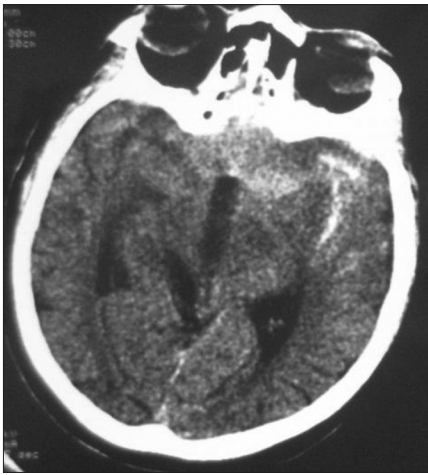
STA is the terminal branch of the external carotid artery and one of the main feeders of the scalp. STA, in its anatomic course, becomes superficial on the zygomatic process after passing the parotid gland and is divided into branches of the anterior frontal and posterior parietal. The artery was covered by time temporal muscle, lipomatous tissue and skin after the zygomatic process. It is open to trauma due to this superficial course. Therefore, a large part of the STA aneurysms are pseudoaneurysm. Although approximately, 400 patients with STA aneurysm were reported in the literature up to now, the majority of the cases are posttraumatic pseudoaneurysms. Trauma causes the development of pseudoaneurysm by direct injury to the arterial wall.<sup>[1]</sup> In recent years, iatrogenic causes seen after commonly used procedures in neurosurgical practice such as craniotomy using Gardner cap and placing external ventricular drainage were described.<sup>[2-4]</sup>

True aneurysms are seen only in 10% of all STA aneurysms.<sup>[5]</sup> In the study conducted by Dominique VD, STA cases in the literature between 1861 and 2010 were examined, 20 of a total

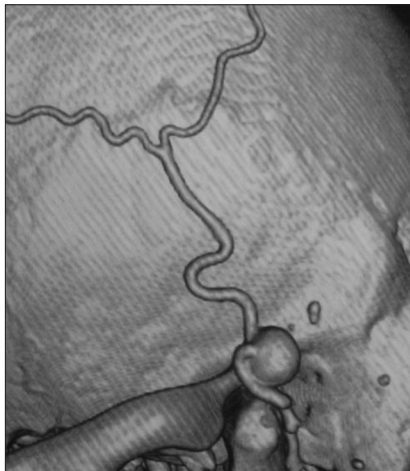
Access this article online	
Quick Response Code:	Website: www.asianjns.org
	DOI: 10.4103/1793-5482.165788

## Address for correspondence:

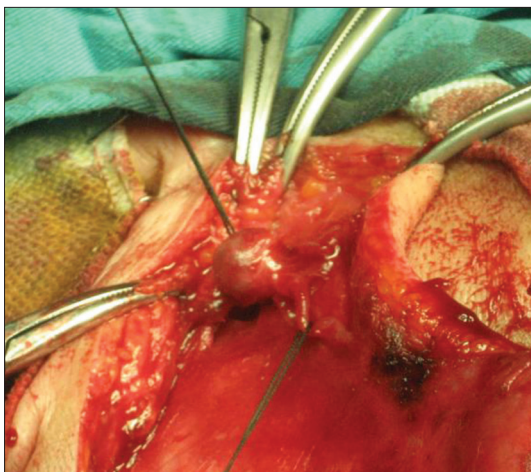
Dr. Emre Delen, Department of Neurosurgery, Edirne State Hospital, Edirne, Turkey. E-mail: emredelen1979@yahoo.com



**Figure 1:** Computed tomography an image consistent with extensive subarachnoid hemorrhage on the left sylvian cistern was detected



**Figure 2:** Three-dimensional computed tomography angiography revealing a multi aneurysm originating from of both carotis interna posterior communicating artery origin and aneurysmal dilatation on the left superficial temporal artery about 5 mm in size



**Figure 3:** Intraoperative photograph showing true aneurysm of the superficial temporal artery

of 166 STA aneurysms were identified as a true aneurysm. All true aneurysms were confirmed histologically. In the same study, the presence of STA aneurysm was reported in only one patient after severe subarachnoid hemorrhage.

The exact pathophysiology of the true aneurysms has not been established. However, atherosclerosis and congenital defects in the arterial wall are accused in the etiology.<sup>[6]</sup> In particular, it has been suggested that the congenital changes in the elastic membrane may cause the development of a true aneurysm.<sup>[7]</sup> The higher incidence of true aneurysms in elder ages than pseudoaneurysms suggests that the cause can be hemodynamic stress, as well as atherosclerosis.

The majority of patients with true STA aneurysms were identified with a pulsatile painful mass. The presence of an intracranial aneurysm associated with the STA aneurysm is extremely rare.<sup>[8]</sup> There are very few case reports in the literature showing this relationship. We detected STA aneurysm in only one case identified after subarachnoid hemorrhage.<sup>[5]</sup> In this case presented by Yonetani *et al.*,<sup>[9]</sup> the detection of an aneurysm in the patient's right radial artery in addition to STA aneurysm and the loss of the patient after 7 years due to subarachnoid hemorrhage suggests the presence of an intracranial aneurysm.

In the case presented STA aneurysm is identified incidentally while examinations are performed after subarachnoid hemorrhage. Two aneurysms originated from a posterior communicating artery in the intracranial component have been identified. We considered that STA aneurysm was the component of the multiple intracranial aneurysms. The emergency of the operation can be an excuse for the lack of histological examination of the STA aneurysm. However, this situation is the missing aspect of the case presented. Therefore, there is no definitive proof for that STA aneurysm was whether a true aneurysm or a pseudoaneurysm. As of settlement, being on the zygoma leads to the possibility of injury. However, when we interrogated the patient retrospectively, we did not detect any evidence leading in this direction. Furthermore, the presence of multiple intracranial aneurysms, the patient's older age and the presence of atherosclerosis suggest us that the STA aneurysm was a true aneurysm.

In our study, another issue that we want to emphasize is the necessity of displaying the external carotid artery and its branches in the examinations performed after subarachnoid hemorrhage. Conventional cerebral angiography is the gold standard in the diagnosis of intracranial aneurysms.<sup>[10-12]</sup> Even though with low incidence, it has some complications like stroke. Digital subtraction angiography (DSA) may be insufficient to demonstrate thrombosed aneurysms.<sup>[8,10]</sup> In addition, 3D CT imaging developed rapidly in recent years and allowing noninvasive imaging is an advanced imaging

technique allowing also imaging surrounding anatomic structures and its superiority against the DSA in imaging of thrombosed aneurysms has been shown.<sup>[13]</sup> In the case presented, STA aneurysm was demonstrated by 3D CTA and probably the presence of the STA aneurysm was identified thanks to this chosen technique. Therefore, the patient's medical status, especially after subarachnoid hemorrhage, and the presence of intracranial aneurysms detected might have caused to the extended examinations on the external carotid artery. We wanted to draw the attention to this issue with this study.

## Conclusion

Due to factors such as the presence of associated intracranial aneurysms and atherosclerosis; it has been considered that our case was a true STA aneurysm associated with multiple intracranial aneurysms, and contributed the literature in terms of to be very rare.

## References

1. Reddick EJ, Andersen CA. Superficial temporal artery aneurysms: An important preoperative diagnosis. *Mil Med* 1981;146:405-6.
2. Hakan T, Ersahin M, Somay H, Aker F. Pseudoaneurysm of the superficial temporal artery following revision of a middle cerebral artery aneurysm clipping: Case report and review of the literature. *Turk Neurosurg* 2011;21:430-4.
3. Lee HS, Jo KW, Lee SH, Eoh W. Traumatic pseudoaneurysm of the superficial temporal artery due to Gardner traction. *J Korean Neurosurg Soc* 2010;48:291-3.
4. Angevine PD, Connolly ES Jr. Pseudoaneurysms of the superficial temporal artery secondary to placement of external ventricular drainage catheters. *Surg Neurol* 2002;58:258-60.
5. van Uden DJ, Truijers M, Schipper EE, Zeebregts CJ, Reijnen MM. Superficial temporal artery aneurysm: Diagnosis and treatment options. *Head Neck* 2013;35:608-14.
6. Riaz AA, Ismail M, Sheikh N, Ahmed N, Atkin G, Richman P, *et al.* Spontaneously arising superficial temporal artery aneurysms: a report of two cases and review of the literature. *Ann R Coll Surg Engl* 2004;86:W38-40.
7. Nishioka T, Kondo A, Aoyama I, Nin K, Shimotake K, Tashiro H, *et al.* A case of spontaneous superficial temporal artery aneurysm. *No Shinkei Geka* 1988;16:1009-12.
8. Coenegrachts K, Hermans R, Vander Poorten V, Thijs M, Wilms G. Non-traumatic giant aneurysm of a superficial temporal artery. *JBR-BTR* 2005;88:72-4.
9. Uchida N, Sakuma M. Atherosclerotic superficial temporal artery aneurysm: Report of a case. *Surg Today* 1999;29:575-8.
10. Buckspan RJ, Rees RS. Aneurysm of the superficial temporal artery presenting as a parotid mass. *Plast Reconstr Surg* 1986;78:515-7.
11. Peick AL, Nichols WK, Curtis JJ, Silver D. Aneurysms and pseudoaneurysms of the superficial temporal artery caused by trauma. *J Vasc Surg* 1988;8:606-10.
12. Locatelli D, Messina AL, Ricevuti G, Gajno TM. Superficial temporal artery aneurysms. *J Neuroradiol* 1988;15:89-93.
13. Kawabori M, Kuroda S, Nakayama N, Kenmotsu Y, Shimizu H, Tanino M, *et al.* Spontaneous giant aneurysm of the superficial temporal artery: case report. *Neurol Med Chir (Tokyo)* 2009;49:198-201.

**How to cite this article:** Delen E, Ozkara E, Aydin HE, Ozbek Z. True aneurysm of superficial temporal artery accompanying multiple intracranial aneurysm. *Asian J Neurosurg* 2016;11:76-7.

**Source of Support:** Nil, **Conflict of Interest:** None declared.