



OPEN ACCESS

## CASE REPORT

## Pituitary abscess

Jameela Mohammed Al salman,<sup>1</sup> Rawan Al Muataz Billa Al Agha,<sup>2</sup> Mohamed Helmy<sup>3</sup>

<sup>1</sup>Medical Department, Salmaniya Medical Complex, Isa Town, Bahrain

<sup>2</sup>Department of Internal Medicine, Salmaniya Medical Complex, Manama, Bahrain

<sup>3</sup>Department of Neurosciences, Salmaniya Medical Complex, Manama, Bahrain

**Correspondence to**

Dr Jameela Mohammed Al salman, jalsalman@hotmail.com

Accepted 17 May 2017

**SUMMARY**

Pituitary abscess is an uncommon pituitary lesion. Its clinical diagnosis can be difficult to distinguish from other pituitary lesions. This pathology is characterised by vague symptoms of headaches, generalised tiredness and hypopituitarism manifestations. A history of recent meningitis, paranasal sinusitis or head surgery can be a suggestive of the source of infection.

A 20-year-old man was admitted to neurosurgery department with complain of headache, fatigue, polyuria, polydipsia, blurred vision and sexual dysfunction. MRI of the head revealed a suprasellar mass that was centrally hyperintense lesion on T2-weighted images with peripheral hypointensity and isointense centrally on T1 images with peripheral hyperintensity images. Treatment of this lesion pituitary abscess was surgical drainage of the pituitary area through a trans-sphenoidal approach and broad spectrum antibiotic therapy with ceftriaxone, metronidazole and vancomycin for 6 weeks. The patient continues to have pituitary insufficiency and treated with oral hydrocortisone.

Although pituitary abscess is a rare condition, it should always be kept in mind when evaluating a patient with hypopituitarism. After the diagnosis, the surgery and antibiotics should be commenced rapidly. The outcome is usually good with proper treatment.

**BACKGROUND**

The pituitary gland is an endocrine gland about the size of a pea and weighs 0.5 gm in humans. Hormones secreted from the pituitary gland control: growth, blood pressure, certain functions of the sex organs, thyroid glands and metabolism as well as some aspects of pregnancy, childbirth, nursing, water/salt concentration and the kidneys, temperature regulation and pain relief.<sup>1</sup> Different kind of lesions may develop in the pituitary gland which could lead to over or under secretion of hormone production and subsequently present as an incidental finding on imaging, symptoms of mass pressure or hormonal disturbances.

A rare pituitary lesion is a pituitary abscess. Pituitary abscess is very rare accounting for 0.2%–0.6% of all pituitary lesions. Only around 250 case reports have been described so far since the first case was described by Heslop in 1848.<sup>2</sup> Pituitary abscess is an uncommon disease that usually presents with vague symptoms. To reach a diagnosis in such cases is usually difficult. The condition is considered a life-threatening one, however, fortunately the major number of cases have a rather chronic course. Based on different reports, these abscesses are characterised by the following: it constitutes less

than 1% of all the pituitary diseases being seen by the specialist; higher female predominance; the age range is between 12 to 76 years and the average period between onset the symptoms and diagnosis is 8 months.<sup>3</sup>

Preoperative diagnosis is a dilemma as symptoms such as pituitary abnormal function are non-specific, radiological findings are not distinctive of an abscess and symptoms like headache or visual disturbances are vague. In addition, infectious symptoms such as fever, meningism and high white cell count (WBC) are not seen in around 70–8% of cases. Therefore, majority of the cases are diagnosed either post mortem or postoperatively.<sup>4</sup>

Pituitary abscess can develop in a normal pituitary gland (about 70%) or in pre-existing pituitary pathology (about 30%). Of the pre-existing lesions, a pituitary adenoma is most common, followed by a Rathke's cleft cyst, craniopharyngioma and lymphoma.<sup>5</sup> The therapies available are trans-sphenoidal surgery, antibiotics and hormonal replacement.

**CASE PRESENTATION**

A 20-year-old Bahraini man presented to accident and emergency department in Salmaniya Medical Complex (Manama/Bahrain) in March 2016 complaining of headache which he described as severe, continuous and exacerbated with exposure to bright light. In addition, he complained of photosensitivity, nausea, left eye blurred vision and generalised body fatigue. These symptoms were worsening over a month period of time. He denied history of limb weakness, abnormal movements or seizure, loss of consciousness or sensory manifestations.

He was initially managed with analgesia and in view of his alarming symptoms MRI brain was requested.

**INVESTIGATIONS**

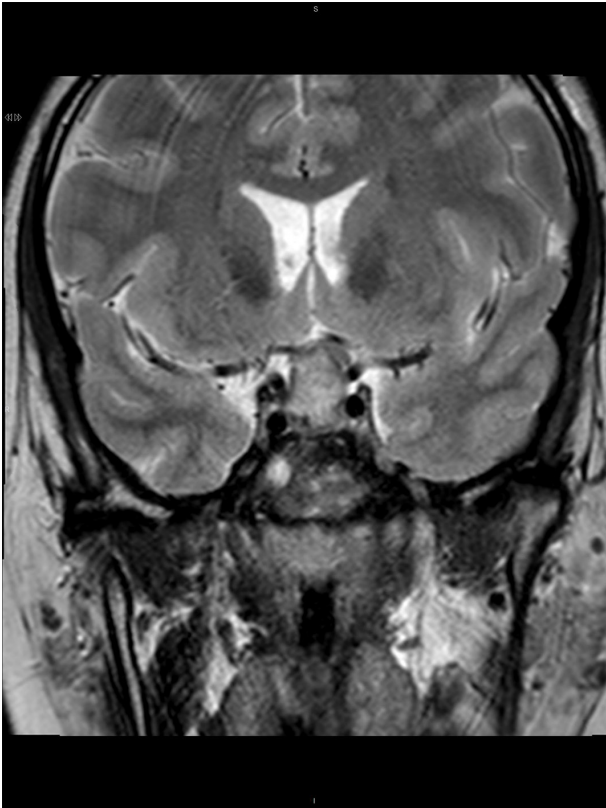
Multiplanar multisequential images were taken with postimage, and preimage contrast was given. The scan showed presence of heterogeneously hyperintense lesion on T2-weighted images with peripheral hypointensity (figure 1 and not suppressed on fluid-attenuated inversion recovery images (figure 2). The optic chiasm was compressed and displaced superiorly by the lesion. Both cavernous sinuses were mildly compressed too with sparing of internal carotid artery blood flow. T1 images with no contrast showed fluid level (figure 3).

Therefore, the conclusion was suggestive of macroadenoma of pituitary gland (size

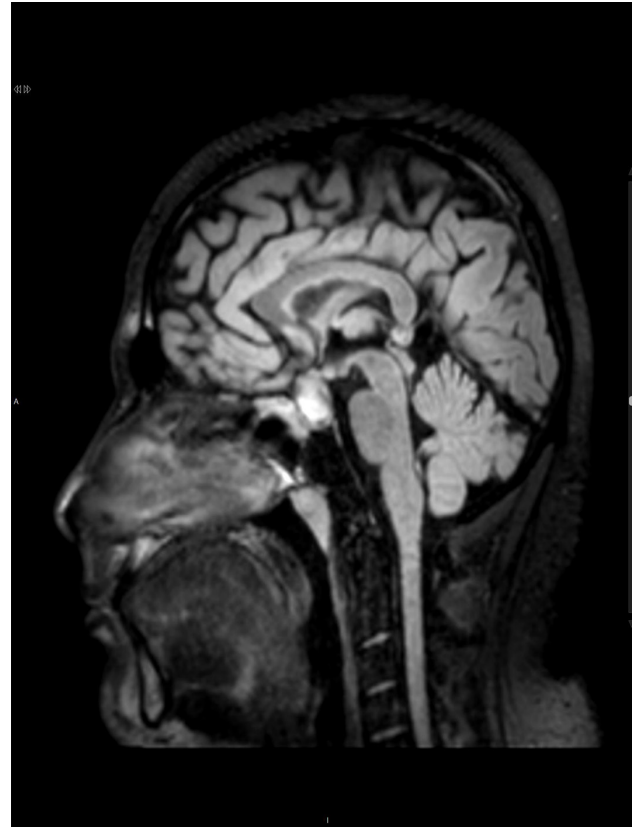

CrossMark

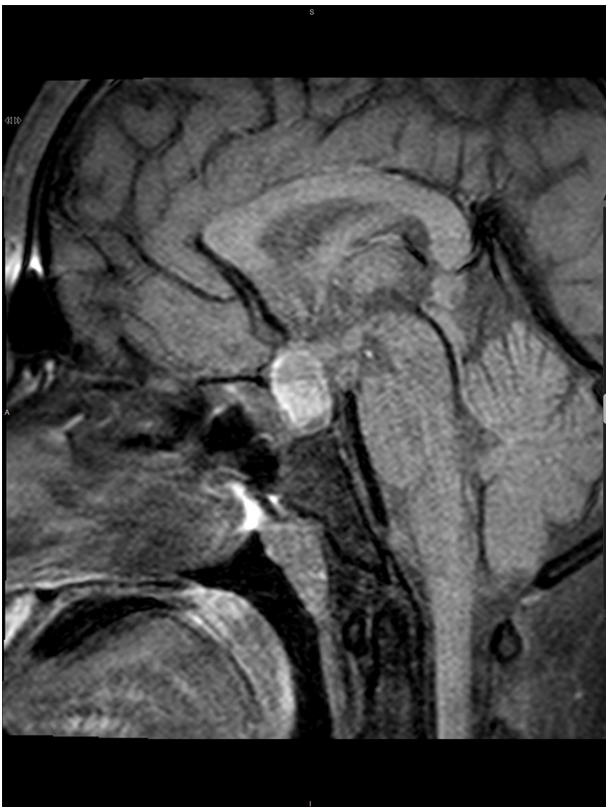**To cite:** Al salman JM, Al Agha RAMB, Helmy M. *BMJ Case Rep* Published Online First: [please include Day Month Year]. doi:10.1136/bcr-2016-217912



**Figure 1** MRI fluid-attenuated inversion recovery image (sagittal view) the sphenoid sinus filled with debris and thick mucosal lining.



**Figure 3** MRI T1 image (sagittal view) non-contrast fat saturated showing fluid level



**Figure 2** MRI T2 image (frontal view) sellar/suprasellar mass that was isohyperintense with peripheral hyperintensity

1.8×1.5×1.3 cm in size) with haemorrhage and a mass effect on optic chiasm.

In view of the MRI findings, pituitary hormonal assessment was done. Furthermore, the patient gave history of loss of libido, failure of erection, polyuria and polydipsia but denied any gynaecomastia or change in body part size. The results showed central hypogonadism, central hypoadrenalism, normal thyroid function and mildly elevated level of prolactin. He was commenced on hydrocortisone oral tablet (20 mg on morning, 10 mg on evening doses). On examination, patient did not show any cranial nerve, limb or gait abnormalities. There was no thyromegaly or signs of acromegaly. A chest X-ray done was normal (table 1).

#### DIFFERENTIAL DIAGNOSIS

1. Pituitary adenoma
2. Pituitary abscess
3. Pituitary haemorrhage

#### TREATMENT

After investigating the patient, he was scheduled for theatre by July 2016 for trans-sphenoidal removal of the pituitary macroadenoma. Intraoperatively the patient was kept on left side 20° with an incision done in the right nostril, the mucosa was separated and the sphenoid sinus mucosa removed. The sellar floor identified and removed. Thick capsule of abscess incised with yellowish pus was drained. The cavity was cleaned and irrigated with antibiotics and saline. The pus was sent for Gram stain, culture, acid-fast bacilli (AFB) stain and histopathological evaluation. The pituitary was not removed.

The histopathology showed features suggestive of inflammatory lesion possibly an abscess. There is no evidence of pituitary

**Table 1** Patient's laboratory results and normal ranges

Test	Result	Normal range
Adrenocorticotrophic hormone	4.2 pmol/L	<10.0
Cortisol (at zero time)	101 nmol/L	193–690
Cortisol (at 30 min)	430.53 nmol/L	
Cortisol (at 60 min)	529.60 nmol/L	
Insulin-like growth factor 1	No reagent available	
Thyroxine (T4), free	8.0 pmol/L	6.0–24.5 (adult)
Thyroid-stimulating hormone	1.88 mIU/L	0.25–4.0 (euthyroid) (adult)
Follicle-stimulating hormone	0.1 IU/L	1.6–11.0 (male)
Luteinising hormone	0.6 IU/L	1.5–9.3 (20–70 years)
Progesterone	1.32 nmol/L	0.89–3.88 (males)
Prolactin	21.69 ng/mL	0.7–16.8 ng/mL (male)
Testosterone	0.27 nmol/L	9.1–40.0 (male 20–50 years)
Estradiol	49 pmol/L	36.71–220.26 (male)
Urine osmolality	716 mOsm/kg	50–1400
Plasma sodium	133 mmol/L	132–146
Plasma osmolality	283 mOsm/kg	275–295

adenoma in this small and partly compressed biopsy. The Gram stain showed few WBC and a sterile culture. AFB stain did not show any acid fast bacilli.

#### OUTCOME AND FOLLOW-UP

Postoperatively, the patient was shifted to intensive care unit for overnight observation. After that, he was transferred to a neurosurgery ward. He was commenced on the following antibiotics: metronidazole 400 mg three times per day, ceftriaxone 1 g once per day and vancomycin 1 g two times daily for a total of 6 weeks. He was doing well with improvement in symptoms and normal functional status.

The patient continued to have pituitary insufficiency on follow-up and the hydrocortisone as continued. No further headaches have been noticed or other symptoms. Follow-up MRI was done and showed no more enhancing residual abscess pockets within the pituitary fossa suggesting complete resolution.

#### DISCUSSION

Pituitary abscesses are divided into two types: primary and secondary. The primary subtype constitutes the majority of the pituitary abscess cases. On the other hand, the secondary subtype usually rises from within an existing pituitary lesion. It can be caused by a haematogenous or direct spread from distant lesions such as meningitis or sinusitis. Vates *et al* reviewed 24 cases of pituitary abscess. The study showed that 19.7% of the affected patients had a positive history of sepsis or an obvious source of bacteraemia, 12.5% gave history of cerebrospinal fluid (CSF) leak in the sense of rhinorrhoea, 41.7% had history of pituitary surgery or sphenoid sinus disease, 8.3% with history of brain radiation and 4.2% had a chronic history of sphenoid inflammation and disease.<sup>6</sup> On the other hand, another study by Lindholm *et al* did not show an infectious cause in 9 out of 21 cases of pituitary abscess. Furthermore, Jimeno *et al* described that most likely the primary source of the pituitary abscess was from the spread of infection from a maxillary or frontal sinusitis.<sup>7 8</sup> In other reports, cavernous sinus thrombosis was once suggested that it may play a role in pituitary infection and inflammation.<sup>9</sup> In our case, there was a strong suspicion that source of infection was due to direct spread from the sphenoid sinuses as the MRI showed evidence of chronic inflammation and mucosal

thickening despite that the patient denied any symptoms of upper respiratory or sinusitis.

The organisms mostly isolated from pituitary abscesses are Gram-positive cocci (mainly *Staphylococcus* and *Streptococcus*), Gram-negative organisms such as *Neisseria*, *Escherichia coli* and *Corynebacterium*. Others less likely to be isolated organisms are fungi and parasites.<sup>10</sup> However, the majority of the pituitary abscess cultures have been reported to be sterile. The reason for this could be because of the use of antibiotics preoperatively or the laboratory techniques used was inappropriate for the growth of fungus or anaerobic organism.<sup>11</sup> It was suggested once that pituitary abscess does not represent a bacterial infection. It is just an inflammatory reaction secondary to pituitary infarction. As the high frequency of the sterile cultures and along with it, the associated endocrine abnormalities can be explained by simple inflammation of the gland.<sup>12</sup>

Radiologically, it still very challenging to differentiate between a pituitary abscess and adenoma. The CT and MRI (including the diffusion-weighted images) findings of both conditions are more or the less the same for both conditions. Shimamura *et al* suggests that a way of differentiating both pituitary lesions is by the high uptake of the abscess on thallium-201 single-photon emission CT on the early and delayed images.<sup>13</sup>

Surgical drainage is the standard treatment for a pituitary abscess. The trans-sphenoidal approach is the recommended approach; however, craniotomy is preferred if the abscess is suprasellar or significant evacuation is considered difficult. The operation is considered invasive and traumatic procedure. Complications of surgery include meningitis, vascular injury and CSF leakage. The incidence of complications is decreasing with the development in medical practices.<sup>14</sup>

The operation could also increase the risk of or delay the recovery from anterior pituitary insufficiency and diabetes insipidus. Liu *et al* reported that only 8 of the 30 patients (including 3 patients who had normal preoperative pituitary function) attained normal pituitary function following surgery. The rest of the patients continued to require hormone replacement therapy, and 6 of the 21 patients with preoperative diabetes insipidus required postoperative desmopressin acetate.<sup>15</sup> Therefore, the surgery can also lead to destruction of the pituitary gland.<sup>14</sup> Broad-spectrum antibiotic therapy must be started as soon as the diagnosis of pituitary abscess is confirmed. After identification of

## Reminder of important clinical lesson

the organism, a specific antibiotic therapy should be continued for 4 to 8 weeks.

Although pituitary abscess is a rare condition, it should always be kept in mind when evaluating a patient with hypopituitarism. This case presents one of the rare causes of pituitary insufficiency. A pituitary abscess must be tickled in the differential diagnosis of a patient with hypopituitarism and signs of systemic infection, and the patient should have an MRI assessment. Treatment consists of debridement, systemic administration of antibiotics and hormonal replacement.

### Learning points

- ▶ Pituitary abscess should be kept in mind in the differential diagnosis of a pituitary mass.
- ▶ Surgical intervention is the treatment of choice followed by prolonged course of intravenous antibiotics.
- ▶ The pituitary should have follow-up with brain MRI and to rule out hormonal deficiencies with appropriate hormonal replacement.

**Contributors** JMAS managed the patient from infectious perspective and supervised the writing of the case report. RAMBAA managed the patient from infectious perspective and wrote the case report. MH managed the patient for the neurosurgery perspective.

**Competing interests** None declared.

**Patient consent** Obtained.

**Ethics approval** Hospital Ethical Committee.

**Provenance and peer review** Not commissioned; externally peer reviewed.

**Open Access** This is an Open Access article distributed in accordance with the Creative Commons Attribution Non Commercial (CC BY-NC 4.0) license, which permits others to distribute, remix, adapt, build upon this work non-commercially, and license their derivative works on different terms, provided the original work

is properly cited and the use is non-commercial. See: <http://creativecommons.org/licenses/by-nc/4.0/>

© BMJ Publishing Group Ltd (unless otherwise stated in the text of the article) 2017. All rights reserved. No commercial use is permitted unless otherwise expressly granted.

### REFERENCES

1. Gibo H, Hokama M, Kyoshima K, *et al.* [Arteries to the pituitary]. *Nihon Rinsho* 1993;51:2550–4.
2. Kummraganti S, Bachuwar R, Hundia V. Pituitary abscess: a rare cause of pituitary mass lesion. *Endocrine Abstracts* 2013;31:1.
3. Liu F, Li G, Yao Y, *et al.* Diagnosis and management of pituitary abscess: experiences from 33 cases. *Clin Endocrinol* 2011;74:79–88.
4. Dutta P, Bhansali A, Singh P, *et al.* Pituitary abscess: report of four cases and review of literature. *Pituitary* 2006;9:267–73.
5. Ciappetta P, Calace A, D'Urso PI, *et al.* Endoscopic treatment of pituitary abscess: two case reports and literature review. *Neurosurg Rev* 2008;31:237–46.
6. Vates GE, Berger MS, Wilson CB, *et al.* Diagnosis and management of pituitary abscess: a review of twenty-four cases. *J Neurosurg* 2001;95:233–41.
7. Lindholm J, Rasmussen P, Korsgaard O. Intracellular or pituitary abscess. *J Neurosurg* 1973;38:616–9.
8. Jimeno C, Añel-Quimpo J. Pituitary abscess manifesting with amenorrhea: a case report and review of literature. *Phil J Int Med* 2004;42:41–4.
9. Berger SA, Edberg SC, David G. Infectious disease in the sella Turcica. *Rev Infect Dis* 1986;8:747–55.
10. Heary RF, Maniker AH, Wolansky LJ. Candidal pituitary abscess: case report. *Neurosurgery* 1995;36:1009–12.
11. Boggan JE. Pituitary abscesses. In: Wilkins RH, Rengachary SS, eds. *Neurosurgery*. 2nd ed. London: McGraw-Hill Book Company, 1996:3321–2.
12. Bjerre P, Riishede J, Lindholm J. Pituitary abscess. *Acta Neurochir* 1983;68(3-4):187–93.
13. Shimamura N, Ogane K, Takahashi T, *et al.* Pituitary abscess showing high uptake of thallium-201 on single photon emission computed tomography--case report. *Neurol Med Chir* 2003;43:100–3.
14. Ciappetta P, Calace A, D'Urso PI, *et al.* Endoscopic treatment of pituitary abscess: two case reports and literature review. *Neurosurg Rev* 2008;31:237–46.
15. Liu F, Li G, Yao Y, *et al.* Diagnosis and management of pituitary abscess: experiences from 33 cases. *Clin Endocrinol* 2011;74:79–88.

Copyright 2017 BMJ Publishing Group. All rights reserved. For permission to reuse any of this content visit <http://group.bmj.com/group/rights-licensing/permissions>.

BMJ Case Report Fellows may re-use this article for personal use and teaching without any further permission.

Become a Fellow of BMJ Case Reports today and you can:

- ▶ Submit as many cases as you like
- ▶ Enjoy fast sympathetic peer review and rapid publication of accepted articles
- ▶ Access all the published articles
- ▶ Re-use any of the published material for personal use and teaching without further permission

For information on Institutional Fellowships contact [consortiasales@bmjgroup.com](mailto:consortiasales@bmjgroup.com)

Visit [casereports.bmj.com](http://casereports.bmj.com) for more articles like this and to become a Fellow