

Contents lists available at [ScienceDirect](#)

International Journal of Surgery Case Reports

journal homepage: www.casereports.com

Adult Hirschsprung's disease: A case report and literature review

Christopher Gamez^b, Theunis Otte de Boer^a, Nidia Saca^c, Landry Umbu^b, Sameh Shoukry^{b,*}, Penelope Mashburn^b, Peter M. DeVito^b^a Northeast Ohio Medical University, USA^b Trumbull Regional Medical Center, USA^c American University of Antigua, Antigua

ARTICLE INFO

Article history:

Received 14 March 2021

Received in revised form 7 April 2021

Accepted 7 April 2021

Available online 10 April 2021

Keywords:

Surgery

Volvulus

Obstruction

Adult hirschsprung

Small bowel

Duhamel's

ABSTRACT

INTRODUCTION & IMPORTANCE: Adult Hirschsprung's disease (AHD) is a difficult diagnosis to make due to its rarity, frequently after emergency interventions have been conducted. We present a case of possible AHD and sketch a classic presentation of Adult Hirschsprung's Disease. This would help recognize and include AHD in the differential diagnoses of chronic constipation where appropriate.

CASE PRESENTATION: The case involved a 41-year-old male with a history of multiple abdominal surgeries for volvuli and a ventral hernia repair complicated by post-operative SBO. Presenting symptoms were chronic constipation, abdominal colic, and dilation. SBO secondary to volvulus was discovered, decompressed, and emptied of 3000cc fecal material in the OR. His case was again complicated twice by SBO which led to the suspicion of AHD and instigated this systematic review. Papers were extracted from the EBSCO and PubMed databases. Papers were excluded if patients were younger than 10 years old.

CLINICAL DISCUSSION: The classic patient will be a male over the age of 10 years old with an average age of 30 years old and a long history of chronic constipation, often complicated by an acute symptomatic obstruction. Patients may have had a history of multiple surgical or non-surgical interventions to relieve their constipation.

CONCLUSION: AHD is being seen more frequently with the increasing availability of healthcare in under-served areas of the world. Duhamel's procedure is the most effective procedure after diagnosis has been made. Barium enema and a biopsy show hypo- or a-ganglionic segments that are to be resected for curative purposes.

© 2021 Published by Elsevier Ltd on behalf of IJS Publishing Group Ltd. This is an open access article under the CC BY-NC-ND license (<http://creativecommons.org/licenses/by-nc-nd/4.0/>).

1. Introduction

Hirschsprung's disease is considered a newborn disease, however, certain circumstances have allowed for the escape of appropriate diagnosis at birth. According to the very extensive article by Kenny et al. [1], embryonic neural crest cells migrate in the craniocaudal direction along vagus nerves simultaneously while the intestinal tract is growing. The cells migrate by responding to complex environmental factors. This has been theorized to be a possible cause for Hirschsprung's disease where factor imbalances, such as a laminin overrepresentation, cause segments of aganglionic myenteric plexus now unable to relax and facilitate peristalsis appropriately causing the inability to excrete fecal matter.

Hirschsprung's disease is the most common cause of congenital gut motility disease, occurring in 1/5000 births with a 4:1 male predominance, based mostly on Caucasian samples not considering different ethnicities. Predominantly, short segment Hirschsprung's disease is identified in 80% of the cases where the aganglionic segment of the bowel is isolated to the rectosigmoid. Hirschsprung has a genetic component with the RET-gene being overrepresented with 50% of the familial cases and between 15–35% of the sporadic cases. Additionally, conditions like Down Syndrome increase the risk for Hirschsprung disease by 100-fold compared to unaffected people. In adults, the initial disease most likely presented in its mildest form, which led to atypical presentation and later onset of clinical symptoms [1].

This systematic review was written due to the lack of awareness and the rarity of AHD. There has been a trend of increased reporting on AHD suggesting that many cases have been going unnoticed and like the case report presented by the writer, there are adverse events and financial damages that are related to late diagnoses of this rare disease. Therefore, a typical patient will be sketched using case reports from 2005 onwards to look for trends among these cases.

* Corresponding author at: 1350 E Market St., Warren, OH, 44483, USA.

E-mail addresses: christopher.gamez@steward.org (C. Gamez), tdeboer@neomed.edu (T.O. de Boer), nidias@auamed.net (N. Saca), landry.umbu@steward.org (L. Umbu), samehs@auamed.net (S. Shoukry), penelope.mashburn@steward.org (P. Mashburn).

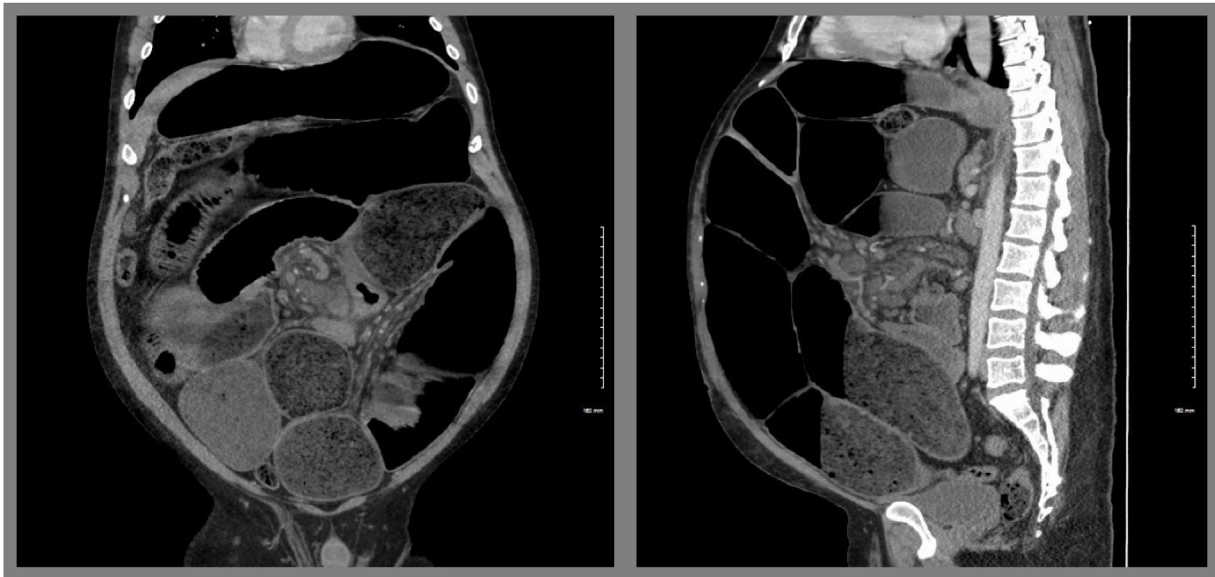


Fig. 1. A. Coronal and B. Saggital views from the initial CT in the ED, showing massively distended small bowel loops with multiple air-fluid levels.

2. Materials & methods

A case presentation is presented followed by a retrospective search of case reports on Adult Hirschsprung's disease. These papers were analyzed and compared on history, symptomology, age, surgeries with outcomes, and case-specific information. This analysis is then compared to our case to create a "classic presentation" of adult Hirschsprung's disease, by the lead investigator. This paper is written as close to the PRISMA guidelines [2] as possible and reported in line with the SCARE 2020 criteria [3].

No review protocol was used, and the literature was searched from 2005 onwards, English language, and case reports. This was done with the reasoning that in 2005 a fantastic article was published by Miyamoto [4] who did a fantastic job looking at the literature prior to 2005.

A bibliography was created by searching EBSCO and PubMed, which was later supplemented with google scholar when an article mentioned something that needed clarification or was deemed to be essential supplemental information.

The following is one of the electronic searches performed for the signs and symptoms in PubMed:

(Signs and Symptoms[Mesh] OR signs and symptoms[tiab] OR signs & symptoms[tiab] OR sign and symptom[tiab]) AND (Hirschsprung Disease[Mesh] OR Adult Hirschsprung disease[tiab] OR Hirschsprungs Disease[tiab] OR Aganglionic Megacolon[tiab] OR Congenital Megacolon[tiab] OR Rectosigmoid Colon Aganglionosis[tiab] OR Rectosigmoid Aganglionosis[tiab] OR Congenital Intestinal Aganglionosis[tiab] OR Colonic Aganglionosis[tiab] OR Total Colonic Aganglionosis[tiab]) AND adult*[tiab]

Studied subjects were males and females above the age of 10. The patients were all diagnosed with Adult Hirschsprung's disease and all had some sort of follow-up. The cases were included if the patients were above 10 years old, which some consider necessary for Hirschsprung's to be considered the adult type [5]. The data extracted was done by the author only. After the primary screening articles were screened for containing a full case report on the disease history. There was little concern for biases in the papers up until the outcome of the research. The word of the author was used to determine whether a procedure was deemed successful and uncomplicated. This will be discussed in the discussion session.

3. Presentation of case

A 41-year-old male with a prior surgical history of volvulus in 2014 and a ventral hernia that was repaired in 2017. The latter procedure was complicated by small bowel obstruction (SBO) postoperatively. At the time of presentation at the ED, he endured acute severe abdominal pain diffusely. The patient passed little flatus and had no bowel movement ever since the exacerbation of the abdominal pain during the night. He denied nausea and vomiting. The patient mentioned a long history of constipation which he self-manages with Linzess. Physical examination showed a healed midline incision from prior medical care.

CT scan showed distended stomach and loops of small bowel with an air-fluid level (Fig. 1). Swirling of the mesentery and prominent lymph nodes were noted. SBO was suspected and a nasogastric tube was inserted to attempt decompression and in preparation for emergency exploratory laparotomy.

Upon entry of the abdomen, the enlarged small bowel exteriorized (Fig. 2), twisted upon itself, and released an internal hernia incidentally. The NG tube did not decompress part of the small bowel which had dusky areas of ischemia. The ischemic small bowel was incised to decompress and remove 3000cc of feculent material from the enterotomy incision. Both a GIA and TA stapler were used to make a primary anastomosis after a 5 cm segment was resected. The volvulus was unwound, and the small bowel was now decompressed and returned into the abdominal cavity. The patient awakened from anesthesia with no complications and was eventually returned to the ICU in stable condition.

During his time in the ICU, the patient developed mild peritonitis, abdominal pain, tachycardia, and low-grade fever of 101.5 F likely due to spillage of feculent material. Antibiotics were ordered and the patient's symptoms persisted until 3 days after surgery. At this time, the patient did not pass flatus or stool, so a CT was ordered showing dilated small bowel loops with thickened walls. Small bowel obstruction was suspected and 6 cm proximal to the ileocecal junction there appeared to be a transition point (Fig. 3). Wound drainage was serosanguinous and on CT there was no fluid noted around the anastomosis. Pyridostigmine was used to encourage post-surgical bowel motility. Seven days post-operative, the afebrile patient appeared well, passing flatus and stool, and was

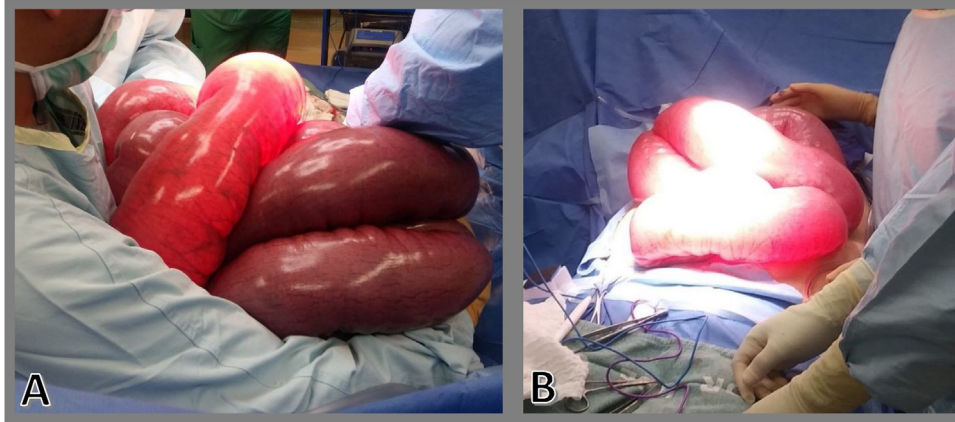


Fig. 2. A. Image showing the degree of small bowel dilation. B. Showing self-exteriorization of dilated small bowel loops immediately upon entry into the abdominal cavity during the index case.

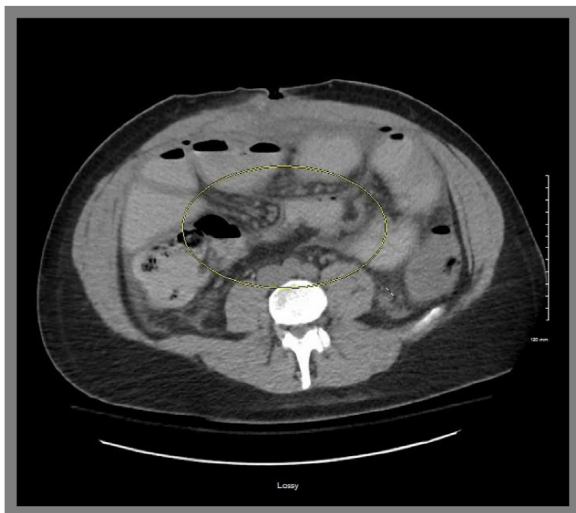

Fig. 3. CT on POD 3 showing a possible transition point in the distal ileum, approx. 6 cm from the cecum.

able to walk around, however, that night the wound dehisced. The patient was brought back to the OR where it became apparent that the PDS sutures had come undone. The staples were removed, and the wound reopened for inspection. Upon inspection, there were no concerns of contamination or infections neither of perforations nor other pathologies. The small bowel was again dilated and needed to be decompressed to be able to close the entry site. An enterotomy was performed on the distal ileum resecting two cm in the process. Finally, a double-barreled decompressive ileostomy was placed to prevent the reoccurrence of any obstructions. After closing the patient, he recovered in stable condition.

On POD 2 he was transferred to a larger tertiary-care facility and subsequently discharged from there in stable condition on POD 13. According to our pathology lab's report, both preoperative and postoperative diagnoses remained as SBO with small bowel volvulus. Since our resection and intraoperative biopsy specimens were exclusively obtained from the small bowel, the pathologist was unable to confirm that this was a definite case of AHD. Nonetheless, given this patient's presentation, history, and clinical course which is in line with the known literature about this condition, we were confident that AHD may have been an underlying condition.

4. Results

After the initial results, 74 studies were identified which were analyzed and sorted for the correct age ranges, language, and time-frames. Studies were excluded if it was not discernable which patient was what age or if the patients were below the age of 10 years old. Data extracted from the papers that contributed to the case reports were the year of publication, author, gender, age, presenting symptoms, type of surgical procedures performed, outcome, surgical complications, additional information that made a case special, and general findings within the paper. One study was removed due to part of the population being under the age of 10 and the symptoms presented were not specifically assigned to those cases, making it impossible to draw conclusions specific to AHD. Ultimately, we analyzed 20 case reports from which information will be obtained.

14 studies were case reports, 3 were case series, 2 case report with literature review, and 1 case series with literature review. There were 36 patients analyzed, 23 males and 13 females with an average age of 30.8 years old.

Chronic constipation was seen in 100% of the patients (36/36), while intestinal obstruction with distention was seen in 35/36 patients (97.2%). Pain was mentioned in 12 cases (33%) and evidence of fecal impaction was seen in 33 cases (91.6%). Half of the patients were reported to have tried laxatives or home remedies, often enemas, for relief (50%). Nausea and vomiting were seen in 5 patients (13.8%) and low nutrition was noted in 8 patients (22.2%). Looking more into past complications, 16.7% of the patient had a history, or came in, presenting with sigmoid volvulus. 11.1% of patients had a known history of delayed meconium and finally, 30.6% had a history of some sort of procedure to treat active symptomology. This also included current and previous sigmoid volvulus [6,7].

One patient was used who has had an extensive history postmortem, which is why this patient was excluded from the diagnostic section. 28 patients out of 35 were subjected to barium enemas (80%) which, in 18 out of 35 patients, indicated a transition zone (51.4%). 32 out of 35 had a biopsy (91.4%) pre- or post-procedure and just 4 out of 35 had anorectal manometry (11.4%). 9 out of 35 physicians used other imaging (25.7%) for their diagnosis of AHD.

Duhamel's procedure and variants were used 8 times out of 35 (22.9%) with one case showing complications (12.5%). There were no long-term complications. The Soaves procedure was performed 9 out of 35 times (25.7%) with 1 surgical complication (11.1%). The last of the three main procedures used for AHD is the

Swenson's procedure performed 6 times (17.1) with 2/6 procedures showing complications (33.3%). 3 surgeries were done according to Rehbein's procedure (8.7%) and 2 cases (5.7%) were without treatment with no complications reported.

5. Conclusions

Hirschsprung's disease was first described extensively in 1950 by Rosin [8]. From here on there has been a growing body of literature. There is no clear indicator of the exact number of cases that were reported, apparent in different citations of reported cases. Chen et al., for example, mentions 300 reported cases up until 2006 [5], while Zhang and Ding [9], report 300 reported cases up until 2016 [9]. Adamou (2019) in his turn described a growth from 490 to 600 cases from 2009 till 2019 [10]. Part of this is due to the lack of medical access in certain parts of the world. Adamou (2019), for example, reported that her cases, both in their early twenties, had never received any sort of medical attention before in their lives. It is estimated that 20–40% of the cases of infantile Hirschsprung's disease are diagnosed in Africa, while this is 90% in the Western world [11]. This naturally leads to the unsolved question of whether AHD is simply undiagnosed infantile Hirschsprung's disease, or if it is Adult-onset Hirschsprung's disease. It would explain why many of the articles that I found were outside the Western world, like Niger, Nigeria, and China. It is also an indicator that there may be more attention given to adult Hirschsprung's disease and that it causes more cases of this disease to be recognized.

The case report described earlier is a typical presentation. Credit must be given to Miyamoto for his detailed review and similarly characteristic case report [4]. Here he describes that there is a predominant population of males with an average age of 24 years old. The article describes how patients have chronic constipation since a young age with intervals of one week to 2 months between bowel movements. Later in life, they tend to try and remedy on their own in 73–92%. At some point, like in our case, a patient will have more severe constipation [12] and an actual obstruction. This leads to abdominal distention in 83% of the cases. This is typically paired with pain and tenderness in 40–80% of the cases. Fecal matter is palpable in over 50% due to fecal impaction being present in around 30% of the cases. In the study of Prato et al. [13], he describes that 100% of his pediatric population with Hirschsprung's disease presented with delayed meconium passage [5,8,10]. This is also noted in this literature review where Bakari et al. [14], Ahmad et al. [15], and Shitta et al. [11] noted a history of delayed meconium passage in childhood. 11% of delayed meconium was reported in the AHD population, according to our findings. It is possible however that this information was not asked or passed along in the case reports. Miyamoto's article looked before 2005 and shows similar trends to this research. All patients suffered from a history of chronic constipation with abdominal distention in virtually all cases. We found fewer patients suffering from pain and cases of patients relieving their constipation with home remedies, such as enemas.

Interestingly, Duhamel's procedure appeared to be most successful and with the least number of complications, which was not immediately clear in our systematic review [16]. The three major procedures used, Soave, Swenson's, and Duhamel were all equally used. Soave's and Duhamel's procedures were used with the least number of complications and Swenson's had the most [17,18]. Interestingly, there were a variety of alternative procedures performed as a treatment instead of the well-known and documented procedures used for Hirschsprung's disease [8,19]. Worth noting is that a protective colostomy might make a difference in procedural outcomes [20], which may be an area worth looking into as surgery is the only curative [21].

Unfortunately, many of the case reports that were found simply did not mention the symptoms that were looked at. This can be interpreted as that it was not significantly present, or that it was not recorded. This could potentially skew the data presented to you in this paper. For example, in infants, according to Prato et al. [13], delayed meconium is always present. This would be an interesting topic for future research as this may be a significant indicator or difference between adult and infant Hirschsprung's disease. Second, the low number of patients reported on has limited strength, which can exaggerate certain outcomes. Finally, a problematic point observed by the writer was the lack of definition of successful treatment. What appears to happen is that chronic constipation is regarded as the main concern and that a lack of constipation is deemed a successful outcome. In a few papers which were regarded as uncomplicated, it was mentioned that patients had 3–4 bowel movements per day after the procedure. Further research should be conducted to see whether this is deemed satisfactory by the patient [22–26].

In conclusion: The classic presentation of AHD is typically male, who has a history of chronic constipation that presents with distended abdomen with colicky pain who has a history of laxative use or enemas to remedy chronic constipation. Upon palpation, you will likely be able to palpate masses that are backed up fecal material and possibly will be able to observe peristalsis upon abdominal inspection. In some cases, there will be a history of malnutrition. Upon a barium enema, which should be the first step in the investigation, a dilated colon will be visualized, typically marked by a cutoff point with a shape of a funnel indicating the transition point. A rectal biopsy will display a segment aganglionic intestine, and an anorectal manometry can be implemented to confirm the diagnosis if the rectal biopsy was inconclusive. Surgery is curative and should be picked depending on the comfort level of the surgeon.

Declaration of Competing Interest

The authors report no declarations of interest.

Funding

None.

Ethical approval

Documented on-site in the patient's chart and available upon request.

Consent

Written informed consent was obtained from the patient for publication of this case report and accompanying images. A copy of the written consent is available for review by the Editor-in-Chief of this journal on request.

Author contribution

C. Gamez – Index Case, Review of Drafts.
T. O. DeBoer – Writing of Original Manuscript, Review of Drafts.
N. Saca – Review of Drafts.
L. Umbu – Index Case, Review of Drafts.
S. Shoukry – Final Review, Formatting, Submission.
P. Mashburn – Index Case, Guidance, Final Review.

Registration of research studies

Not applicable.

Guarantor

Christopher Gamez, MD.
Lndry Umbu, MD.

Provenance and peer review

Not commissioned, externally peer-reviewed.

References

- [1] S.E. Kenny, P.K.H. Tam, M. Garcia-Barcelo, Hirschsprung's disease, *Semin. Pediatr. Surg.* 19 (2010) 194–200, <http://dx.doi.org/10.1053/j.sempedsurg.2010.03.004>.
- [2] O. Gulpinar, A. Gucal Guclu, How to write a review article? *Türk Üroloji Dergisi/Turk. J. Urol.* 39 (2014) 44–48, <http://dx.doi.org/10.5152/tud.2013.054>.
- [3] R.A. Agha, T. Franchi, C. Sohrabi, G. Mathew, for the SCARE Group, The SCARE 2020 guideline: updating consensus Surgical Case Report (SCARE) guidelines, *Int. J. Surg.* 84 (2020) 226–230.
- [4] M. Miyamoto, K. Egami, S. Maeda, K. Ohkawa, N. Tanaka, E. Uchida, T. Tajiri, Hirschsprung's disease in adults: report of a case and review of the literature, *J. Nippon Med. Sch.* 72 (2005) 113–120, <http://dx.doi.org/10.1272/jnms.72.113>.
- [5] F. Chen, J.H. Winston, S.K. Jain, W.L. Frankel, Hirschsprung's disease in a young adult: report of a case and review of the literature, *Ann. Diagn. Pathol.* 10 (2006) 347–351, <http://dx.doi.org/10.1016/j.anndiagpath.2006.03.017>.
- [6] E. Lupon, F. Labbe, E. Nini, S. Sondji, Hirschsprung disease in an adult with intestinal malrotation and volvulus: an exceptional association, *J. Med. Case Rep.* 13 (2019) 124, <http://dx.doi.org/10.1186/s13256-019-2020-0>.
- [7] S. Wu, X. Sun, Y. Yu, Y. Shen, Hirschsprung's disease-related giant sigmoid volvulus complicated by refractory hypertension in an elderly man, *Am. J. Case Rep.* 19 (2018) 467–471, <http://dx.doi.org/10.12659/ajcr.908389>.
- [8] J.D. Rosin, J.A. Barga, J.M. Waugh, Congenital megacolon of a man 54 years of age: report of case, *Proc. Staff Meet. Mayo Clin.* 25 (1950) 710–715 <http://www.ncbi.nlm.nih.gov/pubmed/14797838>.
- [9] M. Zhang, K. Ding, Adult congenital megacolon with acute fecal obstruction and diabetic nephropathy: a case report, *Exp. Ther. Med.* 18 (2019) 2726–2730, <http://dx.doi.org/10.3892/etm.2019.7852>.
- [10] H. Adamou, I. Amadou Magagi, O. Habou, O. Adakal, M.B. Aboulaye, A. Robnodji, L. James Didier, R. Sani, H. Abarchi, Diagnosis and surgical approach of adult Hirschsprung's disease: about two observations and review of the literature. *Case series, Ann. Med. Surg.* 48 (2019) 59–64, <http://dx.doi.org/10.1016/j.amsu.2019.10.017>.
- [11] A.H. Shitta, B.T. Ugwu, S.D. Peter, K.N. Ozoilo, P.F. Adighije, B.I. Omolabake, Hirschsprung's disease in an adult: a case report, *J. West Afr. Coll. Surg.* 4 (2014) 121–126 <https://pubmed.ncbi.nlm.nih.gov/26457270>.
- [12] A. Nishijima, S. Shiotani, H. Hayakawa, H. Nishijima, Pseudo-Hirschsprung's disease with rectal hypoganglionosis: an autopsy case of circulatory failure due to severe constipation, *Leg. Med. (Tokyo)* 17 (2015) 177–179, <http://dx.doi.org/10.1016/j.legalmed.2014.11.005>.
- [13] A. Pini Prato, V. Rossi, S. Avanzini, G. Mattioli, N. Disma, V. Jasonni, Hirschsprung's disease: what about mortality? *Pediatr. Surg. Int.* 27 (2011) 473–478, <http://dx.doi.org/10.1007/s00383-010-2848-2>.
- [14] A.A. Bakari, B.M. Gali, A.G. Ibrahim, H.A. Nggada, N. Ali, D. Dogo, A.M. Abubakar, Congenital aganglionic megacolon in Nigerian adults: two case reports and review of the literature, *Niger. J. Clin. Pract.* 14 (2011) 249–252, <http://dx.doi.org/10.4103/1119-3077.84032>.
- [15] T. Ahmad, M. Riaz, A. Khan, M.M. Khan, Hirschsprung's disease: a rare entity in adults, *J. Coll. Phys. Surg. Pak.* 29 (2019) 674–676, <http://dx.doi.org/10.29271/jcpsp.2019.07.674>.
- [16] Y. Han, M.-B. Lin, Y.-J. Zhang, L. Yin, Total laparoscopic modified Duhamel operation in combination with transanal endoscopic microsurgery, *JSL J. Soc. Laparoendosc. Surg.* 18 (2014) 128–131, <http://dx.doi.org/10.4293/108680813X13693422520288>.
- [17] A.O. Ademuyiwa, C.O. Bode, O.A. Lawal, J. Seyi-Olajide, Swenson's pull-through in older children and adults: peculiar peri-operative challenges of surgery, *Int. J. Surg.* 9 (2011) 652–654, <http://dx.doi.org/10.1016/j.ijisu.2011.08.006>.
- [18] M. Adhi, S. Khan, H. Zafar, M. Arshad, Duhamel's procedure for adult Hirschsprung's disease, *J. Coll. Phys. Surg.* 22 (2012) 395–397, PMID: 22630102, <https://jcpsp.pk/archive/2012/Jun2012/14.pdf>.
- [19] C. Calkins, Hirschsprung disease beyond infancy, *Clin. Colon Rectal Surg.* 31 (2018) 051–060, <http://dx.doi.org/10.1055/s-0037-1604034>.
- [20] N.D. Duncan, J. Plummer, S.E. Dundas, A. Martin, A.H. McDonald, Adult Hirschsprung's disease in Jamaica: operative treatment and outcome, *Colorectal Dis.* 13 (2011) 454–458, <http://dx.doi.org/10.1111/j.1463-1318.2009.02174.x>.
- [21] J.A. López Ruiz, L. Tallón Aguilar, L. Sánchez Moreno, J. López Pérez, F. Pareja Ciurol, F. Oliva Mompeán, F.J. Padillo Ruiz, Hirschsprung disease with debut in adult age as acute intestinal obstruction: case report, *Rev. Esp. Enferm. Dig.* 108 (2016) 742–746, <http://dx.doi.org/10.17235/reed.2016.3841/2015>.
- [22] F.L.S. Tan, Y.-M. Tan, S.M. Heah, F. Seow-Choen, Adult Hirschsprung's disease presenting as sigmoid volvulus: a case report and review of literature, *Tech. Coloproctol.* 10 (2006) 245–248, <http://dx.doi.org/10.1007/s10151-006-0288-8>.
- [23] C. Fortea-Sanchís, D. Martínez-Ramos, I. Rivadulla-Serrano, J.M. Daroca-José, G. Paiva-Coronel, J.L. Salvador-Sanchís, Hirschsprung's disease in adults, *Rev. Esp. Enferm. Dig.* 103 (2011) 150–151, <http://dx.doi.org/10.4321/s1130-01082011000300007>.
- [24] J.-F. Qiu, Y.-J. Shi, L. Hu, L. Fang, H.-F. Wang, M.-C. Zhang, Adult Hirschsprung's disease: report of four cases, *Int. J. Clin. Exp. Pathol.* 6 (2013) 1624–1630 <http://www.ncbi.nlm.nih.gov/pubmed/23923081>.
- [25] C.M. Fielding, E.G. Holt, Abdominal distension and constipation in an adult, *Clin. Gastroenterol. Hepatol.* 13 (2015) e163, <http://dx.doi.org/10.1016/j.cgh.2015.04.004>.
- [26] A. Bapaye, G. Waghlikar, S. Jog, A. Kothurkar, S. Purandare, N. Dubale, R. Pujari, M. Mahadik, V. Vyas, J. Bapaye, Per rectal endoscopic myotomy for the treatment of adult Hirschsprung's disease: first human case (with video), *Dig. Endosc.* 28 (2016) 680–684, <http://dx.doi.org/10.1111/den.12689>.

Open Access

This article is published Open Access at [sciencedirect.com](https://www.sciencedirect.com). It is distributed under the [IJSCR Supplemental terms and conditions](#), which permits unrestricted non commercial use, distribution, and reproduction in any medium, provided the original authors and source are credited.