

Case Report

Retinal Endovascular Surgery with Tissue Plasminogen Activator Injection for Central Retinal Artery Occlusion

Yuta Takata Yasuhito Nitta Akio Miyakoshi Atsushi Hayashi

Department of Ophthalmology, University of Toyama, Toyama, Japan

Keywords

Central retinal artery occlusion · Retinal endovascular surgery · Tissue-type plasminogen activator · Vitrectomy

Abstract

Purpose: To report 2 cases of central retinal artery occlusion (CRAO) who underwent retinal endovascular surgery with injection of tissue plasminogen activator (tPA) into the retinal artery and showed a remarkable improvement in visual acuity and retinal circulation. **Methods:** Standard 25-G vitrectomy was performed under local anesthesia. Simultaneously, tPA (80,000 units/mL) solution was injected into the retinal artery of the optic disc for 2–3 min using a microneedle. Changes in visual acuity, fundus photography, optical coherence tomography (OCT), fluorescein angiography, and laser speckle flowgraphy (LSFG) results were examined. **Results:** Both cases could be treated within 12 h after the onset of CRAO. Case 1 was a 47-year-old woman. Her visual acuity improved from counting fingers before operation to 0.08 logMAR 1 month after the surgery. However, thinning of the retina at the macula was observed by OCT. Case 2 was a 70-year-old man. His visual acuity improved from counting fingers to 0.1 logMAR 2 months after the surgery. Both fluorescein angiography and LSFG showed improvement in retinal circulation after the surgery in case 2. **Conclusions:** Retinal endovascular surgery with injection of tPA into the retinal artery was feasible and may be a way to improve visual acuity and retinal circulation when performed in the acute phase of CRAO.

© 2018 The Author(s)
Published by S. Karger AG, Basel

Introduction

Non-arteritis central retinal artery occlusion (CRAO) is a disorder in which retinal blood flow in the retinal artery is interrupted by an embolus or thrombus causing sudden loss of visual acuity due to retinal ischemia and necrosis [1]. Several treatments such as ocular massage, anterior chamber paracentesis, acetazolamide administration, hyperbaric oxygen therapy, and fibrinolytic therapy have been performed for CRAO, but the prognosis for visual acuity is typically poor [1].

We and others have shown that retinal endovascular surgery with injection of a tissue plasminogen activating factor (tPA) into the retinal vein for central retinal vein occlusion was effective at improving visual acuity [2, 3]. Recently, intraretinal arterial cannulation for CRAO was shown to significantly improve visual acuity from -1.6 to -0.82 logMAR at 1 month [4]. Here, we introduce direct injection of tPA into the retinal artery as a treatment for acute CRAO.

We report 2 CRAO cases who underwent this endovascular surgery within 12 h after the onset of CRAO and showed a significant improvement in visual acuity and retinal circulation.

Case Description

Case 1

A 47-year-old woman with no medical history presented with sudden visual loss in her right eye. The visual acuity of the right eye was counting fingers. The anterior segment examination was normal. A cherry red spot was found in the macula of the right eye (Fig. 1a). The optical coherence tomography (OCT) image showed increased reflectivity of the inner retinal layers in the macula (Fig. 1b). We diagnosed the patient with CRAO in the right eye and performed retinal endovascular surgery 8 h after the onset. This treatment was approved by the Ethics Review Board of the University of Toyama.

The surgical procedures were as follows. Under local anesthesia, pars plana vitrectomy was performed with the standard 4-port system of 25-G size. After the vitreous had been visualized by triamcinolone acetonide, posterior vitreous detachment was created and vitrectomy was performed. tPA (Monteplase; Eisai Co., Ltd., Tokyo, Japan) was dissolved in saline and adjusted to 80,000 units/mL. About 1 mL of the tPA solution was placed in a 1-mL syringe (MedOne Surgical, Inc., Sarasota, FL, USA), a specially made microneedle (Tochigi Seiko, Co., Ltd., Tochigi, Japan) was attached, and the syringe was connected to the viscous fluid control system of the vitrectomy machine (Constellation[®] Vision System; Alcon, Fort Worth, TX, USA). After thoroughly removing the air from the microneedle, we introduced it into the vitreous cavity, inserted it into the retinal artery at the optic disc, and injected about 0.1–0.2 mL of tPA solution into the retinal artery over the course of 2 or 3 min (see online suppl. video; for all online suppl. material, see www.karger.com/doi/10.1159/000489696). During the injection, the tPA solution flushed the blood from the blood vessel, and the red color of the arteries disappeared and turned white. As this change could be seen in both the retinal arteries and the retinal veins, we determined that the injection was successful. Bleeding occurred when the needle was removed from the retinal artery after the tPA injection. The bleeding was stopped by raising the intraocular pressure to 35 mm Hg and waiting for 3–5 min. The blood was then removed and fluid-air exchange was performed.

There were no complications after the surgery. The visual acuity of the right eye remarkably improved to 1.4 logMAR at 3 days, 0.3 logMAR at 5 days, 0.1 logMAR at 1 week, and 0.08

logMAR 1 month after the surgery. Fundus photographs and OCT images 3 days (Fig. 1c, d) and 1 month (Fig. 1e, f) after the surgery are shown.

Case 2

A 70-year-old man with hypertension presented with sudden vision loss in the right eye. The visual acuity of his right eye was counting fingers. The anterior segment examination was normal except for cataracts. Fundus examination showed a cherry red spot in the macula of his right eye (Fig. 2a). OCT imaging showed increased reflectivity of the inner retinal layers of the macula of his right eye (Fig. 2b). Preoperative fluorescein angiography of the right eye revealed a delay in arterial filling (Fig. 2e). With the diagnosis of CRAO in the right eye, we performed retinal endovascular surgery and simultaneous cataract surgery 12 h after the onset. This case showed a postoperative vitreous hemorrhage 1 day after the surgery, with visual acuity at 0.7 logMAR. An additional vitreous surgery was performed 5 days after the first surgery to remove the vitreous hemorrhage. The patient's visual acuity improved to 0.7 logMAR 1 week and 0.22 logMAR 1 month after the surgery. A postoperative fundus photograph and OCT image are shown in Figure 2c and d. Fluorescein angiography showed early filling of the retinal artery and recovery of retinal circulation (Fig. 2g). On laser speckle flowgraphy (LSFG) (LSFG-NAVI; Nidek, Gamagori, Japan), the mean blur rate value of the optic disc increased from 6.4 before the surgery (Fig. 2f) to 35.5 two months after the surgery (Fig. 2h). Visual acuity remarkably improved to 0.1 logMAR at 2 months.

Discussion

This report presents 2 cases of CRAO (2 eyes) that underwent retinal endovascular surgery within 12 h after onset and achieved a greatly improved visual acuity 2 months after the surgery. We could perform pre- and postoperative examinations by fluorescein angiography and LSFG only for case 2; the images showed improvement of retinal blood flow after the surgery [5].

In animal experiments, irreversible damage to the retina occurred after 4 h of CRAO [6]. In clinical practice, we often observe incomplete occlusion of the retinal artery in CRAO cases, but treatment should be initiated as soon as possible [1].

No standard treatment for CRAO has been established. An EAGLE study showed a similar efficacy in a local intra-arterial fibrinolysis group and a conservative standard treatment group [7], but the authors concluded that local intra-arterial fibrinolysis is not recommended because of its higher rate of adverse reactions. Others reported direct approaches to retinal emboli or thrombi in a small number of CRAO cases. Feist and Emond [8] described using a transluminal YAG laser to photodisrupt a visible embolus in the retinal artery. García-Arumí et al. [9] described surgical removal of the embolus by incision of the retinal artery. However, these approaches are not widely accepted.

A previous investigation reported that 74% of retinal emboli are composed of cholesterol, 10.5% of calcific material, and 15.5% of platelet-fibrin [10]. Another study reported that visible retinal emboli were observed in only 17% of CRAO and about half of them were platelet-fibrin emboli [11]. Since tPA cannot dissolve cholesterol or calcific materials, the effects of this retinal endovascular surgery with tPA injection may be limited to CRAO induced by platelet-fibrin thrombi.

Neither of our cases showed any visible emboli in the retinal artery, which suggested a platelet-fibrin thrombus. This may be one reason why our technique of retinal endovascular

surgery accompanied by tPA injection was effective at improving the patients' visual acuity and recovering retinal circulation. Our technique has another advantage, namely that of no possible systemic complications, because only 16,000–24,000 units of tPA were injected into the retinal artery. However, further study is obviously needed to confirm the efficacy of this treatment.

Conclusions

We successfully treated 2 cases of CRAO by retinal endovascular surgery with injection of tPA within 12 h after the onset. Visual acuity was improved to -0.08 and 0.1 logMAR, respectively, 2 months after the surgery. This study demonstrates that our technique is feasible and may provide a new treatment modality for some CRAO patients.

Statement of Ethics

The authors have no ethical conflicts to disclose.

Disclosure Statement

All authors have no conflict of interest in this study.

References

- 1 Patel PS, Sadda SR. Retinal artery occlusions. In: Schachat AP, Sadda SR, editors. *Ryan's Retina*. 6th ed. Elsevier; 2018. p. 1136–50.
- 2 Kadosono K, Yamane S, Arakawa A, Inoue M, Yamakawa T, Uchio E et al. Endovascular cannulation with a microneedle for central retinal vein occlusion. *JAMA Ophthalmol*. 2013 Jun;131(6):783–6.
- 3 Ishida M, Abe S, Nakagawa T, Hayashi A. Short-term results of endovascular surgery with tissue plasminogen activator injection for central retinal vein occlusion. *Graefes Arch Clin Exp Ophthalmol*. 2017 Nov;255(11):2135–40.
- 4 Kadosono K, Yamane S, Inoue M, Yamakawa T, Uchio E. Intra-retinal Arterial Cannulation using a Microneedle for Central Retinal Artery Occlusion. *Sci Rep*. 2018 Jan;8(1):1360.
- 5 Sugiyama T, Araie M, Riva CE, Schmetterer L, Orgul S. Use of laser speckle flowgraphy in ocular blood flow research. *Acta Ophthalmol*. 2010 Nov;88(7):723–9.
- 6 Hayreh SS, Zimmerman MB, Kimura A, Sanon A. Central retinal artery occlusion. Retinal survival time. *Exp Eye Res*. 2004 Mar;78(3):723–36.
- 7 Schumacher M, Schmidt D, Jurklies B, Gall C, Wanke I, Schmoor C, et al.; EAGLE-Study Group. Central retinal artery occlusion: local intra-arterial fibrinolysis versus conservative treatment, a multicenter randomized trial. *Ophthalmology*. 2010 Jul;117(7):1367–75.e1.
- 8 Feist RM, Emond TL. Transluminal Nd:YAG laser embolysis for central retinal artery occlusion. *Retina*. 2005 Sep;25(6):797–9.
- 9 García-Arumí J, Martínez-Castillo V, Boixadera A, Fonollosa A, Corcostegui B. Surgical embolus removal in retinal artery occlusion. *Br J Ophthalmol*. 2006 Oct;90(10):1252–5.
- 10 Arruga J, Sanders MD. Ophthalmologic findings in 70 patients with evidence of retinal embolism. *Ophthalmology*. 1982 Dec;89(12):1336–47.
- 11 Cho KH, Ahn SJ, Cho JH, Jung C, Han MK, Park SJ et al. The Characteristics of Retinal Emboli and its Association With Vascular Reperfusion in Retinal Artery Occlusion. *Invest Ophthalmol Vis Sci*. 2016 Sep;57(11):4589–98.

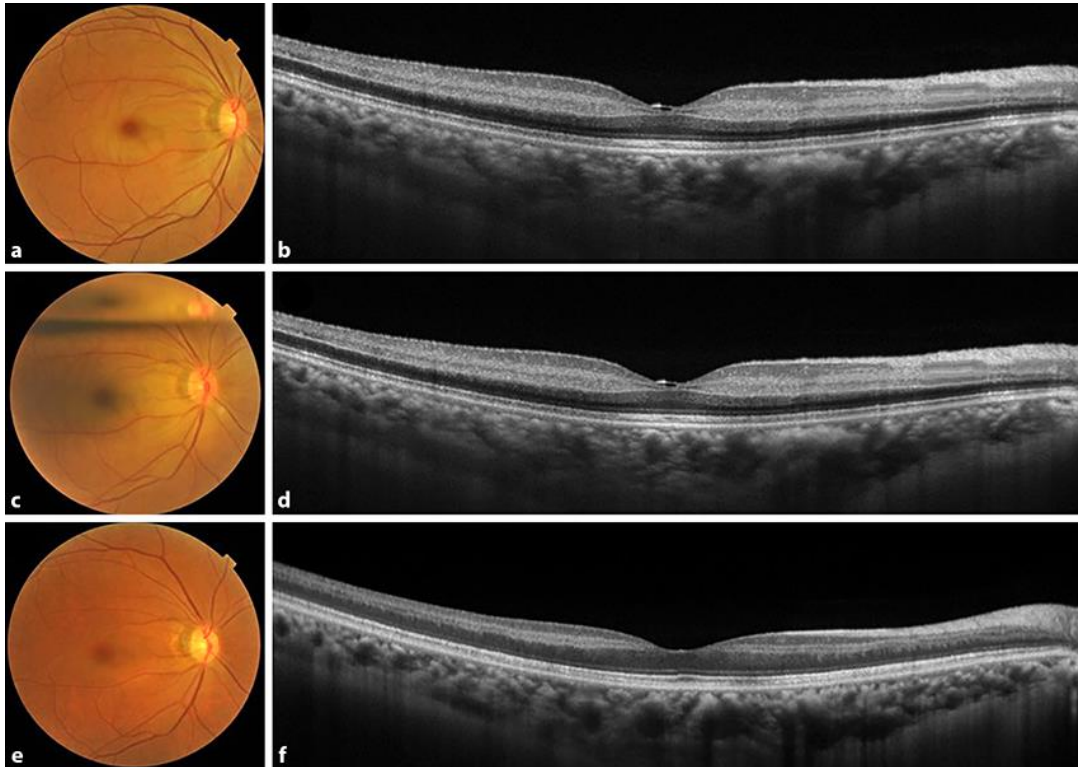


Fig. 1. Photographs of the right eye of case 1. **a, b** Preoperative fundus photograph (**a**) and optical coherence tomography (OCT) image (**b**). **c, d** Fundus photograph with a gas bubble (**c**) and OCT image (**d**) 3 days after the retinal endovascular surgery. **e, f** Fundus photograph (**e**) and OCT image (**f**) 1 month after the surgery.

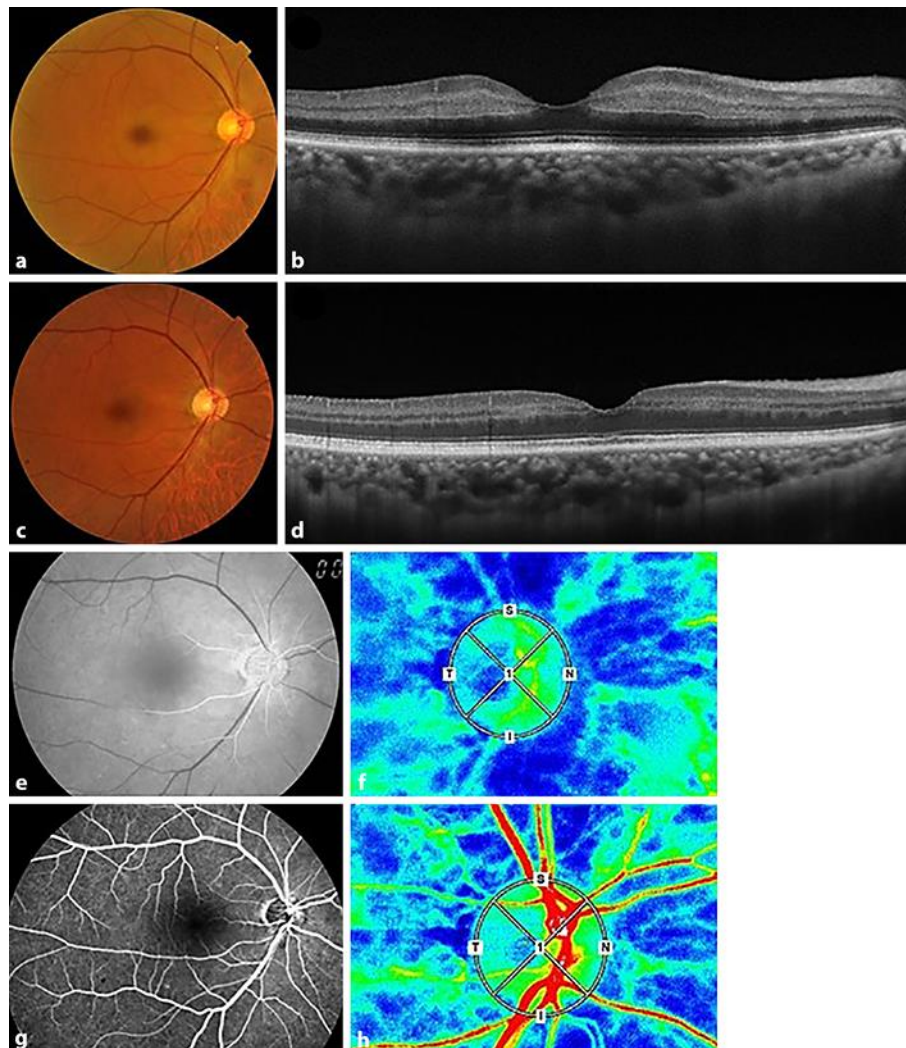


Fig. 2. Photographs of the right eye of case 2. **a, b** Preoperative fundus photograph (**a**) and optical coherence tomography (OCT) image (**b**). **c, d** Fundus photograph (**c**) and OCT image (**d**) 1 month after the retinal endovascular surgery. **e, f** Preoperative fluorescein angiogram (**e**) and laser speckle flow graph (**f**). **g, h** Fluorescein angiogram (**g**) 3 weeks after the surgery and laser speckle flow graph (**h**) 2 months after the surgery. **f, h** The circles demarcate the optic disc. **e, g** The photographs were taken 35 s after fluorescein injection.