

Comparison of Surgical and Oncological Outcomes between Chest Wall Perforator Flaps and Therapeutic Mammoplasty

Samreen Khan, MBBS
John Mathew, MS, FRCS, DM,
FRCS (Surgery)

Background: Chest wall perforator flaps (CPF) and therapeutic mammoplasty (TM) are often done in patients with anticipated poor cosmetic outcome with level 1 breast conservation surgery. The aim of this study was to assess the complications and oncological outcomes between CPF and TM.

Methods: Prospectively collected data of breast conservation surgery between September 2016 and January 2021 by a single surgeon were reviewed. Specific outcomes included complications needing intervention, re-excision and mastectomy rate, locoregional recurrence, and distant metastasis. Patients were followed up at 3 months and then every 12 months. Statistical analysis included chi-squared test and independent *t* test, and a *P* value of less than 0.05 was considered significant.

Results: There was no statistically significant difference between CPF and TM with regard to patient characteristics except for BMI and bra cup size, which was significantly higher in the TM group. One patient who had TM returned to the operating room for a hematoma evacuation, and one patient who had CPF had fat grafting, for unsatisfactory cosmetic outcome. Five of the 30 patients having CPF had further re-excision surgery for inadequate margins, but none needed mastectomy, and four of the 43 patients having TM had further surgery (one had re-excision of margins and three had mastectomy) and this was not statistically significant (*P* = 0.346). There was no locoregional recurrence in CPF and TM groups after a median follow-up of 22 months and 25 months, respectively.

Conclusion: There is no significant difference in early complications and oncological outcomes between CPF and TM. (*Plast Reconstr Surg Glob Open* 2021;9:e3811; doi: 10.1097/GOX.0000000000003811; Published online 7 September 2021.)

INTRODUCTION

Level 1 oncoplastic surgery involves tumor excision requiring less than 20% of breast volume and this does not require specialist plastic surgery techniques.¹ In patients requiring larger excision (level 2 oncoplastic surgery), a volume displacement technique like therapeutic mammoplasty (oncoplastic application of breast reduction and mastopexy techniques to treat selected breast tumors)² or volume replacement technique like chest wall perforator flaps (CPF) are required to avoid asymmetry and breast deformity.

It is well documented that excision of more than 20% of the breast volume may result in significant deformity without these level 2 procedures.³ These deformities are

difficult to manage with high levels of complications and patient dissatisfaction.⁴ Mastectomy can be avoided in a significant proportion of patients because of the option of these level 2 procedures.

Location of the tumor is another factor to consider when planning breast conservation surgery. Excision of tumors involving the lower quadrants of the breast are associated with increased deformity compared with other areas and special consideration needs to be taken when considering surgery in these areas.⁵ Tumors involving all quadrants of the breast can be managed with these level 2 procedures. Often patients have the option of both these procedures, and final choice may depend on various patient and tumor factors, which need to be discussed with the patient. Some patients would prefer avoiding scars on the breast itself or dislike contralateral procedures for symmetry and these patients may choose CPF. In

From the Peterborough City Hospital North West Anglia NHS Foundation Trust, Peterborough, United Kingdom.

Received for publication April 9, 2021; accepted July 12, 2021.

Copyright © 2021 The Authors. Published by Wolters Kluwer Health, Inc. on behalf of The American Society of Plastic Surgeons. This is an open-access article distributed under the terms of the [Creative Commons Attribution-Non Commercial-No Derivatives License 4.0 \(CCBY-NC-ND\)](https://creativecommons.org/licenses/by-nc-nd/4.0/), where it is permissible to download and share the work provided it is properly cited. The work cannot be changed in any way or used commercially without permission from the journal.

DOI: 10.1097/GOX.0000000000003811

Disclosure: The authors have no financial interest to declare in relation to the content of this article.

Related Digital Media are available in the full-text version of the article on www.PRSGlobalOpen.com.

contrast, others may prefer smaller uplifted breasts and do not mind scars on their breast. These patients may choose therapeutic mammoplasty (TM). However, in patients with very small breasts or those with no ptosis, CPF may be the only option. Tumor replacement technique with CPF allows higher volume of breast excision in patients with high tumor-to-breast ratio. Even T4 tumors with skin involvement can be excised widely and the cavity replaced with a skin paddle based on chest wall perforator as shown in [Figure 1](#). (See [Video \[online\]](#), which displays lateral chest wall perforator flap reconstruction.)

Donor site morbidity is a concern in volume replacement techniques where they have a scar in the side of the chest wall towards the back, often in the bra line in cases of lateral chest wall perforator as shown in [Figure 2](#). Chest wall perforator flap is a relatively new technique compared with therapeutic mammoplasty in breast cancer surgery, and complications and oncological outcomes of these two procedures has not been compared previously.

METHODS

A review of prospectively collected data of consecutive patients having breast conservation surgery between September 2016 and January 2021 by a single surgeon was performed. Patient characteristics, treatment details, and surgical outcomes were noted. Specific outcomes included complications needing intervention, re-excision rate, and mastectomy rate. We also looked into the incidence of locoregional recurrence and distant metastasis between the two groups.

Patients with breast cancers diagnosed on screening or after a symptomatic presentation were reviewed. Treatment plan was decided in the multidisciplinary settings consisting of breast surgeons, radiologists, pathologists, oncologists, and breast care nurses. The MDT made the decision to offer the patient level-2 procedure based on the size of the tumor in relation to the size of the breast on imaging. The pros and cons of the procedure or procedures, if they had both options, were discussed with the patient by the oncoplastic breast surgeon. In some patients with small breasts or those with no ptosis, therapeutic mammoplasty was not deemed a good option. These patients were offered perforator flaps. Patients undergoing TM were offered a symmetrization procedure

at a later date. Neoadjuvant and adjuvant treatments were administered according to local evidence-based guidelines of the breast unit. Unit guidelines help to achieve a clear margin of 1 mm following wide local excision and those with less than 1 mm margin had re-excisions following discussion at the MDT. All patients received postoperative radiation treatment.

Four factors are taken into account when choosing the surgical option.

- 1) Anticipated volume of the residual breast after wide local excision and position of nipple. Both the procedures were often suitable in all patient groups except in patients with small breasts with no ptosis where perforator flap may be the only option. [Figure 3](#) shows a flowchart that provides a guide to how decisions were made. In patients with grade 3 ptosis as per Regnault classification,⁶ the first choice of procedure was therapeutic mammoplasty.
- 2) Site of the tumor. If the bulk of the tumor was closer to the periphery of the breast compared with the nipple areola complex except in medially placed tumors, we were likely to offer CPF. On the contrary, if the bulk of the tumor was closer to the nipple areola complex, we were more likely to offer TM.
- 3) Axillary surgery. When planning lateral chest wall perforators, to achieve better perfused flaps, we try to preserve both the LICAP and LTAP if possible. We usually sacrifice the LTAP vessels during axillary clearance. Thus, preserving both LICAP and LTAP may be valuable in situations where axillary clearance is advised after positive SLNB. Another alternative in the situation where SLNB is positive in a patient who had LTAP is to offer radiation treatment to the axilla (which is not unit policy and only done if MDT agrees in special circumstance or part of a trial). A third option we offer in a situation where SLNB is positive in a patient who had an LTAP is to do the axillary clearance after the adjuvant chemotherapy is completed; this will allow time for the flap to develop collaterals from the recipient site. Here, the sequencing of chemotherapy and axillary clearance is similar to those patients having pre-neoadjuvant sentinel node biopsy,^{7,8} the only difference being the breast conservation surgery is done before chemotherapy.

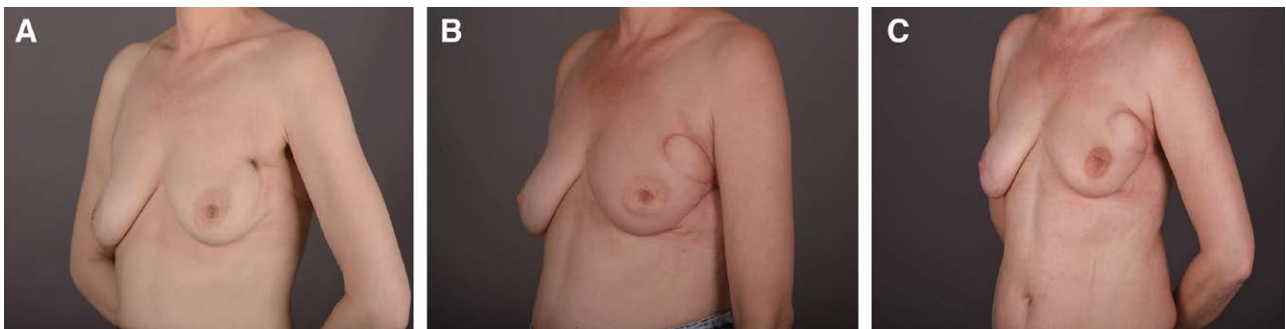


Fig. 1. Preoperative photograph (A), 3 months postoperative photograph (B), and 18 months postoperative photograph (C) of a patient who had left LTAP flap reconstruction for locally advanced breast cancer with skin involvement.

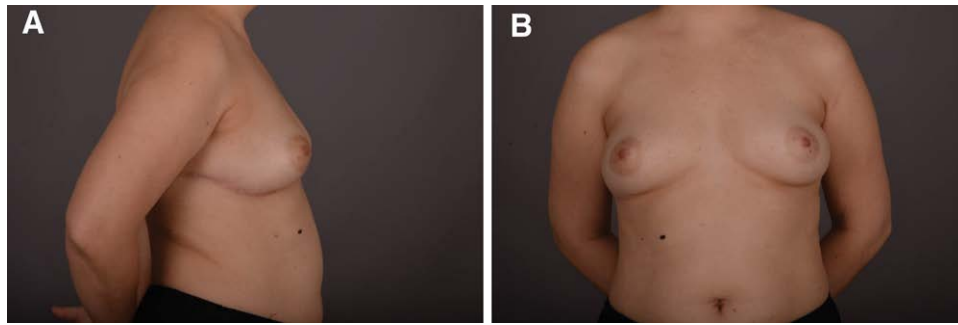


Fig. 2. Lateral (A) and front (B) views of patients who had right lateral chest wall perforator flap reconstruction at 5 months after surgery.

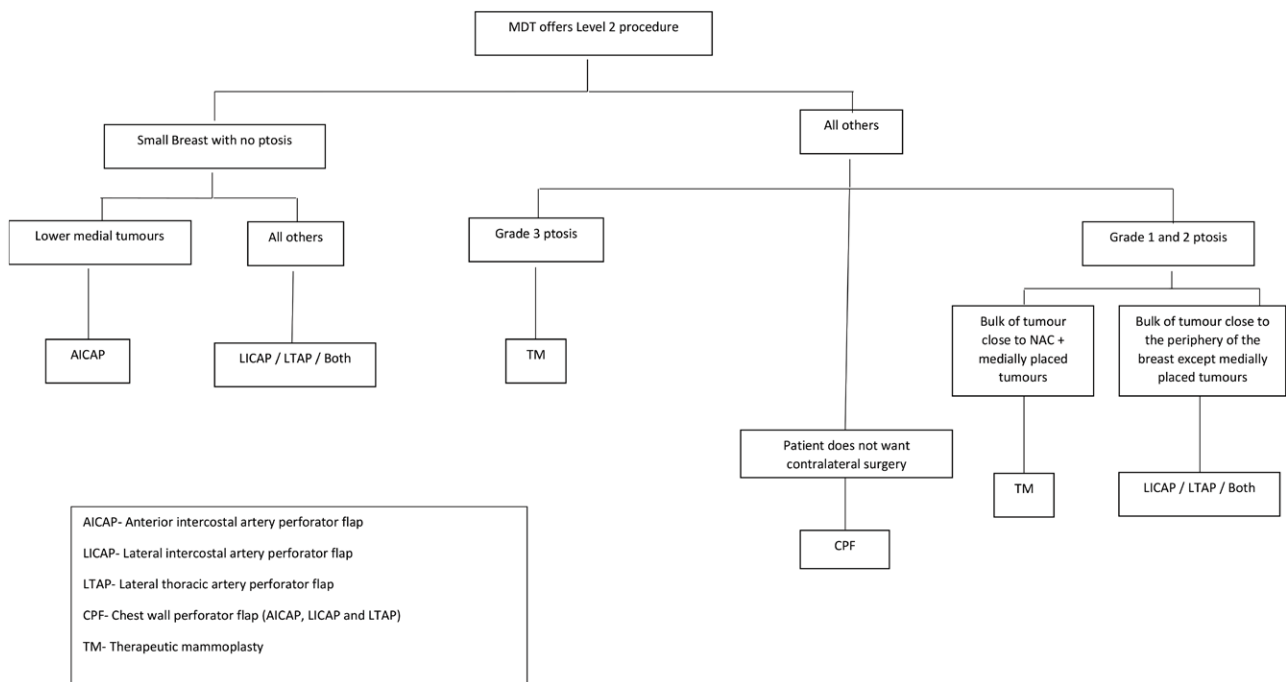


Fig. 3. Flow chart showing how the decisions are made with regard to operation.

- 4) Contralateral surgery. A proportion of patients would like to avoid contralateral surgery and would prefer CPF to TM.

Chest wall perforator flap planning and procedure. Three named perforator flaps were used for partial breast reconstruction: lateral intercostal artery perforator flap (LICAP), lateral thoracic artery perforator flap (LTAP), and anterior intercostal artery perforator flap (AICAP).

Chest wall perforators were localized preoperatively with a handheld Doppler. Patients were placed in supine position with sandbag in the back to get adequate access. Arm is usually kept at 90 degrees on an arm board. If additional exposure of the back is required for larger flaps, arm and forearm are flexed and the forearm and the hand are supported on a padded stand safely in front of the forehead.

The surgeon used 2.5 magnification for dissection. Wide local excision was done first in all patients. In patients undergoing lateral CPF and SLNB, long

thoracic artery perforator was identified and dissected out first to prevent inadvertent injury to the vessel while doing SLNB. In patients undergoing axillary node clearance, lateral thoracic artery perforator was compromised. Axillary clearance can be done with low incisions used for lower quadrant tumors. For tumors involving the lower outer quadrant, a turnover flap is often used as shown in [Figure 4](#). For tumors located higher up the breast, a similar turnover flap can be used, but in some cases the flap could be propelled into the defect as shown in [Figure 5A](#). In cases where additional access is required to the upper outer quadrant of the breast or if an area of the skin in the upper outer quadrant needs to be excised along with the tumor, the incision can be extended upward and closed, as shown in [Figure 5](#). [Figure 6](#) shows the postoperative picture of a patient who had excision of skin tethered with cancer in the left upper outer quadrant. [Figure 7](#) shows the postoperative picture of patients who had the extended incision for additional access.

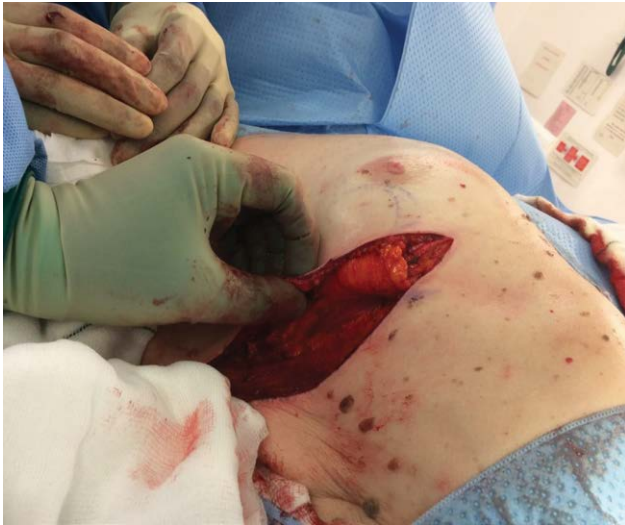

Fig. 4. LICAP turnover flap for lower outer quadrant tumor.

Length of the flap is dependent on the distance from the medial edge of the cavity following wide local excision to the proposed pedicle (the pivot point). Although flap markings are made preoperatively, the decision with regard to the final length is made intraoperatively based on the above dimensions. Where additional bulk is required at the recipient site, a longer flap is planned, which flops loosely and folds on itself in the wide local excision cavity. The donor site incision does not cross the midline and in those who need additional bulk, the incision can be curved upward as shown in [Figure 5A](#) and the donor defect closed as in [Figure 5B](#). The de-epithelization of the flap is performed at the end after the flap dissection, and bleeding from the de-epithelized skin especially at the tip is often reassuring. Patients undergoing large excisions should be warned regarding lateral deviation of the nipple as shown in [Figure 6](#). This can be corrected on a later date.

AICAP are done for medially located tumors in the lower quadrant of the breast. [Figure 8](#) shows the preoperative picture of a woman with a tumor involving the lower inner quadrant of the breast with dimpling, and the intraoperative picture after excision of cancer.

Therapeutic mammoplasty. Wise pattern and vertical scar techniques were used to approach tumors in different quadrants of the breast. Tumor defects located outside the classic reduction area were approached with primary pedicles or using dual pedicles.

Length of follow-up was defined from the date of diagnosis to the last clinic or imaging appointment. Patients were followed up at 3 months and then every 12 months by surveillance mammogram and clinical examination. Evidence of recurrences and distant metastasis were obtained from patients' MDT notes and their clinical, radiological and pathology records.

Statistical analysis. Data were stored, and statistical analysis was done on Microsoft excel (version 16). The results were presented as number of cases with percentage in brackets or median with range in brackets. Chi-squared test was used to analyze any statistical difference between the two groups (CPF and TM) with regard to type of presentation, bra cup size, pathology type (DCIS or invasive), patients having neoadjuvant chemotherapy, grade, ER status, her-2 status, node positive disease and outcomes measured. Independent t-test was used to assess any statistically significant difference between the groups with regard to age, BMI and size of the tumor. A *P* value of less than 0.05 was considered significant.

RESULTS

One hundred and eighty-seven patients had breast conservation surgery during this period as shown in [Table 1](#): CPF—30, TM—43, level 1 breast conservation surgery—114. There was no statistically significant difference between CPF and TM with regard to presentation, median age, operation for DCIS or invasive disease, median size on radiology, and patients receiving neoadjuvant chemotherapy. There was also no difference between the two groups with regard to final pathology, as shown in [Table 2](#). Median sizes of the tumor on pathology were 25mm, 26mm and 16mm in patients who had CPF, TM, and level 1 breast conservation surgery, respectively. Patients undergoing TM had a significantly higher BMI and bra cup being D and above compared with CPF.

One patient who had anterior intercostal perforator flap had fat grafting for unsatisfactory cosmetic outcome and

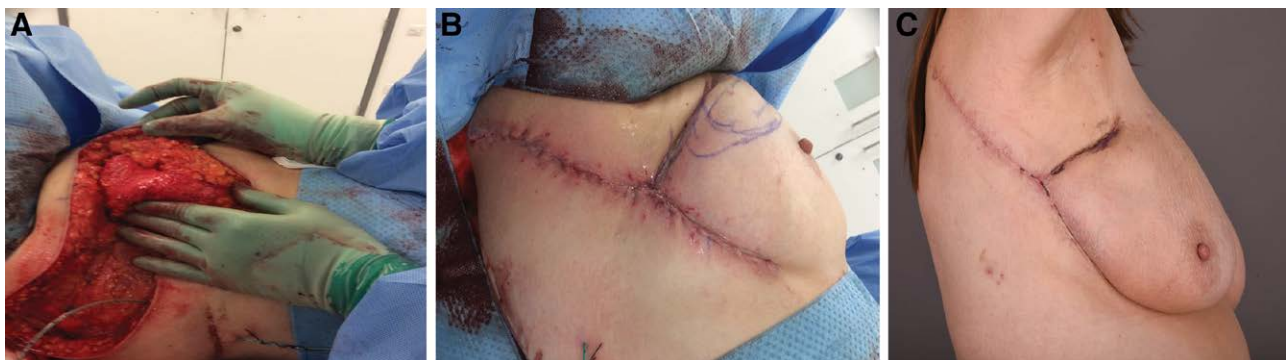

Fig. 5. Lateral chest wall perforator flap (LTAP+LICAP) for a multifocal breast cancer involving the upper outer quadrant of the right breast (specimen weight- 322gms). A, The flap being propelled into the defect. B, Closure of the extended incision for additional access to the upper outer quadrant. C, 2-week postoperative photograph of the patient with extended incision with glue dressing.

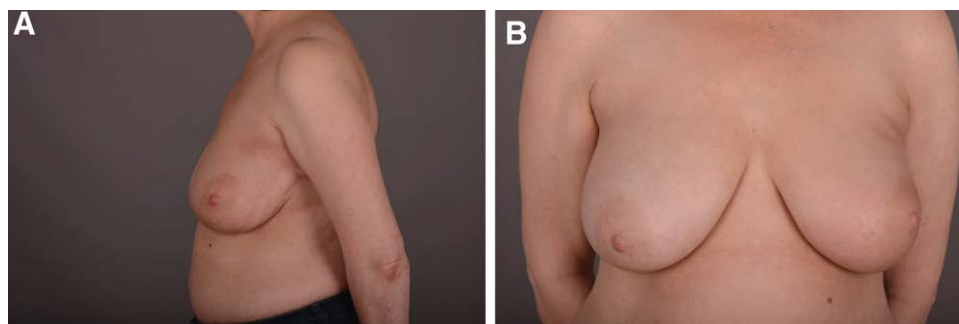


Fig. 6. Lateral (A) and frontal (B) views at 18-months postoperative of a patient who had the extended incision with excision of the tumor with the overlying skin (left breast).

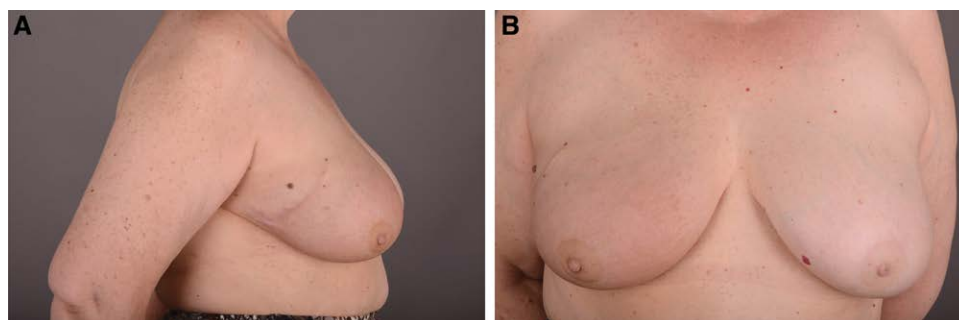


Fig. 7. Lateral (A) and frontal (B) views at 24-months postoperative of a patient who had extended incision for a tumor involving right upper outer quadrant.

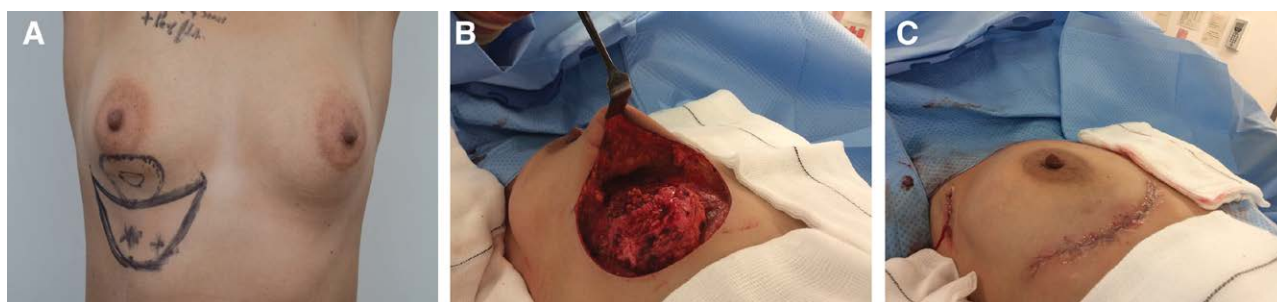

Fig. 8. A, Preoperative photograph of a patient with tumor involving the lower inner quadrant of the breast with dimpling. B, C, Intraoperative photographs of mobilized AICAP after tumor excision and subsequent closure.

one patient who had TM returned to the operating room for hematoma, as shown in Table 3. In our study, three patients with CPF complained of pain at the donor site at 3 months, two of them settled spontaneously, and one needed to be referred to the pain team. Two patients who had lateral chest wall perforator flap had lateral deviation of the nipple following the operation and radiotherapy. Both patients were not concerned and declined any correction.

Of the 43 patients undergoing TM, 11 had symmetrization procedure of the contralateral side during the follow-up period. None of the patients with CPF had contralateral surgery.

Five of the 30 patients who had CPF had re-excision of margins, but none needed mastectomy. Only one patient who had TM had re-excision of margins and three patients underwent mastectomy because of multiple margin involvement.

Three patients developed distant metastasis in the CPF group after a median follow-up of 22 months. Four patients developed distant metastasis in TM group after a median follow-up of 25 months. There was no locoregional recurrence in either group.

DISCUSSION

This article looks into the early-to-medium term outcomes of partial breast reconstruction with perforator flap compared with therapeutic mammoplasty. Perforator flap reconstruction is a relatively new procedure. Although Hamdi et al described its use in partial breast reconstruction in 2006,^{9,10} its popularity has picked up pace only recently. The two groups in this study were comparable. There was no statistically significant difference between the two groups (CPF and TM) with regard to presentation, median age, operation for DCIS or invasive disease, median size,

Table 1. Patient Characteristics and Treatment of Patients Having Breast Conservation Surgery

Characteristics and Treatment	Chest Wall Perforator Flaps (30) LICAP 12 LTAP 2 LICAP + LTAP 13 AICAP 3 Median Follow-up 22 M (1-49)		Therapeutic Mammoplasty (43) Wise 23 Vertical 20 Median Follow-up 25 m (2-50)		CPF versus TM P value	Level 1 Breast Conservation Surgery (114) Median Follow-up 24 (1-50)
Symptomatic versus screening	28 (93%)	versus 2 (7%)	34 (79%)	versus 9 (21%)	0.093	60 (53%) versus 54 (47%)
Median age (y)	54	(31-78)	55	(38-86)	0.497	59 (35-88)
Median BMI	25	(16-35)	31	(20-44)	0.001	
Bra cup A, B & C versus D and above	24 (80%)	versus 6 (20%)	11 (26%)	versus 32 (74%)	0.001	
DCIS versus invasive	2 (7%)	versus 28 (93%)	5 (12%)	versus 38 (88%)	0.478	19 (17%) versus 95 (83%)
Median size on radiology	24 mm	(11-55)	25 mm	(6-76)	0.119	14 mm (3-50)
Neoadjuvant chemotherapy	11 (37%)		13 (30%)		0.430	14 (12%)

Table 2. Postoperative Pathology Data of Patients Undergoing Breast Conserving Surgery

Pathology	Chest Wall Perforator Flaps (30)	Therapeutic Mammoplasty (43)	CPF versus TM P Value	Level 1 Breast Conservation Surgery (114)
Median size	25 mm (10-63)	26 mm (15-90)	0.211	16 mm (3-50)
Grade 3 or high grade	2 pCR	4 pCR	0.624	10 pCR
ER +ve	15 (50%)	19 (44%)	0.589	39 (34%)
Her 2 +ve	22 (73%)	29 (67%)	0.613	79 (69%)
Node positive	3 (10%)	6 (14%)	0.564	11 (10%)
	11 (37%)	13 (30%)		15 (13%)

those having neoadjuvant chemotherapy, and final pathology. Patients undergoing TM are expected to have bigger breasts and higher BMI, and this was the case in our study as well. Both the procedures had very few complications needing intervention. One patient with TM returned to the operating room for a hematoma evacuation. One patient with CPF had localized hematoma of the donor site, which was managed conservatively with negative pressure dressing. A multicentre audit of perforator flap reconstruction has reported a complication rate of 7.1%, and most of the complications were managed conservatively.¹¹ In a study of 40 partial breast reconstructions, five patients (13%) were reported as needing additional treatment for complications (three had fat necrosis, two had venous congestion).¹²

In the present series, a combination of LTAP with LICAP was commonly used. In a series reported by McCulley et al on LTAP flap partial breast reconstruction, 19 of 31 (61%) were performed as a combination with LICAP, and overall, it represented 44% of flaps.¹³

Although there are a number of studies reporting the use of AICAP in partial breast reconstruction,^{14,15} in the present study only three patients had AICAP. In our series, these procedures were mostly limited to patients with medially placed tumors in small breasts with very little ptosis. The incision is often visible when looking from the front, and in addition, trying to raise the inframammary fold sometimes may result in unpleasant scars. One patient had to undergo additional fat grafting.

Donor site morbidity is unique to CPF when compared with TM. In the past, latissimus dorsi flaps have been used for partial breast reconstruction.¹⁶ In both lateral CPF and latissimus dorsi flaps, scars are well concealed postoperatively on the frontal view. However, latissimus dorsi flaps have been reported to have increased donor site morbidities.¹⁷ In our study, three patients with perforator flaps complained of pain at the donor site at 3 months; two of them settled spontaneously with time, and one needed to be referred to the pain team. Similarly, studies from other centers have not reported many donor site problems in the short and medium term.^{11,18}

In our hospital, patients undergoing therapeutic mammoplasty were not offered contralateral symmetrization at the time of cancer surgery. It is our practice to wait for at least 6 months after radiotherapy before we offer contralateral symmetrization procedure. In this series, 11 of 43 (26%) patients had symmetrization as a delayed procedure. The delay in symmetrization may have an impact on quality of life and would warrant further evaluation. In a multicentre prospective cohort study on therapeutic mammoplasty, only one-third of the total 880 patients were offered simultaneous symmetrization procedure at the time of cancer surgery.¹⁹ In a study by Clough et al, of the 175 patients undergoing therapeutic mammoplasty, symmetrization procedure was offered to patients having large excisions in the immediate setting.²⁰ Overall, 47 patients (27%) had symmetrization, 34 in the immediate

Table 3. Short-term Outcome of Patients Having Breast Conservation Surgery

Short-term Outcome	Chest Wall Perforator Flaps (30) Median Follow-up 22 M (1-49)	Therapeutic Mammoplasty (43) Median Follow-up 25 M (2-50)	CPF versus TM P Value	Level 1 Breast Conservation Surgery (114) Median Follow-up 24 (1-50)
Complications needing intervention	Fat grafting 1 (3%)	Hematoma 1 (2%)	0.795	Hematomas 2 (2%)
Re-excision versus mastectomy	5 versus 0 (17%)	1 versus 3 (9%)	0.346	11 versus 1 (11%)
Locoregional recurrence	0	0		1 (1%)
Distant metastasis	3 (10%)	4 (9%)	0.920	2 (2%)

setting. Of those patients who did not have immediate symmetrization, 13 had symmetrization as delayed procedure (9.2%).

To avoid re-excision, in our unit we try to achieve a clear margin of 1mm on final histology. Of the 30 patients undergoing perforator flap reconstruction, five (17%) needed re-excision, but none had residual tumor at re-excision, and none needed mastectomy. In contrast, only four of 43 patients (9%) needed further surgery in the TM group but three needed mastectomies. Multicentre audit on perforator flaps by Soumian et al showed a re-excision rate of 13% and mastectomy rate of less than 1%.¹¹ Like in our series, all patients having re-excision had the procedure soon after the primary surgery and there was no delay in adjuvant treatment.

Previous studies have reported on oncological safety of perforator flaps with short- and medium-term follow-ups.^{11,18} In our study, there was no evidence of local recurrence in both CPF and TM groups after a medium-term follow-up of 22 and 25 months, respectively. A study by Soumian et al reported one local recurrence in 112 patients after a median follow-up of 15 months.¹¹ Another study by Ho et al reported one regional recurrence in 30 patients after a median follow-up of 48.5 months.¹⁸

In our series, three patients (10%) receiving CPF and four patients (9%) receiving TM had distant metastasis. This is higher than when compared with patients who received level 1 breast conservation surgery (2%). Patients having CPF and TM had larger symptomatic cancers compared with those having level 1 breast conservation surgery. In the study reported by Soumian et al, only 1% of patients having CPF had distant metastasis; however, their follow-up was relatively short (15 months).¹¹

LIMITATIONS

This article comparing the complications and oncological safety of CPF and TM is relatively small with a medium-term follow-up. Although both the procedures can be used to deal with tumors involving any of the quadrants of the breast, one may be more suitable than the other based on patient characteristics and tumor position. Since the indications may differ between the procedures to some extent, one may argue that this is a true like-for-like comparison. Nevertheless, these two procedures are indicated in patients with high tumor-to-breast volume ratio, and it is important to know the complication rate and oncological outcome between the two procedures. It is also important to compare the aesthetic outcomes and patient-related outcomes between the two procedures, and this has not been addressed in this article.

In conclusion, surgical and oncological outcomes of CPF with partial breast reconstruction are comparable to TM in the medium term. High-quality studies with long-term follow-ups are required to confirm its oncological safety.

John Mathew, MS, FRCS, DM, FRCS (Surgery)

Peterborough City Hospital
North West Anglia NHS Foundation Trust
Edith Cavell Campus, Bretton Gate
Peterborough, PE3 9GZ
UK

Email: john.mathew4@nhs.net

REFERENCES

- Clough KB, Kaufman GJ, Nos C, et al. Improving breast cancer surgery: a classification and quadrant per quadrant atlas for oncoplastic surgery. *Ann Surg Oncol*. 2010;17:1375–1391.
- Macmillan RD, James R, Gale KL, et al. Therapeutic mammoplasty. *J Surg Oncol*. 2014;110:90–95.
- Bulstrode NW, Shrotria S. Prediction of cosmetic outcome following conservative breast surgery using breast volume measurements. *Breast*. 2001;10:124–126.
- Berrino P, Campora E, Santi P. Postquadrantectomy breast deformities: classification and techniques of surgical correction. *Plast Reconstr Surg*. 1987;79:567–572.
- Clough KB, Soussaline M, Campana F, et al. [Mammoplasty combined with irradiation: conservative treatment of breast cancer localized in the lower quadrant]. *Ann Chir Plast Esthet*. 1990;35:117–122.
- Regnault P. Breast ptosis. Definition and treatment. *Clin Plast Surg*. 1976;3:193–203.
- Gandhi A, Coles C, Makris A, et al. Axillary surgery following neoadjuvant chemotherapy - multidisciplinary guidance from the Association of Breast Surgery, Faculty of Clinical Oncology of the Royal College of Radiologists, UK Breast Cancer Group, National Coordinating Committee for Breast Pathology and British Society of Breast Radiology. *Clin Oncol (R Coll Radiol)*. 2019;31:664–668.
- Mathew J, Courtney CA, Robertson JFR. Surgical management of the breast cancer after preoperative systemic treatment. In: Toi M, Winer E, Benson J, Klimberg S, eds. *Personalized Treatment of Breast Cancer*. 1st ed. Japan: Springer; 2016:263–293.
- Hamdi M, Van Landuyt K, de Frene B, et al. The versatility of the inter-costal artery perforator (ICAP) flaps. *J Plast Reconstr Aesthet Surg*. 2006;59:644–652.
- Hamdi M, De Frene B. Pedicled perforator flaps in breast reconstruction. *Semin Plast Surg*. 2006;20:73–78.
- Soumian S, Parmeshwar R, Chandarana M, et al. Chest wall perforator flaps for partial breast reconstruction: Surgical outcomes from a multicenter study. *Arch Plast Surg*. 2020;47:153–159.
- Kim JB, Eom JR, Lee JW, et al. Utility of two surgical techniques using a lateral intercostal artery perforator flap after breast-conserving surgery: a single center retrospective study. *Plast Reconstr Surg*. 2019;143:477–487.
- McCulley SJ, Schaverien MV, Tan VK, et al. Lateral thoracic artery perforator (LTAP) flap in partial breast reconstruction. *J Plast Reconstr Aesthet Surg*. 2015;68:686–691.
- Carstensen L, Biggaard J. Management of central breast tumours with immediate reconstruction of the nipple-areola complex; a suggested guide. *Breast*. 2015;24:38–45.
- Tenna S, Brunetti B, Morelli Coppola M, et al. The anterior intercostal artery perforator flap: clinical applications in partial breast reconstruction. *Plast Reconstr Surg*. 2017;140:746e–747e.
- Rusby JE, Paramanathan N, Laws SA, et al. Immediate latissimus dorsi mini-flap volume replacement for partial mastectomy: use of intra-operative frozen sections to confirm negative margins. *Am J Surg*. 2008;196:512–518.
- Smith SL. Functional morbidity following latissimus dorsi flap breast reconstruction. *J Adv Pract Oncol*. 2014;5:181–187.
- Ho W, Stallard S, Doughty J, et al. Oncological outcomes and complications after volume replacement oncoplastic breast conservations-the Glasgow experience. *Breast Cancer (Auckl)*. 2016;10:223–228.
- O'Connell RL, Baker E, Trickey A, et al; TeaM Steering Group; Mammary Fold Academic and Research Collaborative. Current practice and short-term outcomes of therapeutic mammoplasty in the international TeaM multicentre prospective cohort study. *Br J Surg*. 2018;105:1778–1792.
- Clough KB, Ihrai T, Oden S, et al. Oncoplastic surgery for breast cancer based on tumour location and a quadrant-per-quadrant atlas. *Br J Surg*. 2012;99:1389–1395.