



Original Article

## Neuroglial heterotopia of the middle ear: A case series and systematic literature review

Jared T Ahrends<sup>1</sup>, Justin M. Moore<sup>2</sup>, Hemant Varma<sup>1\*</sup>

Departments of <sup>1</sup>Pathology, <sup>2</sup>Surgery, Beth Israel Deaconess Medical Center, Harvard Medical School Boston, Massachusetts, United States.

E-mail: Jared T Ahrends - jahrends@bidmc.harvard.edu; Justin M. Moore - jmoore4@bidmc.harvard.edu; Hemant Varma - hvarma@bidmc.harvard.edu

**\*Corresponding author:**

Hemant Varma,  
Department of Pathology  
Beth Israel Deaconess Medical  
Center, Harvard Medical School  
Boston, Massachusetts,  
United States

[hvarma@bidmc.harvard.edu](mailto:hvarma@bidmc.harvard.edu)

Received : 14 December 2020

Accepted : 05 January 2021

Published : 17 February 2021

**DOI**

10.25259/SNI\_904\_2020

**Quick Response Code:**



### ABSTRACT

**Background:** The differential diagnosis for mass forming lesions of the middle ear is broad. While uncommon, neuroglial heterotopias can occur in the middle ear and can be a source of diagnostic confusion for clinician, radiologist, and pathologist alike.

**Methods:** We identified three cases of neuroglial heterotopia of the middle ear in our institutional archives from 2000 to 2020 and performed extensive histological and immunohistochemical characterization of the three lesions. We conducted a systematic literature review to identify 27 cases published in the English literature between the years 1980 and 2020. Only cases with histological verification of neuroglial heterotopia specifically involving the middle ear were included. We compiled the clinical, radiological, and histopathological findings for all 30 cases.

**Results:** Patients most frequently presented with chronic otitis media (40%), hearing loss (40%), or prior history of ear surgery or trauma (13%). The median age at surgery was 49 years with a male predominance (M:F 2:1); however, a bimodal age distribution was noted with an earlier onset (11 years or younger) in a subset of patients. Immunohistochemical characterization showed mature neuronal and reactive glial populations with low Ki67 proliferation index and chronic inflammatory infiltrates. There was no neuronal dysplasia or glial atypia, consistent with benign, nonneoplastic, mature glioneuronal tissue.

**Conclusion:** Immunohistochemical characterization of these lesions and clinical follow-up confirms their benign natural history. Potential etiologies include developmental misplacement, trauma, and chronic inflammation/reactive changes resulting in sequestered encephalocele.

**Keywords:** Heterotopia, Middle ear, Neuro-otology, Skull base

### INTRODUCTION

Extracranial neuroglial heterotopias are infrequent lesions that present as masses and can be a source of diagnostic confusion for the surgeon, radiologist, and pathologist, and need to be distinguished from neoplasms to avoid unnecessary overtreatment. These lesions most commonly occur in midline structures of the head and neck, particularly the nasal cavity.<sup>[22]</sup> Rare cases have been reported in the nasopharynx,<sup>[2]</sup> oropharynx,<sup>[6]</sup> hard palate,<sup>[3]</sup> oral cavity,<sup>[1]</sup> tongue,<sup>[7]</sup> and scalp.<sup>[8]</sup> Midline neuroglial heterotopias are also observed in children with congenital facial defects.

Neuroglial heterotopias in nonmidline structures, such as the middle ear, are rare with only cases reports and two limited case series published in the literature.<sup>[9,12,15-17,19,20,23-29]</sup> Isolated neuroglial

This is an open-access article distributed under the terms of the Creative Commons Attribution-Non Commercial-Share Alike 4.0 License, which allows others to remix, tweak, and build upon the work non-commercially, as long as the author is credited and the new creations are licensed under the identical terms.

©2020 Published by Scientific Scholar on behalf of Surgical Neurology International

tissue in the middle ear without a connection to the central nervous system (CNS) is associated with prior surgeries in the ear and mastoid region, prior ear trauma, or known congenital craniofacial anomalies.<sup>[12,20,25]</sup> These lesions are particularly rare in patients without a prior history of surgery, trauma, or congenital anomaly.

The histopathological features of these lesions have been described in very few cases and are limited in overall scope and completeness.<sup>[9,12,15-17,19,20,23-29]</sup> Here, we describe middle ear neuroglial heterotopias in three patients and provide the most comprehensive histological and immunohistochemical characterization to date. In addition, we performed a thorough and systematic review of all published reports of middle ear neuroglial heterotopias according to the Preferred Reporting Items for Systematic Reviews and Meta-Analyses (PRISMA) guidelines<sup>[21]</sup> and summarize the clinical, radiological, and histopathological findings. Features that confirm the nonneoplastic nature of these lesions include a low proliferation index, absence of dysplastic neurons or atypical glial cells, and associated chronic inflammatory/reactive changes. Finally, we discuss potential etiologies for the heterotopic brain tissue in the middle ear including a developmental, traumatic, or chronic inflammatory causes.

## MATERIALS AND METHODS

This study was approved under Institutional Review Board (IRB) protocol number 2016-p-000316, which includes waived requirement for patient consent on archived pathology tissue.

We identified three cases of neuroglial heterotopia of the middle ear in our institutional archives from 2000 to 2020. Clinical records were abstracted for demographic information, presenting symptoms, prior surgical history, diagnostic imaging, and clinical follow-up. Surgical specimens were processed by formalin fixation and paraffin embedding and stained with hematoxylin and eosin (H and E). All antibodies used in this study (GFAP, Olig2, synaptophysin, NeuN, CD34, and Ki67) were obtained from Dako (Agilent Pathology Solutions, Santa Clara, CA). Immunohistochemistry staining was performed on a Dako Autostainer Link48 (Agilent Pathology Solutions, Santa Clara, CA), according to our institution's standard operating procedure.

A literature review was performed by searching the PubMed from years 1980 to 2020 according to PRISMA guidelines. Globally, our study included human patients of any age reported in the English literature published after 1980 to cover all reports in the era of modern imaging. The MEDLINE database was searched with the PubMed search engine with the following Boolean phrase: (“neuroglial” OR “brain” OR “neural” OR “glial”) AND (“heterotopia” OR “heterotopic” OR “ectopia” OR “ectopic” OR “choristoma” OR “sequestered

encephalocele”) AND “middle ear.” After applying an English language filter, the search returned 21 results. First, article titles and abstracts were screened for applicability and availability and suitable abstracts were reviewed in detail. Then, a detailed review of the full article was performed for applicability. This review resulted in selection of 14 articles outlining 27 separate cases of neuroglial heterotopia of the middle ear. A symptom or finding was deemed present if mentioned in the article at least once and deemed absent or not present if not mentioned. Data were tabulated.

## RESULTS

### Clinical history

#### Case 1

A 49-year-old male who presented with recurrent chronic otitis media and bilateral conductive hearing loss. He previously had Eustachian tubes placed many years prior. The patient had no history of congenital anomalies. Computed topography (CT) scans demonstrated opacification of the mastoids suggesting bilateral mastoiditis, as well as a soft-tissue mass within the right epitympanum [Figure 1a]. There was no radiological evidence for cranial base bony defect. The right ear was examined with an operative microscope and dissection of the mastoid revealed green mucoid material and areas of thin bone. Dissection toward the epitympanum revealed a smooth yellow cystic mass, which was removed and sent for pathologic examination. The operation was completed without complications.

#### Case 2

A 49-year-old male who presented with chronic left-sided otitis media and the sensation of left ear fullness. Eustachian tube placement relieved the pressure temporarily; however, symptoms recurred after 2 years. The patient had no history of congenital anomalies, prior trauma, or other surgical procedures in the area. Head CT was significant for a soft-tissue mass in the middle ear with a small equivocal defect in the tegmen tympani [Figure 1b] without any connection between the middle ear mass and the brain. The patient underwent craniotomy for removal of middle ear mass and reconstruction of possible skull base defect. A 2 mm defect in the antrum of the middle ear was identified and a soft-tissue mass was removed from the middle ear cavity and sent for histological examination. Cerebrospinal fluid (CSF) leak was not observed during the procedure. The tegmen defect was then repaired and the operation was completed without complication.

#### Case 3

A 48-year-old woman who presented with progressive bilateral decrease in hearing over 2 years with occasional

tinnitus and right ear fullness. An audiogram revealed mild-to-moderate conductive hearing loss in the right ear. Prior history was notable for chronic otitis media as a child but no history of congenital anomalies, prior surgery, or local trauma. Examination revealed a bulging but intact right tympanic membrane. Head CT revealed complete opacification of the right middle ear cavity with possible though not definitive dehiscence of the tegmen tympani [Figure 1c]. Magnetic resonance imaging did not reveal definitive encephalocele. Mastoidectomy was performed and a pink-red soft-tissue mass was removed from the right middle ear. Neither a skull base defect nor CSF leak was detected during the procedure. The operation was completed without complication and the specimen was sent for histological examination.

Clinical follow-up data were limited in Cases 1 and 2, with no recurrence or complications at 1.5 and 1 month following surgery, respectively. These patients were subsequently lost to follow up. The patient in case 3 experienced no recurrence of symptoms or relapse 4 years after surgery.

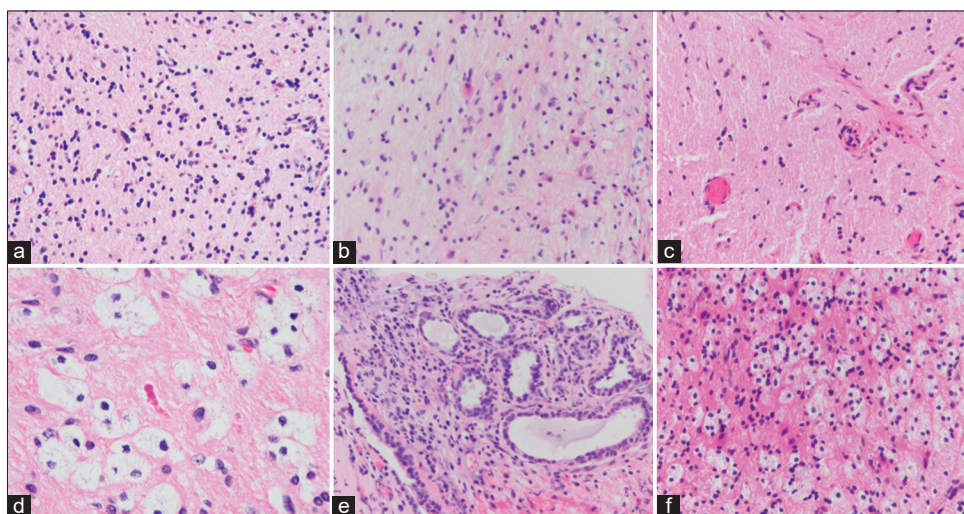
## Histopathology

Gross examination of the resected masses revealed variably colored fragments of soft tissue that were tan-pink in Case 1 (up to 0.6 cm), yellow-pink in Case 2 (0.4 cm), and pink-red in Case 3 (0.5 cm). All three cases had similar histological findings and revealed mildly hypercellular mature neuroglial tissue with reactive astrogliosis [Figure 2]. All specimens displayed scattered mature neurons in a background of neuropil. Occasional Rosenthal fibers were seen in Case 1 [Figure 2d]. Benign glandular epithelium was observed along the edge of the lesion in Case 2, consistent with middle ear mucosa [Figure 2e]. Prominent mononuclear inflammatory cells with vacuolated cytoplasm were seen in Cases 1 and 3 [Figures 2d and f]. Neither choroid plexus nor ependymal cells were present in any case. No cytologic atypia, dysplastic neurons, necrosis, microvascular proliferation, or mitotic figures were observed in any case.

The lesions were further characterized by immunohistochemistry to assess the neuroglial origin of



**Figure 1:** Computed tomography scans demonstrating soft-tissue mass in the middle ear from Case 1 (a), Case 2 (b), and Case 3 (c).



**Figure 2:** Histological features of neuroglial heterotopia (H and E). Mature neuroglial tissue with reactive gliosis in background neuropil was apparent in Case 1 (a), Case 2 (b), and Case 3 (c). Rosenthal fibers were apparent in Case 1 (d) and prominent macrophage infiltration was seen in Case 1 (d) and Case 3 (f). Glandular middle ear mucosa was present along the edge of Case 2 (e). Images a-c, e and f at  $\times 200$ . Image d at  $\times 400$ .

the tissue and to exclude neoplasm. All three cases were diffusely positive for GFAP, which also highlighted reactive gemistocytic astrocytes [Figure 3a]. Small Olig2-positive oligodendrocytes were present in all cases [Figure 3b]. The lesions contained mature neural elements, including large NeuN-positive neurons in a synaptophysin-positive neuropil background [Figure 3c and d] respectively. CD34 immunostain highlighted only small caliber blood vessels, with no aberrant staining in neurons [Figure 3e]. Numerous CD68-positive macrophages and microglia were observed, with focal areas of perivascular cuffing in Case 1 [Figure 3f]. The Ki67 proliferation index was low in all cases, estimated to label <1% of cells (data not shown). Together, the clinical and histological findings in all three cases were consistent with benign neuroglial tissue.

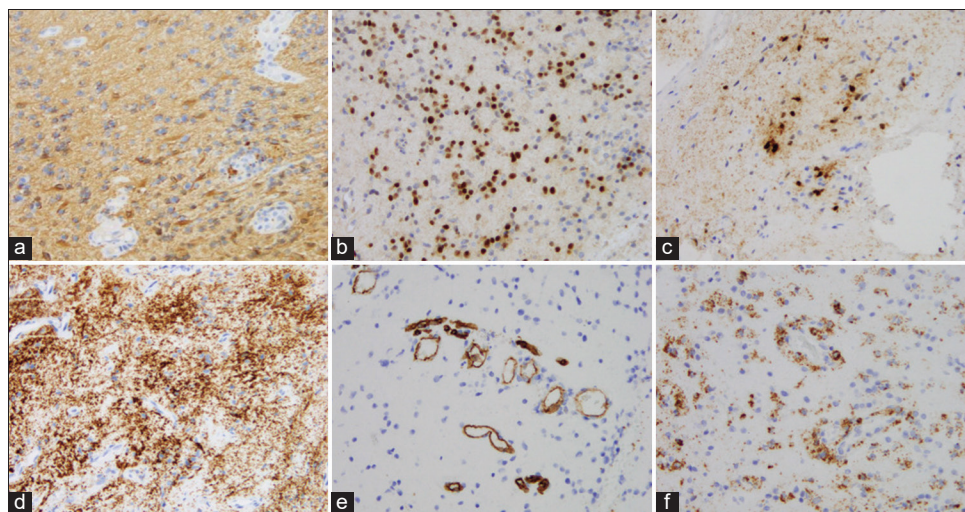
### Literature review

We exhaustively reviewed the literature from 1980 to 2020 according to the PRISMA guidelines<sup>[21]</sup> and identified 27 cases of histologically confirmed middle ear neuroglial heterotopia, which were combined with the three cases described above, for a total of 30 cases [Table 1].<sup>[9,12,15-17,19,20,23-29]</sup> There were also cases of neuroglial heterotopia limited to the inner auditory canal or confined to the mastoid region without involvement of the middle ear, which were not included here.<sup>[10,12]</sup> The median patient age at diagnosis was 49 years (range 3–81 years), with five pediatric patients (<18 years age). There was a male predominance, with a male-to-female ratio of 2:1. The most common symptoms leading to clinical presentation were chronic otitis media (12/30 cases, 40%) and hearing loss (12/30 cases, 40%). A history of prior ear surgery or

trauma was noted in 4 of 30 cases (13%). CT was the most common imaging modality used to identify these lesions and bony erosion or dehiscence was either suggested or identified in 23% (7/30) of cases. Imaging characteristics were not reported in 40% (12/30) of cases. All cases showed mature neuroglial tissue on H and E stained sections with 80% (24/30) reporting some degree of chronic inflammatory infiltrates or reactive astrogliosis. GFAP and S100 were the most commonly used immunostains to identify the glial component, reported as positive in 27 (90%) and 17 (56%) cases, respectively. Neurofilament was the most common neuronal marker reported (14/30 cases, 47%). None of the prior cases reported Ki67 proliferation index, which was <1% in all three of our cases.

### DISCUSSION

Here, we provide a comprehensive clinical, radiological, and histopathological characterization of neuroglial heterotopias of the middle ear. Our results extend findings of prior reports, including age at diagnosis, presenting symptoms, and radiological findings [Table 1]. The majority of prior descriptions are limited to single case reports and even in the only two published case series,<sup>[12,20]</sup> clinical and histological data are scant or unavailable. In our three patients, all had a history of chronic otitis media, and none had prior history of middle ear surgery, trauma, or congenital craniofacial anomaly. Histopathological examination showed mature glial and neuronal elements in all cases. Variable mononuclear inflammatory infiltrates, including CD68-positive macrophages and microglia, were present in all three of our cases. Similarly, chronic inflammatory infiltrates were specifically described in 16 of 27 (59%) of prior cases. There



**Figure 3:** Immunohistochemical analysis of neuroglial tissue from the middle ear. (a) GFAP and (b) Olig2 highlight astrocytes and oligodendrocytes, respectively, without atypia. (c) NeuN demonstrates the presence of mature-appearing differentiated neurons. (d) Synaptophysin highlights the background neuropil. (e) CD34 highlights background blood vessels without aberrant neuronal expression. (f) Numerous CD68-positive macrophages/microglia are present. All images at  $\times 200$ .

**Table 1:** Review of prior middle ear neuroglial heterotopias.

Reference	Number of cases	Age/sex	Prior history	Imaging	Histological findings
Gulya <i>et al.</i> , 1987 <sup>[17]</sup>	1	8 F	Progressive unilateral hearing loss	CT: middle ear mass without bony erosion	H and E: CNS gray and white matter with overlying middle ear mucosa and focal choroid plexus. IHC: not performed
Slater <i>et al.</i> , 1988 <sup>[27]</sup>	1	7 M	Aural problems	CT: no evidence of skull defect	H and E: gemistocytic astrocytes and inflammatory cells. IHC: GFAP
Klein <i>et al.</i> , 1989 <sup>[15]</sup>	1	4 M	Chronic otitis media	CT: soft-tissue density in the mesotympanum without erosion of overlying bone Not reported.	H and E: small fragments of brain tissue with minimal gliosis and rare gemistocytic astrocytes IHC: not performed
McGregor <i>et al.</i> , 1994 <sup>[20]</sup>	3	3 M 36 M 65 M	Case 1: recurrent meningismus Case 2: chronic otitis media and prior mastoidectomy Case 3: chronic otitis media and prior ear surgery		H and E: mature CNS tissue with reactive gliosis and mature neurons, focally lined by cuboidal epithelium IHC: GFAP
Gyure <i>et al.</i> , 2000 <sup>[12]</sup>	11	29–67 M:F 4:7	Chronic otitis media/mastoiditis in 5 cases Hearing loss in 1 case. Prior ear surgery in 1 case Prior ear trauma in 1 case Unknown history in 4 cases	No bone erosion on radiograph for 2 cases Imaging not reported for 9 cases	H and E: varying proportions of neurons and glia with reactive astrogliosis and inflammatory cells consisting of lymphocytes and macrophages. Cuboidal epithelium was present in nine cases IHC: S-100, GFAP, neurofilament
Plontke <i>et al.</i> , 2000 <sup>[23]</sup>	1	11 M	Bilateral hearing loss	CT: band-shaped mass in meso- and hypo-tympanum	H and E: glial tissue in background neuropil with chronic inflammation IHC: S-100
Lee <i>et al.</i> , 2004 <sup>[16]</sup>	1	50 M	Progressive unilateral hearing loss	CT: mass-like lesion with soft-tissue density in middle ear cavity. Possible bony erosion of overlying tegmen tympani	H and E: mature disorganized glial tissue in a loose fibrillary background IHC: S-100, GFAP
Waldman <i>et al.</i> , 2005 <sup>[29]</sup>	1	3 M	Abnormal right eardrum	CT: soft tissue in the middle ear and epitympanum without bony dehiscence	H and E: fibrillary stroma with glial-type cells and fibrovascular tissue with cuboidal epithelium IHC: GFAP, synaptophysin, cytokeratin, Melan-A
Uğuz <i>et al.</i> , 2006 <sup>[28]</sup>	1	61 M	Unilateral hearing loss and tinnitus	CT: mass-like lesion of soft tissue density in middle ear cavity. Areas of bony erosion in epitympanic space	H and E: mature neuroglial tissue in a fibrovascular stroma IHC: S-100, GFAP

(Contd...)

**Table 1:** (Continued).

Reference	Number of cases	Age/sex	Prior history	Imaging	Histological findings
Farneti <i>et al.</i> , 2007 <sup>[19]</sup>	1	74 M	Recurrent otitis media	CT: soft mass within the epitympanum. Tegmen tympani not involved	H and E: glial tissue with nodules of neuronal cells IHC: GFAP, NeuN, cytokeratin MNF116
Martinez-Peñuela <i>et al.</i> , 2011 <sup>[19]</sup>	2	61 M	Case 1: unilateral hearing loss Case 2: unilateral hypoacusia and tinnitus	CT: opacified middle ear with soft-tissue mass filling the antrum and attic CT: dehiscence of tegmen tympani related to soft-tissue mass in the attic	H and E: mature glial tissue, scattered neuronal nuclei, and chronic inflammation in a fibrillary background IHC: S-100, GFAP, neurofilament
Shemanski <i>et al.</i> , 2013 <sup>[25]</sup>	1	81 M	Chronic otitis media and hearing loss	CT: middle ear soft-tissue mass with possible erosion of the attic	H and E: mature, disorganized glial-like tissue on a loosely fibrillary background IHC: GFAP, S-100, cytokeratin, MAP
Shim <i>et al.</i> , 2016 <sup>[26]</sup>	1	63 F	Unilateral hearing loss	CT: soft-tissue density in middle ear with possible erosion of tegmen tympani	H and E: scattered mononuclear cells in a fibrillary background IHC: GFAP
Quatre <i>et al.</i> , 2020 <sup>[24]</sup>	1	63 M	Unilateral hearing loss and tinnitus	CT: fluid and mucus in the mastoid and right tympanum; no associated bony changes	H and E: glial tissue with chronic and subacute inflammatory changes IHC: GFAP
Ahrendsen <i>et al.</i> , 2020	3	48 F 48 M 49 M	Case 1: chronic otitis media and progressive hearing loss Case 2: chronic otitis media Case 3: progressive hearing loss	CT: soft-tissue mass in the middle ear of all three cases. Two cases with possible tegmen tympani dehiscence	H and E: neuroglial tissue with reactive gliosis, mature neurons, and chronic inflammation IHC: GFAP, Olig2, NeuN, synaptophysin, CD34, CD68, Ki67

CT: Computed tomography; H and E: Hematoxylin and eosin; IHC: Immunohistochemistry (positive staining), CNS: Central nervous system.

were no dysplastic neuronal elements, cytologic atypia, or mitotic figures in the three cases described here. The Ki67 proliferation index was <1% in all lesions, likely representing inflammatory cells within the lesions and arguing against a neoplastic proliferation. To the best of our knowledge, there is no report of malignant transformation of a neuroglial heterotopia in the head and neck or any other extracranial site. However, in cases with concerning clinical and/or histological features, additional analyses can be performed to evaluate for possible glial malignancy, including immunohistochemistry for IDH1 R132H, P53, and ATRX. Similarly, cytogenetic and molecular studies on resected tissue can be performed to identify genetic signatures of glial neoplasms.<sup>[18]</sup>

The origin of neuroglial heterotopia in the middle ear is uncertain with multiple potential explanations, including aberrant development, trauma, and/or chronic infection/inflammation of the middle ear cavity.<sup>[13,23]</sup> The association with congenital facial abnormalities suggests that at least in some cases, aberrant development may play a role in patients presenting earlier in life. The middle ear cavity develops from the first two pharyngeal arches and the first pharyngeal pouch, while the bones in the middle ear and anterior portions of the skull are derived from neural crest derivatives. Neuroectodermal tissue is not normally found in these structures due to physical separation between the developing neural tube and the pharyngeal arches/pouches.<sup>[4]</sup> However, it is possible that a failure of anterior neuropore

closure during the 4<sup>th</sup> week of gestation may lead to persistent neuroectoderm attached to surface endoderm and result in misplaced neuroglial tissue within the middle ear. However, there are several patients with a prior history of middle ear surgery, where heterotopias were only detected on subsequent surgeries, thereby arguing against a developmental origin, at least for these cases, since these likely would have been detected during the initial surgery.<sup>[12,20]</sup> Thus, developmental neuroglial misplacement is unlikely to explain all cases.

An alternative explanation is that a temporary bony defect in the skull base leads to encephalocele formation with sequestration of the herniated brain tissue after subsequent closure of the healed defect. The tegmen tympani is a thin bone that separates the middle ear cavity from the cranial cavity. Repeated bouts of inflammation, infection, and/or trauma to this area of bone could create a temporary breach, resulting in encephalocele formation. Once the inflammation resolves, healing and fibrosis may sequester and isolate neuroglial tissue within the middle ear without radiologic or clinical evidence of connection to the CNS. Given the thin separation between the intracranial space and the middle ear by the tegmen tympani, combined with a propensity toward middle ear infection/inflammation in the patients presented here, this pathological mechanism seems plausible, especially in patients with a prior history of infections or trauma.

The correct diagnosis of middle ear neuroglial heterotopias has important clinical implications. Presenting symptoms are generally vague and nonspecific. However, once a mass is identified (typically by imaging studies), the differential diagnosis of isolated mass lesions of the middle ear is broad and includes cholesteatoma, adenoma, paraganglioma, teratoma, meningioma, retrotympenic vascular tumor, endolymphatic sac tumor, neuroma, schwannoma, and carcinoma. When heterotopic tissue is encountered in the middle ear, it is most commonly composed of salivary gland tissue.<sup>[5]</sup> Neuroglial tissue in the middle ear, although rare, should prompt a careful search for continuity with the CNS. If such a defect is identified, closure of the defect and prophylactic antibiotics should be considered to prevent meningitis and other serious complications.<sup>[11,14]</sup> Furthermore, based on the results presented here, neuroglial heterotopia of the middle ear is a benign, nonneoplastic process that is curable with surgery alone, so misclassification as a neoplasm could result in unnecessary treatment and associated morbidity.

## CONCLUSION

We present the clinical, radiological, and detailed histopathological characteristics of neuroglial heterotopia in the middle ear. Immunohistochemical characterization and a low Ki67 proliferation index of these lesions confirm their benign natural history. The reactive inflammatory changes

and history of prior surgery/trauma or chronic infection/inflammation suggest potential etiologies for these lesions. Heterotopic neuroglial tissue should be on the differential for mass lesions of the middle ear and correctly recognized as a benign, nonneoplastic lesion with favorable long-term outcome after surgery.

## Declaration of patient consent

Institutional Review Board permission obtained for the study.

## Financial support and sponsorship

Nil.

## Conflicts of interest

There are no conflicts of interest.

## REFERENCES

1. Aanaes K, Hasselby JP, Bilde A, Therkildsen MH, von Buchwald C. Heterotopic neuroglial tissue: Two cases involving the tongue and the buccal region. *Oral Surg Oral Med Oral Pathol Oral Radiol Endod* 2008;105:e22-9.
2. Al-Ammar AY, Noumas HS, Alqahtani M. A midline nasopharyngeal heterotopic neuroglial tissue. *J Laryngol Otol* 2006;120:e25.
3. Anjaneyulu C, Deka RC. Heterotopic neuroglial tissue in hard palate. *Indian J Pediatr* 2004;71:451-2.
4. Anthwal N, Thompson H. The development of the mammalian outer and middle ear. *J Anat* 2016;228:217-32.
5. Buckmiller LM, Brodie HA, Doyle KJ, Nemzek W. Choristoma of the middle ear: A component of a new syndrome? *Otol Neurotol* 2001;22:363-8.
6. Chen D, Dedhia K, Ozolek J, Mehta D. Case series of congenital heterotopic neuroglial tissue in the parapharyngeal space. *Int J Pediatr Otorhinolaryngol* 2016;86:77-81.
7. Corsi A, Veccia N, Riminucci M. Glial choristoma of the tongue. Clinicopathological analysis of a case and pathogenetic insights. *Pol J Pathol* 2017;68:162-7.
8. Drapkin AJ. Rudimentary cephalocele or neural crest remnant? *Neurosurgery* 1990;26:667-73; discussion 674.
9. Farneti P, Balbi M, Foschini MP. Neuroglial choristoma of the middle ear. *Acta Otorhinolaryngol Ital* 2007;27:94-7.
10. Francis HW, Nager GT, Holliday MJ, Long DM. Association of heterotopic neuroglial tissue with an arachnoid cyst in the internal auditory canal. *Skull Base Surg* 1995;5:37-49.
11. Glasscock ME, Dickins JR, Jackson CG, Wiet RJ, Feenstra L. Surgical management of brain tissue herniation into the middle ear and mastoid. *Laryngoscope* 1979;89:1743-54.
12. Gyure KA, Thompson LD, Morrison AL. A clinicopathological study of 15 patients with neuroglial heterotopias and encephaloceles of the middle ear and mastoid region. *Laryngoscope* 2000;110:1731-5.
13. Heffner DK. Brain in the middle ear or nasal cavity: Heterotopia

- or encephalocele? *Ann Diagn Pathol* 2004;8:252-7.
14. Kamerer DB, Caparosa RJ. Temporal bone encephalocele- Diagnosis and treatment. *Laryngoscope* 1982;92:878-82.
  15. Klein MV, Schwaighofer BW, Sobel DF, Fantozzi RD, Hesselink JR. Heterotopic brain in the middle ear: CT findings. *J Comput Assist Tomo* 1989;13:1058-60.
  16. Lee JI, Kim KK, Park YK, Eah KY, Kim JR. Glial choristoma in the middle ear and mastoid bone: A case report. *J Korean Med Sci* 2004;19:155-8.
  17. Levine PA, Gulya AJ, Glasscock ME, Pensak ML. Neural choristoma of the middle ear. *Otolaryngol Head Neck Surg* 1987;97:52-6.
  18. Louis DN, Perry A, Reifenberger G, von Deimling A, Figarella-Branger D, Cavenee WK, *et al.* The 2016 World Health Organization classification of tumors of the central nervous system: A summary. *Acta Neuropathol* 2016;131:803-20.
  19. Martinez-Peñuela A, Quer S, Belouqui R, Bulnes MD, Martinez-Peñuela JM. Glial choristoma of the middle ear: Report of 2 cases. *Otol Neurotol* 2011;32:e26-7.
  20. McGregor DH, Cherian R, Kepes JJ, Kepes M. Case reports: Heterotopic brain tissue of middle ear associated with cholesteatoma. *Am J Med Sci* 1994;308:180-3.
  21. Moher D, Liberati A, Tetzlaff J, Altman DG, PRISMA Group. Preferred reporting items for systematic reviews and meta-analyses: The PRISMA statement. *PLoS Med* 2009;6:e1000097.
  22. Penner CR, Thompson LD. Nasal glial heterotopia: A clinicopathologic and immunophenotypic analysis of 10 cases with a review of the literature. *Ann Diagn Pathol* 2003;7:354-9.
  23. Plontke SK, Preyer S, Pressler H, Munding PM, Plinkert PK. Glial lesion of the infratemporal fossa presenting as a soft tissue middle ear mass-rudimentary encephalocele or neural Wcrest remnant? *Int J Pediatr Otorhinolaryngol* 2000;56:141-7.
  24. Quatre R, Baguant A, Gil H, Schmerber S. Glial heterotopia of the middle ear. *Eur Ann Otorhinolaryngol Head Neck Dis* 2020;137:207-9.
  25. Shemanski KA, Voth SE, Patitucci LB, Ma Y, Popnikolov N, Katsetos CD, *et al.* Glial choristoma of the middle ear. *Ear Nose Throat J* 2013;92:555-7.
  26. Shim HJ, Kang YK, An YH, Hong YO. Neuroglial choristoma of the middle ear with massive tympanosclerosis: A case report and literature review. *J Audiol Otol* 2016;20:179-82.
  27. Slater DN, Timperley WR, Smith CM. Heterotopic middle ear gliomatosis. *Histopathology* 1988;12:230-1.
  28. Uğuz MZ, Arslanoğlu S, Terzi S, Etit D. Glial heterotopia of the middle ear. *J Laryngol Otol* 2007;121:e4.
  29. Waldman EH, DeSantis E, Lustig LR, Tunkel DE. Pathology quiz case. *Arch Otolaryngol Head Neck Surg* 2005;131:363.

**How to cite this article:** Ahrendsen JT, Moore JM, Varma H. Neuroglial heterotopia of the middle ear: A case series and systematic literature review. *Surg Neurol Int* 2021;12:60.