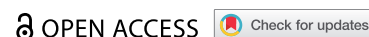

CASE REPORT



Post-partum occurrence of Wunderlich syndrome and microangiopathic haemolytic anaemia (MAHA): a case report

Neeraja Swaminathan , Ramy Sedhom , Anum Shahzad and Zurab Azmaiparashvili

Department of Internal Medicine, Albert Einstein Medical Center, Philadelphia, PA, USA

ABSTRACT

This is a case of a 27-year-old primigravida with monochorionic diamniotic twin gestation who was admitted to the hospital for induction of labour. Her postpartum course was complicated by microangiopathic haemolytic anemia (MAHA). The etiology for the MAHA was initially thought to be secondary to pre-eclampsia and vitamin B12/folate deficiency. However, she had persistent anemia and further workup demonstrated that she had a left renal cell carcinoma (RCC) with perinephric haemorrhage consistent with Wunderlich syndrome. This case was intriguing because of its unusual presentation and the several diagnostic and therapeutic challenges along the way.

Abbreviations: MAHA: microangiopathic haemolytic anaemia; RCC: renal cell carcinoma; BP: blood pressure; WS: Wunderlich syndrome; CT: computed tomography; LFTs: liver function tests; LDH: lactate dehydrogenase; HELLP: haemolysis elevated liver enzymes, low platelets; DIC: disseminated intravascular coagulation; PLASMIC: score for TTP – includes platelet count <30 x 10⁹/L, evidence of haemolysis (reticulocyte count >2.5%, haptoglobin undetectable, or indirect bilirubin >2mg/dL), active cancer, history of solid organ transplant, mean corpuscular volume (MCV) <90fL, INR <1.5, creatinine <2mg/dL. Each item is scored as being present (YES) or not (NO). Absence of active cancer and solid organ transplant gets scored with a point each. The total points are added up to categorize the severity and risk of TTP. Low risk <4, Intermediate 5, high risk >6; TTP: thrombotic thrombocytopenic purpura; APLA- anti-phospholipid antibody; BMI: body mass index; TMAs: thrombotic microangiopathies; HUS: haemolytic uremic syndrome; vWF: von Willebrand factor

ARTICLE HISTORY

Received 21 June 2020
Accepted 27 January 2021

KEYWORDS

Wunderlich syndrome; renal cell carcinoma (RCC); microangiopathic haemolytic anaemia (MAHA); post-partum

1. Background



Wunderlich syndrome (WS), initially described by Wunderlich in 1856, is a rare syndrome of spontaneous nontraumatic bleeding in the perinephric space which is subcapsular and retroperitoneal in location [1,2]. It is usually associated with the Lenk's triad which comprises acute flank pain, palpable flank mass and hypovolemic shock. All three of these features occur concomitantly in only about 20% of cases. Haematuria is also common but not always present [1–3]. Renal neoplasms specifically angiomyolipoma which is a benign neoplasm accounts for 60–65% cases of WS. Other aetiologies include renal cell carcinoma (RCC), vasculitis such as polyarteritis nodosa (PAN) pheochromocytoma and other retroperitoneal tumours [1,2,4]. Incidence of WS in pregnancy is extremely rare and there is no clear guidance on how to manage it and it often requires a collaborative approach of several specialists such as obstetricians, internists and urologists [5,6].

2. Case presentation

A 27-year-old pregnant patient presented to the hospital for induction of labour. She had a twin gestation

but her course during pregnancy was otherwise unremarkable. At 36 weeks, she was newly detected to have an elevated blood pressure. Hence, she was diagnosed with pre-eclampsia for which the definitive management is to deliver the fetus. This patient underwent a vacuum-assisted vaginal delivery. Labour was complicated by post-partum haemorrhage which was medically managed. She received packed red-cell transfusions and her haemoglobin stabilized.

Two days post-partum, she was noted to have an acute drop in haemoglobin and platelets accompanied by hypoxia, tachycardia. She was also noted to be lethargic but arousable and oriented to time, place and person. She underwent a CT for pulmonary embolism which was negative. She had no recurrence of vaginal bleeding and had no retained products of conception. Pelvic exam performed by the obstetrician did not show any abnormalities. She was afebrile and had no clinical focus of infection. However, she received 48 hours of empiric broad spectrum antibiotic coverage which was subsequently stopped as blood and urine cultures remained negative.

CONTACT Neeraja Swaminathan  neeraja1991@yahoo.co.in  Department of Internal Medicine, Albert Einstein Medical Center, 5501 Old York Road, Philadelphia, PA 19141, USA

© 2021 The Author(s). Published by Informa UK Limited, trading as Taylor & Francis Group on behalf of Greater Baltimore Medical Center. This is an Open Access article distributed under the terms of the Creative Commons Attribution-NonCommercial License (<http://creativecommons.org/licenses/by-nc/4.0/>), which permits unrestricted non-commercial use, distribution, and reproduction in any medium, provided the original work is properly cited.

Labs were notable for thrombocytopenia, significantly elevated lactate dehydrogenase (LDH), low haptoglobin (undetectable), with peripheral smear showing anisopoikilocytosis and schistocytes (1–2 in every high-power field), elevated creatinine. Her LFTs were completely normal which ruled out HELLP. Her coagulation parameters were normal which made the likelihood of this being disseminated intravascular coagulation (DIC) low. The patient had a high PLASMIC score of 6 concerning for microangiopathic haemolytic anaemia as a consequence of thrombotic thrombocytopenic purpura (TTP). ADAMTS13 enzyme, complement levels, antiphospholipid antibody (APLA) workup were sent and she underwent plasmapheresis and was initiated on IV steroids. She received a total of 3 sessions of plasmapheresis. Serial blood smears were checked and she had improvement in platelet count and fewer schistocytes.

However, ADAMTS level came back as normal, thereby ruling out TTP. APLA workup was also negative. Vitamin b12 level was low at 180 pg/mL (213–816 pg/mL) and folate level was low normal at 7.2 ng/mL (5.4 to 20 ng/mL). Additionally she had a history of pre-eclampsia as well. Both of these conditions can lead to haemolytic anaemia. Despite the plasma exchange, steroids and blood product support, only her platelet count improved whereas her haemoglobin continued to remain low.

Hence, she underwent abdominal imaging as part of the anaemia workup in this postpartum patient to look for evidence of occult blood loss. This showed a new heterogeneous hyperechoic left renal mass that measured 11 cm. CT done for better characterization showed that the mass was surrounded by a large perinephric/subcapsular hematoma with patent renal vasculature. The patient underwent an angiogram which did not demonstrate any active bleeding and selective embolization of the branch supplying the tumour was performed. She underwent a radical nephrectomy and the surgical pathology was reported as renal cell carcinoma (pT2bN0M0), histological grade 2 with negative margins. She underwent PET CT which showed no evidence of metastasis and it was deemed that he did not require any further adjuvant therapy. She was counselled to continue follow up for surveillance.

3. Discussion

The spontaneous subcapsular renal haemorrhage or Wunderlich syndrome is an uncommon initial presentation of renal cell carcinoma. It is more often due to a benign renal pathology. The management of Wunderlich syndrome could be either through an exploratory surgery or through an interventional

radiological guided approach to stop a bleeding vessel. At present, there are no clear guidelines that favours either approach. While early surgery is often not feasible if the patient is unstable delayed surgery post embolization can make resection difficult because of adherence [7].

Just as Wunderlich's syndrome is rare, the diagnosis of a urological cancer such as RCC during pregnancy is also uncommon. Some of the predisposing factors for RCC in pregnancy are elevated levels of estrogen and progesterone, polymorphism of the estrogen receptor gene, increment in body mass index (BMI) and increased risk of diabetes and hypertension. Given that the symptoms of RCC in pregnancy such as flank pain, hematuria, hypertension mimic other common pregnancy related disorders, the diagnosis of RCC can frequently be missed or delayed [8,9].

Thrombocytopenia develops in 5–10% of women during pregnancy and postpartum period. There are multiple reasons for thrombocytopenia in pregnancy ranging from benign due to hemodilution to more serious ones. There are several pregnancy-specific thrombotic microangiopathies (TMAs) as well such as pre-eclampsia and HELLP syndrome. Thrombotic thrombocytopenic purpura (TTP) and atypical haemolytic uremic syndrome (HUS) can also independently occur in pregnant women. Given the significant overlap and very subtle differences between the presentations of all these entities, it can be very difficult to distinguish between them at the outset. The decision on instituting a treatment modality whether that is plasmapheresis for antibody mediated TTP, plasma infusion for congenital TTP or complement inhibitor for atypical HUS, prompt delivery for pre-eclampsia/HELLP; boils down to clinical acumen. ADAMTS 13, Shiga toxin are part of the initial workup but often take a while to result and typically in practice, empiric plasmapheresis is initiated and stopped only after the levels come back as normal [10,11]. In this patient who developed postpartum haemolytic anaemia and thrombocytopenia, it was extremely challenging to ascertain the aetiology. She was initially being managed as a case of TTP. Given that she met several diagnostic criteria for TTP, high dose steroids and plasmapheresis were initiated. However, it was the persistence of anaemia despite transfusion support and plasmapheresis which prompted further workup with abdominal imaging. This eventually clinched the diagnosis since it showed the left renal mass with associated spontaneous perinephric haemorrhage. It is notable that this renal mass was not visualized in any of her antenatal scans.

After the discovery of the renal tumour, another differential that came up was the possibility of paraneoplastic microangiopathy. RCC is more commonly

associated with erythrocytosis and thrombocytosis. However, malignancy related TTP has been reported in several adenocarcinomas, most commonly of breast, lung, and stomach [12]. Although its exact pathophysiology is not known, most cases of malignancy related TMA have a normal ADAMTS 13 activity. Proposed mechanism for TMA in malignancy includes bone marrow involvement of metastatic cancer-causing secondary myelofibrosis and direct release of prothrombotic von Willebrand factor (vWF) multimers which promote coagulation. Another mechanism is that there is red cell fragmentation from direct contact of erythrocytes with tumour emboli. However, both these theories are more suitable in metastatic cancer [12,13].

This patient had localized disease and no distant spread noted on imaging. She also had a normal ADAMTS 13 level. Therefore, it appears that her thrombocytopenia was likely multifactorial in the setting of elevated blood pressure, vitamin b12 and folic acid deficiency and the presence of a renal mass.

4. Conclusion

This case report describes the presentation of Wunderlich syndrome which is a rare disease entity. Additionally, it highlights the differentials for MAHA, elucidates the need to repeatedly test our hypothesis without premature closure and demonstrates the complexity in discerning the aetiology when the differentials being considered have overlapping presentations. It also impresses the need for multidisciplinary approach in the management of patients.

Disclosure statement

No potential conflict of interest was reported by the authors.

ORCID

Neeraja Swaminathan  <http://orcid.org/0000-0002-9043-0420>

Ramy Sedhom  <http://orcid.org/0000-0002-9395-0851>

References

- [1] Kim JW, Kim JY, Ahn ST, et al. Spontaneous perirenal hemorrhage (Wunderlich syndrome): an analysis of 28 cases. *Am J Emerg Med* [Internet]. 2019;37(1):45–47. .
- [2] Simkins A, Maiti A, Cherian SV. Wunderlich Syndrome. *Am J Med* [Internet]. 2017;130(5):e217–8.
- [3] Wang BH, Pureza V, Wang H. A tale of Wunderlich syndrome. *J Surg Case Rep*. 2012;2012(11):rjs015–rjs015.
- [4] Lee SH, Yun SJ. Polyarteritis nodosa presenting as bilateral Wunderlich syndrome: rare cause of flank pain in a young woman. *Am J Emerg Med*. 2017;35(5):800.e1–800.e3.
- [5] Hassanpour A, Ahmed F, Yeganeh BS, et al. Spontaneous rupture of renal cell carcinoma in pregnancy, surgical management with fetal preservation: a case report. *Urol J*. 2018;15(6):400–402.
- [6] Kane D, Abdelrahman M, Looney AT, et al. Wunderlich's syndrome in pregnancy: a shocking triad. *BMJ Case Reports CP*. 2019;12(5):e229219.
- [7] Boussios S, Pavlidis N. Renal cell carcinoma in pregnancy: a rare coexistence. *Clin Transl Oncol*. 2013;16(2):122–127.
- [8] Yilmaz E, Oguz F, Tuncay G, et al. Renal cell carcinoma diagnosed during pregnancy: a case report and literature review. *J Int Med Res*. 2018;46(8):3422–3426. .
- [9] Buda A, Pizzocaro G, Ceruti P, et al. Case report: renal cell carcinoma presenting as hypertension in pregnancy. *Arch Gynecol Obstet*. 2007;277(3):263–265.
- [10] George J, Nester C, McIntosh J. Syndromes of thrombotic microangiopathy associated with pregnancy. *Hematology*. 2015;2015(1):644–648.
- [11] Cines D, Levine L. Thrombocytopenia in pregnancy. *Hematology*. 2017;2017(1):144–151.
- [12] Houston S, Hegele R, Sugar L, et al. Is thrombotic microangiopathy a paraneoplastic phenomenon? Case report and review of the literature. *Clin Kidney J*. 2011;4(5):292–294. .
- [13] Lee E, Otoukesh S, Abdi PA, et al. Hemolytic anemia of malignancy: a case study involving signet ring cell metastatic breast cancer with severe microangiopathic hemolytic anemia. *Case Rep Oncol*. 2019;12(1):104–108.