

## CASE REPORT

# Acute fibrinous constrictive pericarditis and large pericardial effusion as the first manifestation of systemic lupus erythematosus disease in an adult male patient

Hannaneh Yousefi-Koma<sup>1</sup>  | Rozita Jalalian<sup>2</sup>  | Babak Bagheri<sup>2</sup> 

<sup>1</sup>School of Medicine, Tehran University of Medical Sciences (TUMS), Tehran, Iran

<sup>2</sup>Faculty of Medicine, Department of Cardiology, Cardiovascular Research Center, Mazandaran University of Medical Sciences, Sari, Iran

## Correspondence

Rozita Jalalian, Faculty of Medicine, Cardiovascular Department, Cardiovascular Research Center, Mazandaran University of Medical Sciences, Serah Joibar, the beginning of Valiasr Highway, Imam Square, Sari, Iran.  
Email: [rozita\\_jalalian@yahoo.com](mailto:rozita_jalalian@yahoo.com)

## Key Clinical Message

Systemic lupus erythematosus (SLE) can have various manifestations. Although cardiac involvement is very common in SLE patients, a severe acute pericarditis as the first manifestation of SLE in a male patient is relatively rare. A 36-year-old male was admitted to our hospital with acute pericarditis, large circumferential fibrinous pericarditis, and major criteria of a high-risk case of acute pericarditis. After a complete investigation, the underlying disease was revealed to be SLE. All of his symptoms were completely resolved after 6 weeks of treatment with non-steroidal anti-inflammatory drugs and corticosteroids with no need for a pericardiocentesis. Patients with acute fibrinous pericarditis should be considered and precisely investigated for multiorgan autoimmune process such as SLE, to avoid unnecessary intervention, and minimize the risk of recurrence and chronicity of the condition.

## KEYWORDS

constrictive pericarditis, Doppler echocardiography, fibrinous pericarditis, pericarditis, SLE

## 1 | INTRODUCTION

Pericardial syndromes are not uncommon manifestations in clinical practice.<sup>1</sup> About 5% of all patients admitted to the emergency department with the chief complaint of chest pain, are diagnosed with acute pericarditis.<sup>2</sup> Cardiac involvement is a common presentation of different autoimmune rheumatic diseases. Systemic lupus erythematosus (SLE) is a chronic autoimmune rheumatic disease with multiorgan involvement. Cardiac involvement has been reported in about 50% of SLE patients; in some cases, as their first presentation of SLE.<sup>3</sup> The most common type of cardiac involvement in SLE patients is pericarditis.<sup>4</sup> While it

is classically known that SLE like most of other autoimmune diseases is more prevalent in women, cardiac involvement as pericarditis in SLE is more prevalent in male patients.<sup>2</sup> Although being a common manifestation of SLE, it is uncommon for acute fibrinous pericarditis with constrictive features to be the first presentation of SLE in patients with severe manifestations and in need for hospital admission.<sup>5</sup>

## 2 | CASE PRESENTATION

A 36-year-old Iranian male patient was presented to our emergency department (Fatemeh-Zahra Hospital of Sari

This is an open access article under the terms of the [Creative Commons Attribution-NonCommercial-NoDerivs](https://creativecommons.org/licenses/by-nc-nd/4.0/) License, which permits use and distribution in any medium, provided the original work is properly cited, the use is non-commercial and no modifications or adaptations are made.

© 2023 The Authors. *Clinical Case Reports* published by John Wiley & Sons Ltd.

University of Medical Sciences) with pleuritic chest pain, dyspnea, fever, and chills. His first symptoms had been pleuritic chest pain, dyspnea, and fatigue which began about 1 month earlier and had progressively worsened in the last few days. The patient described the chest pain to be sharp, radiating to the left shoulder, worse in supine position, and alleviated while leaning forward. He reported exertional dyspnea with a III to IV function class of the New York Heart Association (NYHA) classification.<sup>6</sup> He described the fever to have an intermittent pattern and was first detected 10 days before hospital admission. He had no rash, alopecia, or oral ulcers. He did not complain of arthralgia or morning stiffness. Our patient had been visited by a pulmonologist before hospital admission, and was first prescribed with bronchodilators which did not relieve his symptoms. Therefore, a chest computed tomography scan (CT scan) was performed and revealed enlarged cardiac silhouette, severe pericardial effusion, and mild to moderate left-sided pleural effusion, for which he was referred to our institution for pericardiocentesis and further investigations.

He had a history of a psoriatic-like rash on his posterior neck about a month ago which resolved with topical treatment with no recurrence. He did not mention any history of recent viral or bacterial infection. His family history was negative for Mycobacterium tuberculosis infection or any autoimmune diseases.

On physical examination, the patient looked slim (i.e., height: 173 cm, weight: 60 kg, and body mass index at 20.04 kg/m<sup>2</sup>). He was febrile (i.e., body temperature at 39.5°C), had a pulse rate of 82 beats per minute, blood pressure of 70/110 mmHg, respiratory rate of 14 breaths per minute, and an elevated jugular venous pressure (JVP). Heart sounds were muffled. Respiratory sounds were decreased at the base of the left hemithorax. There was bilateral distal lower limb pitting edema up to the distal part of his shins which was graded as 1+ (i.e., rebounded in 2–3 s after applying pressure). Pulsus paradoxus was not present. There was not any rash, alopecia, or oral ulcers. In electrocardiogram (ECG), generalized low voltages were seen.

Transthoracic echocardiography (TTE) showed large pericardial effusion, more than 4 cm in diameter, with loculation and septation, fulfilled with fibrin strands (i.e., bread and butter pattern). Increased pericardial thickening, more than 1 cm thickness, with constrictive physiology were observed. No pericardial calcification was seen (Figure 1). There was septal bounce with abnormal double motion of interventricular septum in diastole (Figure 2). Septal shift was seen in apical 4 chamber view with bulging of the interventricular septum with inspiration toward the left ventricle (LV), causing underfilled LV and bulging of interventricular septum toward the right ventricle (RV)

at LV filling with expiration, all happening reversely (Figure 3) (Supplementary video 1). Doppler study showed significant respiratory variations of tricuspid and mitral valve. The tricuspid valve inflow E velocity was increased more than 50% with inspiration, and the mitral valve inflow E velocity was increased more than 40% with expiration. Tissue Doppler imaging showed exaggerated E' velocity in septum (Figure 4 (A)) and annulus reversus (i.e., decreased E' lateral velocity compared to E' septum velocity) (Figure 4 (B)). TTE study in subcostal view demonstrated pericardial thickening (Figure 5 (A)) (supplementary video 2) and dilated inferior vena cava (IVC) without respiratory collapse (Figure 5 (B)).

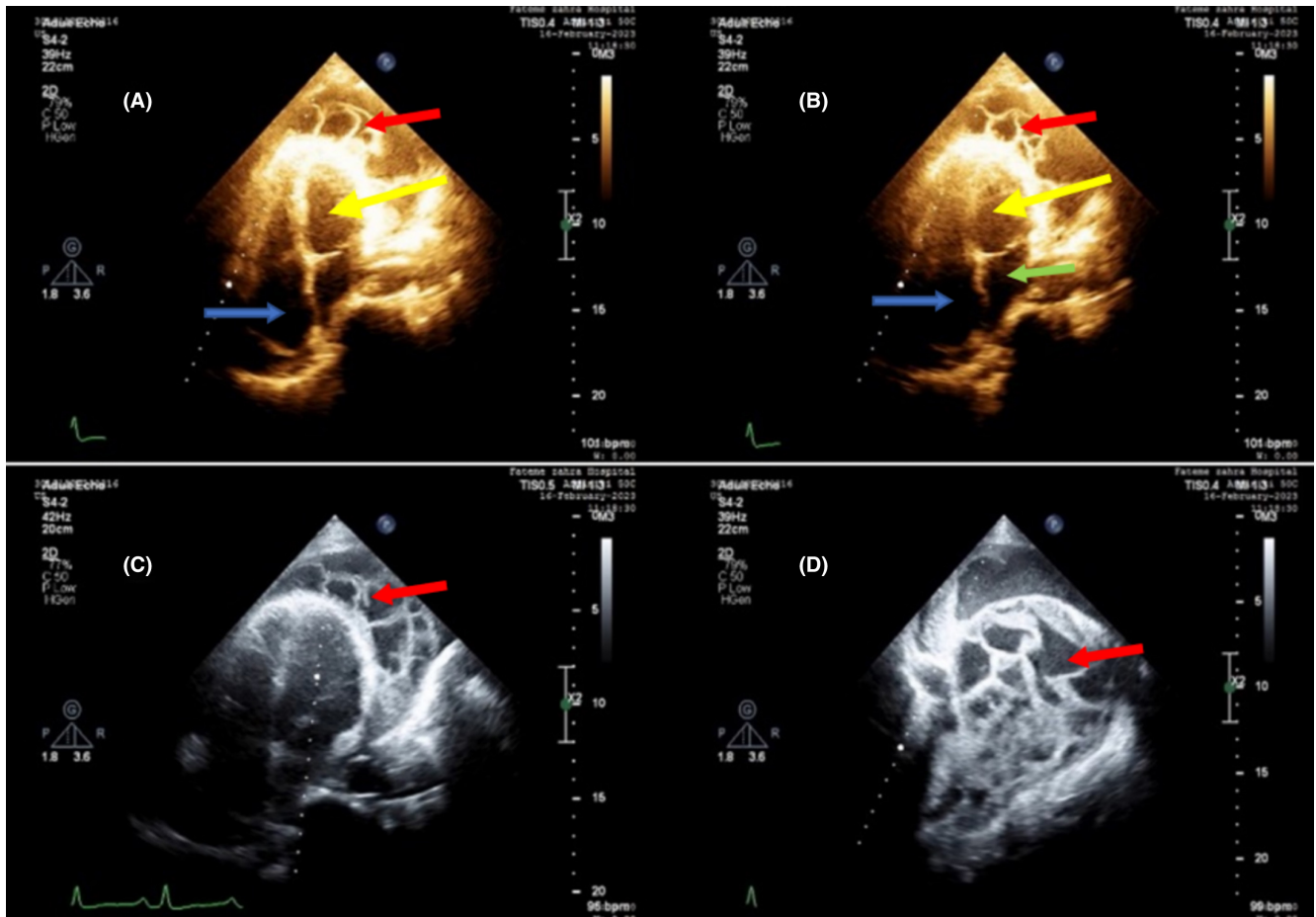
All of the TTE imaging results mentioned above, were in favor of acute fibrinous pericarditis with constrictive features. Abdominal ultrasonography was performed to assess any evidence of malignancy and the result was clear. Laboratory investigations revealed mild leukocytosis with 14,850 white blood cell per microliter, elevated C-reactive protein (CRP), and erythrocyte sedimentation rate (ESR) (Table 1). Tuberculin skin test with purified protein derivative (PPD) was performed and the result turned out to be negative (Table 1). Viral screening test results were also negative. Mycobacterium tuberculosis (TB), and other probable infectious diseases were ruled out (Table 1). We started pericarditis treatment with anti-inflammatory agents of oral ibuprofen 600 mg every 8 h (q8h) and colchicine 0.5 mg daily (q24h) while continuing our investigations for immune-mediated inflammatory processes as a probable cause.

Our patient was on the treatment protocol of ibuprofen and colchicine for 1 week with no significant improvement of his signs and symptoms or TTE examination. Therefore, after 1 week from his admission, corticosteroids were added to our patient's treatment regimen with the starting dose of 30 mg prednisolone daily; 60 kg \* 0.5 mg/kg/day.

Meanwhile, Investigations for autoimmune etiology revealed high titers of anti-nuclear antibody (ANA) and rheumatoid factor (RF) with elevated levels of anti-ds DNA antibody (Table 1). As anti-ds DNA antibody is a specific marker for SLE, we calculated our patient's score for diagnosis of SLE according to the 2019 European league against rheumatism (EULAR) and the American College of Rheumatology (ACR) classification criteria for SLE.<sup>7</sup> Thus, rheumatologic consult was ordered.

Our patient's treatment regimen with NSAIDs changed to disease-modifying anti-rheumatic drugs (DMARDs) administration of hydroxychloroquine with a daily dose of 400 mg.

Our patient was discharged home after 2 weeks of admission with the diagnosis of acute fibrinous pericarditis as the first manifestation of SLE. He had weekly follow-up visits with TTE examinations.



**FIGURE 1** TTE imaging results in apical four-chamber view: large size pericardial space with septation, loculation, and fibrin strands surrounding the heart. (A), (B), (C) and (D) different moments of the heart cycle. The yellow arrows point towards the left ventricle, the red arrows point towards the fibrin strands and pericardial effusion in the pericardial space, the blue arrows point towards the right atrium, and the green arrow points towards the left atrium.

On his sixth week of anti-inflammatory treatment at his follow-up visit, all of his signs and symptoms were resolved. TTE study showed that all the pericardial fibrin strands and effusion were completely resolved (Figure 6 (A),(B)) (Supplementary video 3). Hemodynamic of constrictive pattern was completely reversed in doppler study of mitral valve inflow with no respiratory variations.

After 6 months, our patient has remained symptom-free at his follow-up visits and is receiving his anti-inflammatory drugs for SLE treatment based on his rheumatologist's order.

### 3 | DISCUSSION

To come up with a final diagnosis of our patient, we summarized our patient's disease course as follows;

A 36-year-old male patient was admitted to our emergency department with pleuritic chest pain, dyspnea, intermittent fever, and a CT scan carried out few days

before, demonstrating severe pericardial effusion. The first suspected differential diagnosis was acute pericarditis. According to the 2015 European society of cardiology (ESC) guidelines for diagnosis and management of pericardial diseases, our patient's high fever (i.e., 39.5°C) and large pericardial effusion are considered major predicting factors of a poor prognosis.<sup>2</sup> Therefore, patient admission and search for the pericarditis etiology were mandatory.<sup>2</sup> Our patient was admitted and administration of NSAIDs was started.

With clinical signs and symptoms (i.e., characteristic chest pain and pericardial rub) suggestive of pericarditis, the diagnosis was confirmed by the ECG (i.e., generalized low voltages), TTE (i.e., fibrinous circumferential pericardial effusion, and thickened pericardium), and laboratory findings (i.e., elevated CRP and ESR). In Doppler investigations, constrictive patterns of pericarditis were observed. Since our patient's disease manifestations had started 4 weeks earlier, the diagnosis of acute fibrinous pericarditis was confirmed after the completion of the

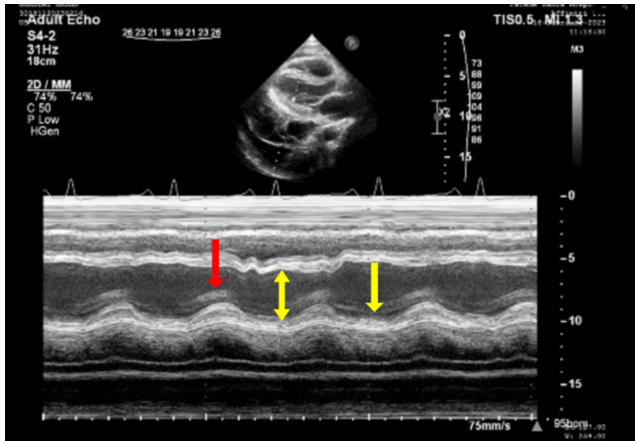


FIGURE 2 TTE imaging results: M-mode parasternal long axis shows septal bounce. The red arrow points towards expiration motion and the yellow arrows point towards inspiratory motions.

mentioned investigations. Even though our patient could not be categorized as a case of cardiac tamponade, hemodynamic alteration was present.<sup>2</sup> These hemodynamic changes are mainly because of pericardial thickness and the huge amount of fibrin strands in the pericardial effusion.<sup>8</sup> We monitored him closely, for the sake of any further hemodynamic alterations, started our search for the etiology, and decided to postpone the pericardiocentesis till the results of our primary investigations were ready.<sup>8</sup>

The diagnosis of constrictive pericarditis was confirmed by TTE investigations which in a sum up demonstrated the following: (1) thickened and hyperechoic pericardial layers; (2) massive circumferential pericardial effusion; (3) ventricular septal motion toward left ventricle during inspiration (septal bounce) detected in M-mode; (4) dilated IVC without respiratory collapse; (5)

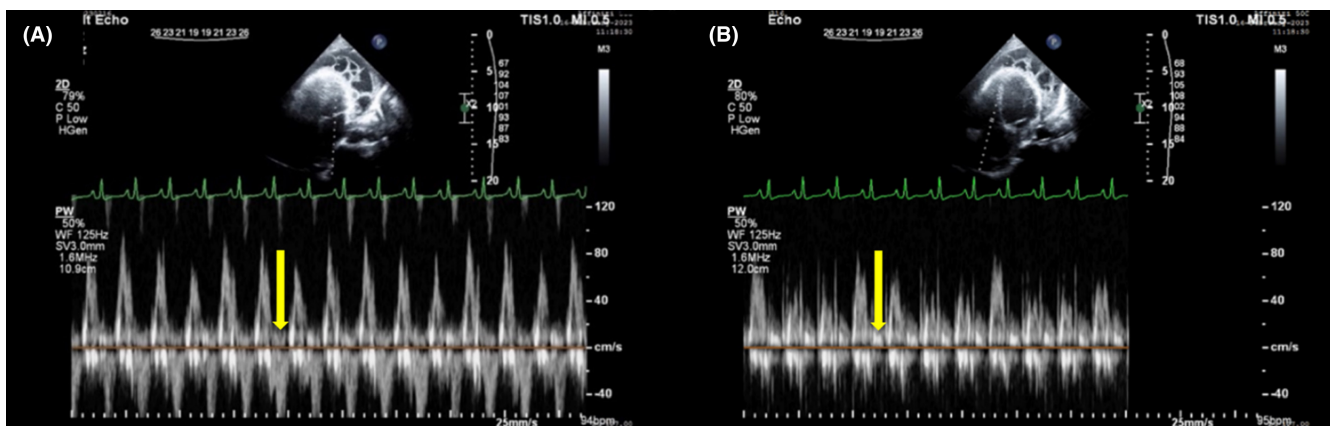


FIGURE 3 TTE imaging results. (A) Apical four-chamber view showed more than 40% respiratory variations of the mitral valve inflow E velocity. (B) Apical four-chamber view showed more than 50% respiratory variations of tricuspid valve inflow with inspiration. The yellow arrows point towards the respiratory variations.

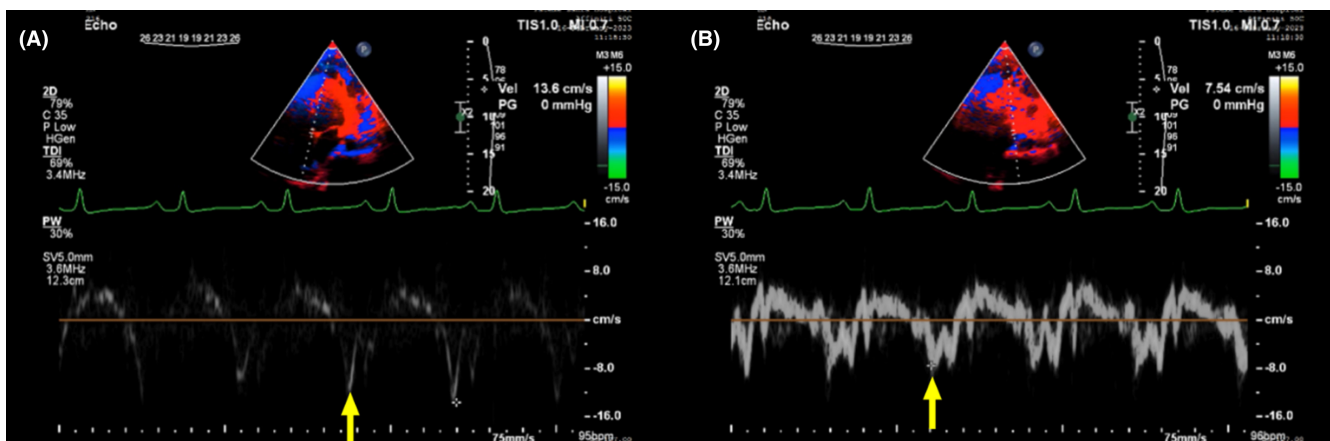
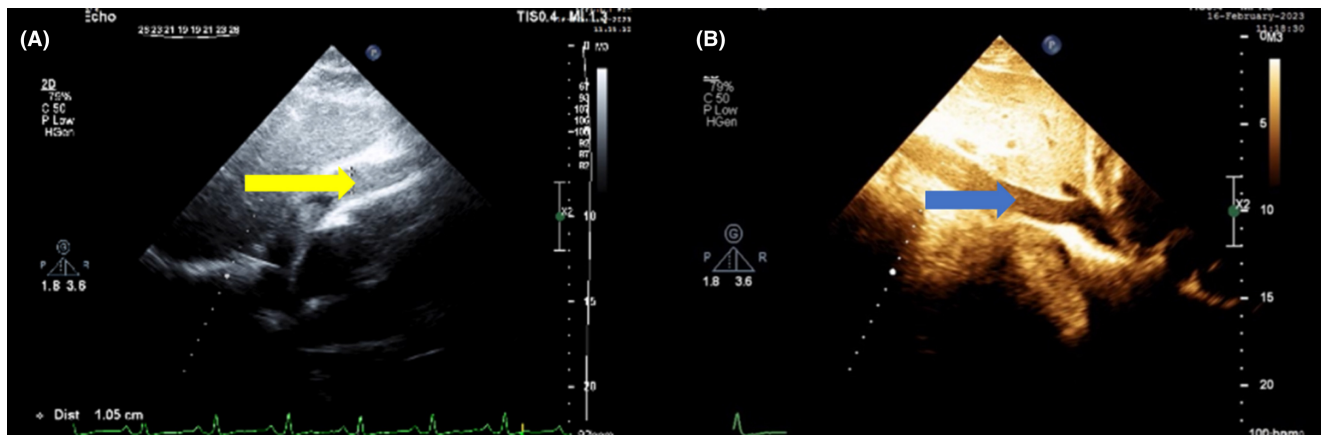


FIGURE 4 TTE imaging results. (A) Septal tissue Doppler imaging (TDI) showed exaggerated E' velocity of septum. (B) Decreased E' lateral velocity (i.e., annulus reversus). The yellow arrows point towards E' velocity.



**FIGURE 5** TTE imaging results in subcostal view. (A) Increased pericardial thickening. (B) Dilated IVC without inspiratory collapse. The yellow arrow points towards pericardium and the blue arrow points towards IVC.

**TABLE 1** Laboratory findings.

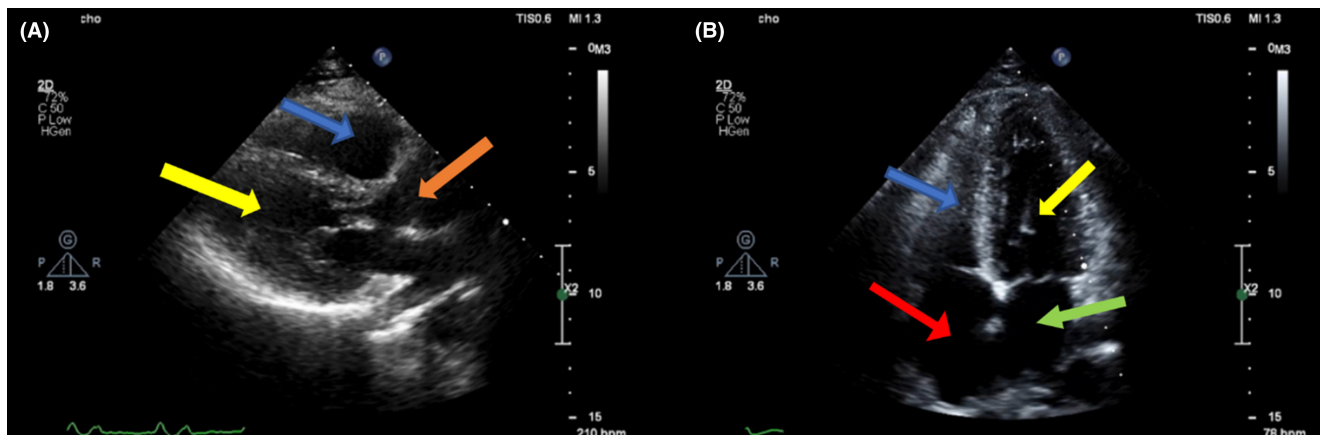
Laboratory tests	Results
WBC	14,850 /micL
Hb	14.5 g/dL
PLT	376000 /micL
ESR	74 mm/h
CRP	63 mg/L
Cr	1.3 mg/dL
Rheumatoid factor (RF)	46 IU/mL (positive > 20)
Anti-nuclear antibody (ANA) (IF)	1/80 (negative <1/80)
Anti-ds DNA	51.5 IU/mL (positive > 35)
Anti-Sm	Negative
Anti-Ro	Negative
Anti-La	Negative
Anti-neutrophil cytoplasm antibodies (ANCA)	Negative
Anti-cyclic citrullinated peptide (anti-CCP)	17 U/mL (equivocal: 12–18, positive >18)
Angiotensin converting enzyme (ACE)	18 U/L (normal range: 13.3–63.9)
Ferritin	94 ng/mL (male normal range: 24–336 ng/mL)
Anti-HCV antibody	Negative
HBs-Ag	Negative
HIV 1 & 2 Ag	Negative
PPD (72 h)	Negative
IGRA (QuantiFERON)	Negative
2 ME	Negative

more than 50% respiratory variation of the mitral peak E velocity (with more than 25% variation suggestive for constrictive pattern); (6) more than 50% respiratory variation of the tricuspid peak E velocity (with more than 40%

variation suggestive for constrictive pattern); (7) reverse pattern for early diastolic peak velocity (e') of lateral and septal mitral annulus known as annulus reversus (i.e., e' lateral > e' septal).

There are specific forms of constrictive pericarditis described in the literature making it difficult to classify our patient. Given the signs of elevated JVP, severe pericardial effusion, and constrictive features in an acute course which completely resolved after 6 weeks of receiving anti-inflammatory medications, we assumed transient constrictive and effusive-constrictive forms to be the major differential diagnoses.<sup>2,9</sup> The transient form was ruled out with regards to our patient's large pericardial effusion containing fibrin strands. Effusive-constrictive pericarditis is defined as constrictive pericarditis with tamponade presentation. Even though our patient had elevated JVP, his hemodynamic status was not consistent with a tamponade presentation. Therefore, by not fitting into any of these two specific forms, we prefer to present our case as a merely constrictive pericarditis. The most important and tricky differential diagnosis of constrictive pericarditis is restrictive cardiomyopathy.<sup>10</sup> This was ruled out for our patient by the TTE findings (e.g., presence of respiratory variations of mitral valve inflow).<sup>9</sup>

According to the 2015 ESC guidelines for diagnosis and management of pericardial diseases, there are two main categories for the etiology of pericardial syndromes: infectious and noninfectious. In the infectious category, viral infections and TB are the most common causes. We ruled out TB infection by tuberculin skin test, and viral causes were not probable as there was no history of any symptoms that triggered our clinical suspicion. For non-infectious causes, autoimmune diseases and malignancies secondary to metastasis are the main focus. We searched for any abnormal presentations or lesions in the chest CT scan and abdominal sonography consistent with laboratory findings for a neoplastic diagnosis, but none was



**FIGURE 6** TTE imaging results after anti-inflammatory treatment in parasternal long axis (A) and apical four-chamber (B) views, complete resolution of pericardial fibrin and thickening. The yellow arrows point towards the left ventricles, the blue arrows point towards the right ventricle, the green arrow points towards left atrium, the red arrow points towards the right atrium, and the orange arrow points towards the aorta.

found. Therefore, we continued our etiology investigation by executing autoimmune-specific laboratory tests.<sup>2</sup>

After 1 week of treatment with NSAIDs, neither his signs and symptoms, nor his TTE results showed any significant improvements. Thereby, corticosteroids were added to his treatment regimen. At the same time, autoimmune-specific investigations for the etiology of the pericarditis, revealed high ANA and RF titers, and elevated anti-ds DNA antibody levels.

Anti-ds DNA antibody is an SLE-specific autoantibody. Thus, we calculated our patient's score for SLE involvement based on the 2019 EULAR/ACR classification criteria for SLE.<sup>7</sup> ANA positive with a 1/80 titer, fever as a constitutional symptom (score weight: 2), acute pericarditis (score weight: 6), and positive anti-ds DNA antibody (score weight: 6), collectively made up a total of 12 score which made our SLE diagnosis definite.

Thereafter, we managed our patient with the consult of rheumatologists with the final diagnosis of large circumferential fibrinous constrictive pericarditis as the first presentation of SLE. NSAIDs were replaced by hydroxychloroquine for our patient. Our patient started to show progressive improvement from the second week of treatment and was completely symptom-free after 5 weeks of treatment with hydroxychloroquine and corticosteroids, with no need of pericardiocentesis.

The corticosteroid protocol used for our patients with the recommended starting dose was then adjusted and tapered based on our patient's symptomatic and laboratory improvements as followed: (1) 30 mg prednisolone daily for 2 weeks; (2) 25 mg prednisolone for 4 weeks; (3) tapering and dose modifications with rheumatologist's order reached to a 10-mg daily dose of prednisolone.<sup>2</sup>

There are several remarkable aspects regarding this case. First of all, the diagnosis of constrictive pericarditis

along with large pericardial effusion can be very tricky especially in acute phases. This is because constrictive features of acute pericarditis may not be represented in CT scans or magnetic resonance imaging. Therefore, it is crucial to execute a complete Doppler echocardiography study for the patient.

The main concern respecting constrictive pericarditis is the missed diagnosis of its underlying cause. This could lead to a recurrent and/or chronic course of the disease to the point that the patient presents signs and symptoms indicating pericardiectomy, or more precisely epicardiectomy. Epicardium is the inner layer of pericardia, and responsible for constrictive features of constrictive pericarditis. Therefore, it is technically more troublesome to resect with a reported 6%–12% mortality rate of the procedure.<sup>2</sup> This can go further with the involvement of other heart layers. In order to prevent these adverse consequences, a thorough and precise search for the etiology is essential so that the optimal treatment is provided<sup>11</sup>; as with our case which starting hydroxychloroquine resulted in remarkable resolution of our patient's manifestations.

Although pericardial diseases occurring in the course of SLE are relatively common, it is of great value to consider a full investigation for the etiology of constrictive pericarditis, as if the underlying cause is not treated promptly it can lead to a chronic course with probable eventual need for epicardiectomy and a more complicated disease course.<sup>11</sup> Therefore, a thorough investigation of its etiology would result in less morbidity and mortality in patients.

## 4 | CONCLUSION

This case reminds us to have thorough attentive investigations for constrictive pericarditis so that less probable

etiologies are not missed, optimal treatment is delivered, and serious adverse events are prevented. It is of great consideration to execute a rigorous investigation for autoimmune etiologies even when there is no prior history. In cases of acute pericarditis, constrictive pathophysiology must always be kept in mind so that inappropriate pericardiocentesis is prevented.

### AUTHOR CONTRIBUTIONS

**Hannaneh Yousefi-Koma:** Writing – original draft; writing – review and editing. **Rozita Jalalian:** Conceptualization; data curation; writing – review and editing. **Babak Bagheri:** Supervision.

### ACKNOWLEDGMENTS

No funds, grants, or other support were received for this case report.

### FUNDING INFORMATION

None.

### CONFLICT OF INTEREST STATEMENT

None.

### DATA AVAILABILITY STATEMENT

The authors confirm that the data supporting the findings of this study are available within the article or its supplementary materials.

### CONSENT

Written informed consent was obtained from the patient for publication of this case report.

### ORCID

Hannaneh Yousefi-Koma  <https://orcid.org/0000-0001-7498-301X>

[org/0000-0001-7498-301X](https://orcid.org/0000-0001-7498-301X)

Rozita Jalalian  <https://orcid.org/0000-0001-9721-4950>

Babak Bagheri  <https://orcid.org/0000-0002-5133-2481>

### REFERENCES

1. Kalra AG, Sharp AJ, Dinkha L, et al. Effusive-constrictive pericarditis in a young active duty male. *Cureus*. 2020;12(8):e9997. doi:10.7759/cureus.9997
2. Adler Y, Charron P, Imazio M, et al. 2015 ESC guidelines for the diagnosis and management of pericardial diseases: the task force for the diagnosis and Management of Pericardial Diseases of the European Society of Cardiology (ESC) endorsed by: the European Association for Cardio-Thoracic Surgery (EACTS). *Eur Heart J*. 2015;36(42):2921-2964. doi:10.1093/eurheartj/ehv318

3. Chourabi C, Mahfoudhi H, Sayhi S, et al. Cardiac tamponade: an uncommon presenting feature of systemic lupus erythematosus (a case-based review). *Pan Afr Med J*. 2020;28(36):368. doi:10.11604/pamj.2020.36.368.25044
4. Gumireddy SR, Chaliki HP, Cummings KW, et al. Systemic lupus erythematosus presenting As constrictive pericarditis. *Circ Cardiovasc Imaging*. 2020 Sep;13(9):e010254. doi:10.1161/CIRCIMAGING.119.010254
5. Sumajaya IDGD, Aryadi IPH, Eryana IM. Effusive-constrictive pericarditis as first manifestation of late-onset systemic lupus erythematosus: an atypical case with grave prognosis. *Egypt Heart J*. 2023;75(1):30. doi:10.1186/s43044-023-00353-6
6. Bredy C, Ministeri M, Kempny A, et al. New York heart association (NYHA) classification in adults with congenital heart disease: relation to objective measures of exercise and outcome. *Eur Heart J Qual Care Clin Outcomes*. 2018;4(1):51-58. doi:10.1093/ehjqcco/qcx031 PMID: 28950356.
7. Aringer M, Costenbader K, Daikh D, et al. 2019 European league against rheumatism/American College of Rheumatology Classification Criteria for systemic lupus erythematosus. *Arthritis Rheumatol*. 2019;71(9):1400-1412. doi:10.1002/art.40930
8. Iavazzo A, Pinna GB, Romeo MG, et al. A rare case of effusive-constrictive pericarditis caused by *Streptococcus agalactiae*: emergency surgical treatment. *Medicina (Kaunas)*. 2022;58(6):699. doi:10.3390/medicina58060699
9. Miranda WR, Oh JK. Effusive-constrictive pericarditis. *Cardiol Clin*. 2017;35(4):551-558. doi:10.1016/j.ccl.2017.07.008 PMID: 29025546.
10. Reuss CS, Wilansky SM, Lester SJ, et al. Using mitral “annulus reversus” to diagnose constrictive pericarditis. *Eur J Echocardiogr*. 2009;10(3):372-375. doi:10.1093/ejechocard/jen258
11. Sagristà-Sauleda J, Angel J, Sánchez A, et al. Effusive-constrictive pericarditis. *N Engl J Med*. 2004;350(5):469-475. doi:10.1056/NEJMoa035630 PMID: 14749455.

### SUPPORTING INFORMATION

Additional supporting information can be found online in the Supporting Information section at the end of this article.

**How to cite this article:** Yousefi-Koma H, Jalalian R, Bagheri B. Acute fibrinous constrictive pericarditis and large pericardial effusion as the first manifestation of systemic lupus erythematosus disease in an adult male patient. *Clin Case Rep*. 2023;11:e7958. doi:10.1002/ccr3.7958