

# Rotating the Tip in Long Noses: A Strategy rather than a Single Technique

Rasha Abdelkader, MD\*  
Sameh El-Noamany, MD†  
Kyrillos Makarem, MD‡

**Background:** Rhinoplasty is one of the most commonly performed aesthetic surgical procedures in plastic surgery, the incidence of which has increased up to approximately 1 million cases in 2016 according to the recent International Society of Aesthetic Plastic Surgery survey. This study aimed at defining the importance of each sequential procedure within the same surgery, the extent to which a procedure can be performed, and those that can be omitted.

**Methods:** In this descriptive study, 27 candidates (18 women; nine men; age range, 20–48 years) for primary rhinoplasty between September 2016 and September 2019 were included. All had long noses, their main concern was reduction of nasal tip projection and all were seeking cranial tip rotation to enhance their tip aesthetics. Those who required revision rhinoplasty or who had nasal deformities due to congenital defects, and those older than 60 or younger than 18 years of age, were excluded.

**Results:** The average nasolabial angle in women preoperatively was  $88.2 \pm 6.6$  and postoperatively  $102.8 \pm 5.6$ . In men, the average average nasolabial angle preoperatively was  $79.6 \pm 5.4$  and postoperatively  $92.3 \pm 2.3$ . In both men and women, the *P* value was  $<0.001$ , which indicates high significance. Tip rotation was achieved in all patients, with 81% achieving ideal rotation, and 19% exceeding the ideal range.

**Conclusions:** Rotating the tip in long noses is a complex procedure. It can be achieved by many described techniques, but not all are required. A general strategy should be followed during which variable techniques, with varying efficacy, can be utilized. (*Plast Reconstr Surg Glob Open* 2021;9:e3629; doi: [10.1097/GOX.0000000000003629](https://doi.org/10.1097/GOX.0000000000003629); Published online 29 June 2021.)

## INTRODUCTION

Rhinoplasty continues to be one of the most common aesthetic surgical procedures in plastic surgery, the incidence of which has increased up to approximately 1 million cases in 2016 according to the recent International Society of Aesthetic Plastic Surgery survey.<sup>1</sup> Among the many goals to be achieved through rhinoplasty procedures, sculpting the tip of the nose is most challenging.<sup>2</sup>

The nasal tip is supported in its position by several anatomical features, including the innate strength of the

lower lateral cartilage, attachment of the medial crura to the septum, and the attachment of upper lateral cartilage to alar cartilage. Additionally, minor tip support is provided by the dorsal septum, inter-domal ligaments, membranous septum, nasal spine, surrounding skin and soft tissues, and the alar side walls.<sup>3</sup>

The tripod concept described by Anderson and the spring model introduced by Westreich and Lawson provided an understanding of the dynamics of tip rhinoplasty.<sup>4,5</sup> The anatomy of the two alar cartilages forms a functional tripod that provides tip support. The right and left lateral crura comprise two pillars of the tripod, and two conjoined medial crura function as the third pillar.

Based on a thorough understanding of the structural factors that maintain tip position and the dynamics of the tip complex,<sup>3–5</sup> a strategy can be proposed for rotating the

From the \*Department of Plastic Surgery, Faculty of Medicine, Cairo University, Egypt; †Department of Plastic Surgery, Faculty of Medicine, Cairo University, Egypt; and ‡Department of Plastic Surgery, Faculty of Medicine, Cairo University, Egypt.

Received for publication December 4, 2020; accepted April 6, 2021.

Copyright © 2021 The Authors. Published by Wolters Kluwer Health, Inc. on behalf of The American Society of Plastic Surgeons. This is an open-access article distributed under the terms of the [Creative Commons Attribution-Non Commercial-No Derivatives License 4.0 \(CCBY-NC-ND\)](https://creativecommons.org/licenses/by-nc-nd/4.0/), where it is permissible to download and share the work provided it is properly cited. The work cannot be changed in any way or used commercially without permission from the journal.

DOI: [10.1097/GOX.0000000000003629](https://doi.org/10.1097/GOX.0000000000003629)

**Disclosure:** All the authors have no financial interest to declare in relation to the content of this article. This study did not receive any funding.

Related Digital Media are available in the full-text version of the article on [www.PRSGlobalOpen.com](http://www.PRSGlobalOpen.com).

tip in a durable, sustainable manner to establish an aesthetically pleasing nasolabial angle. However, a long nose poses a challenge in its management and can ultimately lead to surgical pitfalls. Therefore, such procedures require adequate analysis and forethought, and many excisional, reconstructive, or camouflaging steps may be required to achieve a durable rotated nose.

In the current study, the authors sought to group the different techniques within fixed strategies to address nasal rotation and to define the importance of each technique, the extent to which a technique can be performed, and those that can be omitted within the same surgical procedure.

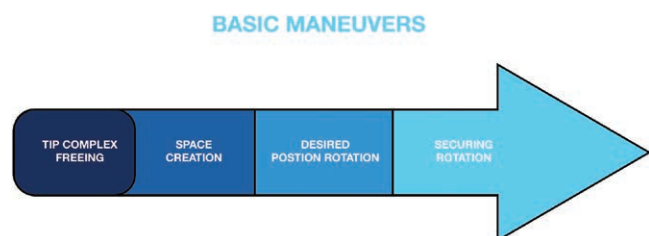
## METHODS

This descriptive study was performed between September 2016 and September 2019. It was conducted on 27 patients (18 women and nine men) who were candidates for primary rhinoplasty. They all had long noses and wished to enhance their tip aesthetics, with the main goal being a cephalic tip rotation. Patient age ranged from 20 to 48 years. All patients reported detailed history, underwent full nasal examination and received detailed information regarding the study. Each patient signed an informed consent to participate in the study and for their photographs to be published for educational purposes. The study protocol was approved by Faculty of Medicine, Cairo University Ethics Committee.

Revision rhinoplasty cases, reconstruction of nasal deformities due to congenital birth defects such as cleft lip, and patients aged older than 60 years and younger than 18 years were all excluded from our study. All study patients were photographed in standard views preoperatively and 12 months postoperatively. All surgeries were performed under general anesthesia, with the hypotensive technique and an external approach.

Rotating the nasal tip in the current study comprised a single strategy encompassing a sequence of methods and techniques:

1. Tip complex opening: skin and mucosal opening.
2. Space creation for the tip through caudal septum shortening, anterior septal angle modification, caudal upper lateral cartilage trimming, and lower lateral cartilage (LLC) trimming.
3. Achieving the desired degree of rotation by utilizing techniques addressing the medial and/or lateral crurae (tripod components).
4. Securing the rotation in place by utilizing septo-columellar sutures in cases of free columellar strut graft, or using septal extension grafts (Fig. 1).



**Fig. 1.** Illustration of basic maneuvers and sequence of methods and techniques.

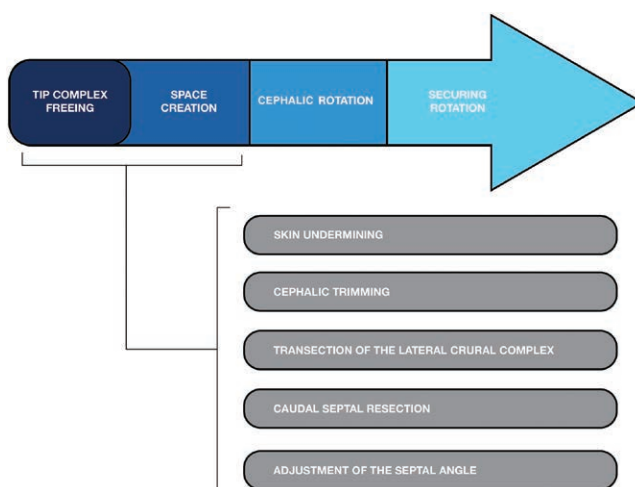
Several techniques were used for rotating the tip in the current study; however, not all techniques were used for all patients. A selected combination was performed according to each patient's situation, while addressing the overall goal.

To address the skin component, skin undermining was performed in all cases using the spreading technique with dissecting scissors, leaving the submuscular aponeurotic system and soft tissue on the cartilage then directly excising them; this was aided by injection of saline and adrenaline. In cases where the lateral crura of the LLC was wide (>6mm in men and >5mm in women) and the cartilage was strong, cephalic trimming was performed, leaving up to 5mm and up to 6mm of lateral crurae bilaterally in female and male patients, respectively.

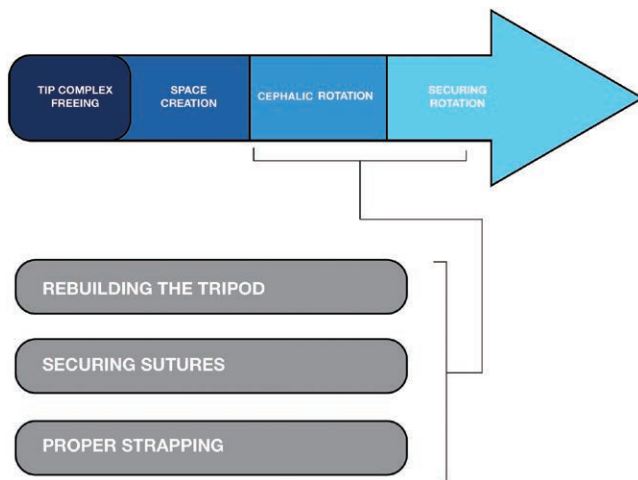
Additionally, in patients presenting with an over-projected tip, lateral crural transection and overlapping with suturing was performed. Either Prolene or polydioxanone (PDS) 5-0 were used with a taper ended needle tip.

For 17 patients displaying a long caudal septum that opposed rotation, caudal septal resection was carried out. In contrast, septal extension grafts were made in seven cases, whereas the so-called tongue in groove technique (TIG) was performed in three cases. Finally, adjustment of the degree of the anterior septal angle was established (Fig. 2).

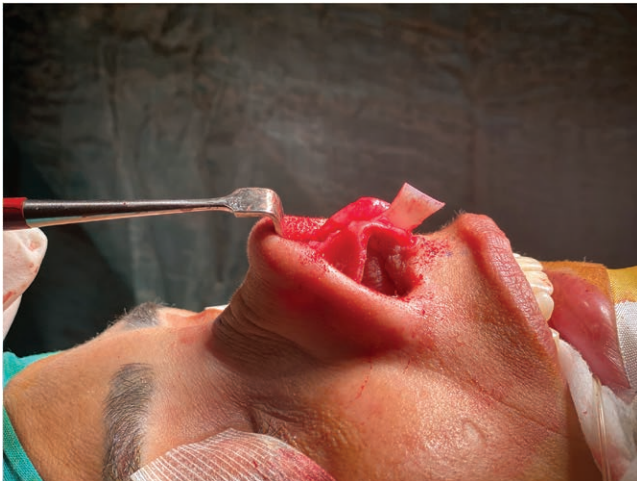Securing the rotation was then accomplished by either a columellar strut and septo-columellar sutures in cases with a short caudal septum (17 cases) using septal extension grafts fixed cranially side to side (seven cases, Fig. 3), or finally resorting to the TIG technique in the remaining three cases. (See Video 1 [online], which displays a free graft inserted between the two medial crurae, strengthening and supporting them especially in Middle-Eastern noses where cartilages are naturally weak.) (See Video 2 [online], which displays one suture passing through both medial crurae and the caudal septum after inserting the strut securing rotation and desired tip projection. Prolene 5/0 is used in all cases) (See Video 3 [online], which displays the cases with long nondeviated caudal septum together with hanging columella; the caudal septum can be used as a strut. In these cases, septo-columellar sutures are meaningless. This



**Fig. 2.** Illustration of methods and techniques used for tip complex freeing and space creation.



**Fig. 3.** Illustration of methods and techniques used for cephalic rotation and securing rotation.



**Fig. 4.** Intraoperative photograph demonstrating septal extension graft placement. This intraoperative image was taken during the surgical correction.

technique is durable, giving strong tip support.) Adjustment of the anterior septal angle was performed in all cases.

In three patients presenting with over-projected and de-rotated tips, the lateral crurae were effectively shaped with an alar setback technique aimed to strengthen the medial crurae, in which they were transected on both sides and sutured again after a columellar strut placement. Additionally, the lateral crurae were transected and overlapped, aiming at correction of the deformity. Postoperative strapping and casting was done for 1 week, then night strapping for 1 month was applied in all cases (Fig. 4).

Patient assessment was carried out both subjectively and objectively. Subjective patient satisfaction was determined with a direct questionnaire using a scale from zero (least satisfaction) to three (greatest satisfaction) regarding nasal tip rotation 1 year postoperatively.

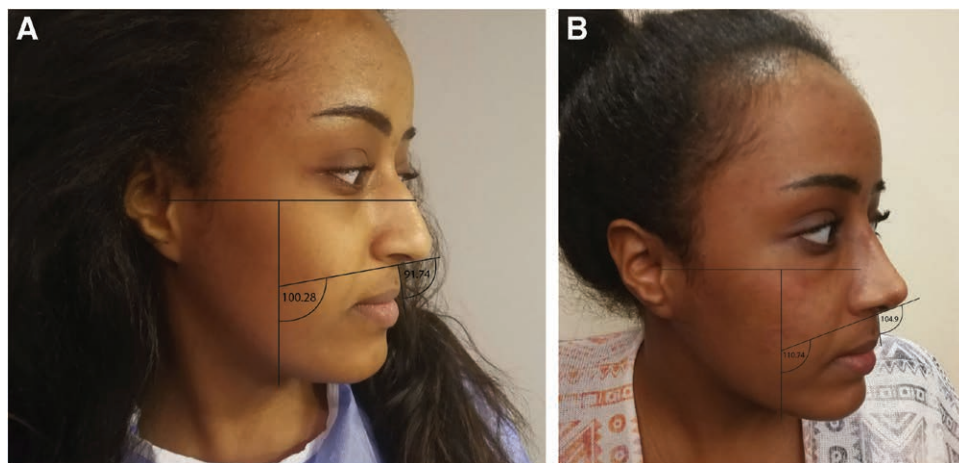
The degree of rotation was objectively assessed by measuring the nasolabial angle in postoperative photographs and comparing it with the preoperative photographs, using Adobe Illustrator CC 2018 for measurements (Fig. 5). Data were statistically described in terms of mean ( $\pm$  SD), or frequencies (number of cases) and percentages when appropriate. A comparison between the current study results and the ideal range<sup>6,7</sup> was made using Student *t* test for independent samples. Comparison between pre and postoperative values was performed using paired *t* test. Two-sided *P* values of less than 0.05 were considered statistically significant. All statistical calculations were performed using SPSS (Statistical Package for the Social Sciences; IBM Corp, Armonk, N.Y.) release 22 for Microsoft Windows.

## RESULTS

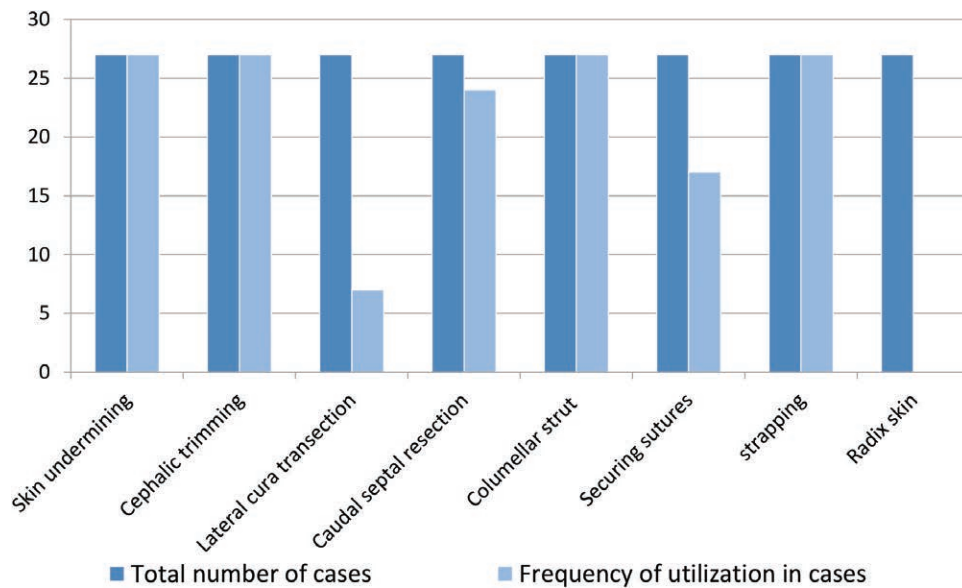
A total of 30 patients were recruited; 27 completed the 1-year follow-up period and rhinoplasty questionnaire survey. The mean age (years) was  $24.22 \pm 6.16$ .

### Pre- and Intraoperative Demographics

Fifteen patients presented with caudal rotation with animation during smiling, denoting a hyper-active



**Fig. 5.** Nasolabial angle and columellar facial angle measurements of a patient. A, Preoperative lateral view. B, Postoperative lateral view.



**Fig. 6.** Bar chart illustrating frequency of utilization of various techniques in comparison with total number of cases.

depressor septi nasi; accordingly, disinsertion was performed to abolish this rotating effect. Septal deviation was present in 18 cases (seven with S deviation and 11 with C deviation). Caudal septum deviation was present in 14 of the cases, among which five had long septa and nine had septa of adequate length.

Additionally, 20 patients had a dorsal hump that required excision. In seven of those, more than 3mm had to be excised, and a transverse osteotome was used; spreader flaps were utilized to maintain the internal nasal valve patency and function. In 13 of the cases, less than 3mm needed to be removed, and a rasp was used with the placement of spreader grafts to maintain valve mechanism and function.

In 10 cases, alar contour grafts were used to maintain the external nasal valve function, seven of which required alar transection. Three of these cases had innately weak LLC, and an additional alar rim graft was added.

#### Various Techniques Used to Alter Tip Rotation

A different combination of techniques was used on each patient. Skin undermining (27 cases), cephalic trimming (27 cases), septal angle adjustment (27 cases), columellar strut (either free grafting in 17 cases, septal extension graft in seven cases, or TIG in three cases), and strapping were all performed in 100% of patients. Alar contouring and tip grafting were performed in 25 patients (92.5%). Lateral crural transection was the least commonly performed technique, used in only seven patients (25.9%) (Fig. 6).

The results of the subjective assessment were as follows: 13 patients (48%) answered as three, as a satisfaction indicator in our questionnaire, seven patients (26%) answered as two, and five (19%) patients answered as one. Only two patients (7%) answered as zero. Those two patients underwent a second operation. One patient complained of alar flaring; accordingly, alar base excision was

performed. The second patient had a Polly-beak deformity and underwent direct excision of the remaining dorsal hump cartilage.

For objective assessment, the average NLA in women preoperatively was  $88.2 \pm 6.6$  and postoperatively  $102.8 \pm 5.6$ . In men the average NLA preoperatively was  $79.6 \pm 5.4$  and postoperatively  $92.3 \pm 2.3$ . This reflects a *P* value of less than 0.001, which shows high significance. The percentage of ideal rotation reached in women was 62%, while 38% had a rotation exceeding the ideal range. In contrast, the postoperative NLA measurements among male patients reached, and were all within, the ideal range of rotation (Tables 1, 2).

## CASES

### Discussion

Optimizing the degree of tip rotation is one of the most critical steps in modern rhinoplasty, which causes huge, long-term impact on the final aesthetics of the nose (Figs. 7–9). It can relieve most patients' stress and have a great impact on their satisfaction. The position of the nasal tip is defined by static and dynamic anatomical structures

**Table 1. Pre- and Postoperative NLA Angle Measurements in Male Patients**

Male Cases	NLA	
	Preoperative	Postoperative
1	73.05	89.19
2	75.38	94.67
3	87.3	95.3
4	83.06	92.2
5	77.32	89.6
6	73.89	91.33
7	86.63	94.5
8	77.26	92.78
9	82.27	90.64



**Table 2. Pre- and Postoperative NLA Angle Measurements in Female Patients**

Female Cases	NLA Angle	
	Preoperative	Postoperative
1	85.69	100.5
2	96.81	100
3	91.74	104.9
4	81.73	102.82
5	78.73	98.95
6	93.12	109.33
7	88.36	95.96
8	100.72	111.17
9	80.7	103.24
10	83.02	105.28
11	93.32	108.23
12	93.07	110.12
13	75.16	94.39
14	89.7	107
15	89.54	96.68
16	85.03	109.11
17	87.48	95.63
18	92.86	97.52

that the facial plastic surgeon must understand for a precise correction and a successful outcome.<sup>3</sup> Long noses do not all share similar anatomy. There are two types of long noses with increased acuteness of the nasolabial angle beyond normal values. Type 1 presents a normal alar cartilage complex inferiorly displaced by a long nasal septum and long upper lateral cartilages. Type 2 is usually encountered in old age and is caused by a dislocation of the alar cartilages downward from the aponeurotic attachments to the septal angle, and in secondary cases with lack of support.<sup>7,8</sup>

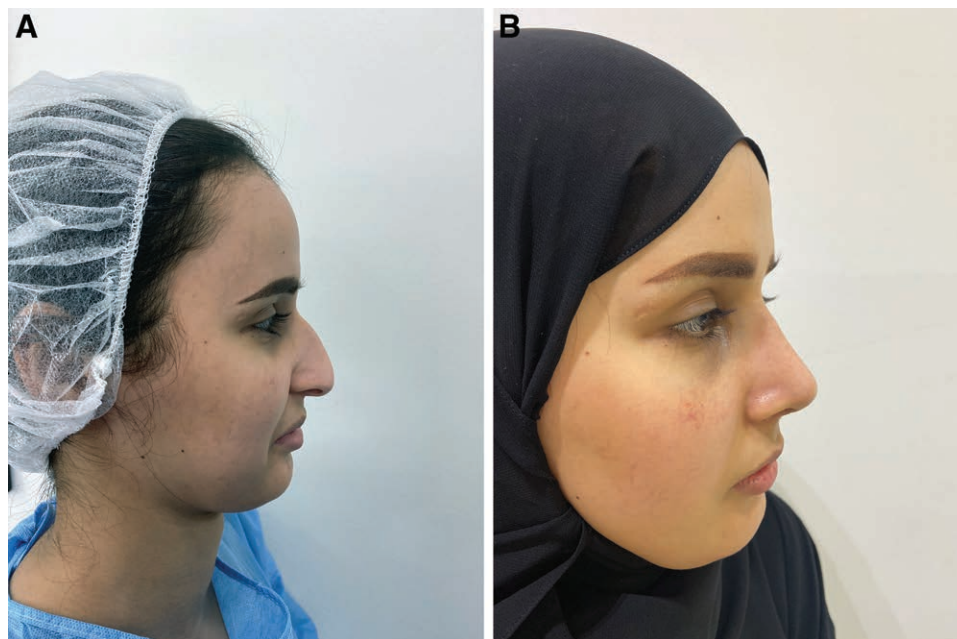Rotating the tip in long noses can pose a complex scenario to many surgeons. Many factors play a role in the degree of tip rotation and subsequently many techniques have been described. Therefore, rotation of the tip in long

noses actually depends on a number of specific major techniques that should be used consistently; otherwise, the result can be compromised or lead to failure in achieving a successful long-term outcome. Nevertheless, during the completion of each surgical strategy, not all steps/techniques need to be done, so an appropriate choice of techniques addressing each issue can be performed according to each individual case scenario.

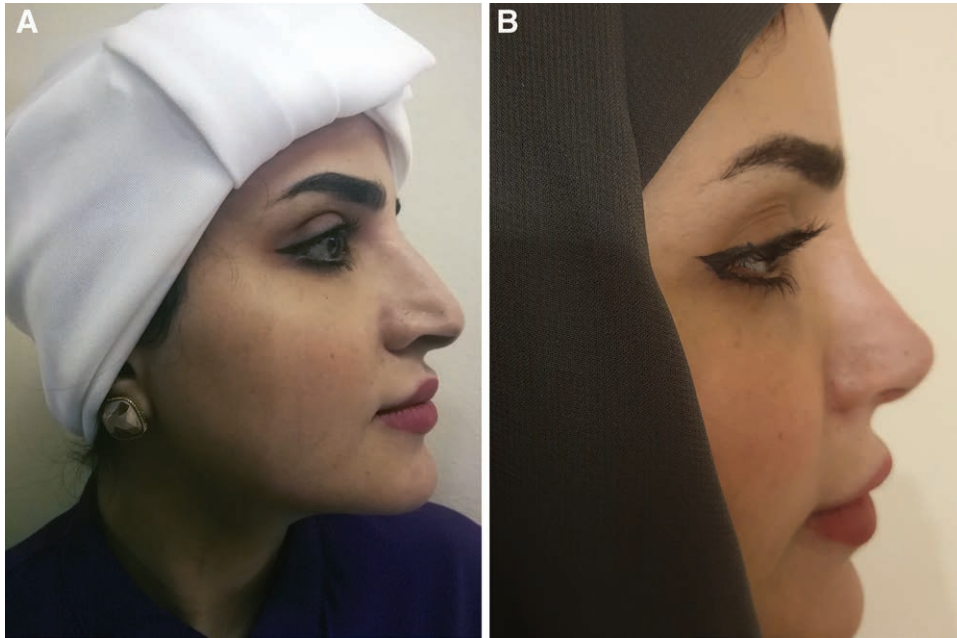Throughout the period of this study, it should be stressed that each case was unique; therefore, the techniques utilized or the extent of performance were always different. Sometimes reproduction of the same technique and replicating it constantly for all tip rotation cases can lead to suboptimal results during long-term follow up, when compared with utilizing different techniques or the same one but to a different extent according to each individual case.

Nasal skin undermining was carried out in all the cases included in the study, thus creating the space needed for tip movement; however prolonged edema that obscures the tip work is possible. Care must also be provided to avoid skin flap thinning or injury to the subdermal plexus, and this was achieved by the spreading technique, such that the unnecessary tissues over the cartilage were finally excised and did not jeopardize the subdermal plexus. All of our cases were Middle-Eastern noses with a thick envelope. Cephalic trimming, which was also performed in all cases, aids in tip definition and rotation but can injure the underlying mucosa, deforming the tip with aggressive resection, or affecting an originally weak external valve function, as in most Middle-Eastern noses.<sup>9</sup>

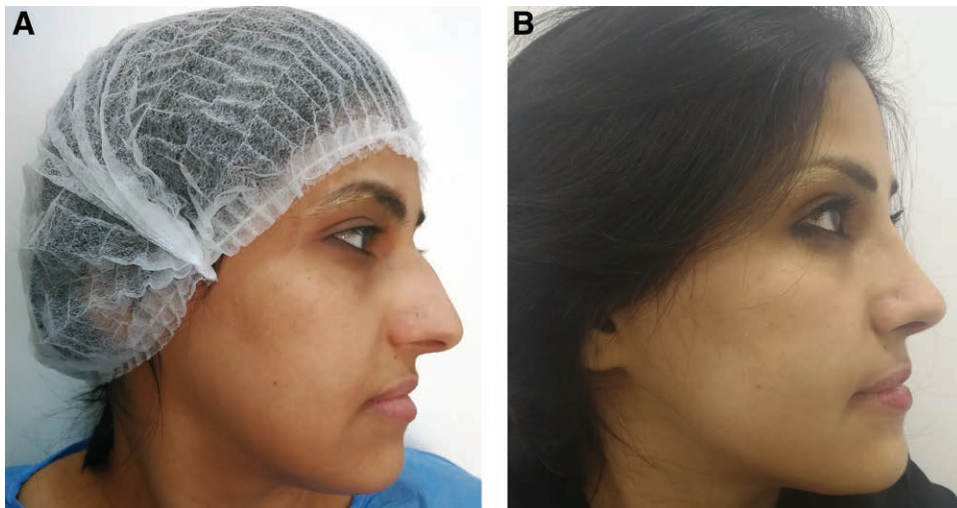
Caudal septum handling was performed in 17 cases, for shortening or changing the anterior septal angle. It provides the space for the tip to rotate but can result in a



**Fig. 7.** Caudal septal shortening performed with trimming of the lower lateral cartilages (case 1). An obtuse anterior septal angle was created with placement of a columellar strut in addition to columellar-septal suturing. A, Preoperative lateral view. B, Postoperative lateral view.



**Fig. 8.** Lower lateral cartilage trimming with alar setback and alar contour grafting (Case 2). The tongue in groove technique was utilized with an anterior septal angle creation. A, Preoperative lateral view. B, Postoperative lateral view.



**Fig. 9.** Shortening of the caudal septum aimed at creating an obtuse anterior septal angle. In addition, insertion of septal extension grafts cranially fixed side by side to the caudal septum. A, Preoperative lateral view. B, Postoperative lateral view.

depressed dorsum if an inadequate septal remnant is left; hence, utmost care is needed to preserve at least 1 cm of septal cartilage both ventrally and caudally after sub-mucous septal resection to preserve nasal architecture. The surgeon should also avoid injury to the mucosa surrounding the septum to avoid septal perforation. Shortening of the caudal nasal septum was performed in some of the cases where they were of adequate length, although deviated; shortening was then compensated by septal extension grafts.

Columellar strut is an extremely beneficial concept and was utilized with all cases to strengthen and elongate the medial crurae and create the desired cephalic

rotation and subsequently alter the NLA. Columellar strut is a tool to achieve medial crural support together with rotation and projection control. It can be used by simply suturing the medial crurae together in the postero-anterior direction. However, the cartilage can be sandwiched between the medial crurae for extra strength in the Middle-Eastern nose. The cartilage may present as a free columellar strut, septal extension graft with its cranial end fixed to the caudal septum, or by using the caudal septum itself as a strut. These techniques are all proven effective tools; however, they have variable degrees of stability versus stiffness.<sup>10</sup>

Free strut graft was classically described to control both rotation and projection. It is of lesser value in long-term tip support, although it yields a less stiff tip.<sup>11–14</sup> Septal extension graft was described early by Byrd et al, and is a very effective way to control tip position and create a beautiful supra-tip break with long-term stability.<sup>15</sup> It has been revisited by many authors with many modifications and extended indications.<sup>16–18</sup>

The tongue in groove technique is useful in correcting excess columellar appearance and maintaining correction of caudal deviation. It is also utilized to control nasal tip rotation and projection while preserving the integrity of the lobular cartilaginous complex and may be combined with either external or internal rhinoplasty. However, it carries the most risk of tip stiffness to the extent that it is described by many patients as being like a rock.<sup>19–21</sup> The tripod concept together with cantilever spring model can clarify the role of the medial and lateral crurae of both LLC in the formation of tip rotation degree.<sup>4,5</sup> Lateral crural transection and overlapping with sutures can be performed to provide symmetry while simultaneously achieving the desired tip rotation but carries the disadvantage of weakening the cartilaginous framework.<sup>9</sup>

Alar setback technique creates symmetrical LLC, thus altering the rotation and causing nasal tip deprojection, but also has the disadvantage of weakening the LLC complex.<sup>22</sup> Alar contour grafts can compensate for the resulting weakness.<sup>23</sup>

Medial crurae lengthening plays a role in tip rotation through lengthening of the nose. This could be achieved either by sutures to LLC or by cartilage graft usage, whether free, extension, or TIG.<sup>10</sup>

Columellar-septal sutures are an effective way to secure tip rotation, joining the tip complex to the upper two-thirds of the nose. It is mandatory only when using a free columellar strut graft or just medial crurae suturing. Many techniques have been described for columellar-septal fixation.<sup>24</sup> In the current study, Danielle suture was extremely beneficial for securing tip rotation; it consists of a suture to fix the columella strut between both crurae, bilateral domal creation sutures to create tip definition, and domal equalization suture to narrow and align the domes.<sup>25</sup>

The tripod was maintained and secured, aiming toward longevity and prevention of de-rotation over time. In addition, securing sutures were performed with non-absorbable suture material in 17 of the presenting cases. Moreover, during septal cartilage harvesting, at least 1 cm each in the anterior and dorsal septum were preserved, insuring adequate septal support. When cephalic trimming was performed for alar contouring, 5–6 mm of the lateral crurae of LLC were preserved bilaterally in female and male patients, respectively. This ensured adequate external nasal valve function. Additionally, tip sheen grafting was performed in 25 of the included 27 patients, ensuring added support, more projection, and more definition, thereby maintaining and restoring the major and minor tip support mechanisms. Nasal valve obstruction was prevented by LLC alar contour grafting in 10 cases and by adding a supporting alar rim graft in the remaining two cases. Postoperative strapping for 1 week, then

night strapping for an extra month is helpful to splint the tip rotation, and to decrease the postoperative edema encountered in the open rhinoplasty technique as well as with skin undermining.

In the current study, the NLA was used to measure the degree of rotation and compare the pre and postoperative results. According to Bryan et al, the ideal nasolabial angle was  $95.96 \pm 2.57$  degrees with a range of 93.3–98.5 for men, whereas in women, the SD was  $97.79 \pm 2.32$  degrees, ranging from 95.5 to 100.1 degrees. However, this preference varies according to ethnicity, sex, and age.<sup>24</sup> Postoperative NLA results were also compared with the ideal range.

The columellar-facial angle, as an alternative to NLA, which aims to abolish the metrics resulting from the anatomical variants of facial features, was also used as an alternative for nasal tip measurements in the course of this study. It was proved that the measurements correlated, as both techniques utilize the same horizontal variant (line from the anterior columella to the subnasale). However, the NLA is a more popular measure and was most commonly used as the latter lacked the true soft tissue (labial) component, hence used for comparison in the study.<sup>7</sup>

Addressing all elements of the tip is the key for a successful and reproducible rhinoplasty surgery. Although many techniques were described to rotate the tip, it is not mandatory to do them all in each individual to achieve the final outcome.

A newly positioned tip will be subjected to unpredictable forces generated by scar tissue contraction following surgery; hence, securing every step can help ensure a more stable predictable outcome. However, a 1-year follow-up period is mandatory in all cases for the final evaluation of the outcome.

## CONCLUSIONS

Rotating the tip in long noses is a complex procedure. It can be achieved by many described techniques that should not be carried out all at once. Certain strategies should be followed, including variable techniques with variable efficacy. The tripod concept and the cantilevered spring tripod model are both of extreme value while rotating the tip in long noses, as both the medial and lateral crurae of both LLC share in the formation of tip rotation degree. Therefore, all elements of both LLC should be addressed while tip rotation is carried out. The current study aimed at providing a strategy using techniques previously mentioned in the literature; however, grouping them allowed for a more systematic approach.

**Rasha Abdelkader, MD**

Department of Plastic Surgery  
Faculty of Medicine Cairo University  
38 Mohi Eldin Abou Elezz St. Mohandessin  
Cairo 12511 Egypt  
E-mail: rasha.abdelkader@gmail.com

## PATIENT CONSENT

*Patients provided written consent for the use of their images.*

# REFERENCES

1. Saltz R. The international study on aesthetic/cosmetic procedures performed in 2016. ISAPS 2016. Available at: <https://www.isaps.org/wp-content/uploads/2017/10/GlobalStatistics2016-1.pdf>. Accessed May 26, 2021.
2. Ghavami A, Janis JE, Acikel C, et al. Tip shaping in primary rhinoplasty: an algorithmic approach. *Plast Reconstr Surg*. 2008;122:1229–1241.
3. Daniel RK, Palhazi P. The nasal ligaments and tip support in rhinoplasty: an anatomical study. *Aesthet Surg J*. 2018;38:357–368.
4. Anderson JR. A reasoned approach to nasal base surgery. *Arch Otolaryngol*. 1984;110:349–358.
5. Westreich RW, Lawson W. The tripod theory of nasal tip support revisited: the cantilevered spring model. *Arch Facial Plast Surg*. 2008;10:170–179.
6. Armijo BS, Brown M, Guyuron B. Defining the ideal nasolabial angle. *Plast Reconstr Surg*. 2012;129:759–764.
7. Kim DW, Egan KK. Metrics of nasal tip rotation: a comparative analysis. *Laryngoscope*. 2006;116:872–877.
8. Benlier E, Top H, Aygit AC. Management of the long nose: review of techniques for nasal tip supporting structures. *Aesthetic Plast Surg*. 2006;30:159–168.
9. Nagarkar P, Stark RY, Pezeshk RA, et al. Role of the cephalic trim in modern rhinoplasty. *Plast Reconstr Surg*. 2016;137:89–96.
10. Rohrich RJ, Hoxworth RE, Kurkjian TJ. The role of the columellar strut in rhinoplasty: indications and rationale. *Plast Reconstr Surg*. 2012;129:118e–125e.
11. Rohrich RJ, Kurkjian TJ, Hoxworth RE, et al. The effect of the columellar strut graft on nasal tip position in primary rhinoplasty. *Plast Reconstr Surg*. 2012;130:926–932.
12. Bitik O, Uzun H, Kamburoğlu HO, et al. Revisiting the role of columellar strut graft in primary open approach rhinoplasty. *Plast Reconstr Surg*. 2015;135:987–997.
13. Santareno S, Taş S. Concept of anatomic columellar strut grafting in rhinoplasty: an algorithmic approach. *Aesthet Surg J*. 2020;40:NP65–NP71.
14. Cingi C, Bayar Muluk N, Winkler A, et al. Nasal tip grafts. *J Craniofac Surg*. 2018;29:1914–1921.
15. Byrd HS, Andochick S, Copit S, et al. Septal extension grafts: a method of controlling tip projection shape. *Plast Reconstr Surg*. 1997;100:999–1010.
16. Sawh-Martinez R, Perkins K, Madari S, et al. Control of nasal tip position: quantitative assessment of columellar strut versus caudal septal extension graft. *Plast Reconstr Surg*. 2019;144:772e–780e.
17. Rohrich RJ, Durand PD, Dayan E. Changing role of septal extension versus columellar grafts in modern rhinoplasty. *Plast Reconstr Surg*. 2020;145:927e–931e.
18. Toriumi DM. Caudal septal extension graft for correction of the retracted columella. *Oper Tech Otolaryngol Head Neck Surg*. 1995;6:311–318.
19. Shah A, Pfaff M, Kinsman G, et al. Alar-columellar and lateral nostril changes following tongue-in-groove rhinoplasty. *Aesthetic Plast Surg*. 2015;39:191–198.
20. Spataro EA, Most SP. Tongue-in-groove technique for rhinoplasty: technical refinements and considerations. *Facial Plast Surg*. 2018;34:529–538.
21. Kridel RW, Scott BA, Foda HM. The tongue-in-groove technique in septorhinoplasty. A 10-year experience. *Arch Facial Plast Surg*. 1999;1:246–56; discussion 257.
22. Foda HM. Alar setback technique: a controlled method of nasal tip deprojection. *Arch Otolaryngol Head Neck Surg*. 2001;127:1341–1346.
23. Rohrich RJ, Raniere J Jr, Ha RY. The alar contour graft: correction and prevention of alar rim deformities in rhinoplasty. *Plast Reconstr Surg*. 2002;109:2495–505; discussion 2506.
24. Cárdenas JC, Carvajal J, Ruiz A. Securing nasal tip rotation through suspension suture technique. *Plast Reconstr Surg*. 2006;117:1750–5; discussion 1756.
25. Daniel RK. Rhinoplasty: a simplified, three-stitch, open tip suture technique. Part I: primary rhinoplasty. *Plast Reconstr Surg*. 1999;103:1491–1502.