

Received: 2018.11.30
Accepted: 2018.12.27
Published: 2019.03.25

A Case of Lymphangioliomyomatosis (LAM) of the Lung in a Patient with a History of Breast Cancer

Authors' Contribution:
Study Design A
Data Collection B
Statistical Analysis C
Data Interpretation D
Manuscript Preparation E
Literature Search F
Funds Collection G

ABCDEF 1 **Sinem Koc-Günel**
A 1 **Nesrin Tekeli**
D 1 **Christina Smaczny**
DE 2 **Thomas Vogl**
CDE 1 **Gernot Rohde**

1 Medical Clinic 1, Department of Respiratory Medicine and Allergology, Goethe University Hospital, Frankfurt am Main, Germany
2 Department of Diagnostic and Interventional Radiology, Goethe University Hospital, Frankfurt am Main, Germany

Corresponding Author: Sinem Koc-Günel, e-mail: sinem.koc-guenel@kgu.de
Conflict of interest: None declared

Patient: Female, 47
Final Diagnosis: Lymphangioliomyomatosis
Symptoms: Dyspnea
Medication: —
Clinical Procedure: —
Specialty: Pulmonology





Objective: Rare disease
Background: Lymphangioliomyomatosis (LAM) is a rare progressive cystic and nodular disease of the lung characterized by smooth muscle cell proliferation. LAM predominantly affects young premenopausal women. This report is of a case of LAM presenting in a 47-year-old woman with a past history of breast cancer and discusses the possibility of an association between the two conditions.

Case Report: A 47-year-old woman presented as an emergency with an exacerbation of a four-month history of shortness of breath and dry cough. Her symptoms began following the start of anti-hormonal treatment with letrozole and goserelin acetate for a moderately differentiated (grade 2) invasive ductal carcinoma of the breast (pT2, pN0, M0) which was positive for expression of estrogen receptor (ER+), progesterone receptor (PR+), and human epidermal growth factor receptor 2 (HER2+). Until the previous four months, she had breast-conserving treatment with radiotherapy and tamoxifen therapy. Following hospital admission, she was found to be in type I respiratory failure. Chest X-ray, lung computed tomography (CT), and positron-emission tomography (PET) showed diffuse cystic and nodular lung lesions, consistent with a diagnosis of LAM, and anti-hormonal therapy was discontinued. She developed pericarditis that was treated with the anti-inflammatory agent, colchicine. Treatment with letrozole and sirolimus improved her respiratory symptoms.

Conclusions: A rare case of LAM is presented in a woman with a recent history of breast cancer. Because both tumors were hormone-dependent, this may support common underlying gene associations and signaling pathways between the two types of tumor.

MeSH Keywords: Aromatase Inhibitors • Carcinoma, Ductal, Breast • Colchicum • Estrogen Receptor Modulators • Goserelin • Lymphangioliomyomatosis

Full-text PDF: <https://www.amjcaserep.com/abstract/index/idArt/914355>

 1416   1  13



Background

Lymphangioliomyomatosis (LAM) is a rare progressive cystic and nodular disease of the lung characterized by perivascular and peribronchial smooth muscle cell proliferation. LAM predominantly affects young premenopausal women around 35 years of age and affects between 3.3 to 7.4 per million women, worldwide [1]. Patients present clinically with cough, shortness of breath, and with unilateral or bilateral pneumothorax, hemoptysis, pleural effusions, chylothorax and emphysema [2]. LAM is a benign but progressive tumor that belongs to the group of proliferative lesions termed perivascular epithelioid cell tumors (PEComas) [3]. The LAM cells can appear to be atypical histologically and they express high levels of estrogen and progesterone receptors on their surface, consistent with hormonal dependence [4].

It has previously been reported that estrogen promotes the activation of matrix metalloproteinase (MMP) through activation of estrogen receptors to enhance the progression of LAM throughout the lung [5]. Estrogen-driven disease progression also occurs in breast cancer. Anti-estrogen therapy with aromatase inhibitors is an established therapy for LAM, depending on estrogen receptor (ER) status. However, the shared molecular and signaling pathways between ER-positive breast cancer and LAM remain unknown. This report is of a case of LAM presenting in a 47-year-old woman with a past history of breast cancer and discusses the possibility of an association between the two conditions.

Case Report

A 47-year-old woman, with a previous history of invasive ductal carcinoma of the breast, presented to the emergency room with worsening shortness of breath and dry cough during the past four months. The patient reported having noticed progressive dyspnea since she began antihormonal medication with letrozole and goserelin acetate in the four months prior to hospital admission.

In 2015, she had been diagnosed with a moderately differentiated (grade 2) ductal carcinoma of the right breast (pT2, pN0, M0) which was positive for the expression of estrogen receptor (ER+), progesterone receptor (PR+), and human epidermal growth factor receptor 2 (HER2+) using immunohistochemistry of the tumor tissue samples. The patient had initially undergone breast-preserving treatment followed by radiotherapy and tamoxifen therapy until five months prior to admission. The patient was then found to have a recurrence of her breast cancer with bone metastasis. Metastatic breast cancer was ER+, PR+, and HER2+ using immunohistochemistry and was treated with letrozole and goserelin acetate. Also, this patient

reported having had a previous history of angiomyolipoma of the left kidney, which was surgically removed 19 years previously, and a history of asthma during childhood. She denied cigarette smoking. She had two pregnancies, the last one being eight years before admission, without any complications.

Clinical examination at the recent hospital admission showed normal blood pressure and heart rate and a temperature of 38°C. Laboratory results did not show any relevant findings. Arterial blood gas analysis showed type 1 respiratory failure with a partial pressure of oxygen (pO₂) of 64.7 and a pCO₂ of 39.0. Her pulmonary function tests showed a forced vital capacity (FVC) of 2.52 L (68% of predicted value), forced expiratory volume in 1 second (FEV1) of 0.72 L (24% of predicted value), FEV1/FVC ratio or Tiffeneau-Pinelli index of 28.52, residual volume (RV) of 1.29L (74% of predicted value), and total lung capacity (TLC) of 3.81 L (74% of predicted value).

Chest X-ray showed diffuse bilateral reticular lung opacities (Figure 1A). Chest computed tomography (CT) imaging showed numerous thin-walled cysts within the lungs and diffuse ground-glass lung opacities, consistent with the diagnosis of lymphangioliomyomatosis (LAM) (Figure 1B, 1C). The CT scan showed a mild pericardial effusion. The CT imaging findings were supported by positron-emission tomography (PET) imaging. Fludeoxyglucose positron-emission tomography (FDG-PET) of the lungs did not show FDG uptake in the lung parenchyma, which excluded a diagnosis of lymphangitis carcinomatosa.

From the findings of the clinical history, lung function tests, and imaging findings, a diagnosis of LAM was made. A confirmatory lung biopsy was not undertaken as the FDG-PET imaging appeared to exclude metastatic breast cancer or lymphangitic carcinomatosa. The patient was initially treated with oxygen therapy. She developed acute pericarditis and was treated with colchicine. Anti-hormonal therapy with letrozole and goserelin acetate was discontinued. Treatment with letrozole and sirolimus improved her respiratory symptoms.

The patient underwent five weeks of outpatient clinical follow-up to evaluate her response to therapy. Pulmonary function tests and arterial blood gas analysis at five-week follow-up showed a mild improvement of respiratory function. Treatment continued with sirolimus, letrozole, and colchicine. Although currently, little is known about combined therapy with letrozole and sirolimus in LAM, a synergistic effect is anticipated. The patient will continue outpatient follow-up in three months for evaluation of the effects of treatment, including pulmonary function testing and diffusing capacity or transfer factor of the lung for carbon monoxide (DLCO) and a six-minute walking test. Follow-up lung CT imaging is planned in six months.

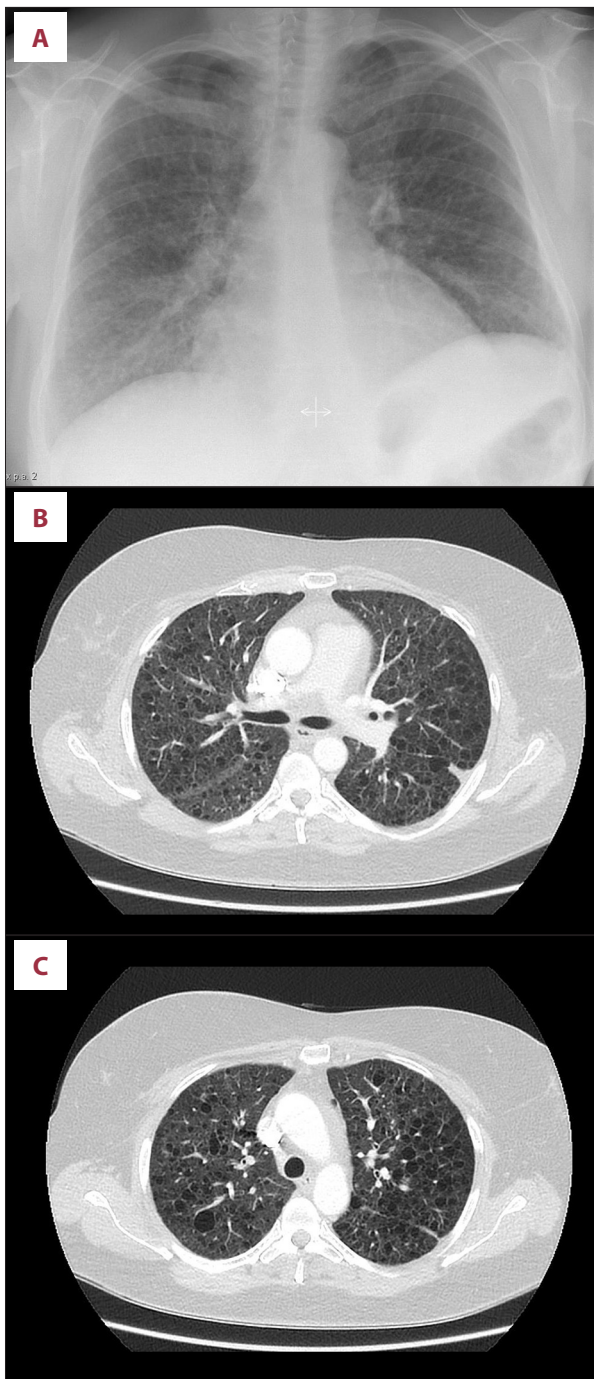


Figure 1. Chest X-ray and computed tomography (CT) images of the lung in a 47-year-old female patient with lymphangioleiomyomatosis (LAM). (A) Chest X-ray shows diffuse reticular opacities throughout both lungs. (B, C). Computed tomography (CT) scan shows numerous thin-walled cysts within the lungs and diffuse ground-glass opacities, characteristic for lymphangioleiomyomatosis (LAM).

Discussion

There have been few previously reported cases or studies on the incidence of breast cancer in patients with lymphangioleiomyomatosis (LAM). In 2016, Nunez et al. analyzed the incidence of three patient cohorts with LAM from three different countries and identified an increased risk of breast cancer in these patient populations [6]. The patient in this case report had a previous diagnosis of angiomyolipoma 19 years previously, but the relevance of this is unclear. She also had a history of asthma, which can be a differential diagnosis for LAM on initial presentation. It is likely the patient had LAM before her diagnosis of breast cancer.

LAM has been reported to progress under the influence of estrogen, including during pregnancy, and stabilizes in post-menopausal women [7]. The exacerbation of pulmonary symptoms that resulted in acute hospital admission in this case could be multifactorial. The patient had a history of two previous pregnancies, but, most importantly she was treated with anti-hormonal therapy that included tamoxifen, the aromatase inhibitor, letrozole, and goserelin acetate, a luteinizing hormone-releasing hormone (LHRH) analog. The data regarding the effects of anti-estrogenic therapy in LAM is currently conflicting. While Yu et al. showed promotion of cell growth following anti-estrogen therapy with tamoxifen [8], treatment with aromatase inhibitors, including letrozole, have been shown to be beneficial [9]. However, since the study data for letrozole is based on small studies, there remain no clear clinical guidelines on the use of letrozole in the treatment of LAM, which might result in worsening of the symptoms. Regarding cell growth in patients with LAM, tamoxifen treatment seems more likely to cause adverse effects, as tamoxifen has been shown to promote cell growth in angiomyolipoma [8]. There have been few studies that have investigated the effects of treatment with gonadotrophin-releasing hormone (GnRH) analogs in patients with LAM [10]. However, in this reported case, no lung biopsy material was available for cell and tissue analysis of hormone receptor status, including estrogen and progesterone on the surface of the LAM cells, which might have resulted in a more individualized approach to anti-hormonal therapy.

The double-blind, randomized, controlled clinical MILES trial investigated the efficiency of sirolimus, an mTOR-inhibitor, in patients with LAM and showed stabilization or improvement of lung function [11]. Sirolimus treatment for 12 months in patients with loss of lung function (FEV1 <70%) resulted in improvement in forced vital capacity (FVC) and stabilization of FEV1 compared with the placebo group [11]. Sirolimus is now recommended by the American Thoracic Society (ATS) for the treatment of patients with LAM [12]. The patient described in this case report was treated with sirolimus according to the ATS guidelines [12].

Colchicine therapy might have beneficial effects on LAM as the tumor cells have been shown to secrete large amounts of interleukin 6 (IL-6), and colchicine is an anti-inflammatory drug that reduces IL-6 levels [13]. In this reported case, colchicine treatment reduced the patient's respiratory symptoms, including symptoms of dyspnea, which might have been due to the effects of colchicine on pericarditis-induced cardiogenic dyspnea.

Conclusions

This case report has highlighted that, although rare, a history of breast cancer can be associated with lymphangioleiomyomatosis (LAM). The incidence, hormone-dependence,

and progression of both diseases suggest common molecular and signaling pathways, which require further investigation. This case report highlights that clinicians should be aware of the possible diagnosis of LAM in the differential diagnosis in patients with progressive shortness of breath and a history of breast cancer, and also supports monitoring of patients with LAM during antihormonal therapy for breast cancer. Radiologists who diagnose LAM on computed tomography (CT) should be aware of the association with breast cancer.

Acknowledgments

The authors thank Dr. Michael Jergas who provided the images of the computed tomography (CT) scans of the patient.

References:

1. Johnson SR, Tattersfield AE: Clinical experience of lymphangioleiomyomatosis in the UK. *Thorax*, 2000; 55(12): 1052–57
2. Kitaichi M, Nishimura K, Itoh H, Izumi T: Pulmonary lymphangioleiomyomatosis: A report of 46 patients including a clinicopathologic study of prognostic factors. *Am J Respir Crit Care Med*, 1995; 151(2 Pt 1): 527–33
3. Zhe X, Schuger L: Combined smooth muscle and melanocytic differentiation in lymphangioleiomyomatosis. *J Histochem Cytochem*, 2004; 52(12): 1537–42
4. Grzegorek I, Lenze D, Chabowski M et al: Immunohistochemical evaluation of pulmonary lymphangioleiomyomatosis. *Anticancer Res*, 2015; 35(6): 3353–60
5. Glassberg MK, Elliot SJ, Fritz J et al: Activation of the estrogen receptor contributes to the progression of pulmonary lymphangioleiomyomatosis via matrix metalloproteinase-induced cell invasiveness. *J Clin Endocrinol Metab*, 2008; 93(5): 1625–33
6. Nunez O, Roman A, Johnson SR et al: Study of breast cancer incidence in patients of lymphangioleiomyomatosis. *Breast Cancer Res Treat*, 2016; 156(1): 195–201
7. Johnson SR, Tattersfield AE: Decline in lung function in lymphangioleiomyomatosis: Relation to menopause and progesterone treatment. *Am J Respir Crit Care Med*, 1999; 160(2): 628–33
8. Yu J, Astrinidis A, Howard S, Henske EP: Estradiol and tamoxifen stimulate LAM-associated angiomyolipoma cell growth and activate both genomic and nongenomic signaling pathways. *Am J Physiol Lung Cell Mol Physiol*, 2004; 286(4): L694–700
9. Lu C, Lee HS, Pappas GP et al: A phase ii clinical trial of an aromatase inhibitor for postmenopausal women with lymphangioleiomyomatosis. *Ann Am Thorac Soc*, 2017; 14(6): 919–28
10. Harari S, Cassandro R, Chiodini I et al: Effect of a gonadotrophin-releasing hormone analogue on lung function in lymphangioleiomyomatosis. *Chest*, 2008; 133(2): 448–54
11. McCormack FX, Inoue Y, Moss J et al., National Institutes of Health Rare Lung Diseases Consortium, MILES Trial Group: Efficacy and safety of sirolimus in lymphangioleiomyomatosis. *N Engl J Med*, 2011; 364(17): 1595–606
12. Feemster LC, Lyons PG, Chatterjee RS et al: Summary for clinicians: Lymphangioleiomyomatosis diagnosis and management clinical practice guideline. *Ann Am Thorac Soc*, 2017; 14(7): 1073–75
13. Entzian P, Schlaak M, Seitzer U et al: Anti-inflammatory and antifibrotic properties of colchicine: Implications for idiopathic pulmonary fibrosis. *Lung*, 1997; 175(1): 41–51