

Trapeziectomy and Abductor Pollicis Longus Suspensionplasty Combined with Extensor Pollicis Brevis Tenodesis for Management of Thumb Basal Joint Osteoarthritis and Metacarpophalangeal Hyperextension

Mohamed Maklad¹  Ravi Mallina¹ Tommy R. Lindau¹

¹Pulvertaft Hand Centre, Derby, United Kingdom

Address for correspondence Tommy R. Lindau, MD, PhD, Pulvertaft Hand Centre, Derby DE22 3NE, United Kingdom (e-mail: tommylindau@hotmail.com).

J Hand Microsurg 2021;13:114–118.

Abstract

Metacarpal joint hyperextension is common cause of postoperative dissatisfaction after trapeziectomy in the management of basal thumb osteoarthritis. The senior author uses this technique to address this biomechanical problem at the time of trapeziectomy.

Keywords

- ▶ basal thumb arthritis
- ▶ trapezectomy
- ▶ EPB tenodesis

Introduction

Osteoarthritis of the basal joint of the thumb, most known as trapeziometacarpal joint (TMCJ), although first carpometacarpal joint (CMCJ) is also frequently used, is the second commonest site of hand osteoarthritis after distal interphalangeal joint. In its global form, the scaphotrapeziotrapezoid joint (STTJ) is also involved. With advanced arthritis at the basal joint and instability due to ligament laxity, deformity with subluxation of the joint can happen by the pull of the abductor pollicis longus (APL) muscle.

As a compensatory mechanism, the adductor pollicis and first dorsal interosseus muscle try to stabilize the base of the first metacarpal. This will lead to narrowing of the first web space and subsequent weakness of the pinch grip. To maintain the pinch function, the metacarpophalangeal joint (MCPJ) hyperextends to increase the thumb span and improve the pinch function (▶**Fig. 1**). This has to be carefully assessed at the time of clinical consultation (▶**Fig. 1**) as it may require concomitant procedures during trapeziectomy. Missed MCPJ hyperextension beyond 30 degrees can lead to substantial drop of the thumb and overall hand function. Trapeziectomy is the standard surgical technique for advanced arthritis of the basal joint of the thumb.¹ Trapeziectomy can be done in isolation but is most often combined with different

techniques to fill the trapeziectomy void and to suspend the first metacarpal with a ligament reconstruction and tendon interposition (LRTI) or other known suspensionplasty techniques such as APL hammock to prevent first metacarpal collapse in the short-to-intermediate period following surgery.^{2–5} Collapse of the first metacarpal can still happen later on despite early postoperative satisfaction. Hence, MCPJ hyperextension may need consideration during trapeziectomy. Different techniques have been described to correct MCPJ hyperextension including sesamoid arthrodesis,⁶ capsulodesis,⁷ extensor pollicis brevis (EPB) rerouting,⁸ and MCPJ fusion.

We provide a technique which the senior author has been using in his clinical practice over the past 15 years, which, we believe, addresses most of the biomechanical abnormalities around a trapeziectomy.

We believe this technique has the following advantages:

1. A combined LRTI using the APL tendon reduces the destabilizing forces at the TMCJ.
2. The APL slip used in our technique acts as a “hammock” around the base of the metacarpal preventing telescoping of the metacarpal base into the trapeziectomy void.
3. Tenodesis of the EPB to the TMCJ capsule reduces the forces leading to protects against MCPJ hyperextension.

published online
June 22, 2020

© 2020. Society of Indian Hand & Microsurgeons. All rights reserved.
Thieme Medical and Scientific Publishers Pvt. Ltd., A-12, 2nd Floor, Sector 2, Noida-201301 UP, India

DOI <https://doi.org/10.1055/s-0040-1713584>
ISSN 0974-3227.

This leaves the extensor pollicis longus tendon for extension of the thumb at both MCP and IP joints.

4. Decompression of both APL and EPB tendons in the first extensor compartment resolves any secondary De Quervain tendinitis that may develop as part of the altered biomechanical load at the base of thumb.⁹

Surgical Technique

The procedure is performed under regional ultrasound-guided supraclavicular anesthesia as a day case. An upper arm tourniquet is used. Skin incision is longitudinally marked from the radial styloid to the first metacarpal base (►Fig. 2). The radial artery is identified as it crosses from volar to dorsal defining the level of the STTJ (►Fig. 3). Adequate mobilization of the radial artery prevents any potential iatrogenic injury during elevation of a capsular flap and excision of the trapezium. A distally based periosteum-capsular TMCJ flap is raised visualizing both the STTJ and TMCJ; trapezium is removed exposing the flexor carpi radialis (FCR) tendon (►Fig. 4). One should take adequate care to clear any residual osteophytes around the FCR tendon without causing any injury to the tendon. By pulling the index finger and metacarpal, the STTJ can be visualized to rule out any scaphotrapezoid arthritis and if present, the proximal trapezoid may be excised as part of the trapeziectomy (►Fig. 5). One should be able to visualize the capitate at the base of the wound following successful

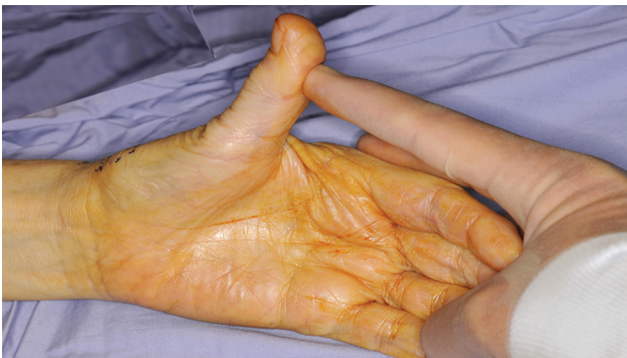

Fig. 1 Passive movement of thumb demonstrates hyperextension of the thumb metacarpophalangeal joint.

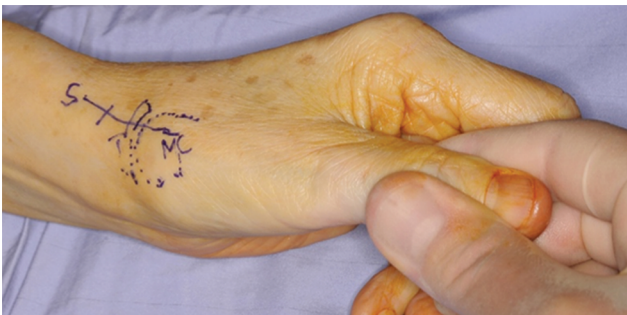

Fig. 2 Surface anatomy of the trapeziometacarpal joint demonstrating longitudinal skin incision from the radial styloid (S) across the trapezium (T) ending at the proximal end of the first metacarpal (MC).

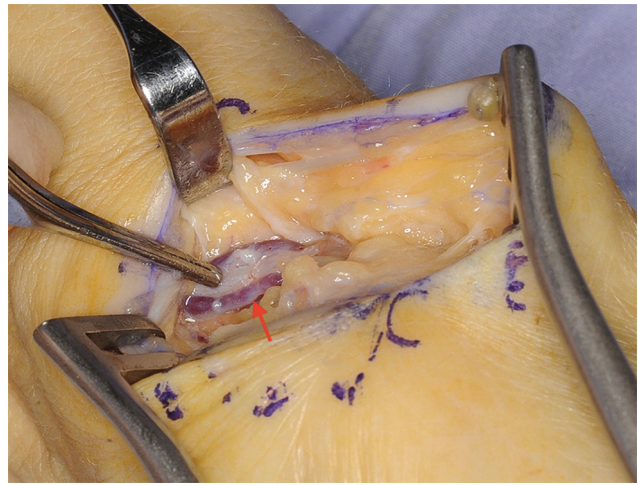


Fig. 3 Dissection of radial artery (at tip of Adson pickup forceps) with venae comitantes (red arrow) running across the wound from volar to dorsal direction (thumb toward lower right quadrant).

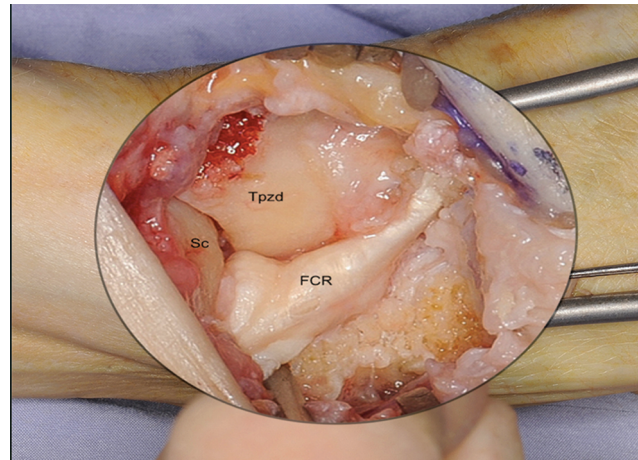


Fig. 4 Flexor carpi radialis (FCR) at the base of the wound following trapeziectomy; scaphoid (Sc) and trapezoid (Tpzd) seen abutting the FCR (thumb toward right).

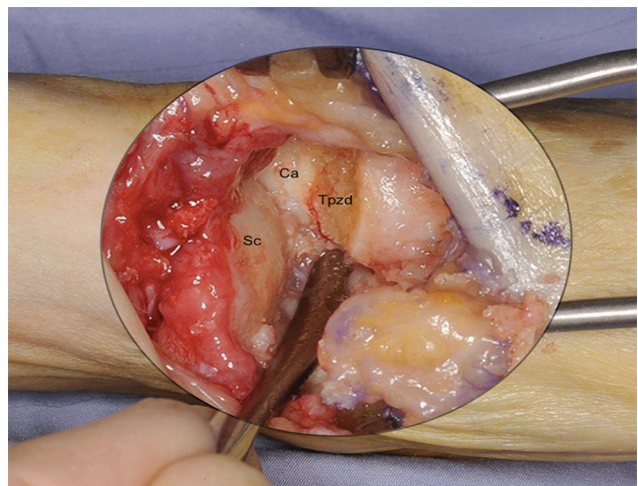


Fig. 5 Excision of proximal trapezoid (Tpzd) due to scaphotrapeziotrapezoid joint osteoarthritis as seen on the distal pole of the scaphoid (Sc). Note that the capitate (Ca) can be seen in the floor of the wound following successful excision of proximal trapezoid (thumb toward right).

resection of the proximal trapezoid (►Fig. 5). The adequacy of the resection can be verified by the absence of trapezoid–scaphoid abutment on passive dart-throwing motion of the wrist.

The first dorsal compartment is incised and the APL and EPB tendons are identified. EPB tendon is confirmed by passive movement of the tendon and checking for the position of thumb MCPJ. A slip of APL is divided proximal in the first extensor compartment and incised into two halves, which are traced distally to the level of insertion of APL at the metacarpal base (►Fig. 6). One slip is used to reinforce the volar beak ligament thereby creating a “hammock” around the metacarpal base running from dorsal radial to volar ulnar (►Figs. 7 and 8). One has to position the thumb in maximum abduction and extension when creating this hammock-like structure around the thumb metacarpal base. The other APL slip is passed through the FCR for interposition and suspension plasty (►Fig. 9). Once passed through the FCR, this second half of APL slip is advanced

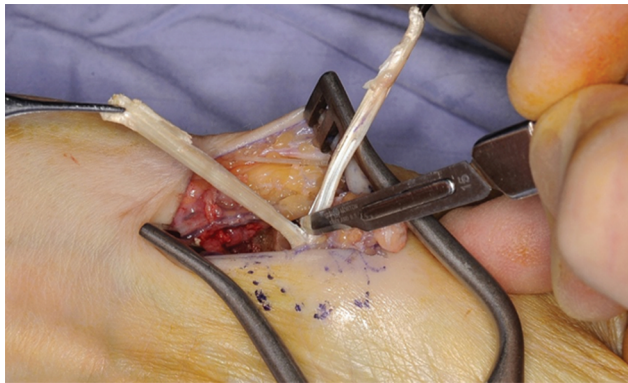


Fig. 6 Dividing a slip of abductor pollicis longus into two halves (thumb toward lower right quadrant).

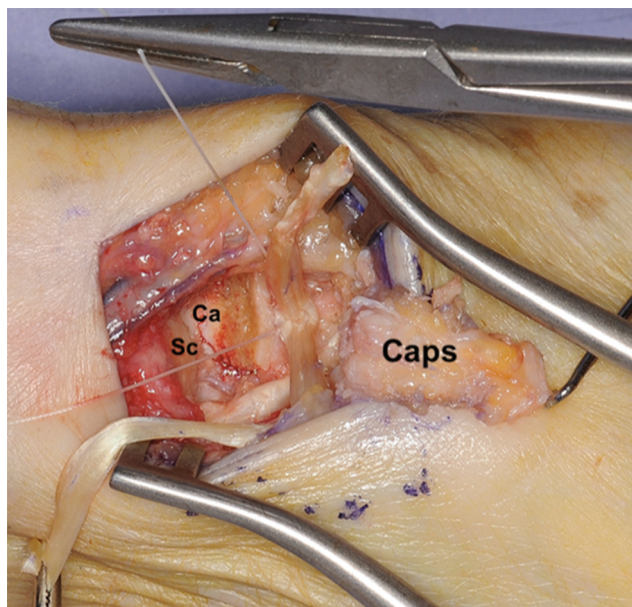


Fig. 7 Reinforcing the half of abductor pollicis longus slip over the volar oblique ligament using 3-0 Ethibond. Ca, capitate; Caps, capsule; Sc, scaphoid (thumb toward right).

from the undersurface of the periosteum–capsular flap along its radial part (►Fig. 10) and down again ulnarly through the periosteum–capsular flap. This slip of the APL is secured within the periosteum–capsular flap, with the thumb in maximum abduction and extension, using a 3-0 Ethibond suture. The redundant ends of both halves of APL slips are interposed in the trapeziectomy void.

The TMCJ periosteum–capsular flap is closed with 4/0 Vicryl. The EPB tendon is then sutured to the dorsal capsule of the TMCJ by 4/0 Vicryl, usually two sutures with adequate tension to achieve functional MCPJ position in slight flexion (►Fig. 11). If adequately tensioned, the absence of MCPJ hyperextension is noted on passive movement of the

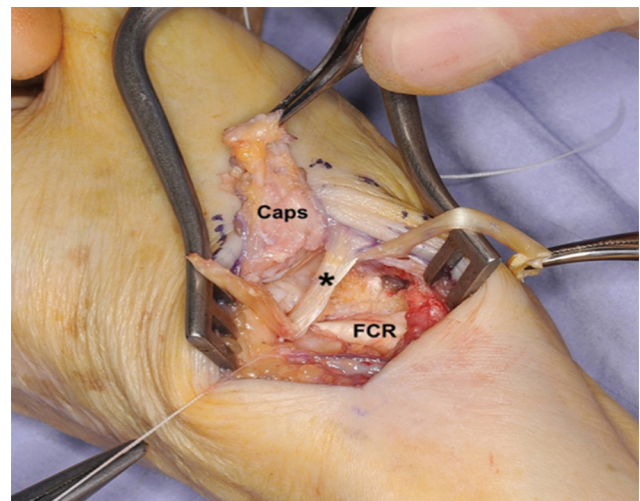


Fig. 8 Creation of hammock (*) by suturing the half of the abductor pollicis longus (*) to the volar oblique ligament, preventing telescoping of metacarpal base into the void created by trapeziectomy. Caps, distally based capsular flap; FCR, flexor carpi radialis (thumb toward upper left quadrant).

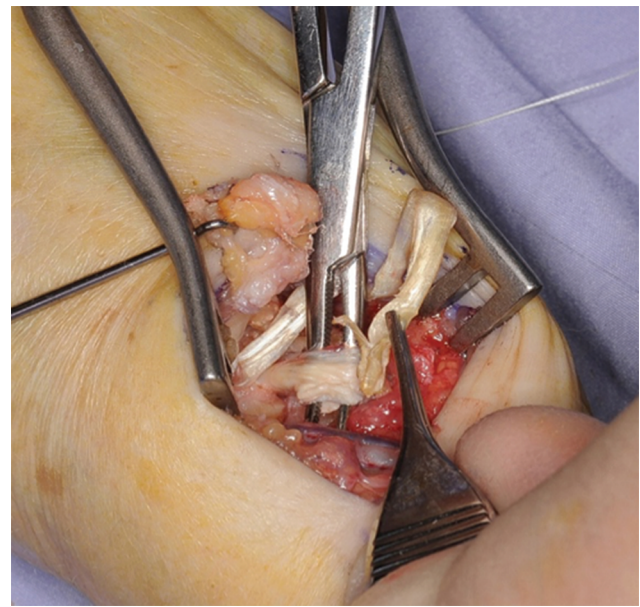


Fig. 9 Longitudinal incision through the flexor carpi radialis (FCR) and passing of the second half of abductor pollicis longus slip through the FCR tendon (thumb toward upper left quadrant).

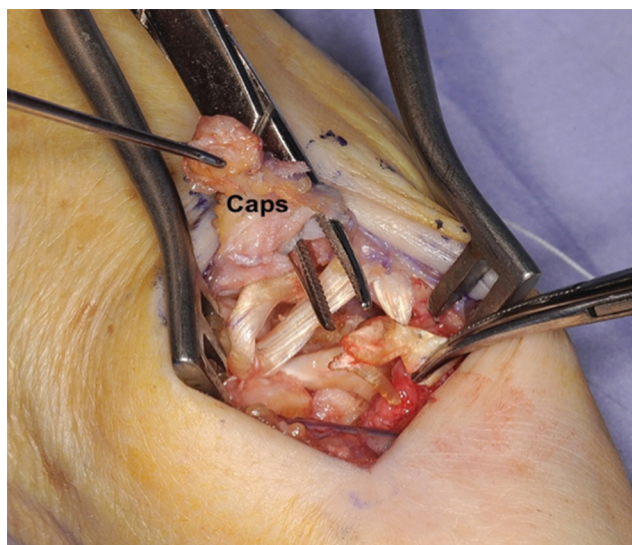


Fig. 10 Passing the second slip of abductor pollicis longus tendon from the undersurface of the capsule up dorsally (shown) and back down to the undersurface of the capsule (not shown), securing it to the capsule using 3-0 Ethibond. Caps, distally based capsular flap (thumb toward upper left quadrant).

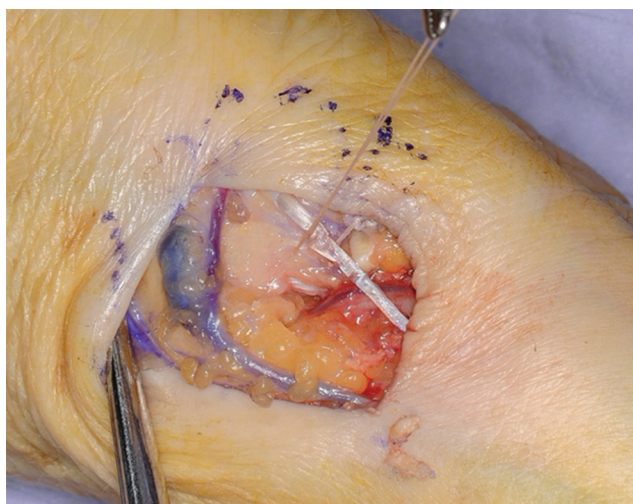

Fig. 11 Tenodesis of the extensor pollicis brevis tendon to the capsule and closure of the capsule and using 4/0 Vicryl.

EPB tendon proximal to the tenodesis without compromise on the MCP flexion (► **Fig. 12**). The skin is closed. The position of the thumb achieved during surgery is supported and protected by nonadhesive dressing and plaster of Paris for 2 weeks (► **Fig. 13**).

Discussion

The main reason to use suspensionplasty technique is to avoid telescoping of the thumb resulting in impingement between the first metacarpal and the distal pole of the scaphoid, potentially leading to scaphometacarpal arthritis. Collapse of the first metacarpal can also lead to MCPJ hyperextension as the EPB further aggravates the deformity caused by the relative shortening of the thumb which subsequently decreases thumb pinch strength. Although recent

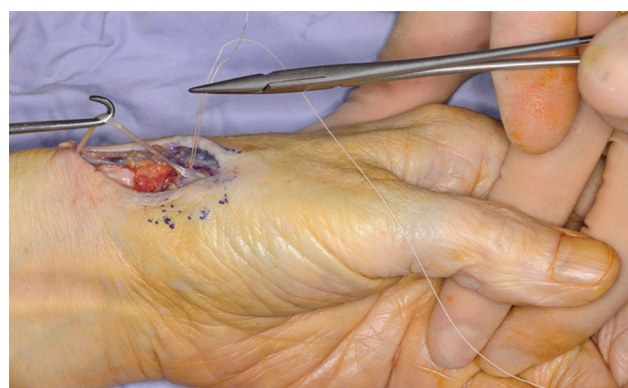

Fig. 12 Absence of thumb metacarpophalangeal joint hyperextension following extensor pollicis brevis capsular tenodesis.

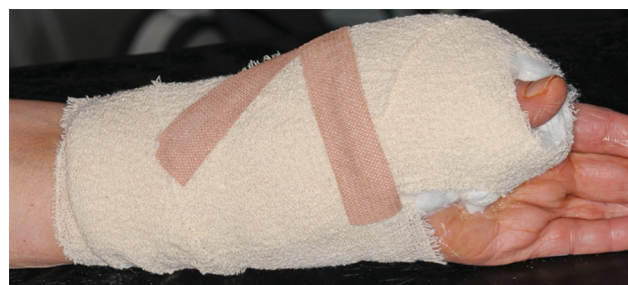

Fig. 13 Application of plaster of Paris slab with the thumb in extension and abduction leaving the thumb interphalangeal joint free.

reports have not shown that this is the case after trapeziectomy alone,⁹ we find that this is one factor that actually can be addressed at the time of surgery without adding significant morbidity, simultaneously addressing all relevant pathomechanics across the basal joint of the thumb.

Technical Pearls and Pitfall

We believe the following are the key technical aspects performing trapeziectomy using our current technique. In fact, some of these steps are useful performing trapeziectomy using any of the techniques described in the literature.

1. Careful assessment of the presence of thumb MCPJ hyperextension preoperatively.
2. Meticulous dissection in the subcutaneous plane avoiding injury to the superficial branches of radial nerve.¹⁰
3. Dissection of the radial artery all along the wound rendering it fully mobile. First, this defines the plane of the STTJ, which is the start of the distally based periosteum-capsular flap. Second, it secures hemostasis throughout the procedure.
4. Raise a good-quality broad distally based periosteum-capsular flap, avoiding inadvertent "buttonholing" of the flap; the broader the flap, the easier it is to visualize the whole STTJ and TMJ.
5. In case of associated STTJ arthrosis, resect the proximal trapezoid.
6. EPB can occasionally run in a separate compartment or lie in a common sheath.¹¹

7. APL has multiple slips going toward the thumb metacarpal base and thenar musculature.¹² It is important that one divides the slip going to the thumb metacarpal base and not the thenar slip.
8. Adequate positioning of the thumb (abduction and extension) when reinforcing the volar oblique ligament and looping the second half of APL slip through FCR and the periosteal capsular flap.

In conclusion, we believe that although currently there are no randomized clinical trials proving our surgical technique to be superior over standard simple trapeziectomy, addressing all the potential postoperative sequelae during the index procedure in the form of APL technique described here and the EPB tenodesis could mitigate some of the potential complications.

Funding

None.

Conflict of Interest

None declared.

References

- 1 Gervis WH. Excision of the trapezium for osteoarthritis of the trapezio-metacarpal joint. *J Bone Joint Surg Br* 1949;31B(4):537–539
- 2 Conolly WB, Lanzetta M. Surgical management of arthritis of the carpo-metacarpal joint of the thumb. *Aust N Z J Surg* 1993;63(8):596–603
- 3 Brunelli G, Monini L, Brunelli F. Stabilisation of the trapezio-metacarpal joint. *J Hand Surg [Br]* 1989;14(2):209–212
- 4 Kaarela O, Raatikainen T. Abductor pollicis longus tendon interposition arthroplasty for carpometacarpal osteoarthritis of the thumb. *J Hand Surg Am* 1999;24(3):469–475
- 5 Sirotakova M, Figus A, Elliot D. A new abductor pollicis longus suspension arthroplasty. *J Hand Surg Am* 2007;32(1):12–22
- 6 Tonkin MA, Beard AJ, Kemp SJ, Eakins DF. Sesamoid arthrodesis for hyperextension of the thumb metacarpophalangeal joint. *J Hand Surg Am* 1995;20(2):334–338
- 7 Eaton RG, Floyd WE III. Thumb metacarpophalangeal capsulodesis: an adjunct procedure to basal joint arthroplasty for collapse deformity of the first ray. *J Hand Surg Am* 1988;13(3):449–453
- 8 Henry M. Extensor pollicis brevis spiral tenodesis for combined metacarpophalangeal instability and trapeziometacarpal arthritis. *Hand (N Y)* 2018;13(2):190–193
- 9 Goubau JF, Goubau L, Goorens CK, et al. De Quervain tenosynovitis following trapeziometacarpal ball-and-socket joint replacement. *J Wrist Surg* 2015;4(1):35–42
- 10 Robson AJ, See MS, Ellis H. Applied anatomy of the superficial branch of the radial nerve. *Clin Anat* 2008;21(1):38–45
- 11 Gonzalez MH, Sohlberg R, Brown A, Weinzweig N. The first dorsal extensor compartment: an anatomic study. *J Hand Surg Am* 1995;20(4):657–660
- 12 Opreanu RC, Wechter J, Tabbaa H, et al. Anatomic variations of the first extensor compartment and abductor pollicis longus tendon in trapeziometacarpal arthritis. *Hand (N Y)* 2010;5(2):184–189