

A huge ovarian mucinous cystadenoma causing virilization, preterm labor, and persistent supine hypotensive syndrome during pregnancy

Suna Kabil Kucur^a, Canan Acar^b, Osman Temizkan^b, Aysim Ozagari^b, Ilay Gozukara^a, Atif Akyol^b

Kabil Kucur S, Acar C, Temizkan O, Ozagari A, Gozukara I, Akyol A. A huge ovarian mucinous cystadenoma causing virilization, preterm labor, and persistent supine hypotensive syndrome during pregnancy. *Autopsy Case Rep* [Internet]. 2016;6(2):39-43. <http://dx.doi.org/10.4322/acr.2016.029>

ABSTRACT

Mucinous cystadenoma (MC) of the ovary is an unilateral, multilocular cystic benign epithelial tumor. Supposed to be hormone responsive, MC reaches huge sizes during pregnancy. Aortocaval compression is common during pregnancy, especially when the pregnant woman is in the supine position. However, the compression recovers with a change in position. The authors report the first case of a huge mucinous cystadenoma of the ovary complicating pregnancy and causing virilization, premature labor, and persistent supine hypotensive syndrome.

Keywords

Pregnancy; Cystadenoma; Mucinous; Ovary; Virilism; Obstetric Labor; Premature

INTRODUCTION

The incidence of ovarian tumors complicating pregnancy ranges between 1% and 2%.¹ Most of these tumors are benign, such as mature cystic teratoma and serous cystadenoma^{2,3}; however, malignancy does occur, but shows an incidence of 1/10,000-50,000.⁴ Adnexal masses are usually asymptomatic during pregnancy unless they reach large sizes. Diagnosis may be done incidentally during routine obstetric ultrasound examination. Mucinous cystadenomas (MCs) are benign epithelial tumors that can reach up to 40 cm in diameter during pregnancy.⁵ Fifteen percent of ovarian tumors are mucinous and 25% of them show a potential malignant transformation.⁶ In this report, we presented an ovarian MC that measured 27 × 30 cm at its longest axis, which

was detected during pregnancy. The tumor caused virilization, premature birth, and inferior vena cava (IVC) syndrome, but no fetal growth impairment. To the best of our knowledge, this is the first case of an ovarian MC of such size causing virilization, preterm labor, and IVC syndrome.

CASE REPORT

A 22-year-old pregnant woman (gravida 2, para 1) presented to the outpatient clinic with dyspnea, palpitation, and lower limbs edema in the 33rd gestational week. Her blood pressure was 80/40 mmHg in both the upright and the lying down

^a Department of Obstetrics and Gynecology - Faculty of Medicine - Dumlupinar University - Kütahya – Turkey.

^b Department of Obstetrics and Gynecology - Sisli Etfal & Research Hospital - Istanbul – Turkey.



positions. Her pulse rate was 130 beats per minute in the upright position and 140 beats per minute when lying down. Ultrasonography revealed an intrauterine pregnancy consistent with the gestational age, normal amniotic fluid index, and echo Doppler ultrasound findings. A multiloculated, cystic, right adnexal mass with a regular surface extending from the true pelvis to 5 cm away to the right side of xyphoid process was disclosed. Abdominal magnetic resonance images confirmed the presence of a right ovarian mass measuring 27 × 30 cm over the uterus occupying the right hemiabdomen (Figure 1A and 1B). Past medical history revealed that the patient had the diagnosis of a 7 cm right ovarian cyst in the 10th week of pregnancy. Her laboratory tests were normal except for a mild anemia (hemoglobin of 11.2 g/L; reference value: 12.0-15.5 g/L). On physical examination, signs of virilization, such as acne, oily skin, and abdominal hirsutism were present (Figure 2).

Persistent hypotension, tachycardia, and edema were attributed to the compression of the IVC caused by the mass. The patient was hospitalized, and betamethasone was administered for fetal lung maturation. After 5 days of hospitalization, the patient entered labor and an emergency laparotomy was performed since she'd had a previous caesarean section.

After a midline skin incision, a 27 cm right ovarian mass weighing 5.5 kg was observed. A lower uterine

incision was undertaken and a female infant was born with an Apgar score of 8 after the first minute, weighing 2700 g. The child had no signs of virilization. A right salpingo-oophorectomy was performed on the mother (Figure 3). Mean arterial blood pressure and pulse rate returned to normal after the operation. The patient was discharged on the sixth postoperative day. The signs of virilization faded away 3 months after the operation.

Histopathology confirmed mucinous cystadenoma with marked luteinizing stroma. Macroscopically, the cyst was multilocular with a smooth external surface. The cut surface showed multiple trabeculae but no solid areas. The maximum thickness of the cyst wall was 1.5 cm. Microscopically, the tumor was composed of glands and cysts lined by a single layer of columnar cells with abundant intracellular mucin. Cellular stratification was minimal, and nuclei were basally located without atypia. Beneath the lining epithelium and amongst the glandular structures, large polygonal cells with eosinophilic to clear cytoplasm, a central round nucleus, and a prominent nucleolus, consistent with luteinized stromal cells, were seen (Figure 4).

On immunohistochemical research, these cells were positive for vimentin and inhibin (Figure 5). Estrogen and progesterone receptors and human chorionic gonadotropin (HCG) were negative.

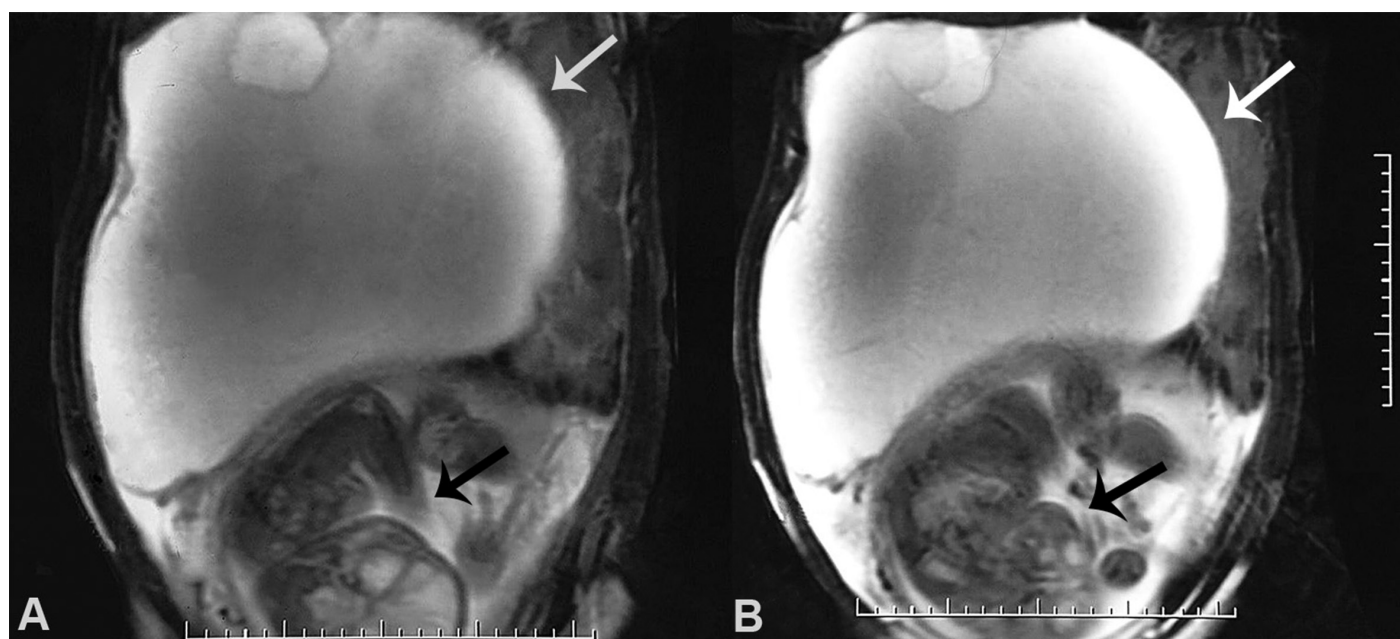


Figure 1. A and B - T2-weighted magnetic resonance imaging of the abdomen showing the gravid uterus with single fetus (black arrows), cephalic presentation and back to the right, and a voluminous cyst with apparent excrescence in the inferior aspect (white arrow).

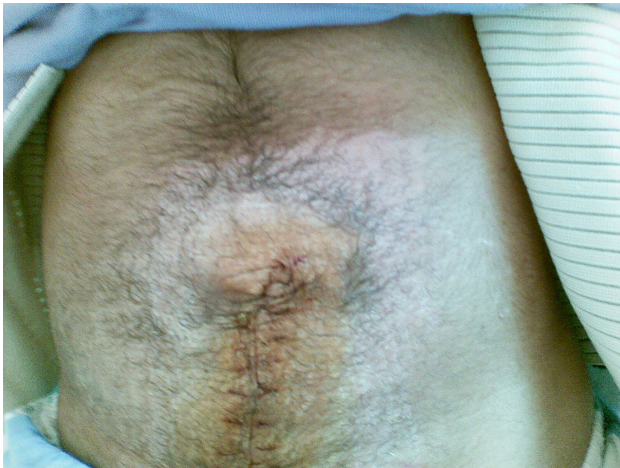


Figure 2. Postoperative macroscopic view of the hypogastric region showing the abdominal hirsutism.

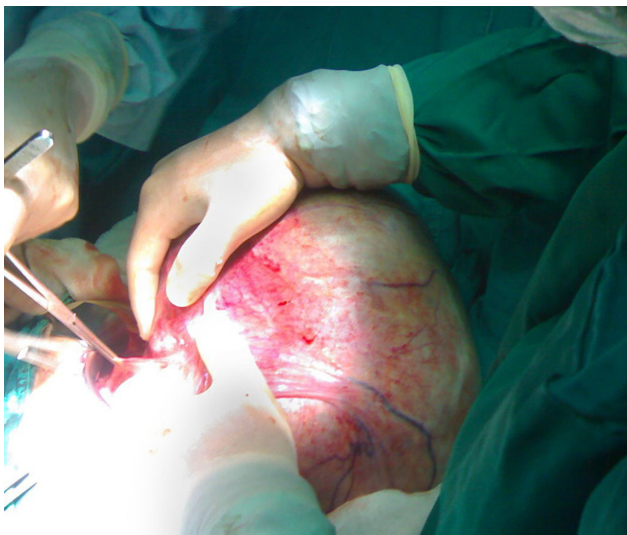


Figure 3. Gross view of the cyst during the salpingo-oophorectomy.

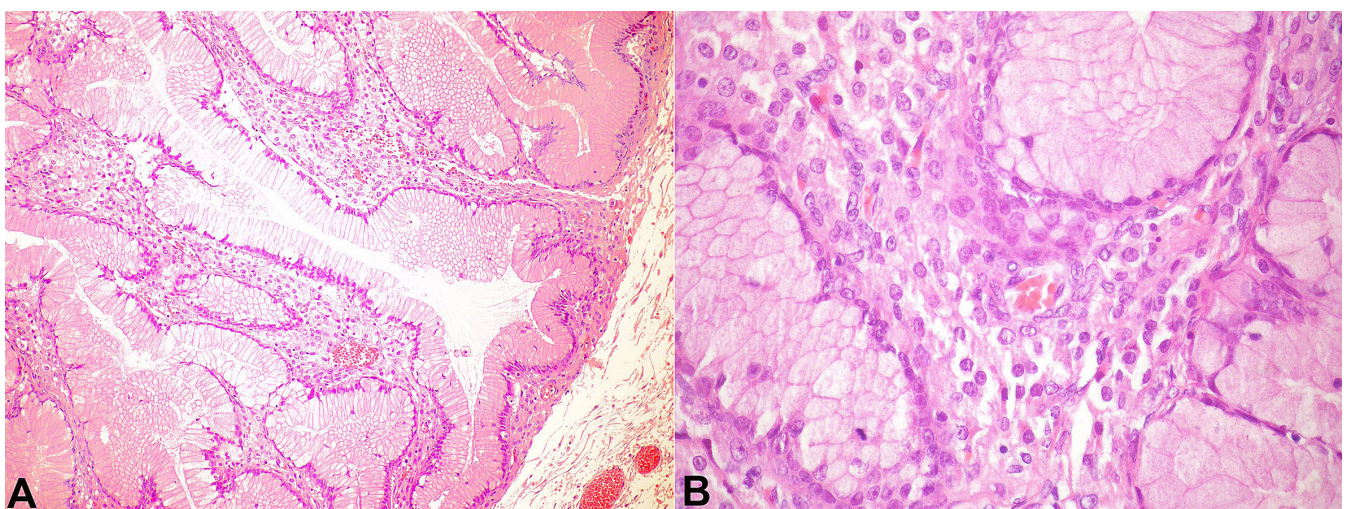


Figure 4. Photomicrography of the cystic tumor showing glands lined by a single layer of columnar cells containing a large amount of mucin and luteinized stromal cells with large nuclei and eosinophilic to clear cytoplasm (H&E, **A** - 100X and **B** - 400X).

DISCUSSION

The frequency of an ovarian tumor during pregnancy, which is diagnosed by ultrasonography is 1.14%. Ninety percent of these tumors are smaller than 5 cm, and generally are spontaneously absorbed before the 16th week of pregnancy.⁷ Although the symptoms caused by these masses were considered as physiological changes of pregnancy in the past, pregnancies complicated with adnexal masses have been increasingly reported due to the increased availability of imaging techniques. MCs of the ovary during pregnancy have been reported with different presentations.^{5,8-11} Virilization related to ovarian pathology is uncommon during pregnancy. The local factors secreted by the tumor and the mechanical pressure of the tumor on the stromal cells have been proposed as the possible reasons for virilization.^{12,13} MCs usually arise from the ovary, as in the presenting case. However, MCs from ectopic ovarian tissue in organs, such as the omentum, appendix, or pancreas, have also been reported.^{14,15} The origin or the pathogenesis of MCs in other organs is not yet well defined. Theories suggest that: (i) MC may be the result of ectopic ovarian tissue or teratoma; and (ii) MC may result from a peritoneal invagination and therefore form a cyst with further mesothelium mucinous metaplasia. In the pancreas and the liver, MC presents ovarian-type or ovarian-like subepithelial stroma, which is the criterion for the diagnosis.¹⁶

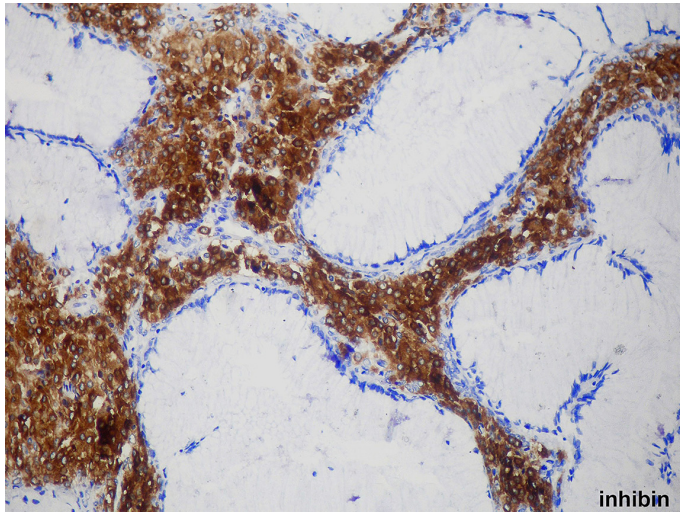


Figure 5. Photomicrography of the cystic tumor showing strong positivity for inhibin in the stromal luteinized cells while the mucinous epithelium is negative (immunohistochemistry 200X).

There are different approaches to the adnexal masses during pregnancy. In a series comprising 36 cases of pregnancies with adnexal masses, Balci et al.¹⁷ concluded that watchful waiting should be adopted unless an unexpected event emerges requiring surgical intervention. Ovarian tumors during pregnancy may complicate with torsion, rupture, infarction, fetal intrauterine growth impairment, fetal malpresentation, preterm labor, and dystocia preventing normal vaginal delivery. In the past, an elective operation was recommended during the second trimester in order to decrease these complications. Lee et al.¹⁸ stated that conservative treatment was safer than elective surgery performed during the second trimester for patients with a low malignancy risk. Indeed, an emergency procedure undertaken after an expectant management did not show worse obstetric outcomes when compared with elective surgery.¹⁸ However, some researchers still advocate elective surgery.⁷

In this setting, in our clinic, we prefer to adopt the expectant management in pregnancies with adnexal benign masses in the absence of any complications. The presenting case was referred to our clinic in the 33rd week of pregnancy with signs of dyspnea, palpitation, and edema. A rapid-growing adnexal cystic mass was present and was believed to be hormone sensitive due to the virilization stigmata. However, the patient's immunohistochemistry was negative for estrogen and progesterone.

Data on immunohistochemical staining for estrogen and progesterone receptors of MCs during pregnancy are conflicting. Although Qublan et al.⁵ reported estrogen receptor positivity on immunohistochemical staining of virilizing MC during pregnancy, our case lacked this positivity. Bolat et al.⁸ recently reported a case of MC in pregnancy in which the immunohistochemistry was negative for estrogen and progesterone receptors but was positive for human chorionic gonadotropin (HCG). The virilization of our patient can be explained by the luteinizing stroma found in the histopathological examination.^{5,18} HCG is the most important hormone; it provides the luteinizing stroma, and therefore the virilization stigmata are supposed to cease with the end of the pregnancy. However, in our case, tumor cells were HCG negative by the immunohistochemistry. In the virilizing MC cases during pregnancy reported by Bolat et al.⁸ and Antoniou et al.,¹⁹ luteinized stromal cells were negative for estrogen and progesterone receptors but positive for HCG. To our knowledge, this present case of an MC complicating pregnancy with virilization is the first in the literature to be estrogen, progesterone, and HCG negative. It could be speculated that another mechanism should be responsible for virilization in these patients.

Similarly, we could not find any reported case with IVC syndrome associated with an MC complicating pregnancy with virilization.^{8,11} Intrauterine growth retardation has been reported in cases of large-sized abdominal masses, but interestingly, such impairment was not observed in our case.⁵ Meanwhile, we believe that the intra-abdominal pressure provided by the ovarian mass, in the present case, was also responsible for the preterm delivery.

Clinicians should keep in mind that hemodynamic derangements consistent with IVC syndrome that do not respond to left-side recumbence or upright position during pregnancy might be due to abdominal masses complicating pregnancy. Symptoms recover immediately after surgical decompression.

REFERENCES

1. Leiserowitz GS. Managing ovarian masses during pregnancy. *Obstet Gynecol Surv.* 2006;61(7):463-70. <http://dx.doi.org/10.1097/01.ogx.0000224614.51356.b7>. PMID:16787549.
2. Usui R, Minakami H, Kosuge S, Iwasaki R, Ohwada M, Sato I. A retrospective survey of clinical, pathologic, and

- prognostic features of adnexal masses operated on during pregnancy. *J Obstet Gynaecol Res.* 2000;26(2):89-93. <http://dx.doi.org/10.1111/j.1447-0756.2000.tb01289.x>. PMID:10870299.
3. Sherard GB 3rd, Hodson CA, Williams HJ, Semer DA, Hadi HA, Tait DL. Adnexal masses and pregnancy: a 12-year experience. *Am J Obstet Gynecol.* 2003;189(2):358-62, discussion 362-3. [http://dx.doi.org/10.1067/S0002-9378\(03\)00731-2](http://dx.doi.org/10.1067/S0002-9378(03)00731-2). PMID:14520194.
 4. Zanotti KM, Belinson JL, Kennedy AW. Treatment of gynecologic cancers in pregnancy. *Semin Oncol.* 2000;27(6):686-98. PMID:11130476.
 5. Qublan HS, Al-Ghoweri AS, Al-Kaisi NS, Abu-Khait SA. Benign mucinous cystadenoma with stromal luteinization during pregnancy: a hormonally responsive tumor and a rare cause of fetal intrauterine growth restriction. *J Obstet Gynaecol Res.* 2002;28(2):104-7. <http://dx.doi.org/10.1046/j.1341-8076.2002.00020.x>. PMID:12078969.
 6. Ioffe OB, Simsir A, Silverberg SG. Pathology. In: Berek JS, Hacker NF, editors. *Practical gynecologic oncology*. Los Angeles: Lippincott Williams & Wilkins; 2000. p. 213-4.
 7. Agarwal N, Parul, Kriplani A, Bhatla N, Gupta A. Management and outcome of pregnancies complicated with adnexal masses. *Arch Gynecol Obstet.* 2003;267(3):148-52. <http://dx.doi.org/10.1007/s00404-001-0287-y>. PMID:12580154.
 8. Bolat F, Parlakgumus A, Canpolat T, Tuncer I. Benign mucinous cystadenoma with stromal luteinization responsible for maternal virilization and fetal intrauterine growth restriction. *J Obstet Gynaecol Res.* 2011;37(7):893-6. <http://dx.doi.org/10.1111/j.1447-0756.2010.01406.x>. PMID:21450020.
 9. Noreen H, Syed S, Chaudhri R, Kahloon LE. A large unilocular mucinous cystadenoma in third trimester of pregnancy. *J Coll Physicians Surg Pak.* 2011;21(7):426-8. PMID:21777533.
 10. Ivanov S, Kovachev E, Minkov R, et al. A rare case of pregnancy combined with a large ovarian tumour. *Akush Ginekol (Sofia).* 2012;51(Suppl 1):29-32. PMID:23236676.
 11. Pather S, Atkinson K, Wang I, Russell P, Kesby G, Carter J. Virilization in pregnancy due to a borderline mucinous ovarian tumor. *J Obstet Gynaecol Res.* 2007;33(3):384-7. <http://dx.doi.org/10.1111/j.1447-0756.2007.00542.x>. PMID:17578373.
 12. MacDonald PC, Grodin JM, Edman CD, Vellios F, Siiteri PK. Origin of estrogen in a postmenopausal woman with a nonendocrine tumor of the ovary and endometrial hyperplasia. *Obstet Gynecol.* 1976;47(6):644-50. PMID:934553.
 13. Verhoeven AT, Mastboom JL, van Leusden HA, van der Velden WH. Virilization in pregnancy coexisting with an ovarian mucinous cystadenoma: A case report and review of virilizing ovarian tumors in pregnancy. *Obstet Gynecol Surv.* 1973;28(9):597-622. <http://dx.doi.org/10.1097/00006254-197309000-00001>. PMID:4614154.
 14. Cohen I, Altaras M, Lew S, Jaffe R, Ben-Aderet N. Huge mesenteric mucinous cystadenoma in normal pregnancy. *Obstet Gynecol.* 1988;71(6 Pt 2):1030-2. PMID:3374916.
 15. Tica AA, Tica OS, Saftoiu A, Camen D, Tica VI. Large pancreatic mucinous cystic neoplasm during pregnancy: what should be done? *Gynecol Obstet Invest.* 2013;75(2):132-8. <http://dx.doi.org/10.1159/000346176>. PMID:23343567.
 16. Cauchy F, Lefevre JH, Mourra N, Parc Y, Tiret E, Balladur P. Mucinous cystadenoma of the mesocolon, a rare entity frequently presenting with features of malignity: two case reports and review of the literature. *Clin Res Hepatol Gastroenterol.* 2012;36(1):e12-6. <http://dx.doi.org/10.1016/j.clinre.2011.09.006>. PMID:22074643.
 17. Balci O, Gezginc K, Karatayli R, Acar A, Celik C, Colakoglu MC. Management and outcomes of adnexal masses during pregnancy: A 6-year experience. *J Obstet Gynaecol Res.* 2008;34(4):524-8. <http://dx.doi.org/10.1111/j.1447-0756.2008.00744.x>. PMID:18946936.
 18. Lee GSR, Hur SY, Shin JC, Kim SP, Kim SJ. Elective vs. conservative management of ovarian tumors in pregnancy. *Int J Gynaecol Obstet.* 2004;85(3):250-4. <http://dx.doi.org/10.1016/j.ijgo.2003.12.008>. PMID:15145260.
 19. Antoniou N, Varras M, Akrivis C, Demou A, Bellou A, Stefanaki S. Mucinous cystadenoma of the ovary with functioning stroma and virilization in pregnancy: a case report and review of the literature. *Clin Exp Obstet Gynecol.* 2003;30(4):248-52. PMID:14664425.

Conflict of interest: None

Submitted on: January 15th, 2016

Accepted on: April 6th, 2016

Correspondence

Suna Kabil Kucur

Department of Obstetrics and Gynecology - Evliya Celebi Training and Research Hospital - Faculty of Medicine - Dumlupinar University

Evliya Celebi Avenue – Okmeydani Street – Kutahya – Turkey

Phone: +90532355-9047

Fax: +90274231-6660

E-mail: dr.suna@hotmail.com