

CASE REPORT

Open Access



# An unusual *Staphylococcus saccharolyticus* spondylodiscitis post kyphoplasty: a case report

Marie-Charlotte Trojani<sup>1\*</sup>, Brigitte Lamy<sup>2,3,4</sup>, Raymond Ruimy<sup>2,3,4</sup>, Nicolas Amoretti<sup>5</sup>, Karine Risso<sup>6</sup> and Christian Roux<sup>7</sup>

## Abstract

**Background:** *Staphylococcus saccharolyticus* is a rarely encountered coagulase-negative, which grows slowly and its strictly anaerobic staphylococcus from the skin. It is usually considered a contaminant, but some rare reports have described deep-seated infections. Virulence factors remain poorly known, although, genomic analysis highlights pathogenic potential.

**Case presentation:** We report a case of *Staphylococcus saccharolyticus* spondylodiscitis that followed kyphoplasty, a procedure associated with a low rate but possible severe infectious complication (0.46%), and have reviewed the literature. This case specifically stresses the risk of healthcare-associated *S. saccharolyticus* infection in high-risk patients (those with a history of alcoholism and heavy smoking).

**Conclusion:** *S. saccharolyticus* infection is difficult to diagnose due to microbiological characteristics of this bacterium; it requires timely treatment, and improved infection control procedure should be encouraged for high-risk patients.

**Keywords:** Spondylodiscitis, Kyphoplasty, Healthcare-associated infection, Case report, *Staphylococcus saccharolyticus*

## Background

*Staphylococcus saccharolyticus* (formerly known as *Peptococcus saccharolyticus*) is a rarely encountered coagulase-negative staphylococcus and the only anaerobic species of the genus *Staphylococcus* [1]. Although it is usually considered a non-pathogenic microorganism of the human skin flora with no particular known tropism to generate specific infections, occasional reports suggest a pathogenic potential through miscellaneous rare deep-seated infections [2–5]. Little is known on its virulence factors, pathogenesis, and determinants of

infection. Recently, genome-sequencing analysis has shown that *S. saccharolyticus* possesses hyaluronidase activity (similar to that of *Staphylococcus aureus*), toxins of the phenol-soluble modulins family, and several quorum-sensing systems that may have a tissue-invasive potential [6].

Infectious complications after vertebroplasty/kyphoplasty are rare, but potentially serious life-threatening complications affecting the patient's functional prognosis can occur (0.46% prevalence rate), which usually result from direct inoculation from skin flora such as *Staphylococcus aureus*, *S. epidermidis*, and *Cutibacterium acnes* [7, 8]. Here, we report the third case of spondylodiscitis due to *S. saccharolyticus* and the first to follow a surgical procedure such as kyphoplasty that specifically stresses

\* Correspondence: [mctroj@hotmail.fr](mailto:mctroj@hotmail.fr)

<sup>1</sup>Département de Rhumatologie, Université Côte d'Azur, CHU de Nice, Nice, France

Full list of author information is available at the end of the article



© The Author(s). 2020 **Open Access** This article is licensed under a Creative Commons Attribution 4.0 International License, which permits use, sharing, adaptation, distribution and reproduction in any medium or format, as long as you give appropriate credit to the original author(s) and the source, provide a link to the Creative Commons licence, and indicate if changes were made. The images or other third party material in this article are included in the article's Creative Commons licence, unless indicated otherwise in a credit line to the material. If material is not included in the article's Creative Commons licence and your intended use is not permitted by statutory regulation or exceeds the permitted use, you will need to obtain permission directly from the copyright holder. To view a copy of this licence, visit <http://creativecommons.org/licenses/by/4.0/>. The Creative Commons Public Domain Dedication waiver (<http://creativecommons.org/publicdomain/zero/1.0/>) applies to the data made available in this article, unless otherwise stated in a credit line to the data.

the risk of healthcare-associated *S. saccharolyticus* infection [2, 3].

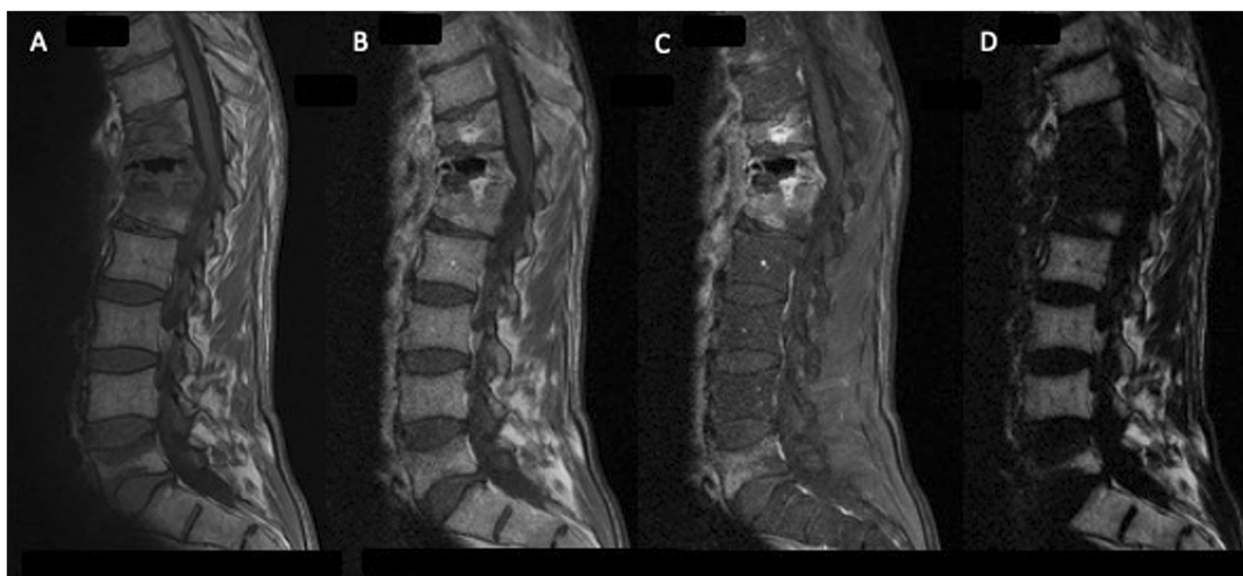
### Case presentation

A 57-year-old man with a history of alcoholism and heavy smoking was admitted for disabling back pain. Four months earlier, he had sustained two vertebral fractures (T10 and T11) due to falling; these were treated by kyphoplasty under computer tomography (CT) guidance. Because the back pain persisted 2 weeks after the procedure, he received a zygapophyseal joint steroid injection under CT guidance. Three days later, his C-reactive protein level was 12.5 mg/l and hyperleukocytosis was moderate (13 G/L including 10 G/L neutrophils) and the patient had no fever. Magnetic resonance imaging (MRI) findings revealed infectious spondylodiscitis (Fig. 1). A *Staphylococcus saccharolyticus* isolate was recovered after 90 h of incubation from one single vial of a first series of three blood culture (BC) sets. The same microorganism was identified from two additional BC series collected 5 and 10 days later after 83 and 100 h of incubation, respectively. It was not possible to perform either culturing or molecular diagnostics using the tissue sample as the patient's condition did not permit disc biopsy. However, the findings from the blood culture tests indicated a definite diagnosis of spondylodiscitis, though a catheter or spinal device was not inserted in the patient. Using disk diffusion assay, the isolate was multi-drug susceptible including to penicillin and cefoxitin. The patient was treated with 2 g of amoxicillin three times a day for a total duration of 4 weeks after consultation with the infectious disease team. Pain and inflammatory

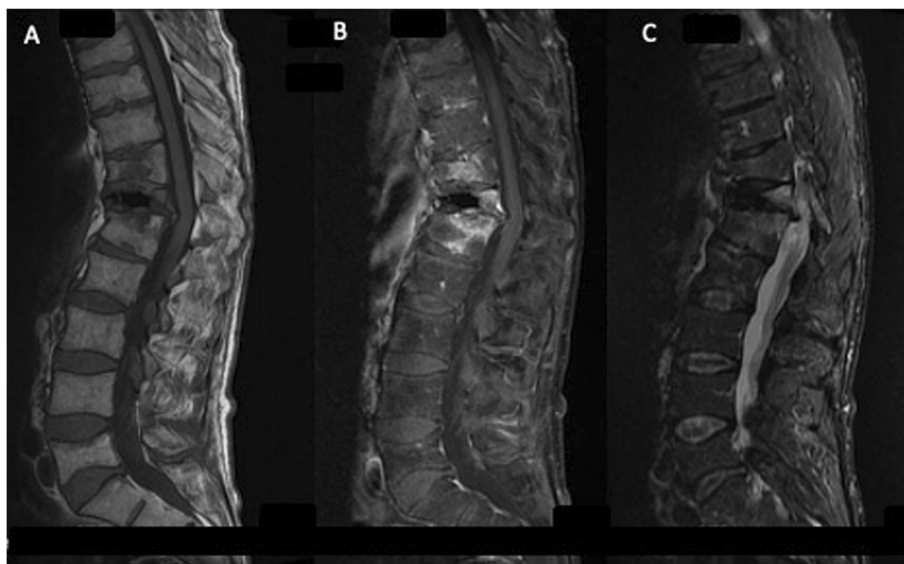
syndrome both gradually regressed, and MRI performed after 12 month showed decrease in hyperintensity (Fig. 2b). No clear source of the bacteria was identified. The infection was presumably from skin and the bacteria was likely introduced in the surgical site during the kyphoplasty procedure. However, we could not identify any defect in the surgical skin preparation and infection control procedures as well as any particular event causing exposure during the kyphoplasty procedure.

### Discussion and conclusions

*S. saccharolyticus* is a lesser known coagulase-negative staphylococcus [1]. Although it is usually considered a skin contaminant, it can cause endocarditis, bone infection, or pyomyositis, which may be associated with poor outcome (Table 1) [2–5, 9–13]. In addition to the tissue-invasive factors that have been unraveled, the dependence on anaerobic conditions is considered to favor the ability to invade human tissue, while biofilm production may contribute to the colonization of medical devices [6]. Further research is needed to understand *S. Saccharolyticus* virulence and the risk of infection better. In this regard, reports should also carefully consider patient comorbidities as host condition may contribute to the disease development. In this context, a literature review was conducted using the key words “*Staphylococcus saccharolyticus*” and “case” on the PubMed database. Eight articles were excluded after reading title and/or abstract because they were not applicable to the topic. A total of 8 articles were selected, which were used to compose the summary table (Table 1). Thus far, only 3 of the 9 reported cases have detailed host risk factors. To date,



**Fig. 1** Spinal MRI, sagittal section: Hyperintensity, T11-T12-L1 vertebrae, para-vertebral soft tissue, and T12-L1 disc consistent with infectious spondylodiscitis. **a** T1-weighted; **b, c, d** IDEAL sequence



**Fig. 2** Spinal MRI, sagittal section 1 year later: A decrease in signal was observed. **a** T1-weighted; **b** T1-weighted with contrast agent; **c** STIR sequence

only 3 cases, including our case, of spondylodiscitis have been reported, of which 1 case has been related to a surgical procedure and multiple-level diskographies [3] and 1 (current) case occurred after kyphoplasty; information on surgical procedure was not retrieved for the third case [2].

Although vertebroplasty is a minimally invasive procedure, the possibility of postoperative infection should not be ignored. It requires major salvage surgery and may lead to residual disability and even death in several cases. In addition to standard skin preparation and the administration of prophylactic antibiotics, surgeons should preoperatively consider immune status, urinary tract infection or other infection source within 6 months, and history of pulmonary tuberculosis to prevent infection post vertebroplasty [14].

It is unclear why *S. saccharolyticus* is specifically associated with spondylodiscitis. This either reflects a specific bacterial niche that remains to be evidenced or represents a publication bias. To date, there is no means to clarify this point. Bruggeman et al. recently reported 8 strains recovered from hip and shoulder prosthetic infections, which suggests that orthopedic sites other than the spine may be infected by *S. saccharolyticus*. Unfortunately, Bruggeman et al. provided no information about the clinical cases, so it is unclear if this potential contaminant was actually the causative agent of all the reported infections [6].

This case highlights several important considerations in *S. saccharolyticus* infection and the pitfalls associated with the diagnostic aspects. Symptoms and biological syndrome may be moderate or absent in the early stage of infection [4]. In our case, fever was absent and the inflammatory biologic syndrome was mild. Possible reasons

could be the proximity of a corticosteroid injection and effective empirical treatment that was timely administered. *S. saccharolyticus*, in addition to being anaerobic, grows slowly, which may be misinterpreted as a contamination because the bacterium grows only in anaerobic bottles (not in aerobic bottles); thus, very few or only a single bottle may be positive. In addition, the long time to positivity is usually a criterion to suspect BC contamination (together with a single/low number of positive bottle). Thus, the characteristics of the result (long time to positivity, low number of positive bottles) could be misinterpreted for a contamination) [1, 13]. This might also lead to under diagnosis when cultures are not incubated for at least 5 days, which is a regular situation with analyses other than BC. These findings advocate for the following: i) a minimum of 5 days of anaerobic culture study when infection is strongly suspected, and no microorganism is recovered on day 3 of incubation. This implies a preferred cooperation between a rheumatologist and microbiologist to adapt and optimize the diagnostic procedures, including molecular diagnostics, when spinal infection is suspected and ii) a fine interpretation of the microbiological findings in order to prevent overlooking an infection etiology when a microorganism that is most frequently a contaminant is recovered.

The favorable evolution after appropriate antibiotics treatment is not a regular option. The rare reported infections (9 to our knowledge) have often been fatal (3 of the 7 available outcomes; Table 1). Timely treatment may be critical. Comorbidities favoring this opportunistic infection are unevenly reported: prosthetic heart valves [9, 10], poor oral hygiene (2), type II diabetes (5), to which we can importantly add tobacco use, alcoholism, and cachexia in this patient.

**Table 1** Summary of cases of infections caused by *S. saccharolyticus*

| Year (ref)      | Location | Age/ Sex | Diagnosis                             | Risk factors   | Comment on clinical presentation  | Biology   | Microbiological diagnosis   | Antimicrobial susceptibility  | Final treatment (total duration)       | Outcome                            |
|-----------------|----------|----------|---------------------------------------|--|---|---|---|---|--|------------------------------------|
| 1990 [4]        | USA      | 61/ M    | Endocarditis                          | No predisposing valvular heart disease                       | Low grade fever at onset; moderate-sized mitral valve vegetation  | Anemia; thrombocytosis; ESR elevation                   | BC; all bottles positive at day 10  | Susceptible to PE, OX, VA, GE, CI, CL; resistant to ME  | NAF + GE (6 wks)                       | Favorable at day 30                |
| 1996 [9]        | USA      | 57/ W    | Prosthetic mitral valve endocarditis  | NA   | Fever; large masses at prosthetic valve level   | Anemia; hyperleukocytosis                               | BC; all anaerobic vials positive at day 1; aerobic vials positive at day 11   | Susceptible to VA, CL, CH; resistant to all $\beta$ -lactam agents (including OX, CES, ME, TET)                   | Valve change; medical treatment (NA)   | Died at day 32 of hospitalization  |
| 2009 [10]       | USA      | NA       | Prosthetic valve endocarditis         | NA   | NA  | NA  | Mitral valve; anaerobic culture; at day NA  | NA  | NA                                     | NA                                 |
| 1990 [11]       | China    | 21/ M    | Pneumonia                             | NA   | Blood-stained sputum; multiple spherical focal lesions in the lung (CT scan)  | Anemia; hyperleukocytosis                               | NA  | Susceptible to LE, MO; NA for other antibiotics   | AZ (6 d); TI + PE (3 d); IM + TI (1 d) | Died at day 120 of hospitalization |
| 2015 [12]       | China    | 26/ W    | Bone marrow infection                 | NA   | High-grade fever; headache at onset; lymph nodes  | Anemia; hyperleukocytosis; ESR and CRP strong elevation | Lung biopsy; positive anaerobic culture at day 10?  | Susceptible to VA, LE, PE, CL; resistant to ME;   | PE + VA (2 d); IM + VA (NA)            | Died at day 114                    |
| 2005 [2]        | France   | 58/ M    | Spondylodiscitis                      | No endocarditis; no underlying disease but poor oral hygiene | Thoracic posterior pains for 2 months; fever; weight loss; NSAIDs/corticosteroids treatment   | At admission, hyperleukocytosis; ESR and CRP elevation  | BC and bone marrow; positive anaerobic cultures at day 3  | Susceptible to VA, TEI, RI, ER, PR, TET, OF, CL; Resistant to ME; No $\beta$ -lactamase production; no mecaA gene | OF+CL (12 wks)                         | Favorable at year 1                |
| 2009 [3]        | USA      | 38/ M    | Spondylodiscitis                      | NA   | Radicular symptoms treated unsuccessfully by microdiscectomy  | Elevation of inflammatory parameters                    | Negative aerobic cultures; negative acid-fast bacilli   | NA  | NA                                     | NA                                 |
| 2017 [5]        | NZ       | 48/ M    | Pyomyositis, spermatic cord infection | Type II diabetes; hyperlipidemia                             | Fever   | Neutrophilia; CRP large increase; CPK normal            | Multiple muscle biopsies; anaerobic positive culture at 24 h; coinfection <i>S. capitis</i> and <i>S. saccharolyticus</i> | Susceptible to FL; Resistant to PE  | CEFA (1 wk); CEP (2 wks)               | Favorable at 4 weeks               |
| 2017 (our case) | France   | 57/ M    | Spondylodiscitis                      | Heavy smoking; alcoholism; unhealthy underweight             | Vertebral fractures (treated by kyphoplasty and zygapophyseal joint steroid injection); no fever; unremarkable clinical examination | Hyperleukocytosis; CRP moderate increase                | Aerobic cultures negative at day 7  | Susceptible to PE; CEF, MA, RI, TET, FO; OF; no $\beta$ -lactamase production                                     | AM (4 wks)                             | Favorable at 46 months             |

M man, W woman, ESR erythrocyte sedimentation rate, BC blood culture, NA non-available, AM amoxicillin, AZ azithromycin, CEFA cefazolin, CEF cefoxitin, CEP cephalosporin, CH chloramphenicol, CI ciprofloxacin, CL clindamycin, ER erythromycin, FL flucloxacillin, FO fosfomicin, GE gentamicin, IM imipenem, LE levofloxacin, MA macrolides, ME metronidazole, MO moxifloxacin, NAF nafcilin, OF ofloxacin, OX oxacillin, PE penicillin, PR pristinamycin, RI rifampicin, TEI teicoplanin, TET tetracycline, TI trimidazole, VA vancomycin



Finally yet importantly, infection control procedures designed to prevent infection following vertebroplasty procedure may require some improvements to achieve infection prevention in patients with poorer condition. This is a challenging goal because, to-date, no suggestions to help reduce the risk of infection are available in the literature when all actions taken have already complied with guidelines. Strategies for improvement may arise from further research on antibacterial advanced cement for kyphoplasty [15, 16] (e.g., Clarkin et al., 2011; Brauer et al., 2013), as well as from further research on improved bundle approaches. Improvements may also arise from a better understanding of the pathophysiology of surgical site infection. A step in this direction was provided by Romano-Bertrand et al. [17], who showed how disturbances of skin microbiota by antiseptics and prophylactic treatment impacted the dynamics of microbiota in deep tissues during cardiac surgery. Although this model does not exactly fit with kyphoplasty, it does clearly show that diverse bacteria may reach the surgical site during invasive procedures. Further understanding is also needed on how the patient's condition and innate immunity may impact the response towards controlling surgical site infection development during the very first steps of invasive procedures. In conclusion, the incidence of *S. saccharolyticus* spondylodiscitis is reportedly low, but clinicians must not fail the diagnosis. We advise that any *S. saccharolyticus* culture in the context of fever and/or orthopedic pain should be cautiously reviewed before being considered a contaminant. Prompt diagnosis and treatment is essential for an improved outcome of this severe infection and overall efforts should be made in infection control during vertebroplasty.

#### Abbreviations

CT: Computer tomography; BC: Blood culture; MRI: Magnetic resonance imaging

#### Acknowledgements

None.

#### Authors' contributions

MCT was in charge of the case review and preparation of the manuscript. CR, BL, conceived the work, provided clinical expert opinion, and helped to draft the manuscript. KR, NA, and RR provided clinical expert opinion and revised the manuscript. All authors read and approved the manuscript.

#### Funding

None.

#### Availability of data and materials

Not applicable. Please contact authors for data requests.

#### Ethics approval and consent to participate

Written consent was obtained from the patient. No ethics committee was necessary for this case report.

#### Consent for publication

Written consent was obtained from the patient for publication of this case report. A copy of the written is available for review by Editor in Chief of this journal.

#### Competing interests

The authors declare that they have no competing interests.

#### Author details

<sup>1</sup>Département de Rhumatologie, Université Côte d'Azur, CHU de Nice, Nice, France. <sup>2</sup>Laboratoire de Bactériologie, Hôpital L'archet 2, CHU de Nice, Nice, France. <sup>3</sup>INSERM U1065, Centre Méditerranéen de Médecine Moléculaire, Equipe 6, Nice, France. <sup>4</sup>Faculté de Médecine, Université Côte d'Azur, Nice, France. <sup>5</sup>Département de Radiologie, Université Côte d'Azur, CHU de Nice, Nice, France. <sup>6</sup>Service d'infectiologie, Université Nice Côte d'Azur, CHU de Nice, Nice, France. <sup>7</sup>Département de Rhumatologie, Université Côte d'Azur, LAHMES EA6309, CNRS, iBV UMR 7277, CHU de Nice, Nice, France.

Received: 17 March 2020 Accepted: 16 July 2020

Published online: 23 July 2020

#### References

- Evans CA, Mattern KL, Hallam SL. Isolation and identification of *Peptococcus saccharolyticus* from human skin. *J Clin Microbiol.* 1978;7:261–4.
- Godreuil S, Jean-Pierre H, Morel J, et al. Unusual case of spondylodiscitis due to *Staphylococcus saccharolyticus*. *Joint Bone Spine.* 2005;72:91–3.
- Mikhael MM, Bach HG, Huddleston PM, Maus TP, Barbari EF. Multilevel diskitis and vertebral osteomyelitis after diskography. *Orthopedics.* 2009;32:60.
- Westblom TU, Gorse GJ, Milligan TW, Schindzielorz AH. Anaerobic endocarditis caused by *Staphylococcus saccharolyticus*. *J Clin Microbiol.* 1990;28:2818–9.
- Young N, Bhally H. Bilateral neck Pyomyositis caused by *Staphylococcus capitis* and *Staphylococcus saccharolyticus* in a diabetic adult. *Case Rep Infect Dis.* 2017;2017:3713212.
- Brüggemann H, Poehlein A, Brzuszkiewicz E, Scavenius C, Enghild JJ, Al-Zeer MA, Brinkmann V, Jensen A, Söderquist B. *Staphylococcus saccharolyticus* Isolated From Blood Cultures and Prosthetic Joint Infections Exhibits Excessive Genome Decay. *Front Microbiol.* 2019;10:478.
- Abdelrahman H, Siam AE, Shawky A, Ezzati A, Boehm H. Infection after vertebroplasty or kyphoplasty. A series of nine cases and review of literature. *Spine J.* 2013;13:1809–17.
- Schofer MD, Lakemeier S, Peterlein CD, et al. Primary pyogenic spondylitis following kyphoplasty: a case report. *J Med Case Rep.* 2011;5:101. <https://doi.org/10.1186/1752-1947-5-101>.
- Krishnan S, Haglund L, Ashfaq A, Leist P, Roat T. Prosthetic valve endocarditis due to *Staphylococcus saccharolyticus*. *Clin Infect Dis.* 1996;22:722–3.
- Bravo LTC, Oethinger MD. *Staphylococcus saccharolyticus*: A Rare but Important Cause of Anaerobic Endocarditis. *Microbiology No. MB 08–8 (MB-357).* *Am J Clin Pathol.* 2009;131:286–99 (Abst n°46).
- Wu X, Yu C, Wang X. A case of *Staphylococcus saccharolyticus* pneumonia. *Int J Infect Dis.* 2009;13:e43–6.
- Liu CJ, Sun B, Guo J, et al. A case of bone marrow infection by *Staphylococcus saccharolyticus*. *Eur Rev Med Pharmacol Sci.* 2015;19:1161–3.
- Lanne S. *Staphylococcus saccharolyticus*: à propos d'un cas d'infection de dispositif cardiaque implantable, enjeux de l'identification et pathogénicité d'un germe méconnu. *Sci Pharm.* 2016; [dumas-01323806](https://doi.org/10.1323806).
- Liao JC, Lai PL, Chen LH, Niu CC. Surgical outcomes of infectious spondylitis after vertebroplasty, and comparisons between pyogenic and tuberculosis. *BMC Infect Dis.* 2018;18(1):555. <https://doi.org/10.1186/s12879-018-3486-x>.
- Clarkin O, Wren A, Thornton R, Cooney J, Towler M. Antibacterial analysis of a zinc-based glass polyalkenoate cement. *J Biomater Appl.* 2011;26(3):277–92. <https://doi.org/10.1177/0885328210364430>.
- Brauer DS, Karpukhina N, Kedia G, et al. Bactericidal strontium-releasing injectable bone cements based on bioactive glasses. *J R Soc Interface.* 2013; 10(78):20120647. <https://doi.org/10.1098/rsif.2012.0647>.
- Romano-Bertrand S, Frapier JM, Calvet B, et al. Dynamics of the surgical microbiota along the cardiothoracic surgery pathway. *Front Microbiol.* 2015; 5:787. Published 2015 Jan 13. <https://doi.org/10.3389/fmicb.2014.00787>.

#### Publisher's Note

Springer Nature remains neutral with regard to jurisdictional claims in published maps and institutional affiliations.