

This article is licensed under the Creative Commons Attribution-NonCommercial 4.0 International License (CC BY-NC) (<http://www.karger.com/Services/OpenAccessLicense>). Usage and distribution for commercial purposes requires written permission.

Single Case

Incomplete Annular Pancreas with Ectopic Opening of the Pancreatic and Bile Ducts into the Pyloric Ring: First Report of a Rare Anomaly

Shinjiro Kobayashi^a Horoyuki Hoshino^a Kouhei Segami^a
Satoshi Koizumi^a Nobuyuki Ooike^b Takehito Otsubo^a

^aDivision of Gastroenterological and General Surgery, St. Marianna University School of Medicine, Kawasaki, Japan; ^bDepartment of Pathology, Showa University Fujigaoka, Yokohama, Japan

Keywords

Annular pancreas · Malformation · Pancreatoduodenectomy

Abstract

The patient was a 56-year-old woman who had experienced epigastralgia and dorsal pain several times over the last 20 years. She was admitted for a diagnosis of acute cholecystitis, and severe intra- and extrahepatic bile duct dilatation with inner air density was noted. No papilla of Vater was present in the descending duodenum, and 2 small holes were present in the pyloric ring. Bile excretion from one of the small holes was observed under forward-viewing endoscope. It was considered that the pancreatic and bile ducts separately opened into the pyloric ring. Based on these findings, malformation of the pancreaticobiliary duct was diagnosed. She did not wish treatment, but the obstruction associated with duodenal stenosis was noted after 2 years. Pancreatoduodenectomy was performed as curative treatment for duodenal stenosis and retrograde biliary infection through the bile duct opening in the pyloric ring. The ventral pancreas encompassed almost the entire circumference of the pyloric ring, suggesting a subtype of annular pancreas. Generally, lesions are present in the descending part of the duodenum in an annular pancreas, and the pancreatic and bile ducts join in the papillary region. However, in this patient, (1) the pancreas encompassed the pylo-

ric ring, (2) the pancreatic and bile ducts opened separately, and (3) the openings of the pancreatic and bile ducts were present in the pyloric ring. The pancreas and biliary tract develop through a complex process, which may cause various types of malformation of the pancreaticobiliary system, but no similar case report was found on a literature search. This case was very rare and could not be classified in any type of congenital anomaly of the pancreas. We would classify it as a subtype of annular pancreas with separate ectopic opening of the pancreatic and bile ducts into the pyloric ring.

© 2016 The Author(s)
Published by S. Karger AG, Basel

Introduction

The pancreas is formed by ventral and dorsal pancreatic buds originating from the endodermal lining, at the junction of the foregut and midgut during the fourth week of gestation. Eventually when the duodenum rotates to the right, the ventral pancreatic bud migrates dorsally and finally comes to lie immediately below and behind the dorsal pancreatic bud. Later, the parenchyma and duct system of the ventral pancreatic bud fuses completely with the dorsal pancreatic bud. Since the pancreas and the biliary tract undergo a complex developmental process, various malformations occur in the pancreaticobiliary system (e.g. annular pancreas, pancreas divisum, anomalous arrangement of the pancreaticobiliary duct, congenital biliary dilation and biliary atresia). Annular pancreas is a congenital anomaly in which histologically normal pancreatic tissue encircles the second portion of the duodenum either partially or completely, thereby causing stenosis or obstruction of the duodenum. The pancreatic duct should open to the major papilla of annular pancreas. However, the ventral pancreas of this case encompassed almost the entire circumference of the pyloric ring. This case was very rare and could not be classified in any type of congenital anomaly of the pancreas. It was classified as a subtype of annular pancreas.

Case Report

A 56-year-old woman visited our institution with chief complaints of epigastric and back pain. She had experienced occasional pain for 20 years. She had no signs of peritoneal irritation, but the upper abdomen was tender. Blood tests results were: total bilirubin 2.5 mg/dl, direct bilirubin 1.2 mg/dl, aspartate aminotransferase 48 IU/l, alanine aminotransferase 55 IU/l, alkaline phosphatase 814 IU/l, γ -glutamyl transpeptidase 333 IU/l, white blood cells 4,600/ μ l and C-reactive protein 1.14 mg/dl, while amylase and lipase were within normal limits. Although she had no history of biliary surgery or endoscopic sphincterotomy, computed tomography showed dilatation of the intrahepatic and extrahepatic bile ducts, and internal air density was observed (fig. 1). There were no obvious neoplastic lesions in the biliary tract or pancreas. Upper gastrointestinal endoscopy showed no duodenal papillae in the second segment of the duodenum, but there were two small juxtaposed orifices on the pyloric ring (fig. 2). One of the small orifices was excreting bile. It was determined that the patient had separate orifices for the pancreatic and biliary ducts on the pyloric ring. When contrast agent was administered into each orifice, the bile duct and the pancreatic duct were separately outlined (fig. 3). Based on these test results, malformation of the pancreaticobiliary duct was diagnosed. Since she did not wish to have the anomaly treated, she was followed-up without intervention for 2 years. However, 2 years after the diagnosis, she was again hospitalized with acute cholangitis. Her duodenum had become stenotic, causing ob-

struction. Since the bile duct had an orifice at the pyloric ring, there was pressure on the bile duct and cholangitis accompanied by sepsis had thus developed. In order to prevent retrograde cholangitis and pancreatitis as well as to resolve the duodenal stenosis, we performed subtotal stomach-preserving pancreatoduodenectomy. The ventral pancreas surrounded the pyloric ring subcircularly and no pancreatic tissue was seen at the second segment of the duodenum. The dorsal pancreas was located higher than its normal position. There was only one extrahepatic bile duct and no abnormalities were detected. Anomalous junction of the cystic duct was confirmed to be absent. Based on these findings, we diagnosed the patient as having one of the subtypes of annular pancreas (fig. 4). Macroscopic findings of the resected specimen also showed that the orifices of the pancreatic and bile ducts were located at the pyloric ring (fig. 5). Histopathological findings demonstrated a ventral and a dorsal pancreas accompanied by the duct of Wirsung and the duct of Santorini, respectively. Fibrillation and fatty replacement were seen mainly in the ventral pancreas. The bile duct also showed ulceration and fibrillation near the orifice (fig. 6). It was believed that fibrillation of the pancreaticobiliary duct had caused stenosis of the pyloric ring. The patient was discharged without postoperative complications. One year has passed, to date, since the surgery and she remains asymptomatic.

Discussion

The pancreas is formed by two anlagen, the dorsal and ventral pancreatic anlagen, which arise around the fourth week of gestation. The dorsal pancreatic anlage develops at the dorsal side of the duodenum, slightly superior to the hepatic diverticulum at the end of the fourth week of gestation. It grows anterior to the portal vein, by the sixth week. Right and left ventral pancreatic anlagen develop adjacent to the biliary bud from the end of the fourth through the fifth week of gestation. The left ventral anlage degenerates by the middle of the sixth week, with only the right ventral anlage remaining. By the sixth or seventh week of gestation, the right ventral anlage and the common bile duct rotate clockwise along with the duodenum, migrating until it comes under the dorsal pancreatic anlage and fuses with it during the seventh week. Consequently, the ventral pancreatic anlage forms the posterior inferior portion of the head and the uncinate process of the pancreas while the dorsal pancreatic anlage forms the superior portion of the head as well as the body and tail of the pancreas [1]. During the early stage of pancreatic development, there are right and left ventral ducts, but the left duct degenerates by the middle of the sixth week of gestation. By the end of the seventh week when the right ventral and dorsal pancreatic anlagen coalesce, the ascending branch, not the descending branch, of the ventral pancreatic duct communicates with the dorsal pancreatic duct to form the duct of Wirsung [2], which opens with the bile duct into the duodenum to form the major duodenal papilla (the papilla of Vater) [3]. In addition, the dorsal pancreatic duct located in the superior portion of the head of the pancreas becomes the duct of Santorini, and it opens into the minor duodenal papilla which is located more rostrally than the major pancreatic duct. On the other hand, the bile duct is originally in a 'solid stage' as with the duodenal anlage. Vacuolization starts from the inferior part of the common bile duct toward the hepatic side from the sixth week, and by the tenth week, formation of the bile duct with a full tubular structure is completed. The junction of the inferior common bile duct and the ventral pancreatic duct is detached from the duodenum at the end of the fifth week of gestation, and then again approaches the duodenum around the eighth week, finally inverting and invaginating into the wall of the pancreas to form the pa-

pilla of Vater around the tenth week [3]. Annular pancreas is a congenital anomaly in which histologically normal pancreatic tissue encircles the second portion of the duodenum either partially or completely, thereby causing stenosis or obstruction of the duodenum [4]. It was first reported by Tiedemann [5] in 1818 and named by Ecker in 1862 [6]. It is usually found in children, but with advances in diagnostic imaging including magnetic resonance imaging, endoscopic retrograde cholangiopancreatography and endoscopic ultrasound, increasing numbers of adult cases have been reported [7–10]. There are several hypotheses regarding the pathogenesis of annular pancreas. One hypothesis is that the free end of the ventral anlage is fixed and stays on the ventral side of the duodenum, allowing the ventral anlage to encircle the second portion of the duodenum to form a ring [11]. The second hypothesis is that both the ventral and the dorsal side of the ventral anlage are enlarged in a lingulate form to incompletely encircle the duodenum [12]. The third hypothesis is that the residual left lobe and overgrowth of the right lobe of the ventral pancreatic anlage both cause annular pancreas [13]. However, according to these hypotheses, the pancreatic duct from the annular portion should open to the major papilla, which cannot explain all courses of the pancreatic duct in cases of annular pancreas. Furthermore, although there are several classifications of annular pancreas based on the morphology of the pancreatic duct at the annular portion [14, 15], there are cases which cannot be classified or have pancreatic ducts with an extremely complex course. Therefore, annular pancreas may be caused by a variety of anomalies occurring during the course of development of the pancreatic anlagen and the duodenum. Annular pancreas usually involves a lesion in the second portion of the duodenum, and the pancreatic and bile ducts merge at the papilla. However, in our case, (1) the pancreas encircled the pyloric ring, (2) the pancreatic duct itself did not have an annular structure and pancreatic parenchyma surrounded the pyloric ring subcircularly, (3) the pancreatic and bile ducts had separate orifices, and (4) the orifices of the pancreatic and bile ducts were located on the pyloric ring. Moreover, the pancreas had both ventral and dorsal sides and neither the body nor the tail was absent. The ducts of Wirsung and Santorini were present and coalescence was observed. There was one common bile duct and the extrahepatic bile duct had a normal course, and the junction of the cystic duct was also normal. Since our literature search yielded no similar cases, we ultimately diagnosed our patient as having a subtype of annular pancreas. We believe that our patient had multiple anomalies which had arisen in the sixth or seventh week of gestation, when the left and right ventral pancreatic anlagen degenerate and rotate, and then persisted into the tenth week, when the papilla of Vater is formed. As mentioned earlier, since the pancreas and the biliary tract undergo a complex developmental process, various malformations occur in the pancreaticobiliary system. Apart from annular pancreas, pancreatic malformations include pancreas divisum and agenesis of the body and tail of the pancreas, and biliary malformations include anomalous arrangement of the pancreaticobiliary duct, congenital biliary dilation, biliary atresia, anomalous course of extrahepatic bile ducts and agenesis of the gallbladder. We believe our case to represent one of the subtypes of these developmental anomalies of the pancreaticobiliary system.

Conclusion

This is the first report of an extremely rare form of annular pancreas with ectopic opening of the pancreatic and bile ducts on the pyloric ring.

Statement of Ethics

We obtained the patient's written informed consent to publish this case report and the publication has been approved by our institute's Committee on Human Research.

Disclosure Statement

The authors declare no conflict of interest. There was no grant support.

References

- 1 Langman J: Medical Embryology, ed 4. Baltimore, Williams & Wilkins, 1981, pp 220–222.
- 2 Dawson W, Langman J: An anatomical-radiological study on the pancreatic duct pattern in man. *Anat Rec* 1961;139:59–68.
- 3 Odgers PNB: Some observations of the development of the ventral pancreas in man. *J Anat* 1930;65:1–7.
- 4 Lloyd-Jones W, Mountain JC, Warren KW: Annular pancreas in the adult. *Ann Surg* 1972;176:163–170.
- 5 Tiedemann F: Über die Verschiedenheiten des Ausführungsganges der Bauchspeicherdrüse bei dem Menschen und den Säugetieren. *Dtsch Arch Physiol* 1818;4:403–411.
- 6 Ecker A: Bildungsfehler des Pankreas und des Herzens. *Z Rat Med* 1862;14:354–356.
- 7 Sharma AK, Mishra PK, Chibber S: Annular pancreas: MR and MR pancreaticography a useful tool. *Ind J Radiol Imaging* 2006;16:4:433–437.
- 8 Lecesne R, Stain L, Reinhold L, et al: MR cholangiopancreatography of annular pancreas. *J Comput Assist Tomogr* 1998;22:85–86.
- 9 Clifford MA: Annular pancreas diagnosed by endoscopic retrograde-choledochopancreatography (ERCP). *Br J Radiol* 1980;53:593–595.
- 10 Kandpal H, Bhatia V, Garg P, Sharma R: Annular pancreas in an adult patient: diagnosis with endoscopic ultrasonography and magnetic resonance cholangiopancreatography. *Singapore Med Case Report J* 2009;50:29–31.
- 11 Lecco TM: Zur Morphologie des Pancreas annulare. *Wien Akad Wiss* 1910;199:391–406.
- 12 Tiecken T: Annular pancreas. *Am J Med* 1901;2:826.
- 13 Baldwin WM: A specimen of annular pancreas. *Anat Rec* 1910;4:299–304.
- 14 Kamisawa T, Yuyang T, Egawa N, et al: A new embryologic hypothesis of annular pancreas. *Hepatogastroenterology* 2001;48:277–278.
- 15 Yogi Y, Shibue T, Hashimoto S: Annular pancreas detected in adults, diagnosed by endoscopic retrograde cholangiopancreatography: report of four cases. *Gastroenterol Jpn* 1987;22:92–99.

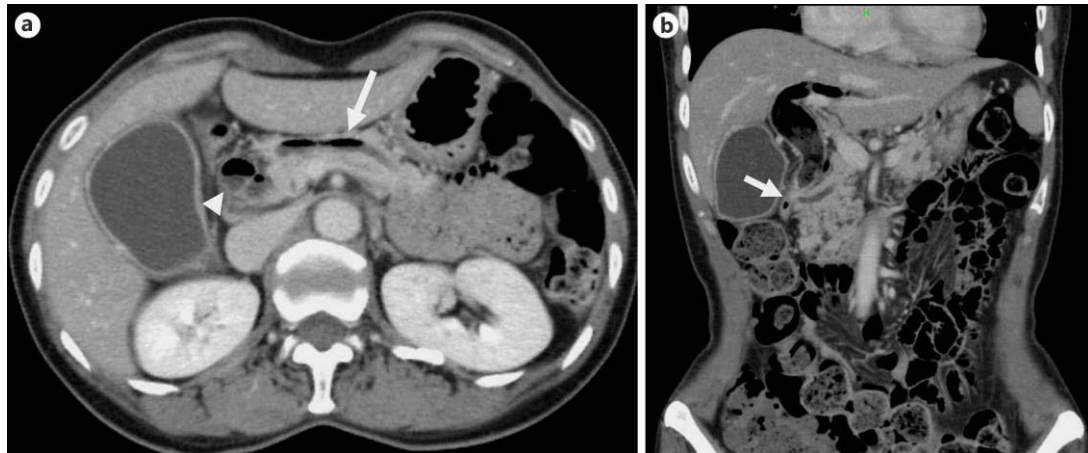


Fig. 1. **a** Contrast computed tomography shows mild pancreatic duct dilation and air density in the pancreatic (arrow) and common bile ducts (arrowhead). **b** The common bile duct shows dilatation. Air density can be seen in the intrahepatic and extrahepatic bile ducts. Orifices of the pancreatic and bile ducts appear to be close to the duodenal bulb (arrow).

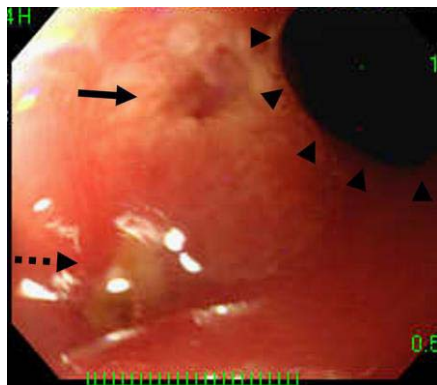


Fig. 2. Upper gastrointestinal endoscopy shows no duodenal papillae in the second segment of the duodenum, but two small juxtaped orifices (arrow) are present on the pyloric ring (arrowhead).

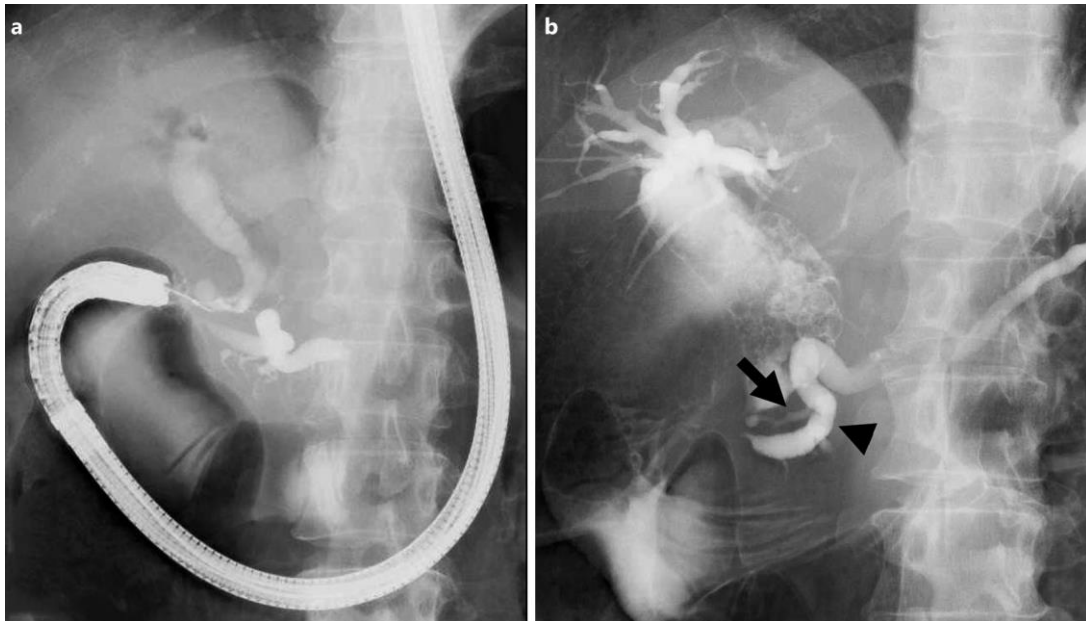


Fig. 3. **a** When contrast agent was administered into each orifice, the bile duct and the pancreatic duct were outlined separately. **b** The duct of Santorini (arrow) showed no dilatation and appeared to be relatively thin as compared to the duct of Wirsung (arrowhead), but both fused at the head of the pancreas, and neither was annular.

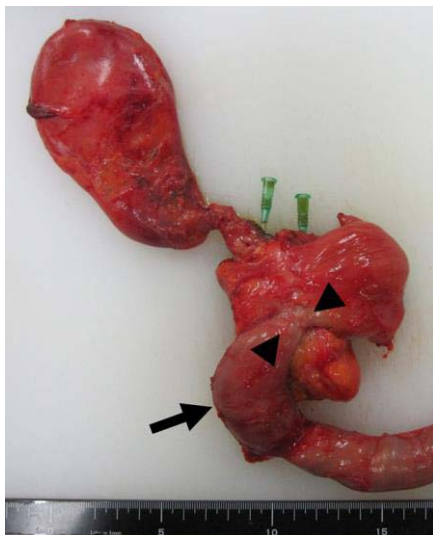


Fig. 4. The ventral pancreas can be seen to surround the pyloric ring (arrowhead) subcircularly and there is no pancreatic tissue at the second segment of the duodenum (arrow). The dorsal pancreas is located in a higher than normal position.

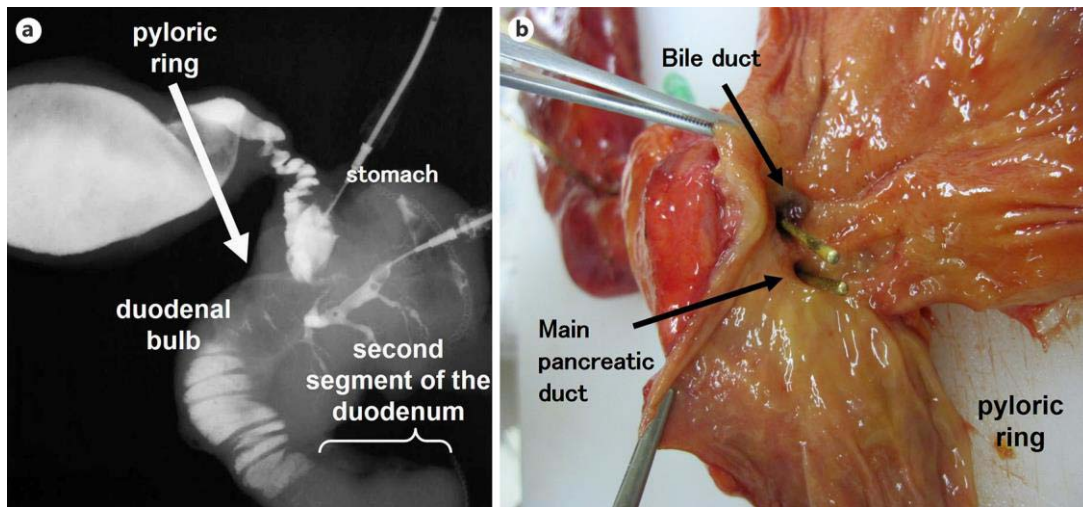


Fig. 5. **a** The ventral pancreas surrounded the pyloric ring subcircularly and no pancreatic tissue was seen at the second segment of the duodenum. **b** Macroscopic findings of the resected specimen also show the orifices of the pancreatic and bile ducts to be located on the pyloric ring.

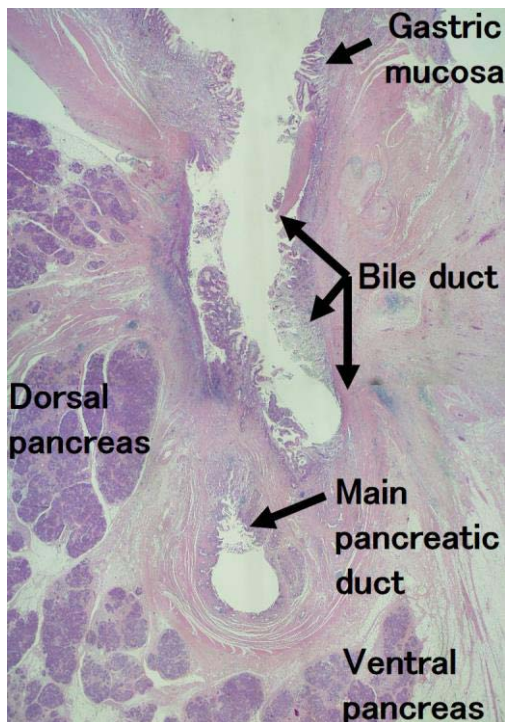


Fig. 6. Histopathological findings demonstrate fibrillization and fatty replacement, mainly in the ventral pancreas. The bile duct also shows ulceration and fibrillization near the orifice (H&E, $\times 20$).