

Original Article

Cochlear Implantation for Patients with a Vestibular Schwannoma: Effect on Tinnitus Handicap

Niels West^{1,2}, Marie Bunne³, Hjalte Sass,^{1,2}, Per Cayé-Thomasen^{1,2}¹Department of Otorhinolaryngology Head & Neck Surgery and Audiology, Rigshospitalet, University Hospital of Copenhagen, Copenhagen, Denmark²Department of Clinical Medicine, University of Copenhagen Faculty of Health and Medical Sciences, Copenhagen, Denmark³Department of Otorhinolaryngology, Oslo University Hospital, Oslo, Norway

ORCID IDs of the authors: N.W. 0000-0002-4556-1309, M.B. 0000-0002-4279-481X, H.S. 0000-0002-7740-8261, P.C.-T. 0000-0002-6837-694X.

Cite this article as: West N, Bunne M, Sass, H, Cayé-Thomasen P. Cochlear implantation for patients with a vestibular schwannoma: Effect on tinnitus handicap. *J Int Adv Otol.* 2022;18(5):382-387.

BACKGROUND: Tinnitus is a common symptom among individuals with a vestibular schwannoma. In recent years, cochlear implantation, often combined with tumor resection, is an increasingly used option in the management of these patients. The existing literature does not account well for the effect of treatment on tinnitus burden. Thus, this paper reports the effect of cochlear implantation on tinnitus in a cohort of vestibular schwannoma patients.

METHODS: Individuals with vestibular schwannoma undergoing cochlear implantation were retrospectively reviewed for tinnitus burden, as evaluated by the Tinnitus Handicap Inventory, administered before and after implantation. The outcome measures were total Tinnitus Handicap Inventory score and scores from each of the Tinnitus Handicap Inventory subdomains (functional, emotional, and catastrophic). In addition, the existing literature on tinnitus in cochlear implanted vestibular schwannoma patients was reviewed.

RESULTS: Tumor management consisted of simultaneous resection (77%), previous resection (9%), observation (9%) and radiation (5%). Complete Tinnitus Handicap Inventory evaluation was available for 17 patients. After implantation, the median THI_{total} changed from 18 to 10 ($P = .0006$), the subdomain $THI_{functional}$ from 10 to 3 ($P = .006$), the $THI_{emotional}$ from 3 to 0 ($P = .023$) and the $THI_{catastrophic}$ from 6 to 1 ($P = .004$). In the scarcely reported tinnitus outcomes in the literature, most but not all cases experienced a decrease in tinnitus.

CONCLUSIONS: The tinnitus burden is significantly reduced by cochlear implantation in individuals with a vestibular schwannoma. This agrees with findings for other etiologies indicating cochlear implantation and supports the eligibility for hearing rehabilitation with a cochlear implant for this specific group of patients.

KEYWORDS: Acoustic neuroma, sensorineural hearing loss, handicap, cochlear implant, treatment, hearing rehabilitation, hearing loss, tinnitus

INTRODUCTION

Vestibular schwannomas (VS) are derived from the vestibulocochlear nerve and the majority is found in the internal auditory canal (IAC) or in the cerebellopontine angle (CPA), although some are located within the labyrinth. The incidence of VS is increasing, likely due to improved and increased access to magnetic resonance imaging technology.¹ The symptoms most commonly associated with VS are ipsilateral hearing loss, tinnitus, and disequilibrium.^{2,3}

As VS tumors are benign in nature, the motive for active tumor management is primarily tumor growth or large size,⁴ secondarily preservation of hearing. Tinnitus is not an indication for active treatment, as several studies have reported a high prevalence of postoperative tinnitus after VS resection. Tinnitus postoperatively was associated with the occurrence of tinnitus preoperatively.^{5,6}

Several studies have documented positive effects of cochlear implantation (CI) on tinnitus, and due to the disabling nature of severe tinnitus, this has increasingly been included as a dependent or independent indication for cochlear implantation.⁷⁻¹⁰ Likewise, cochlear implantation for hearing rehabilitation of sensorineural hearing loss due to a VS is becoming increasingly common in neuro-otology centers around the world.¹¹ A systematic review on sporadic and neurofibromatosis type 2-associated VS undergoing

resection and simultaneous CI showed that the literature is scarce in terms of the effect on tinnitus.¹¹ A recent study reported 8 patients, of which 2 with IAC tumors were elected for resection and implantation due to tinnitus. Tinnitus outcomes were however not reported.¹² Another recent systematic review on sporadic vestibular schwannomas with ipsilateral CI (87% with sequential or simultaneous tumor resection and 13% with tumor in situ) found that the impact on tinnitus was reported in only 7 patients, of which 5 completed a standardized tinnitus assessment tool.¹³

The auditory outcomes of cochlear implantation in VS patients are more unpredictable than in other hearing loss etiologies, as both the tumor and the tumor management can have detrimental effects on the integrity and functionality of the vestibulocochlear nerve. Currently, it is unclear how CI affects tinnitus in individuals with VS. Thus, this study reports the effect of cochlear implantation on tinnitus in a consecutive cohort of VS patients, using a standardized tinnitus assessment instrument—the Tinnitus Handicap Inventory (THI). Additionally, the sparse literature on the effect of CI on tinnitus in individuals with VS is reviewed.

METHODS

Study Design and Participants

A retrospective cohort study of 22 consecutive individuals with VS receiving an ipsilateral CI, operated during the period 2015-2020 was conducted. Pre- and postoperative tinnitus burden was evaluated by the THI.¹⁴

Tinnitus Handicap Inventory is a patient-reported instrument addressing tinnitus handicap, consisting of 25 questions. Included questions can be subdivided into 3 categories: the functional subdomain (11 questions), the emotional subdomain (9 questions), and the catastrophic subdomain (5 questions). Each question can be answered on a graded scale as 0 (no tinnitus), 2 (sometimes), or 4 (yes) points, resulting in a total score ranging from 0 to 100.

Approval to extract and manage data had previously been granted by the Danish Data Protection Agency (2012-58-0004) and the Patient Safety Authority (3-3013-2344/1). Patient consent was not required as per local legislation and national guideline.

Data Analyses

A Shapiro-Wilk test was performed to check for normality in the data distribution. As THI data were not normally distributed, the non-parametric paired *t*-test (Wilcoxon rank) was used. Other data were analyzed with a paired *t*-test. *P*-values <.05 were considered significant. Statistical analyses and illustrations were carried out using the GraphPad Prism software version 8.0 (GraphPad Software, La Jolla, California, USA) for Windows.¹⁵

The literature review was based on the search string “schwannoma AND (cochlear implantation OR cochlear implant)” using the PubMed database.

RESULTS

Between 2015 and 2020, 22 consecutive individuals received a CI ipsilateral to their VS. Among these individuals, 9 were female (41%), and 13 were male (59%). The mean age at the time of implantation was

55 years (range 30-76). In 10 cases (45%), the VS was located in the CPA, in 1 case (5%) it was isolated within the IAC, and in 11 cases (50%), the VS was intralabyrinthine. The VS were sporadic in 21 cases (95%) and related to NF2 in 1 case (5%). Regarding preoperative hearing, 16 cases (73%) had single-sided deafness ipsilateral to the VS, 5 cases (23%) had bilateral sensorineural hearing loss and 1 case (5%) had bilateral normal hearing. 17 cases (77%) underwent cochlear implantation simultaneous to tumor resection, 2 cases (9%) had previously undergone tumor resection and 2 cases (9%) had the tumor left in situ. In addition, 1 case (5%) previously reported¹⁶ was implanted after receiving radiotherapy of the VS. The implanted electrodes were Oticon Medical Neuro Zti EVO in 17 cases (77%), MedEL Flex 26 in 2 cases (9%), Advanced Bionics Midscale and HiRes Ultra 3D in 2 cases (9%) and Cochlear Nucleus 522 in 1 case (5%). At the time of evaluation, the self-reported auditory gain was high in 6 cases (27%), moderate in 10 cases (45%), and low in 6 cases (27%). Daily use was >8 hours/day in 13 cases (59%), between 1 hour/day and 8 hours/day in 3 cases (13%), and <1 hour/day in 3 cases (13%). Information on daily use was unavailable in 2 cases (9%). See Table 1 for patient demography, including tumor localization, surgical details, self-reported tinnitus, etc.

Tinnitus Handicap Inventory Scores

Pre- and postoperative THI scores were available for 17 cases, as only preoperative THI was available for 3 cases and only postoperative THI available for 2 cases, of which 1 qualitatively had reported severe preoperative tinnitus. Among the individuals with both pre- and postoperative THI evaluation, 13 cases (77%) experienced a reduction in tinnitus burden, whereas the burden was stationary in 3 cases (18%) and increased in 1 case (6%).

The median number of days from implantation to completion of the postoperative THI was 234 days (corresponding to approximately 8 months) (interquartile range (IQR) 190 to 302 days). Before implantation, the median total THI score was 18 (IQR 10 to 45) and after implantation the median total THI score was 10 (IQR 0 to 22) (*P* = .0006; Wilcoxon). Regarding THI subdomains, the median functional subdomain score was 10 (IQR 3 to 20) before and 3 (IQR 0 to 14) after the implantation (*P* = .006; Wilcoxon), the median emotional subdomain score was 3 (IQR 0 to 16) before and 0 (IQR 0 to 4) after implantation (*P* = .023; Wilcoxon), whereas the median catastrophic subdomain score was 6 (IQR 3 to 10) before implantation and 1 (IQR 0 to 6) after implantation (*P* = .004; Wilcoxon). Data on THI scores including subdomain scores are plotted in Figure 1. Figure 2 shows the individual change in total THI from pre- to postoperative.

Individuals with self-reported moderate or high auditory gain had a median THI change of -14 points (IQR -24 to -2) compared with those with low auditory gain who had a median THI change of -4 points (IQR -17 to 3) (*P* = .29; paired *t*-test). Individuals with a high daily use (>8 hours) had a median THI change of -15 points (IQR -24 to -2) compared with those with a rare daily use (<1 hour) who had a median THI change of -2 points (IQR -6 to 4) (*P* = .093; paired *t*-test). Two individuals with low self-reported auditory gain and limited daily use (ID 8 and 9) reported a substantial reduction in tinnitus when wearing the CI processor.

Literature Review

Considering the existing literature, tinnitus outcomes in relation to VS and ipsilateral CI have been reported in 9 papers,¹⁷⁻²⁵ including

Table 1. Overview of the 22 Individuals with VS Receiving Ipsilateral CI

ID	Sex	Age	Preop Hearing	VS	Side	VS management	Electrode	Preoperative THI				Postoperative THI			
								Functional	Emotional	Catastrophic	Total	Functional	Emotional	Catastrophic	Total
1	M	30	SSD	Intralab	Left	Simultaneous resection	OM Neuro Zti EVO	10 (62%)	0 (0%)	6 (38%)	16	0 (0%)	0 (0%)	0 (0%)	0
2	M	37	SSD	Intralab	Left	Simultaneous resection	CI Nucleus 522	20 (42%)	16 (33%)	12 (25%)	48	10 (50%)	4 (20%)	6 (30%)	20
3	F	40	NH	CPA	Right	Simultaneous resection (TLA)	OM Neuro Zti EVO	0 (0%)	0 (0%)	0 (0%)	0	NA	NA	NA	NA
4	F	43	Bilat HL	CPA	Right	Simultaneous resection (TLA)	OM Neuro Zti EVO	18 (47%)	8 (21%)	12 (32%)	38	18 (48%)	10 (26%)	10 (26%)	38
5	F	46	SSD	Intralab	Left	Simultaneous resection	OM Neuro Zti EVO	12 (60%)	2 (10%)	6 (30%)	20	NA	NA	NA	NA
6	M	48	SSD	CPA	Right	Simultaneous resection (TLA)	OM Neuro Zti EVO	6 (50%)	2 (17%)	4 (33%)	12	12 (75%)	0 (0%)	4 (25%)	16
7	M	49	SSD	Intralab	Right	Simultaneous resection	MedEL Flex 26	NA	NA	NA	28	12 (50%)	12 (50%)	0 (0%)	24
8	F	53	SSD	CPA	Left	Simultaneous resection (RLA)	OM Neuro Zti EVO	NA	NA	NA	NA	0 (0%)	0 (0%)	0 (0%)	0
9	M	53	SSD	CPA	Left	Previous resection (RLA)	AB midscale	32 (47%)	22 (32%)	14 (27%)	68	26 (54%)	8 (17%)	14 (29%)	48
10	M	54	Bilat HL	CPA	Bilat*	Radiation*	HiRes Ultra 3D (AB?)	16 (67%)	0 (0%)	8 (33%)	24	0 (0%)	0 (0%)	0 (0%)	0
11	F	54	SSD	Intralab	Left	Observation	OM Neuro Zti EVO	8 (57%)	4 (29%)	2 (14%)	14	2 (29%)	2 (29%)	3 (43%)	7
12	F	54	SSD	CPA	Right	Simultaneous resection (TLA)	OM Neuro Zti EVO	10 (56%)	0 (0%)	8 (44%)	18	NA	NA	NA	18
13	F	54	SSD	Intralab	Left	Simultaneous resection	MedEL Flex 28	30 (55%)	16 (30%)	8 (15%)	54	16 (53%)	8 (27%)	6 (20%)	30
14	M	54	SSD	CPA	Left	Simultaneous resection (TLA)	OM Neuro Zti EVO	NA	NA	NA	++	0 (0%)	0 (0%)	0 (0%)	0
15	M	61	SSD	IAC	Left	Observation	OM Neuro Zti EVO	28 (61%)	22 (48%)	10 (22%)	46	10 (100%)	0 (0%)	0 (0%)	10
16	M	66	SSD	Intralab	Right	Simultaneous resection	OM Neuro Zti EVO	10 (56%)	4 (22%)	4 (22%)	18	4 (100%)	0 (0%)	0 (0%)	4
17	M	66	Bilat HL	Intralab	Left	Simultaneous resection	OM Neuro Zti EVO	16 (36%)	20 (46%)	8 (18%)	44	14 (70%)	4 (20%)	2 (10%)	20
18	M	67	SSD	CPA	Right	Previous resection(RLA)	OM Neuro Zti EVO	2 (100%)	0 (0%)	0 (0%)	2	0 (0%)	0 (0%)	0 (0%)	0
19	M	69	Bilat HL	CPA	Right	Simultaneous resection (TLA)	OM Neuro Zti EVO	NA	NA	NA	56	NA	NA	NA	NA
20	F	70	SSD	Intralab	Left	Simultaneous resection	OM Neuro Zti EVO	0 (0%)	0 (0%)	0 (0%)	0	0 (0%)	0 (0%)	0 (0%)	0
21	F	71	SSD	Intralab	Right	Simultaneous resection	OM Neuro Zti EVO	10 (71%)	0 (0%)	4 (29%)	14	2 (25%)	2 (25%)	4 (50%)	8
22	M	76	Bilat HL	Intralab	Left	Simultaneous resection	OM Neuro Zti EVO	0 (0%)	0 (0%)	6 (100%)	6	0 (0%)	0 (0%)	0 (0%)	0

*Previously published case (26);

++, subjective severe tinnitus (no THI available);

AB, Advanced Bionics; Bilat, bilateral; CPA, cerebellopontine angle; F, female; HL, hearing loss; IAC, internal acoustic canal; M, male; OM, Oticon Medical; NA, not available; NH, normal hearing; RLA, retrolabyrinthine approach; SSD, single-sided deafness; THI, tinnitus handicap inventory; TLA, translabyrinthine approach; VS, vestibular schwannoma.

Tinnitus and vestibular schwannoma before and after CI

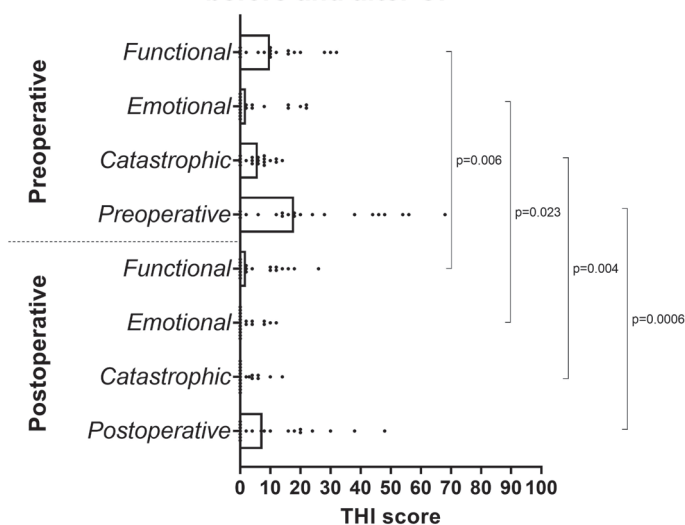


Figure 1. Tinnitus in a consecutive cohort of VS patients (n=16) before and after cochlear implantation, according to total THI scores and subdomain scores. Individual scores plotted with bars indicating medians. CI, cochlear implantation; THI, tinnitus handicap inventory Preoperative indicates total preoperative THI score; Postoperative indicates total postoperative THI score.

a total of 20 patients (see Table 2). All but 3^{19,23,25} of these were case reports. The 3 non-case reports included 3, 4, and 7 patients, respectively. Six of the studies report simultaneous VS resection and concomitant CI,^{17,18,20,23-25} 2 studies report a CI sequential to previous tumor resection^{19,22} and 1 study reports CI in an ear with a tumor under observation.²¹ In 3 papers, the THI is used for quantification of tinnitus,²¹⁻²³ 2 papers use other measurement tools,^{24,25} 1 paper uses the Visual Analog Scale¹⁹ and in the 3 remaining papers, the tinnitus change is only qualitatively reported.^{17,18,20} In 6 papers,^{17-20,23,24} Cochlear implantation is reported to improve tinnitus burden and in 1 paper,²¹ tinnitus is worse after CI. One paper reports that tinnitus is initially worsened after tumor resection and subsequently improved after the CI.²² Finally, the recently published study of Dahm et al.²⁵ reports variable tinnitus outcomes, with stable tinnitus for 3 patients and 1 patient experiencing a tinnitus increase.

Total tinnitus before and after implantation

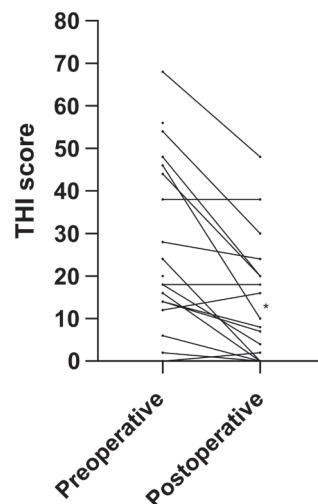


Figure 2. Individual changes in total THI scores from pre- to postoperative (n=16). This case experienced an increase in tinnitus after implantation. THI, tinnitus handicap inventory.

DISCUSSION

Cochlear implantation for patients with a VS is an increasingly offered operation, either as a simultaneous or sequential procedure in relation to VS resection, or for observed tumors without resection. However, until now no extensive reports on tinnitus change as a result of this operation have been published (see Table 2). This is a paradox, as tinnitus may be the main indication for CI in single-sided deafness, including VS cases.^{10,12} Previous studies have shown that CI in general can have a positive effect on tinnitus, regardless of the hearing loss etiology. However, VS patients are exceptional as the tumor represents a lesion on the vestibulocochlear nerve, and as for hearing outcomes, tinnitus outcomes may be more unpredictable than in other CI recipients.¹¹ We found that among 22 consecutive individuals with VS receiving CI, the vast majority experience a substantial drop in tinnitus burden after the operation. The cohort included 1 case experiencing a worsening of tinnitus, which has

Table 2. Overview of the Literature on Tinnitus Following Ipsilateral Cochlear Implantation in Patients with a Vestibular Schwannoma

Author	n	VS	Tumor management	Reported tinnitus
Schutt 2013 (17)	1	Intravestibulocochlear	Simultaneous resection	Tinnitus improved (unspecified)
Bento 2016 (18)	1	Intracochlear	Simultaneous resection	Tinnitus improved (unspecified)
Kim 2016 (20)	1	Intracanalicular	Simultaneous resection	Tinnitus improved (unspecified)
Huo 2016 (21)	1	Intracanalicular	Observation	Tinnitus worsened (THI increase)
Dagna 2016 (22)	1	Intracanalicular	Sequential operation	Tinnitus worsening after resection and improvement after CI (THI)
Rooth 2017 (23)	7	Extrameatal	Simultaneous resection	Tinnitus improved (THI decrease)
Ma 2020 (24)	1	Intracochlear	Simultaneous resection	Tinnitus improved (TRQ)
Dahm 2020 (25)	4	Intra- or extrameatal*	Simultaneous resection	Variable tinnitus changes (Mini-TQ)
Hassepass 2016 (19)	3**	Intralabyrinthine or intracanalicular	Sequential operation	Complete tinnitus suppression upon processor activation (VAS)

Reported cases with VS and contralateral implantation are not listed.

*Specific location not reported, but translabyrinthine approach used indicates non-intralabyrinthine location.

**Another 8 patients were studied, but tinnitus outcomes were not reported.

THI, Tinnitus Handicap Inventory; TRQ, Tinnitus Reaction Questionnaire; Mini-TQ, Mini Tinnitus Questionnaire; VAS, Visual Analog Scale.

also been reported for a few of the previously published cases. Thus, although we can conclude that a significant reduction of tinnitus is the most common finding in this cohort, a worsening of tinnitus may occur in rare cases.

The findings also show that the functional domain is the factor dominating the overall tinnitus score, both before and after implantation. The most substantial postoperative drop is also occurring in the functional domain. Although the catastrophic subdomain is represented by only a few THI items (5 of the 25 items), this domain is the second most influential domain (Figure 1). This explains why the decrease in scores is more significant for these subdomains compared with the emotional one, which is the least affected domain both pre- and post-implantation.

The somewhat ambiguous methods for evaluation of tinnitus may be a limitation to the present and previous studies, as patients may not be adequately instructed to distinguish between the 2 ears, or between the situation with or without an activated processor on the implanted ear. As reported in the study of Hassepass et al. the tinnitus suppression post-implantation was directly dependent on the activation of the processor.¹⁹ Future studies should be more attentive to such details, as the patient responses may differ depending on to which condition the patient refers. Another limitation of the present study is the single postoperative follow-up. Subsequent studies should investigate repeated follow-ups, as performed in the study of Rooth et al.²³ to reveal whether the observed postoperative changes are stationary and to what extent they depend on the CI being switched on or off.

As most of the individuals in the present cohort underwent tumor resection with concomitant CI in single-stage procedures, it was not possible to distinguish between the isolated effect on tinnitus of the implantation and the tumor removal. Thus, theoretically, the tumor management may per se account for some of the observed tinnitus reduction. Nonetheless, the 2 patients who underwent tumor resection and sequential CI, and the 2 patients with observed tumors all experienced a reduction in tinnitus after implantation, suggesting that the tinnitus improvement is indeed attributed to the CI, which is consistent with the finding in 2 studies allowing differentiation between the 2 procedures.^{19,22}

CONCLUSION

This is the first larger study to specifically investigate tinnitus outcomes related to CI for patients with a VS, using the validated THI as an instrument. Most patients receiving a CI ipsilateral to a VS, independent of the type of tumor management, experience a reduction of tinnitus burden. Overall, tinnitus improves significantly after implantation. This information is clinically important and may be used in the decision-making concerning tumor management and hearing rehabilitation in individuals with a VS. Specifically, CI eligibility is supported by the occurrence of severe preoperative tinnitus.

Ethics Committee Approval: Ethical committee approval was not applicable. Approval to extract and manage data had previously been granted by the Danish Data Protection Agency (2012-58-0004) and the Patient Safety Authority (3-3013-2344/1).

Informed Consent: N/A.

Peer-review: Externally peer-reviewed.

Author Contributions: Concept – N.W., P.C.T.; Design – N.W.; Supervision – P.C.T.; Resource – N.W., M.B., P.C.T.; Materials – P.C.T.; Data Collection and/or Processing – N.W., M.B., H.S., P.C.T.; Analysis and/or Interpretation – N.W., P.C.T.; Literature Search – N.W.; Writing Manuscript – N.W., P.C.T.; Critical Reviews – M.B., P.C.T.

Declaration of Interests: The authors declare that they have no conflict of interest.

Funding: The authors declared that this study has received no financial support.

REFERENCES

1. Reznitsky M, Petersen MMBS, West N, Stangerup SE, Cayé-Thomasen P. Epidemiology of vestibular schwannomas – prospective 40-year data from an unselected national cohort. *Clin Epidemiol*. 2019;11:981-986. [\[CrossRef\]](#)
2. West N, Møller MN, Hansen S, Cayé-Thomasen P. Audiovestibular loss of function correlates in vestibular schwannomas. *J Int Adv Otol*. 2018; 14(2):161-165. [\[CrossRef\]](#)
3. Kentala E, Pyykkö I. Clinical picture of vestibular schwannoma. *Auris nasus larynx*. 2001;28(1):15-22. [\[CrossRef\]](#)
4. Stangerup SE, Cayé-Thomasen P. Epidemiology and natural history of vestibular schwannomas. *Otolaryngol Clin North Am*. 2012;45(2):257-268. [\[CrossRef\]](#)
5. Trakolis L, Ebner FH, Machetanz K, Sandritter J, Tatagiba M, Naros G. Postoperative tinnitus After vestibular schwannoma surgery depends on preoperative tinnitus and both pre- and postoperative hearing function. *Front Neurol*. 2018;9:136. [\[CrossRef\]](#)
6. Bell JR, Anderson-Kim SJ, Low C, Leonetti JP. The persistence of tinnitus after acoustic neuroma surgery. *Otolaryngol Head Neck Surg*. 2016; 155(2):317-323. [\[CrossRef\]](#)
7. Vermeire K, Van de Heyning P. Binaural hearing after cochlear implantation in subjects with unilateral sensorineural deafness and tinnitus. *Audiol Neurootol*. 2009;14(3):163-171. [\[CrossRef\]](#)
8. Punte AK, Vermeire K, Hofkens A, De Bodt M, De Ridder D, Van de Heyning P. Cochlear implantation as a durable tinnitus treatment in single-sided deafness. *Cochlear Implants Int*. 2011;12(suppl 1):S26-S29. [\[CrossRef\]](#)
9. Finke M, Bönitz H, Lyxell B, Illg A. Cochlear implant effectiveness in postlingual single-sided deaf individuals: what's the point? *Int J Audiol*. 2017;56(6):417-423. [\[CrossRef\]](#)
10. Friedmann DR, Ahmed OH, McMenomey SO, Shapiro WH, Waltzman SB, Roland JT. Single-sided deafness cochlear implantation: candidacy, evaluation, and outcomes in children and adults. *Otol Neurotol*. 2016;37(2): e154-e160. [\[CrossRef\]](#)
11. West N, Sass H, Cayé-Thomasen P. Sporadic and NF2-associated vestibular schwannoma surgery and simultaneous cochlear implantation: a comparative systematic review. *Eur Arch Otorhinolaryngol*. 2020;277(2): 333-342. [\[CrossRef\]](#)
12. Roberts S, Levin B, Sanli H, Ferch R, Kong K, Eisenberg R. Simultaneous cochlear implantation and removal of acoustic neuroma: implications for hearing. *J Laryngol Otol*. 2020;134(6):519-525. [\[CrossRef\]](#)
13. Bartindale MR, Tadokoro KS, Kircher ML. Cochlear implantation in sporadic vestibular schwannoma: A systematic literature review. *J Neurol Surg B Skull Base*. 2019;80(6):632-639. [\[CrossRef\]](#)
14. Newman CW, Jacobson GP, Spitzer JB. Development of the tinnitus handicap inventory. *Arch Otolaryngol Head Neck Surg*. 1996;122(2):143-148. [\[CrossRef\]](#)
15. GraphPad Software. 2020. Available at: www.graphpad.com
16. Tian L, West N, Cayé-Thomasen P. Cochlear implantation after radiotherapy of vestibular schwannomas. *J Int Adv Otol*. 2021;17(5):452-460.

17. Schutt CA, Kveton JF. Cochlear implantation after resection of an intralabyrinthine schwannoma. *Am J Otolaryngol*. 2014;35(2):257-260. [\[CrossRef\]](#)
18. Bento RF, Gebrim EMMS, Magalhães ATDM, Pereira LV, Fonseca ACDO. Minimally invasive surgery for intracochlear schwannoma removal and simultaneous cochlear implantation. *Int Arch Orl*. 2016;20(3):271-274. [\[CrossRef\]](#)
19. Hassepass F, Arndt S, Aschendorff A, Laszig R, Wesarg T. Cochlear implantation for hearing rehabilitation in single-sided deafness after translabyrinthine vestibular schwannoma surgery. *Eur Arch Otorhinolaryngol*. 2016;273(9):2373-2383. [\[CrossRef\]](#)
20. Kim JW, Han JH, Kim JW, Moon IS. Simultaneous translabyrinthine tumor removal and cochlear implantation in vestibular schwannoma patients. *Yonsei Med J*. 2016;57(6):1535-1539. [\[CrossRef\]](#)
21. Huo Z, Zhang Z, Huang Q, et al. Hearing restoration for adults with vestibular schwannoma in the only hearing ear: ipsilateral or contralateral cochlear implantation? *ORL J Otorhinolaryngol Relat Spec*. 2016;78(5):281-288. [\[CrossRef\]](#)
22. Dagna F, Murri A, Albera R, Cuda D. Cochlear implantation in delayed sudden hearing loss after conservative vestibular schwannoma surgery. *Acta Otorhinolaryngol Ital*. 2016;36(5):428-430. [\[CrossRef\]](#)
23. Rooth MA, Dillon MT, Brown KD. Prospective evaluation of patients undergoing translabyrinthine excision of vestibular schwannoma with concurrent cochlear implantation. *Otol Neurotol*. 2017;38(10):1512-1516. [\[CrossRef\]](#)
24. Ma AK, Patel N. Endoscope-assisted partial Cochlectomy for intracochlear schwannoma with simultaneous cochlear implantation: A case report. *Otol Neurotol*. 2020;41(3):334-338. [\[CrossRef\]](#)
25. Dahm V, Auinger AB, Honeder C, et al. Simultaneous vestibular schwannoma resection and cochlear implantation using electrically evoked auditory brainstem response audiometry for decision-making. *Otol Neurotol*. 2020;41(9):1266-1273. [\[CrossRef\]](#)