



Skin Excision as an Adjunctive Technique to Rhinoplasty in Middle-Aged and Elderly Patients

Stephanie A. Caterson, MD
 Mansher Singh, MD
 Maximilian Kueckelhaus, MD
 E. J. Caterson, MD, PhD
 Elof Eriksson, MD, PhD

Summary: Rhinoplasty in middle-aged and elderly patients comes with its own set of challenges. There is relative lengthening of the nose with drooping of the nasal tip. With aging, the skin loses its elasticity, and the combination of nasal skeletal reduction along with overlying inelastic skin provides a setup for skin redundancy and poor postoperative outcome. We describe a surgical technique involving lenticular skin excision as a part of rhinoplasty in 12 patients older than 50 years to improve the aesthetic outcome. Skin width up to 1.6 cm was excised. Included is a literature review of skin excision in rhinoplasty. In elderly patients with thin, inelastic skin and long nose with a drooping tip, a reduction rhinoplasty technique might result in skin redundancy. Lenticular skin excision along the radix of the nose in these 12 patients improved the aesthetic outcome by decreasing the redundancy and preventing nasal tip ptosis. The wound from the skin resection healed in all the patients with minimal scar, and no complication was noted after at least 1 year of follow-up for each patient. (*Plast Reconstr Surg Glob Open* 2015;3:e532; doi: 10.1097/GOX.0000000000000509; Published online 9 October 2015.)

Rhinoplasty is now being increasingly performed in the middle-aged and elderly population. Approximately 20% of all rhinoplasty procedures in the United States are performed on patients who are older than 55 years.¹ In older patients, rhinoplasty presents a very different challenge compared with that in the younger individuals.² It is very important to characterize the anatomic and viscoelastic changes in the nose while planning rhinoplasty in the aging population.³⁻⁹ There is relative lengthening of the nose with drooping of the nasal

tip and increased prominence of dorsal hump in elderly patients.³⁻⁶ In a younger individual, the nasal skin shrinks and adapts over the reduced nasal skeleton because of its natural elasticity. With aging, the skin loses its elasticity.^{7,8} As such, a combination of nasal skeletal reduction with overlying inelastic skin provides a setup for redundancy and poor postoperative outcome. Multiple techniques have been described to overcome these problems including supratip advancement sutures, postoperative triamcinolone, and defatting.⁹⁻¹² Nasal skin resection for rhinoplasty has also been described.¹³⁻¹⁸ In our study, we describe a lenticular nasal root skin removal as a part of rhinoplasty in middle-aged and elderly patients. Excision of nasal skin in these selected patients will decrease the potential for nasal tip ptosis and result in improved aesthetic outcomes.

From the Division of Plastic Surgery, Brigham and Women's Hospital, Boston, Mass.

Received for publication May 22, 2015; accepted August 4, 2015.

Copyright © 2015 The Authors. Published by Wolters Kluwer Health, Inc. on behalf of The American Society of Plastic Surgeons. All rights reserved. This is an open-access article distributed under the terms of the Creative Commons Attribution-Non Commercial-No Derivatives License 4.0 (CCBY-NC-ND), where it is permissible to download and share the work provided it is properly cited. The work cannot be changed in any way or used commercially.

DOI: 10.1097/GOX.0000000000000509

Disclosure: *The authors have no financial interest to declare in relation to the content of this article. The Article Processing Charge was paid for by the authors.*

Supplemental digital content is available for this article. Clickable URL citations appear in the text.

SURGICAL TECHNIQUE

We reserved external skin excision technique for patients who were at least 50 years old. Among this patient cohort, the operating surgeon used his discretion to identify the patients with skin redundancy, after trimming of nasal skeletal components, who would benefit from this technique. In general, if the patient had more than 1 cm of vertical redundancy of skin, it was considered an indication for skin resection. Twelve patients were operated on using this technique. Most of these patients had either a very large nose or drooping tip or a dorsal hump.

An open rhinoplasty approach with wide nasal skin undermining was performed. Tip and dorsum manipulation, dissection of caudal septum, osteotomies, and sometimes, alar base resection were done as needed. A lenticular horizontal excision was then performed along the level of nasal radix (Supplemental Digital Content 1, which shows lenticular skin excision at the nasal root as a part of rhinoplasty in a representative patient, <http://links.lww.com/PRSGO/A132>). The flap was pulled up till the skin had been tightened. A full thickness skin excision down to nasalis muscle was then performed after confirming the extent of the excision. Skin up to 1.6 cm in width was excised. The incision was then closed in 2 layers with a 5-0 monocryl and 6-0 nylon.

RESULTS

We have performed this technique on 12 patients with at least 1 year of follow-up for each patient. All

our patients had a good aesthetic outcome with no skin redundancy and decreased nasal tip ptosis. We have included a representative preoperative and postoperative picture of rhinoplasty with skin excision showing portrait views and lateral views (Figs. 1, 2). The wound from the skin resection healed in all the patients with minimal scar. The mean Vancouver scar scale of our patients was 0.5 at 1 year follow-up, which indicates very good healing.¹⁹

DISCUSSION

Rhinoplasty in elderly patients presents a unique challenge to the operating surgeon.² The nasal dorsum also assumes a more convex character with aging because of downward rotation of the lobule and columellar retraction.⁶ There is an increased density of sebaceous glands in the nasal tip and alae, resulting in a fuller appearance of the nasal tip complex.¹⁶ The nasal tip also becomes “droopy” (ptotic) with aging mainly because of weakened fibroelastic attachments between the upper and lower lateral cartilages, resulting in downward migration of the lateral crura.^{3,5} With aging, the skin loses elasticity along with thinning of dermis and decreased dermal collagen content.^{7,8}

Skin excision in rhinoplasty has been described in few previous studies. However, the techniques and indications in these limited studies have significant variations from our described study. Joseph¹³ listed 43 operations where he only performed external skin excisions. In such extreme cases, he described

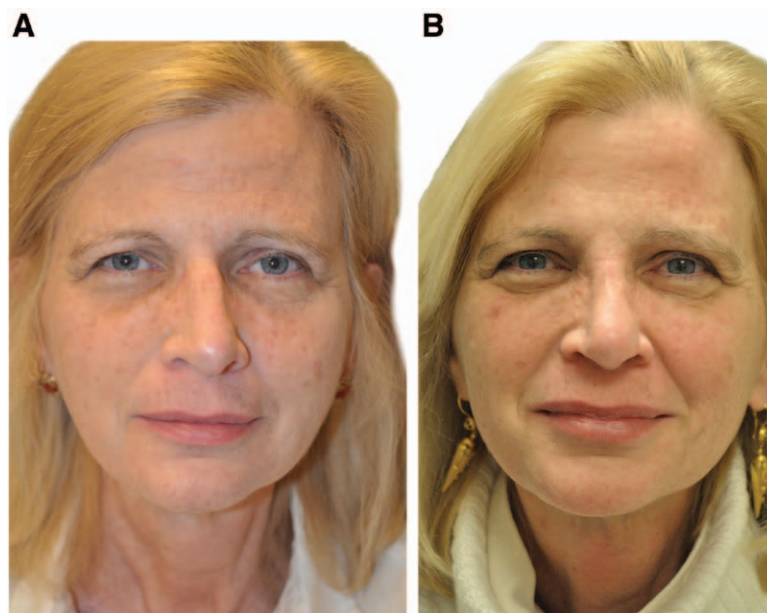

Fig. 1. Preoperative (A) and postoperative (B) portrait view of a representative patient undergoing rhinoplasty with lenticular skin excision.

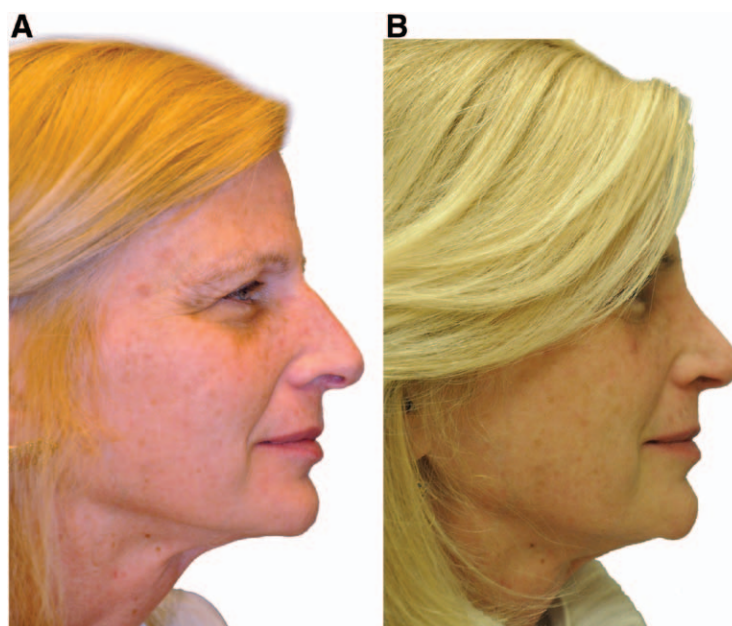


Fig. 2. Preoperative (A) and postoperative (B) lateral view of a representative patient undergoing rhinoplasty with lenticular skin excision.

rhinoplasty as “nasal reduction plasty.”^{13,14} Ozturan et al¹⁵ described a wide-open dorsal approach rhinoplasty for droopy noses. This technique involved a wide incision on the dorsum of the nose with removal of the skin and the underlying tissue.¹⁵ However, there is increased risk of scar because of increased tension in this region compared with the root of the nose. Lemperle and Biewener¹⁶ advocated vertical skin excision for sebaceous nose with supratip deformity. Even though this technique resulted in removal of sebaceous skin, it caused a visible scar that required dermabrasion.¹⁶ Kabaker¹⁷ demonstrated improvement in nasal tip ptosis and dorsal hump with skin excision across the bridge of the nose.

In younger patients, correction of tip ptosis benefits from the development of wound contraction and scar tissue, which pulls the trimmed lower lateral cartilages upward.¹⁷ The overlying skin contracts to fit the smaller nose, and skin resection is not needed. In elderly patients undergoing rhinoplasty, the relatively longer nose with a dorsal hump and droopy tip coupled with lax skin with poor elasticity can result in poor aesthetic outcomes.^{3–8} As such, resection of excessive skin can prevent redundancy and decrease postoperative tip ptosis. Because of abundance of sebaceous cyst in the lower portion of the nose, any incision in this region would likely result in a conspicuous scar. The thin skin around the root of the nose will heal with minimal scar. Based on these factors, our skin excision is located at the root of the nose.

With this technique, we demonstrated very good postoperative outcome with lenticular nasal skin

excisions. In our experience, all the wounds from the skin resection healed with minimal scar, and the resulting smaller soft-tissue envelope provided a better coverage to the underlying osseocartilaginous framework.

CONCLUSIONS

In elderly patients with inelastic skin and long nose with a drooping tip, standard rhinoplasty techniques might result in skin redundancy. Lenticular skin excision along the root of the nose in such patients can improve the aesthetic outcome by decreasing the redundancy and preventing nasal tip ptosis.

Elof Eriksson, MD, PhD

Division of Plastic Surgery
Brigham and Women’s Hospital
Harvard Medical School
75 Francis St, Boston, MA 02115
E-mail: eeriksson@partners.org

PATIENTS CONSENT

The patient provided written consent for the use of her images.

REFERENCES

1. Available at: <http://www.plasticsurgery.org/Documents/news-resources/statistics/2013-statistics/plastic-surgery-statistics-full-report-2013.pdf>. Accessed March 21, 2011
2. Rohrich RJ, Hollier LH Jr, Janis JE, et al. Rhinoplasty with advancing age. *Plast Reconstr Surg*. 2004;114:1936–1944.
3. Krmpotić-Nemanić J, Kostović I, Rudan P, et al. Morphological and histological changes responsible

- for the droop of the nasal tip in advanced age. *Acta Otolaryngol.* 1971;71:278–281.
4. Parkes ML, Kamer FM. The mature nose. *Laryngoscope.* 1973;83:157–166.
 5. Patterson CN. The aging nose: characteristics and correction. *Otolaryngol Clin North Am.* 1980;13:275–288.
 6. Rohrich RJ, Hollier LH, Gunter JP. The aging nose. In: *Dallas Rhinoplasty Symposium* 18; 2001. Pp. 981.
 7. Yaar M, Gilchrest BA. Skin aging: postulated mechanisms and consequent changes in structure and function. *Clin Geriatr Med.* 2001;17:617–630, v.
 8. Gilchrest BA. Age-associated changes in the skin. *J Am Geriatr Soc.* 1982;30:139–143.
 9. Guyuron B, DeLuca L, Lash R. Supratip deformity: a closer look. *Plast Reconstr Surg.* 2000;105:1140–1151; discussion 1152.
 10. Hanasono MM, Kridel RW, Pastorek NJ, et al. Correction of the soft tissue pollybeak using triamcinolone injection. *Arch Facial Plast Surg.* 2002;4:26–30; discussion 31.
 11. Kim SK, Kim JC, Kim JC, et al. Correction of the supratip deformity of the nose. *Aesthet Surg J.* 2012;32:943–955.
 12. Hafezi F, Naghibzadeh B, Nouhi A. Management of the thick-skinned nose: a more effective approach. *Ann Otol Rhinol Laryngol.* 2006;115:444–449.
 13. Joseph J. Nasenverkleinerungen (mit Krankenvorstellung). *Dtsch Med Wochenschr* 1904;30:1094.
 14. Rogers BO. John Orlando Roe—not Jacques Joseph—the father of aesthetic rhinoplasty. *Aesthetic Plast Surg.* 1986;10:63–88.
 15. Ozturan O, Ozucer B, Aksoy F, et al. Wide-open dorsal approach rhinoplasty for droopy noses. *Aesthetic Plast Surg* 2015;39:25–35.
 16. Lemperle G, Biewener A. External skin excision in the sebaceous nose and supratip deformity. *Aesthetic Plast Surg.* 1992;16:303–307.
 17. Kabaker SS. An adjunctive technique to rhinoplasty of the aging nose. *Head Neck Surg.* 1980;2:276–281.
 18. Gubisch W. [The large nose—an esthetic, but also a functional problem]. *Laryngorhinootologie.* 1994;73:244–248.
 19. Fearmonti R, Bond J, Erdmann D, et al. A review of scar scales and scar measuring devices. *Eplasty.* 2010;10:e43.