


Combined Dacomitinib and Selpercatinib Treatment for a Patient with *EGFR*-Mutant Non-Small Cell Lung Cancer and Acquired *CCDC6-RET* Fusion

Cheng-Yin Liu^{1,2}, Chia-Hsin Liu¹ 

¹Division of Pulmonary and Critical Care Medicine, Department of Internal Medicine, Tri-Service General Hospital, National Defense Medical Center, Taipei, Taiwan; ²Department of Internal Medicine, Hualien Armed Forces General Hospital, Hualien City, Taiwan

Correspondence: Chia-Hsin Liu, Division of Pulmonary and Critical Care Medicine, Department of Internal Medicine, Tri-Service General Hospital, National Defense Medical Center, 325, Section 2, Cheng-Gung Road, Nei-Hu Dist. 114, Taipei, Taiwan, Tel +886-2-8792-3311 Ext 16881, Email arron12182012@gmail.com

Abstract: *RET* rearrangements are recognized drivers in lung cancer, representing a small subset (1–2%) of non-small cell lung cancer (NSCLC). Additionally, *RET* fusions also serve as a rare acquired resistance mechanism in *EGFR*-mutant NSCLC. Only a few NSCLC cases have been reported with co-occurrence of *EGFR* mutations and *RET* fusions as an acquired resistance mechanism induced by *EGFR*-tyrosine kinase inhibitors (TKIs). A 68-year-old man diagnosed with lung adenocarcinoma harboring *EGFR* L858R mutation initially responded well to dacomitinib, a second-generation *EGFR*-tyrosine kinase inhibitor (TKI). Afterward, he developed acquired resistance accompanied by a *RET* rearrangement. Next-generation sequencing (NGS) analysis revealed that the tumor possessed both the new *CCDC6-RET* fusion and the *EGFR* L858R mutation. Subsequently, he was treated with a combination of cisplatin, pemetrexed, and bevacizumab resulting in a partial response. Nevertheless, his condition deteriorated as the disease progressed, manifesting as hydrocephalus, accompanied by altered consciousness and lower limb weakness. The subsequent combined treatment with dacomitinib and selpercatinib resulted in a significant improvement in neurological symptoms. Here, we first identified acquired *CCDC6-RET* fusion with a coexisting *EGFR* L858R mutation following dacomitinib treatment. Our findings highlight the importance of NGS for identifying *RET* fusions and suggest the potential combination of dacomitinib and selpercatinib to overcome this resistance. For NSCLC patients with *RET* rearrangements and no access to *RET* inhibitors, pemetrexed-based chemotherapy provides a feasible alternative.

Keywords: NSCLC, *RET* rearrangement, *EGFR* mutation, dacomitinib, selpercatinib, NGS

Introduction

Dacomitinib, an irreversible second-generation epidermal growth factor receptor tyrosine kinase inhibitor (EGFR-TKI), has shown superior progression-free survival (PFS) and overall survival (OS) over gefitinib in patients with advanced non-small cell lung cancer (NSCLC) in the ARCHER 1050 study.^{1,2} Nevertheless, despite high initial response rates, patients typically develop acquired resistance to dacomitinib treatment after approximately 1 to 2 years. *RET* rearrangements are recognized drivers in lung cancer, representing a small subset (1–2%) of NSCLC, and are also identified as a rare, acquired resistance mechanism in *EGFR*-mutant NSCLC.³ There have been only a few reported NSCLC cases with coexisting *EGFR* mutations and *RET* fusions induced by *EGFR*-TKIs.^{4,5} Here, we present a case of dacomitinib-induced *CCDC6-RET* fusion concurrent with an *EGFR* L858R mutation, successfully treated through a combination of dacomitinib and selpercatinib.

Case Presentation

A 68-year-old non-smoker male presented to the emergency department with a 2-month history of non-productive cough, dyspnea on exertion, weight loss, and progressive lower limb weakness. A chest X-ray (CXR) revealed a left-sided opacity (Figure 1A), and the contrast-enhanced chest computed tomography (CT) identified a 7 x 7 cm mass in the left

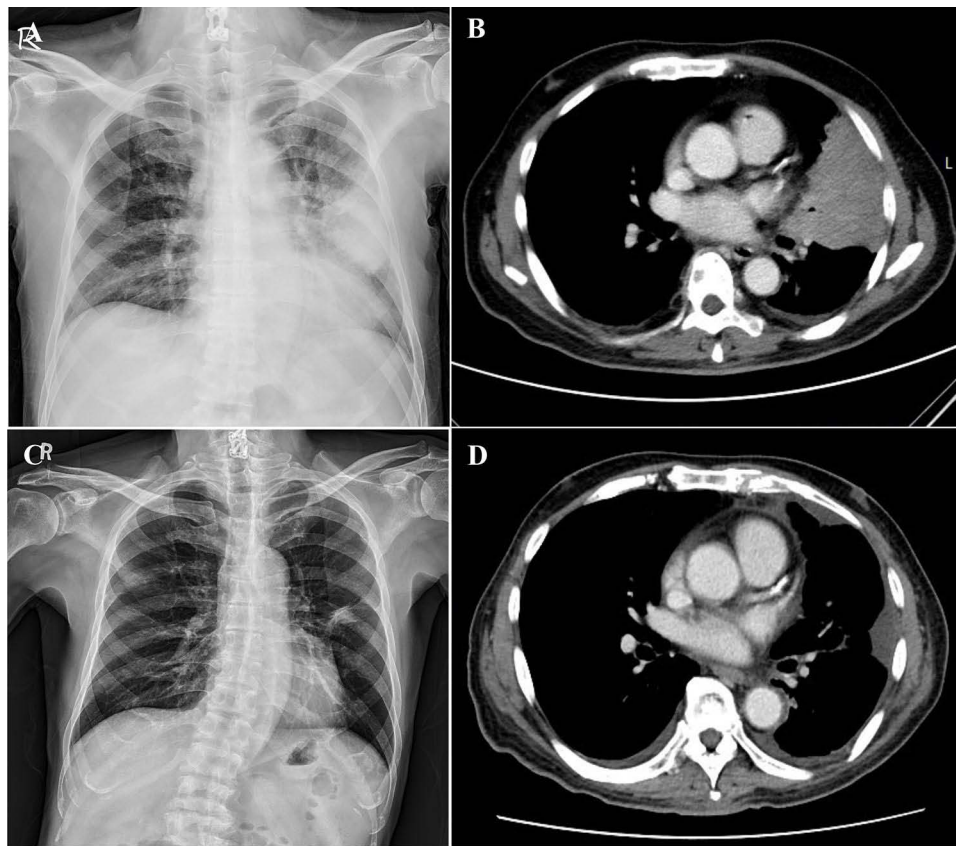


Figure 1 Radiographic findings before and after dacomitinib treatment. (A) Chest X-ray showed a mass-like opacity in the left lung field. (B) CT scan displayed a 7×7 cm mass in the left upper lobe, with enlarged contralateral mediastinal lymph nodes and evidence of multiple bony metastases. (C) Chest X-ray and (D) CT scan revealed a reduced lung tumor size in the left upper lobe after dacomitinib therapy.

upper lobe with contralateral mediastinal lymph nodes enlargement, and multiple bone metastases (Figure 1B). Brain magnetic resonance imaging (MRI) showed a 2.2×1.6 x 1.5 cm lesion with mixed signal intensity in the left thalamus indicative of a metastatic lesion with associated hemorrhage (Figure 2A). Moreover, multiple nodular metastases were identified in the left cerebral hemisphere, along with a metastatic lesion in the left parietal bone. A lung tumor biopsy showed a poorly differentiated lung adenocarcinoma with *EGFR* Ex21 L858R mutation. The patient was diagnosed with stage IVB (T4N3M1c) lung adenocarcinoma, characterized by mediastinal lymphadenopathy and metastases to the brain and multiple bones.

He started treatment with dacomitinib at a daily dosage of 45 mg. After a 6-month course of treatment, both chest X-ray (CXR) and CT scans demonstrated a significant reduction in the lung lesions (Figure 1C and D). Additionally, the brain MRI showed a complete response in the brain metastases (Figure 2B). During monthly evaluations, the patient reported side effects like acneiform eruption, paronychia, and lower limb edema caused by dacomitinib therapy. Consequently, the dosage was progressively reduced from 45 mg to 30 mg, and finally to 15 mg over a period of 5 months. Nevertheless, after 10 months of therapy, the disease progression was observed. CXR and CT scans showed an increase in the size of the primary lung tumor and newly developed pleural nodules with moderate effusion (Figure 3A and B). The brain MRI revealed no interval change in the brain lesion. Next-generation sequencing (NGS) analysis of the pleural fluid revealed the presence of *EGFR* L858R mutations with an allele frequency of 19.5% and a *CCDC6-RET* fusion (Figure 4 and Table S1).

Second-line oral vinorelbine was initiated, but refractory pleural effusion persisted. Third-line chemotherapy with cisplatin, pemetrexed, and bevacizumab was prescribed, followed by maintenance therapy of pemetrexed and bevacizumab, which effectively reduced tumor size and effusion (Figure 3C and D). However, the patient experienced worsened lower limb weakness and decreased consciousness after a 6-month course of treatment. The brain CT scan showed hydrocephalus without apparent metastatic lesions (Figure 5A and B). Additionally, while a diagnostic lumbar puncture

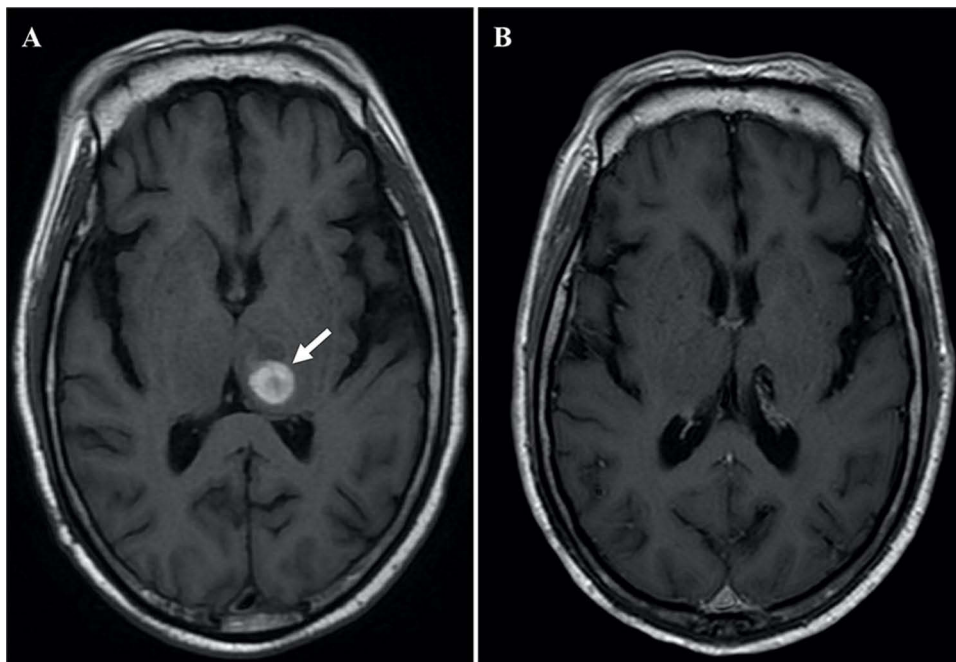


Figure 2 MRI scans displayed a metastatic lesion in the left thalamus before and after dacomitinib treatment. (A) Axial MRI scan showed a 2.2×1.6 × 1.5 cm lesion with mixed signal intensity (arrow), suggestive of a hemorrhagic metastatic lesion. (B) Axial MRI scan revealed complete remission of the previously noted metastatic lesion.

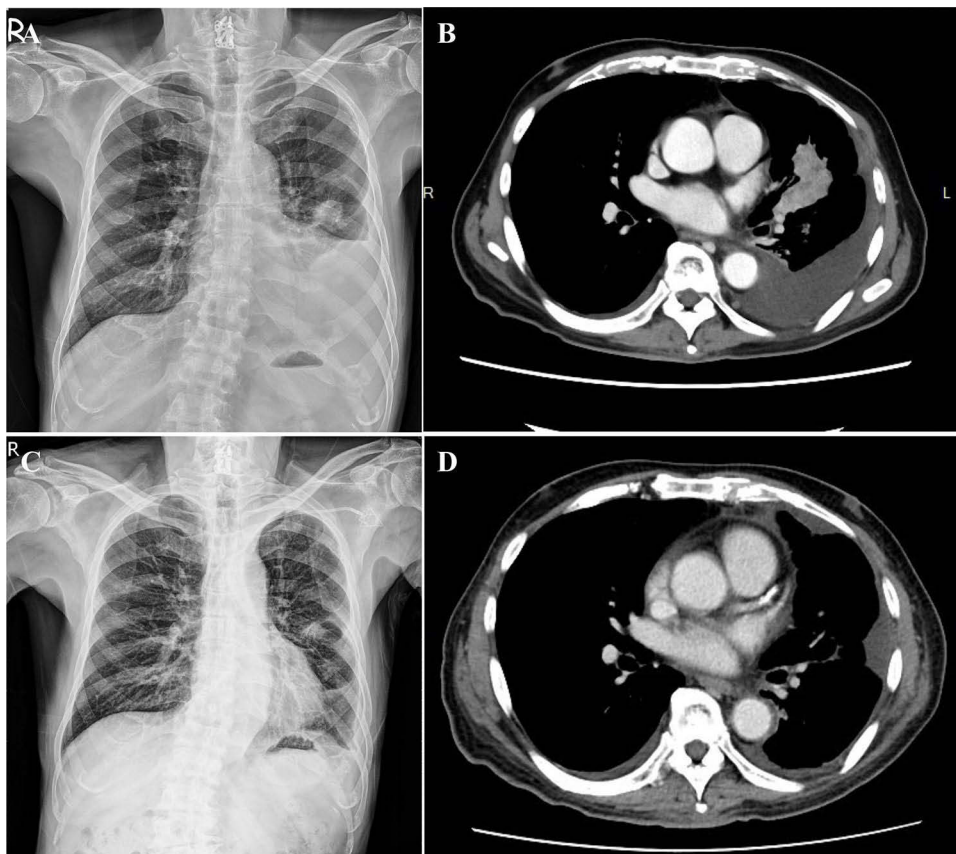


Figure 3 Radiographic findings before and after chemotherapy treatment. (A) Chest X-ray and (B) CT scan demonstrated an enlarged primary lesion in the left upper lobe with associated pleural effusion. (C) Chest X-ray and (D) CT scan revealed a decreased size of the tumor in the left upper lobe with diminished pleural effusion after chemotherapy.

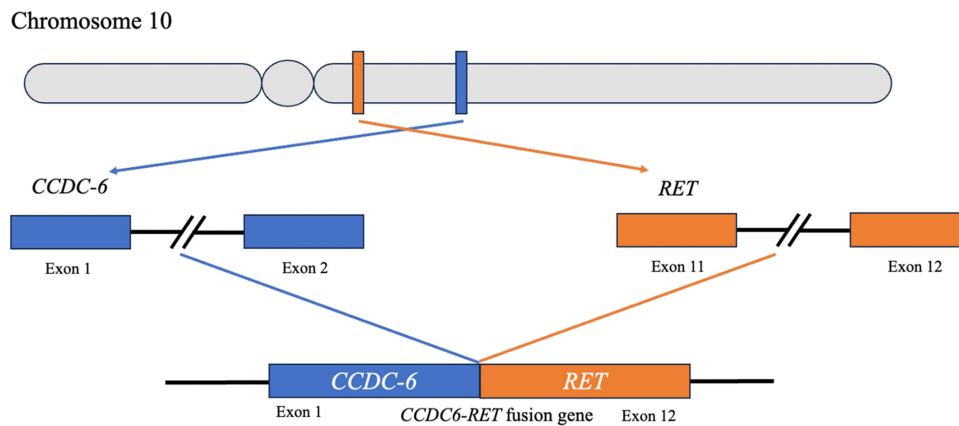


Figure 4 Diagram of the *CCDC6-RET* fusion gene on chromosome 10. The schematic illustrates the fusion between exon 1 of the *CCDC6* gene and exon 12 of the *RET* gene, resulting in the *CCDC6-RET* fusion gene.

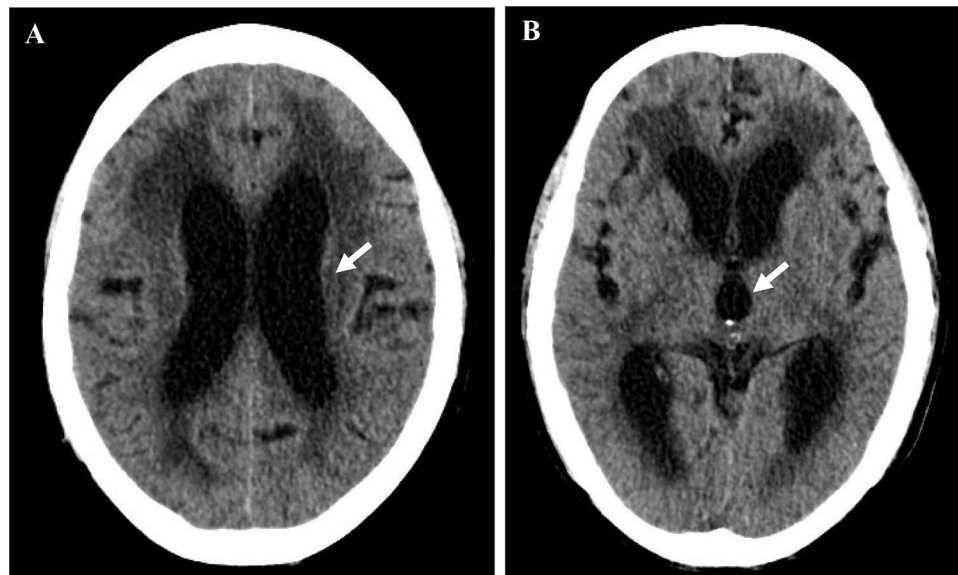


Figure 5 Brain CT scans depicting hydrocephalus. (A) Exhibited a dilated lateral ventricle (arrow). (B) Showed an expanded 3rd ventricle (arrow).

showed no malignant cells in the cerebrospinal fluid (CSF), the persistent elevation of CEA levels suggested ongoing disease progression. Fourth-line chemotherapy with docetaxel and ramucirumab was initiated but showed limited improvement. Consequently, the treatment strategy was changed to a combination of dacomitinib (30 mg daily) and the RET kinase inhibitor selpercatinib (80 mg daily). After a 1-month period of the combination treatment, there were notable improvements in consciousness and strength in both the upper and lower limbs (Figure 6A and B). His treatment timeline and response are shown in Figure S1.

Discussion

Recent studies have highlighted the significance of fusion genes as resistance mechanisms to EGFR inhibitors in *EGFR*-mutant NSCLC.^{6–11} Although *RET* rearrangements and *EGFR* mutations are established as driver alterations in NSCLC, their simultaneous occurrence remains extremely rare. Acquired *RET* fusions, which emerge as resistance mechanisms, have been identified in *EGFR*-mutant NSCLC following *EGFR*-treatment. Kobayashi et al conducted a comprehensive

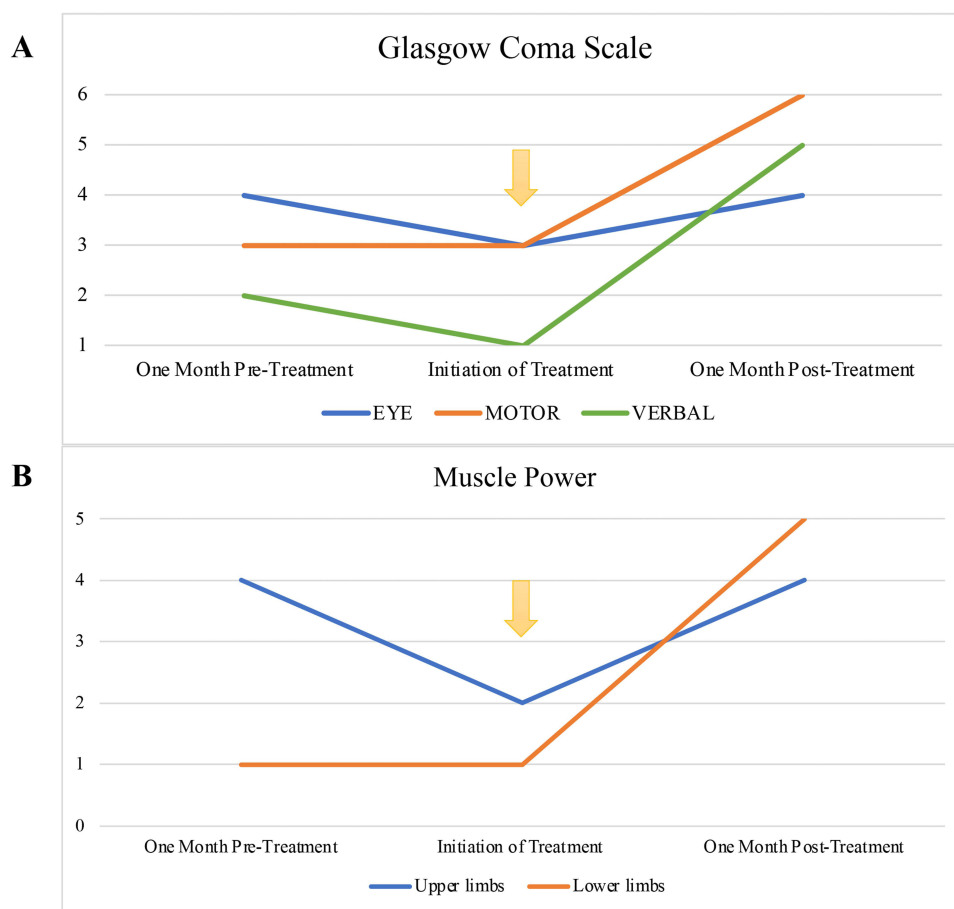


Figure 6 Clinical progression measured by Glasgow Coma Scale and muscle strength evaluation. **(A)** Displayed improvement in Eye, Motor, and Verbal responses as per the Glasgow Coma Scale. **(B)** Illustrated the increase in muscle power for both upper and lower limbs. The initiation of combined treatment is denoted by a yellow arrow.

study on fusion genes and their role in mediating resistance to EGFR TKIs in *EGFR*-mutant lung cancer.¹² Specifically, they identified that only a minority of detected fusion genes, such as *CCDC6-RET*, are functional and capable of imparting resistance to EGFR inhibitors. In a brief review, Zhao et al reported that the co-occurrence of *EGFR* mutations and *RET* fusions in patients with *EGFR*-mutant NSCLC is predominantly induced by osimertinib, a third-generation EGFR-TKI.⁴ Furthermore, they observed that most *RET* fusions involved *CCDC6*, *NCOA4*, and *ANK3-RET*.⁵ Nonetheless, data regarding acquired *RET* fusions induced by other EGFR-TKIs, particularly dacomitinib, and the combined treatment efficacy with *RET* inhibitors, remains limited. In this report, we present the first case of *CCDC6-RET* fusion induced by first-line dacomitinib treatment and reveal a promising treatment response in combination with *RET* inhibitor selpercatinib.

Multiple methods have been utilized for *RET* analysis, including Next-Generation Sequencing (NGS), Fluorescence In Situ Hybridization (FISH), immunohistochemistry, and Reverse Transcription Polymerase Chain Reaction (RT-PCR).¹³ Currently, NGS is the most sensitive technique for detailed *RET* analysis, capable of identifying upstream gene partners and concurrent genomic aberrations that may predict treatment response.¹⁴ DNA-based NGS detects genomic alterations but may miss gene fusions in low-quality samples, whereas RNA-based NGS can identify overlooked *RET* fusions.¹⁵ RT-PCR is effective for detecting the most common *RET* fusion partners but may not identify rarer ones. *RET* FISH offers 100% sensitivity but has only 45–60% specificity and 39–55% false positives; subsequent use after RT-PCR may reduce these false positives.¹⁶ Meanwhile, *RET* immunohistochemistry offers limited clinical utility due to its relatively low sensitivity and specificity. As there are no distinctive clinical characteristics for this NSCLC subset, it's recommended to perform *RET* analysis on both newly diagnosed cases and those showing resistance to EGFR-TKI treatment to detect both *de novo* and acquired *RET* fusions.

Dacomitinib is distinguished as the only EGFR TKI that has demonstrated both PFS and OS benefits over first-generation EGFR TKI specifically in NSCLC patients harboring the *EGFR* L858R mutation, as demonstrated in the ARCHER 1050 study,^{1,2} in comparison to afatinib^{17,18} and osimertinib.^{19,20} Consistently, *in vitro* studies have shown that dacomitinib exhibits the lowest IC₅₀ in lung cancer cell lines with the *EGFR* L858R mutation, surpassing other EGFR TKIs, including osimertinib.²¹ These critical insights form the cornerstone of our treatment rationale, offering a solid foundation for our therapeutic strategy. Additionally, while dacomitinib has demonstrated significant survival outcomes over gefitinib, its effectiveness on the central nervous system (CNS) remains uncertain as the ARCHER 1050 study excluded patients with brain metastases.¹ A recent case series study indicated that dacomitinib has potent efficacy for central nervous system (CNS) metastasis in *EGFR*-positive NSCLC, with an intracranial metastases response rate of 85.7%.^{22,23} In consistent with these results, our case achieved complete remission of brain metastases following a 6-month dacomitinib treatment, underscoring its potent efficacy in managing CNS metastases in *EGFR*-mutant NSCLC.

Selpercatinib and pralsetinib are commercially available RET inhibitors for treating *RET* fusion in NSCLC patients. However, the combination of EGFR-TKIs and RET inhibitors lacks clinical research to determine effective and minimally toxic dosage guidelines. Recent case series have revealed that combining osimertinib and selpercatinib is feasible, safe, and beneficial for patients with *EGFR*-mutant NSCLC harboring an acquired *RET* fusion.²⁴ Furthermore, a few case reports have also confirmed the efficacy of an osimertinib and pralsetinib regimen.^{4,5} However, these crucial clinical insights are predominantly based on data related to the EGFR-TKI osimertinib. Our case provides valuable evidence that the dosage and combination therapy of dacomitinib and selpercatinib is practical, safe, and favorable for patients with concurrent *EGFR* mutations and *RET* fusions. The dose of selpercatinib (80 mg daily) was chosen due to the patient's previous side effects from dacomitinib and the lack of established guidelines for their combined use. The patient experienced significant side effects, such as acneiform eruption, paronychia, and lower limb edema, on the full dose of dacomitinib, leading to a reduction from 45 mg to 30 mg, and eventually to 15 mg. Consequently, we began the combination treatment at 30 mg dacomitinib and 80 mg selpercatinib daily to ensure safety and tolerability without serious adverse events. This approach aligns with findings from the LIBRETTO-431 and ARCHER 1050 studies, which supported dose adjustments to manage side effects without compromising efficacy.^{25,26} Notably, the patient sustained progressive disease with hydrocephalus, but no tumor cells were found in the cerebrospinal fluid (CSF), and there were no brain metastases or leptomeningeal carcinomatosis on the brain imaging studies. This condition may be explained by paraneoplastic syndromes or inflammatory responses, which can result in hydrocephalus without the presence of detectable tumor cells or metastases.^{27,28} Furthermore, the improved neurological function observed highlights the significant CNS activity of both dacomitinib and selpercatinib. Such findings are especially relevant for contexts where the latest third-generation treatments may not be accessible due to economic constraints or regulatory reasons. For instance, the choice of dacomitinib over osimertinib was carefully considered based on its availability and the reimbursement policies in specific regions, providing vital data for similar clinical scenarios globally.

Several retrospective studies have indicated that pemetrexed-based regimens offer long-term survival benefits and are more effective than other chemotherapy regimens for patients with *RET*-rearranged NSCLC.^{29,30} However, these studies primarily involved patients with *de novo* *RET* fusions. Consequently, the efficacy of pemetrexed-based regimens for individuals with acquired *RET* fusions and concurrent *EGFR* mutations remains uncertain. Our case initially received chemotherapy with cisplatin/pemetrexed/bevacizumab due to unavailable RET inhibitors and demonstrated favorable clinical responses. These findings suggest that the potential effectiveness of pemetrexed-based regimens for both *de novo* and acquired *RET* fusions.

Conclusions

To our knowledge, we report the first case of a *CCDC6-RET* fusion induced by first-line dacomitinib in a patient with an *EGFR* L858R mutation and progressive disease with hydrocephalus, which was safely and effectively treated with a combination of dacomitinib and selpercatinib. Additionally, NGS has proven to be instrumental in identifying *RET* fusions. For NSCLC patients with *EGFR* mutations and acquired *RET* fusion, pemetrexed-based chemotherapy presents a feasible alternative treatment when RET inhibitors are inaccessible.

Data Sharing Statement

All data related to the study are included in the paper.

Ethics Approval

This study was approved by the Institutional Review Board of the Tri-Service General Hospital for the publication of case details.

Informed Consent Statement

Written informed consent has been obtained from the patient to publish this paper.

Acknowledgment

The authors are grateful to the patient for his participation. An abstract of this paper was presented at the TSPCCM 2023 Congress as a poster presentation with interim findings.

Author Contributions

All authors made significant contributions to the reported work, including conception, study design, execution, data acquisition, analysis, and interpretation. They participated in drafting, revising, or critically reviewing the article, gave final approval of the version to be published, agreed on the journal to which the article was submitted, and agreed to be accountable for all aspects of the work.

Funding

This research was funded by TSGH, through awards TSGH-D-113114, and supported by the Ministry of National Defense R.O.C., under awards MND-MAB-D-113104.

Disclosure

The authors declare no conflicts of interest in this work.

References

1. Wu YL, Cheng Y, Zhou X, et al. Dacomitinib versus gefitinib as first-line treatment for patients with EGFR-mutation-positive non-small-cell lung cancer (ARCHER 1050): a randomised, open-label, Phase 3 trial. *Lancet Oncol.* 2017;18:1454–1466. doi:10.1016/S1470-2045(17)30608-3
2. Mok TS, Cheng Y, Zhou X, et al. Updated Overall survival in a randomized study comparing dacomitinib with gefitinib as first-line treatment in patients with advanced non-small-cell lung cancer and EGFR-activating mutations. *Drugs.* 2021;81:257–266. doi:10.1007/s40265-020-01441-6
3. Harada G, Yang SR, Cocco E, et al. Rare molecular subtypes of lung cancer. *Nat Rev Clin Oncol.* 2023;20:229–249. doi:10.1038/s41571-023-00733-6
4. Zhao Z, Su C, Xiu W, et al. Response to pralsetinib observed in meningeal-metastatic EGFR-Mutant NSCLC with acquired RET fusion: a brief report. *JTO Clin Res Rep.* 2022;3:100343. doi:10.1016/j.jtocrr.2022.100343
5. Urbanska EM, Sorensen JB, Melchior LC, et al. Durable response to combined osimertinib and pralsetinib treatment for osimertinib resistance due to novel intergenic ANK3-RET Fusion in EGFR -mutated non-small-cell lung cancer. *JCO Precis Oncol.* 2022;6:e2200040. doi:10.1200/po.22.00040
6. Klemptner SJ, Bazhenova LA, Braiteh FS, et al. Emergence of RET rearrangement co-existing with activated EGFR mutation in EGFR-mutated NSCLC patients who had progressed on first- or second-generation EGFR TKI. *Lung Cancer.* 2015;89:357–359. doi:10.1016/j.lungcan.2015.06.021
7. Oxnard GR, Hu Y, Mileham KF, et al. Assessment of resistance mechanisms and clinical implications in patients with EGFR T790M-positive lung cancer and acquired resistance to osimertinib. *JAMA Oncol.* 2018;4:1527–1534. doi:10.1001/jamaoncol.2018.2969
8. Piotrowska Z, Isozaki H, Lennerz JK, et al. Landscape of acquired resistance to osimertinib in EGFR-Mutant NSCLC and clinical validation of combined EGFR and RET Inhibition with osimertinib and BLU-667 for acquired RET fusion. *Cancer Discov.* 2018;8:1529–1539. doi:10.1158/2159-8290.CD-18-1022
9. Vojnic M, Kubota D, Kurzatkowski C, et al. Acquired BRAF Rearrangements Induce Secondary Resistance to EGFR therapy in EGFR-Mutated Lung Cancers. *J Thorac Oncol.* 2019;14:802–815. doi:10.1016/j.jtho.2018.12.038
10. Zhu VW, Klemptner SJ, Ou SI. Receptor tyrosine kinase fusions as an actionable resistance mechanism to EGFR TKIs in EGFR-mutant non-small-cell lung cancer. *Trends Cancer.* 2019;5:677–692. doi:10.1016/j.trecan.2019.09.008
11. Haura EB, Hicks JK, Boyle TA. Erdafitinib overcomes FGFR3-TACC3-mediated resistance to osimertinib. *J Thorac Oncol.* 2020;15:e154–e156. doi:10.1016/j.jtho.2019.12.132
12. Kobayashi Y, Oxnard GR, Cohen EF, et al. Genomic and biological study of fusion genes as resistance mechanisms to EGFR inhibitors. *Nat Commun.* 2022;13:5614. doi:10.1038/s41467-022-33210-2
13. Osta BE, Ramalingam SS. RET fusion: joining the ranks of targetable molecular drivers in NSCLC. *JTO Clin Res Rep.* 2020;1:100050. doi:10.1016/j.jtocrr.2020.100050

14. Drilon A, Rektman N, Arcila M, et al. Cabozantinib in patients with advanced RET-rearranged non-small-cell lung cancer: an open-label, single-centre, Phase 2, single-arm trial. *Lancet Oncol.* 2016;17:1653–1660. 20161104. doi:10.1016/S1470-2045(16)30562-9
15. Ferrara R, Auger N, Auclin E, et al. Clinical and translational implications of RET rearrangements in non-small cell lung cancer. *J Thorac Oncol.* 2018;13:27–45. doi:10.1016/j.jtho.2017.10.021
16. Yoh K, Seto T, Satouchi M, et al. Vandetanib in patients with previously treated RET-rearranged advanced non-small-cell lung cancer (LURET): an open-label, multicentre phase 2 trial. *Lancet Respir Med.* 2017;5(1):42–50. doi:10.1016/S2213-2600(16)30322-8
17. Park K, Tan EH, O'Byrne K, et al. Afatinib versus gefitinib as first-line treatment of patients with EGFR mutation-positive non-small-cell lung cancer (LUX-Lung 7): a phase 2B, open-label, randomised controlled trial. *Lancet Oncol.* 2016;17:577–589. doi:10.1016/S1470-2045(16)30033-X
18. Paz-Ares L, Tan EH, O'Byrne K, et al. Afatinib versus gefitinib in patients with EGFR mutation-positive advanced non-small-cell lung cancer: overall survival data from the phase IIb LUX-Lung 7 trial. *Ann Oncol.* 2017;28:270–277. doi:10.1093/annonc/mdw611
19. Soria JC, Ohe Y, Vansteenkiste J, et al. Osimertinib in Untreated EGFR-Mutated Advanced Non-Small-Cell Lung Cancer. *N Engl J Med.* 2018;378:113–125. doi:10.1056/NEJMoa1713137
20. Ramalingam SS, Vansteenkiste J, Planchard D, et al. Overall survival with osimertinib in untreated, EGFR-mutated advanced NSCLC. *N Engl J Med.* 2020;382:41–50. doi:10.1056/NEJMoa1913662
21. Lavacchi D, Mazzoni F, Giaccone G. Clinical evaluation of dacomitinib for the treatment of metastatic non-small cell lung cancer (NSCLC): current perspectives. *Drug Des Devel Ther.* 2019;13:3187–3198. doi:10.2147/DDDT.S194231
22. Peng W, Pu X, Jiang M, et al. Dacomitinib induces objective responses in metastatic brain lesions of patients with EGFR-mutant non-small-cell lung cancer: a brief report. *Lung Cancer.* 2021;152:66–70. doi:10.1016/j.lungcan.2020.12.008
23. Zhang J, Wang Y, Liu Z, et al. Efficacy of dacomitinib in patients with EGFR-mutated NSCLC and brain metastases. *Thorac Cancer.* 2021;12:3407–3415. doi:10.1111/1759-7714.14222
24. Rotow J, Patel JD, Hanley MP, et al. Osimertinib and selpercatinib efficacy, safety, and resistance in a multicenter, prospectively treated cohort of EGFR-mutant and RET fusion-positive lung cancers. *Clin Cancer Res.* 2023;29:2979–2987. doi:10.1158/1078-0432.CCR-22-2189
25. Zhang J, Ren Y, Wang Q, et al. Thoughts and suggestions on the fact that dacomitinib reduction did not affect its efficacy in the Archer 1050 study. *Future Oncol.* 2022;18:751–753. doi:10.2217/fon-2021-0983
26. Zhou C, Solomon B, Loong HH, et al. First-line selpercatinib or chemotherapy and pembrolizumab in RET fusion-positive NSCLC. *N Engl J Med.* 2023;389:1839–1850. doi:10.1056/NEJMoa2309457
27. Rees JH. Paraneoplastic syndromes: when to suspect, how to confirm, and how to manage. *J Neurol Neurosurg Psychiatry.* 2004;75(2):ii43–50. doi:10.1136/jnnp.2004.040378
28. Graus F, Dalmau J. Paraneoplastic neurological syndromes. *Curr Opin Neurol.* 2012;25:795–801. doi:10.1097/WCO.0b013e328359da15
29. Drilon A, Bergagnini I, Delasos L, et al. Clinical outcomes with pemetrexed-based systemic therapies in RET-rearranged lung cancers. *Ann Oncol.* 2016;27:1286–1291. doi:10.1093/annonc/mdw163
30. Shen T, Pu X, Wang L, et al. Association between RET fusions and efficacy of pemetrexed-based chemotherapy for patients with advanced NSCLC in China: a multicenter retrospective study. *Clin Lung Cancer.* 2020;21:e349–e354. doi:10.1016/j.clcc.2020.02.006

OncoTargets and Therapy

Dovepress

Publish your work in this journal

OncoTargets and Therapy is an international, peer-reviewed, open access journal focusing on the pathological basis of all cancers, potential targets for therapy and treatment protocols employed to improve the management of cancer patients. The journal also focuses on the impact of management programs and new therapeutic agents and protocols on patient perspectives such as quality of life, adherence and satisfaction. The manuscript management system is completely online and includes a very quick and fair peer-review system, which is all easy to use. Visit <http://www.dovepress.com/testimonials.php> to read real quotes from published authors.

Submit your manuscript here: <https://www.dovepress.com/oncotargets-and-therapy-journal>