



Case report

Bilateral inferior oblique muscle paresis after posterior subtenon injection of triamcinolone acetonide



Tso-Ting Lai, Tzu-Hsun Tsai*, Chung-May Yang

Department of Ophthalmology, National Taiwan University Hospital, Taipei, Taiwan

ARTICLE INFO

Article history:

Received 7 March 2014

Received in revised form

7 May 2014

Accepted 9 May 2014

Available online 26 July 2014

Keywords:

inferior oblique muscle

strabismus

subtenon injection

ABSTRACT

Posterior subtenon injections of steroidal drugs are commonly used to treat various chorioretinal inflammatory diseases. Subsequent strabismus is rare, but it is associated with severe visual disturbance when present. We report a case of simultaneous bilateral inferior oblique muscle paresis in a 60-year-old man who developed it after receiving intravitreal injections of bevacizumab and posterior subtenon injections of triamcinolone acetonide for the treatment of diabetic macular edema. The patient complained of excessive pain during the injections, which were performed at the 6 o'clock position in both eyes. According to the literature, inferior oblique muscle paresis after posterior subtenon injections is rare. This complication may be prevented by proper selection of the injection site and paying attention to any unusual patient complaints during the procedure.

Copyright © 2014, The Ophthalmologic Society of Taiwan. Published by Elsevier Taiwan LLC. All rights reserved.

1. Introduction

Posterior subtenon injections of triamcinolone acetonide (PSTA) are commonly used to treat chorioretinal inflammatory diseases such as uveitis and macular edema.¹ This injection technique allows a high local steroid concentration to be sustained over time, but without a substantial increase in systemic drug levels.¹ Common complications of this treatment include ocular hypertension, cataract formation, and ptosis.² Strabismus, although rare after subtenon steroid injections, has been reported—often in association with repeated injections.^{3,4} In this paper, we report a case of bilateral inferior oblique (IO) muscle paresis after a single PSTA.

2. Case Report

A 60-year-old man with diabetic mellitus presented to our clinic with bilateral blurry vision, which had lasted several months. Visual acuity was 20/100 in the right eye and 20/1000 in the left eye. Fundoscopy revealed bilateral macular edema with subretinal

hemorrhage. The anterior chamber and ocular motility were normal. The patient received intravitreal injections of bevacizumab (1.25 mg) and PSTA (40 mg) in both eyes. The PSTAs were performed at the 6 o'clock position in both eyes by passing a 25-gauge 16-mm needle through the inferior conjunctival fornix with a gentle side-to-side fine motion. There was no resistance to drug delivery, but the patient complained of excessive pain during injections. The next day, the patient reported vertical diplopia and image excyclotorsion in the left eye. He had subconjunctival hemorrhage at the lower part of the bilateral eyes. The ductions were normal, whereas the version tests revealed bilateral undererelevation in adduction (Fig. 1). The prism cover test revealed right hypotropia of 3 Δ in the primary gaze, 10 Δ esotropia in the upward gaze, and an orthotropic eye position in the downward gaze. There were also right hypotropia of 6 Δ in the leftward gaze and left hypotropia of 1 Δ in the rightward gaze. The final step of the Bielschowsky test showed right hypotropia of 6 Δ in the left tilt position and left hypotropia of 3 Δ in the right tilt position. The double Maddox rod test revealed 15° incyclotorsion of the left eye. This “A” pattern and the results yielded by motility testing suggested bilateral IO muscle paresis. The symptoms improved spontaneously after 3 months without surgical intervention. Visual acuity improved to 20/50 in the right eye, but remained at 20/1000 in the left eye. An orthotropic eye position in the primary gaze and esotropia of 3 Δ in the upward gaze were noted at the same visit.

Conflicts of interest: No author has any financial or proprietary interest in any material or method mentioned in the paper.

* Corresponding author. Department of Ophthalmology, National Taiwan University Hospital, 12F, Number 7, Chung-Shan South Road, Taipei City, 100, Taiwan.

E-mail address: lucia_tsai@yahoo.com.tw (T.-H. Tsai).

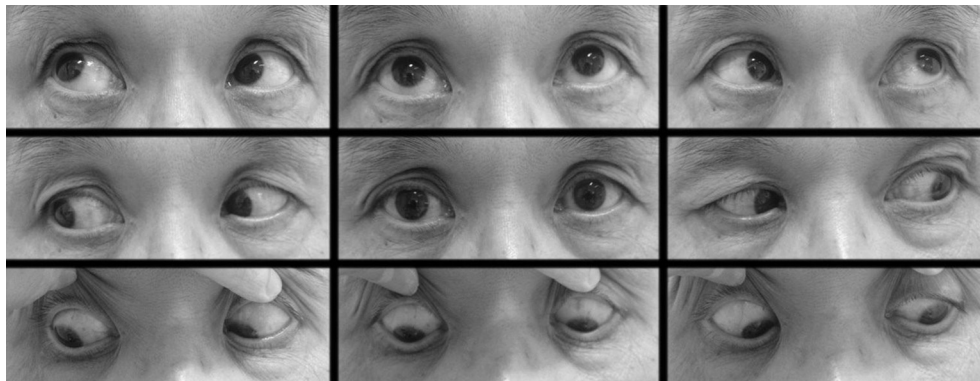


Figure 1. A composite photograph at 1 month after the posterior subtenon injection of triamcinolone acetonide shows bilateral inferior oblique muscle underaction (right upper and left upper), right hypotropia in the primary gaze (center), and esotropia in the upward gaze (middle upper).

3. Discussion

Strabismus is a rarely reported complication of posterior subtenon injections, and only a few cases have been reported in a review of the English literature.^{3–6} Raab reports a case of superior rectus muscle dysfunction after two consecutive subtenon injections of methylprednisolone in the 12 o'clock position.³ In that patient, injury to the muscle and/or the associated nerve supply at some point along the injection path caused superior rectus muscle thinning and tendon attenuation. The literature also includes three reports of extraocular muscle injury after the use of subtenon injections for local anesthesia.⁵ In each case, a blunt curved metal cannula was used for inferonasal drug delivery to the subtenon space. Each of these cases involved immediate periorbital bruising, two cases involved trauma to the inferior rectus muscle, and one case involved damage to the medial rectus. Spierer et al also report a case of superior oblique muscle palsy after subtenon anesthesia; damage to the insertional fibers during superotemporal injection is the possible cause.⁶

Isolated IO muscle palsy is the least common type of isolated extraocular muscle palsy.⁷ The IO muscle arises from the orbital surface of the maxilla, lateral to the lacrimal groove, and passes beneath the inferior rectus muscle at approximately the 6 o'clock position of the orbit. This muscle is innervated by the third cranial nerve at the point just below the lateral border of the inferior rectus muscle. This leaves the IO muscle and its innervating nerve on the path of injection if the PSTA was performed at the 6 o'clock position. The IO muscle paresis in our patient may be related to direct injury to the muscle or its innervation. The side-to-side motion when advancing the needle may further increase the damage. Approximately 24% of patients describe moderate-to-severe pain during PSTA²; however, the excessive pain reported by our patient was unusual and also highly indicative of possible trauma caused by the injections.

An injection in the inferotemporal quadrant or superotemporal quadrant can be used for PSTA; both sites have been documented to successfully deliver a steroidal drug to a location close to the macular area.⁸ An injection in the superotemporal quadrant may have a higher rate of optimal drug delivery to the desired location,⁸ although it is sometimes associated with ptosis occurring several months after the procedure.^{9–11} Other injection methods that use a blunt cannula, instead of a sharp needle, while advancing it through the subtenon space were equally efficacious in treating choriorretinal inflammatory diseases without the risk of direct injury by the sharp tip of the injection needle.^{12,13}

Posterior subtenon injection of triamcinolone acetonide is reportedly associated with late-onset ptosis, which may be related to direct trauma or steroid-induced atrophy of levator aponeurosis.^{9–11} Steroid drugs may be associated with periorbital soft tissue atrophy; however, the atrophy usually occurs a few months after the steroid injection.^{3,9,10,14} Our patient developed strabismus the next day after injection. The rapid course makes the side effect of the steroid less likely as the cause of muscle paresis.

In conclusion, bilateral IO muscle paresis after PSTA is rare. This complication may be prevented by using an injection site other than the 6 o'clock position, using a blunt cannula instead of a sharp needle, and paying attention to any unusual patient complaints during the procedure.

References

- Shen L, You Y, Sun S, Chen Y, Qu J, Cheng L. Intraocular and systemic pharmacokinetics of triamcinolone acetonide after a single 40-mg posterior subtenon application. *Ophthalmology*. 2010;117:2365–2371.
- Lafranco Dafflon M, Tran VT, Guex-Crosier Y, Herbot CP. Posterior sub-Tenon's steroid injections for the treatment of posterior ocular inflammation: indications, efficacy and side effects. *Graefes Arch Clin Exp Ophthalmol*. 1999;237:289–295.
- Raab EL. Limitation of motility after periorbital corticosteroid injection. *Am J Ophthalmol*. 1974;78:996–998.
- O'Connor GR. Periorbital corticosteroid injections: uses and abuses. *Eye Ear Nose Throat Mon*. 1976;55:83–88.
- Jaycock PD, Mather CM, Ferris JD, Kirkpatrick JN. Rectus muscle trauma complicating sub-Tenon's local anaesthesia. *Eye (London)*. 2001;15:583–586.
- Spierer A, Schwalb E. Superior oblique muscle paresis after sub-Tenon's anesthesia for cataract surgery. *J Cataract Refract Surg*. 1999;25:144–145.
- Paralytic strabismus. In: von Noorden GK, Campos EC, eds. *Binocular Vision and Ocular Motility: Theory and Management of Strabismus*. 6th ed. St. Louis, MO: Mosby; 2002:431–432.
- William RF, Ronald LG, Ronald ES. Echographic localization of corticosteroids after periorbital injection. *Am J Ophthalmol*. 1987;103:281–288.
- Dal Canto AJ, Downs-Kelly E, Perry JD. Ptosis and orbital fat prolapse after posterior sub-Tenon's capsule triamcinolone injection. *Ophthalmology*. 2005;112:1092–1097.
- Song A, Carter KD, Neraid JA, Boldt C, Folk J. Steroid-induced ptosis: case studies and histopathologic analysis. *Eye (London)*. 2008;22:491–495.
- Ideta S, Noda M, Kawamura R, Shinoda K, Suzuki K, Ishida S, et al. Dehiscence of levator aponeurosis in ptosis after sub-Tenon injection of triamcinolone acetonide. *Can J Ophthalmol*. 2009 Dec;44:668–672.
- Venkatesh P, Kumar CS, Abbas Z, Garg S. Comparison of the efficacy and safety of different methods of posterior subtenon injection. *Ocul Immunol Inflamm*. 2008;16:217–223.
- Byun YS, Park YH. Complications and safety profile of posterior subtenon injection of triamcinolone acetonide. *J Ocul Pharmacol Ther*. 2009;25:159–162.
- Nozik RA. Orbital rim fat atrophy after repository periorbital corticosteroid injection. *Am J Ophthalmol*. 1976;82:928–930.