


PAPER

PATHOLOGY/BIOLOGY

Marloes E. M. Vester ^{1,2} M.D., Ph.D.; Kurt B. Nolte,³ M.D., Ph.D.; Gary M. Hatch,³ M.D.; Chandra Y. Gerrard,³ M.P.H., B.S.; Reinoud D. Stoel,¹ Ph.D.; and Rick R. van Rijn,^{1,2} M.D., Ph.D.

Postmortem Computed Tomography in Firearm Homicides: A Retrospective Case Series*†

ABSTRACT: Postmortem computed tomography (PMCT) is integrated into the evaluation of decedents in several American medical examiner offices and medicolegal death investigative centers in many other countries. We retrospectively investigated the value of PMCT in a series of firearm homicide cases from a statewide centralized medical examiner's office that occurred during 2016. Autopsies were performed or supervised by board-certified forensic pathologists who reviewed the PMCT scans prior to autopsy. PMCT scans were re-evaluated by a forensic radiologist blinded to the autopsy findings and scored by body region (head–neck, thoracoabdominal, and extremities). Injury discrepancies were scored using a modified Goldman classification and analyzed with McNemar's test. We included 60 males and 20 females (median age 31 years, range 3–73). Based on PMCT, 56 (79.1%) cases had injuries relevant to the cause of death in a single body region (24 head–neck region, 32 thoracoabdominal region). Out of these 56 cases, 9 had a missed major diagnosis by PMCT outside that region, including 6 extremity injuries visible during standard external examination. Yet all had evident lethal firearm injury. We showed that PMCT identifies major firearm injuries in homicide victims and excludes injuries related to the cause of death in other regions when a single body region is injured. Although PMCT has a known limited sensitivity for soft tissue and vascular pathology, it can be combined with external examination to potentially reduce or focus dissections in some of these cases depending on the circumstances and medicolegal needs.

KEYWORDS: autopsy, tomography, X-ray computed, forensic pathology, gunshot sounds, postmortem computed tomography (PMCT), forensic ballistics

In recent years, an increasing number of studies have been published on the use of postmortem computed tomography (PMCT) and postmortem magnetic resonance imaging for medicolegal death investigations (1,2). Autopsy is a traditional and important way of obtaining pathologic information from decedents, especially those with gunshot wounds. However, this procedure can be time-consuming, expensive, and at times might expose pathologists and assistants to biohazards (e.g., blood-borne and airborne pathogens) (3). In general, PMCT is more sensitive than autopsy in detecting fractures, free air, and gas formations (4–6). In contrast, soft tissue injuries such as small vessel lacerations, thin subdural hematomas, soft tissue diseases,

and vascular diseases (e.g., coronary artery disease) are more difficult to detect with noncontrast-enhanced PMCT than autopsy (1,7).

In practice, many American medicolegal jurisdictions rely on external examinations (inspections) without autopsy in some cases of presumed suicidal gunshot wounds. These cases typically have clear circumstances, wound characteristics compatible with being self-inflicted, and no retained projectile. In these cases, PMCT can contribute valuable information including disrupted organs, wound trajectories, and locations of retained projectiles or projectile fragments. In decedents with gunshot wounds of the head, PMCT has a 72.1–100% accuracy in reconstructing wound trajectories when combined with external examination. For gunshot wounds in other locations, the reported accuracy is lower (8–14). Furthermore, PMCT can identify 100% of metal bullet fragments (8,14,15) and in combination with photogrammetry, give 3D, to-scale, true-color bullet wound reconstructions (14,16–18). Consequently, PMCT has become an integral part of the standard postmortem workup at the New Mexico Office of the Medical Investigator (NM OMI) in Albuquerque, New Mexico, United States of America (USA) and several other forensic pathology centers in the world (19,20).

Firearm injuries are a major cause of death in the United States, with 36,252 persons (11.1 per 100,000 population) dying from these injuries in 2015 (21). In the same year, the New Mexico firearm injury death rate of 18.6 deaths per 100,000 population ($n = 390$) was higher than the national rate. These deaths represented approximately 5% of the NM OMI total case

¹Department of Forensic Medicine, Netherlands Forensic Institute, Laan van Ypenburg 6, 2497 GB, The Hague, The Netherlands.

²Department of Radiology and Nuclear Medicine, Amsterdam UMC, University of Amsterdam, Meibergdreef 9, 1105 AZ, Amsterdam, The Netherlands.

³Office of the Medical Investigator, University of New Mexico School of Medicine, 1101 Camino de Salud, Albuquerque, NM 87102.

Corresponding author: Marloes E. M. Vester, MD, PhD. Email: marloes.vester@gmail.com

*Presented at the 71st Annual Scientific Meeting of the American Association of Forensic Sciences, February 18–23, 2019, in Baltimore, MD.

†All procedures performed in studies involving human participants were in accordance with the ethical standards of the institutional and/or national research and with the 1964 Helsinki declaration and its later amendments or comparable ethical standards.

Received 12 Jan. 2020; and in revised form 16 April 2020; accepted 17 April 2020.

load (21-26). Around 26% of these firearm-related deaths were homicides for which the medicolegal death investigation included an autopsy. The aim of a medicolegal autopsy is to determine the condition of the body, including injuries and diseases, along with the cause and manner of death. In general, this process incorporates an evaluation of the external body surface and viscera and laboratory studies such as toxicological investigations. Additionally, with firearm injuries, autopsy is used to recover projectiles and projectile fragments as evidence.

If PMCT can accurately exclude injuries in areas distant to externally visible gunshot wounds and is sufficient to establish the cause of death, dissection can potentially be supplanted or limited in scope to the injured body region and bullet retrieval. Both outcomes could save time and money. The aim of the current study is to compare the performance of autopsy and PMCT in evaluating gunshot injuries in homicide victims.

Materials and Methods

Study Population

The NM OMI is a statewide, centralized, academic medical examiner office, at the University of New Mexico School of Medicine. The office investigates approximately 7000 deaths and performs approximately 2000 medicolegal autopsies annually. The department houses a CT scanner dedicated to postmortem investigations. With almost all decedents who undergo a pathologist external examination and/or autopsy, a total body PMCT scan is obtained. Scans are not performed only when all CT technicians are absent or if the scanner is undergoing repairs.

We studied a retrospective series of firearm homicide cases with complete autopsies and PMCT, performed at the NM OMI from January 1, 2016, to December 31, 2016. We excluded cases with major surgery after the shooting incident, advanced decomposition, extensive thermal injury, and organ donation. No age, sex, or ethnicity selection criteria were applied. General information was collected from the electronic case records on sex, age, ethnicity, place of injury, emergency medical aid, hospital admission, and relevant medical history.

Postmortem Computed Tomography

The morning of autopsy, all decedents were scanned supine, with the forearms placed on the abdomen during the head and neck scan and the upper extremities extended onto the table beyond the head during the torso scan. All scans were performed using a Philips Brilliance Big Bore 16-slice Multi-Detector CT scanner (Philips Medical Systems (Cleveland) INC., Cleveland, OH, 44143, USA; IRS model CIRS, VSD5, software version 4.2.16.; host software version 2.3.5.17167). The standard protocol included 3.0 × 3.0 mm slice thickness with 1.0 mm × 0.5 mm thin slices in soft tissue, bone, lung, and brain kernel/algorithms. The technical parameters included 120 kVp and mAs between 200 and 300 depending on the body region. Coronal and sagittal reformatting was created using soft tissue and bone algorithms for the head-neck and torso. Coronal reformats were created for the lung using a lung algorithm. The brain was reformatted in the axial plane, parallel to the orbitomeatal line. Coronal reconstructions were created of the upper and lower extremities. Where deemed necessary, reconstructions in other planes were generated by the reporting radiologist. Evaluation of the scans was performed using iSite Philips Picture Archive and Communications System (iSite

PACS Version 3.6.150.1, Philips Healthcare Informatics, Foster City, CA).

All eligible PMCT scans were assessed by a board-certified radiologist (RRvR) with 14 years of experience in postmortem radiology. The radiologist was blinded to any information concerning the case such as location of the gunshot wounds, circumstances surrounding demise, and autopsy findings. Abnormalities, including both natural diseases and firearm injuries, were scored per body location into three different regions: head and neck, thorax and abdomen, and extremities.

Autopsy

The circumstances surrounding each case were discussed, and the PMCT scans were reviewed in a daily case conference to determine the type of postmortem examination to be performed, for example, external examination only, partial autopsy, or complete autopsy. In all homicide cases, a complete autopsy including dissection of the brain, neck, and thoracoabdominal cavities as well as other regions that had firearm injuries (e.g., extremities) was performed. Each case had a histologic evaluation that at a minimum reviewed tissues from the brain, heart, lungs, liver, and kidneys. All autopsies were performed or supervised by board-certified forensic pathologists. Supervised trainees included forensic pathology fellows who were also acquainted with the PMCT results at the time of autopsy. Postmortem external findings such as gunpowder residue, number and site of both entrance and exit wounds, and other skin injuries, along with internal findings including wound characteristics were collected from the eligible autopsy reports. Finally, the pathologist’s conclusions of cause and manner of death were recorded.

Analysis

A classification system for discrepancies between premortem diagnoses of clinical patients and autopsy findings was described by Goldman et al. and was modified by Battle et al. (27-29). For this study, we adapted the Goldman classification to evaluate discrepancies between autopsy and PMCT findings (Table 1). If both autopsy and PMCT detected the same abnormalities, no discrepancy was noted (Goldman classification class V). Based on major injuries, decedents were categorized by injured body region: 1—head-neck, 2—thoracoabdomen, 3—extremities, and 4—injuries in more than one region.

To analyze whether PMCT and autopsy differed in the identification of major injuries by body region, we used McNemar’s test for paired data with SPSS version 24 (SPSS statistics,

TABLE 1—Injury/abnormality specification by PMCT, related to the Goldman classification system for discrepancy classification between clinical findings and autopsy (28,29).

Injury	Classification score
No injury of that specific body region or organ.	Class 0
Missed major diagnosis, relevant to the cause of death (e.g., gunshot).	Class I
Missed major diagnosis, not relevant to the cause of death.	Class II
Missed minor (occult) diagnosis (e.g., gallstones).	Class III and (occult) IV
Non discrepancy.	Class V
Nonclassifiable (including signs of medical intervention, e.g., i.v. line).	Class VI

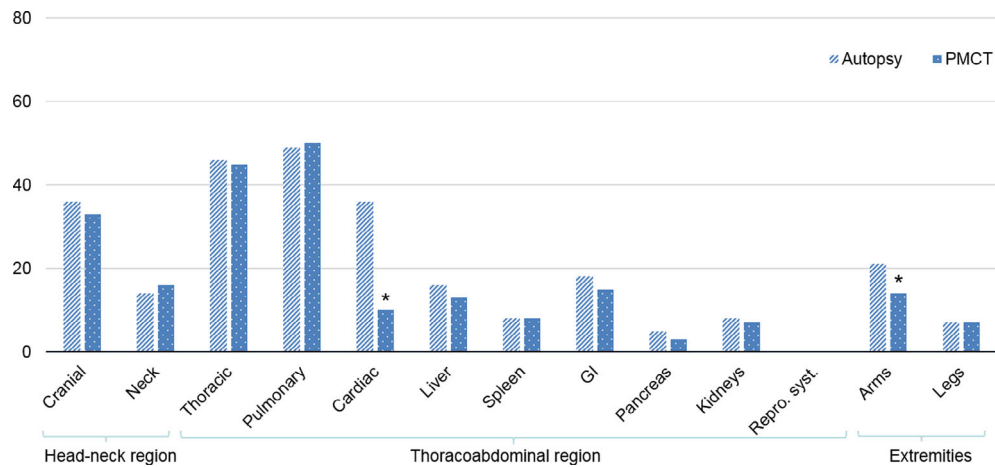


FIG. 1—Major injuries relevant to the cause of death detected by PMCT and autopsy in the 80 included homicide victims (* = significant difference). [Color figure can be viewed at wileyonlinelibrary.com]

IBM, Chicago, Illinois, USA) and VassarStats (©Richard Lowry 1998-2018) for the confidence interval of a proportion with no correction for continuity (30,31). The Bonferroni correction was applied consecutively to correct for multiple testing within the same study population. A p -value < 0.05 was considered significant. Qualitative analysis of discrepancies between PMCT and autopsy was manually performed after statistical analysis.

Results

Study Group

Within the one-year study period, we identified 80 firearm homicide cases that had both a full-body PMCT and a complete autopsy and did not have major surgery, organ harvesting for donation, or decomposition. For each case, 13 anatomic locations were scored for a total of 1040 locations.

The firearm homicide decedents were mostly men (75%) and of white or white Hispanic ethnicity (80.1%), with a median age of 31 years (range 3–73 years). Decedents were mostly found in or around a home (57.5%). Twenty-six (32.5%) cases had emergency medical interventions of which 21 (26.3%) were admitted to a hospital.

Autopsy and PMCT Results

Potentially fatal injuries relevant to the cause of death (e.g., major vascular injury) were identified in 264 (25.4%) locations by autopsy (Fig. 1) and 221 (21.3%) locations by PMCT. Cardiac and major vascular injuries, and injuries to the arms were significantly more often detected by autopsy compared to PMCT ($p < 0.000$ and $p = 0.016$, respectively). After correction for multiple testing by the Bonferroni procedure, the difference in identification of arm injuries between autopsy and PMCT was not significant ($p = 0.208$). Overall, including major and minor abnormalities, autopsy identified more body locations with abnormalities compared to PMCT, respectively, 316 (30.4%) versus 272 (26.2%).

Agreement on Cause of Death Between PMCT and Autopsy

According to PMCT interpretations, 56 (70.0%) cases had injuries relevant to the cause of death in a single body region

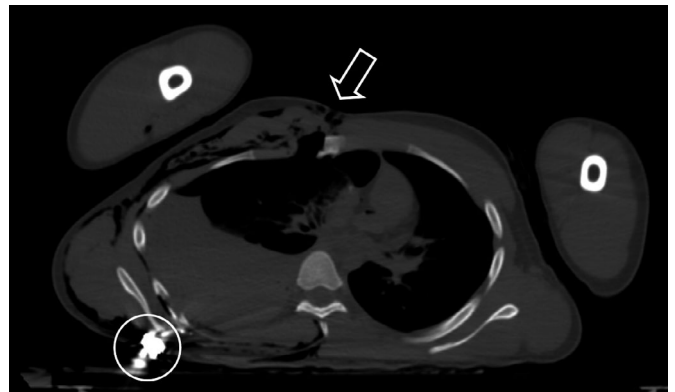


FIG. 2—Postmortem computed tomography (PMCT) horizontal view of the thoracic cavity showing an entrance wound (arrow) on the anterior side of the chest and a retained bullet in the posterior chest wall (circle).

that included twenty-four (30.0%) cases having injuries in the head-neck region and 32 (40.0%) cases in the thoracoabdominal region (Fig. 2). None of the cases had an isolated extremity injury. The remaining 24 cases had injuries in more than one region, including four homicide victims with injuries of the head-neck and extremity regions, eight of the thoracoabdominal and extremity region, seven of the head-neck and thoracoabdominal regions, and five in all body regions. Additionally, in 66 (82.5%) cases the projectile or projectile fragments were retained.

Of the 24 cases with only head-neck injuries seen on PMCT, 2 cases (8.3%) had additional potentially relevant abnormalities identified at autopsy outside of the head-neck region. These findings included a gunshot through an arm (class I discrepancy) and cardiomegaly and left ventricular hypertrophy (class II discrepancy). Of the 32 cases with only thoracoabdominal injuries seen on PMCT, 7 cases (21.9%) had additional injuries potentially relevant to the cause of death outside the thoracoabdominal region. Two cases had very thin subdural hematomas (Fig. 3), one of which had a concomitant subarachnoid hemorrhage (class I discrepancy). Five cases had gunshots through an extremity (class I discrepancy). In summary, of the 56 cases judged by PMCT interpretation to have a single injured body region, 9 cases demonstrated additional potentially relevant injuries outside that particular body region by autopsy (Table 2).

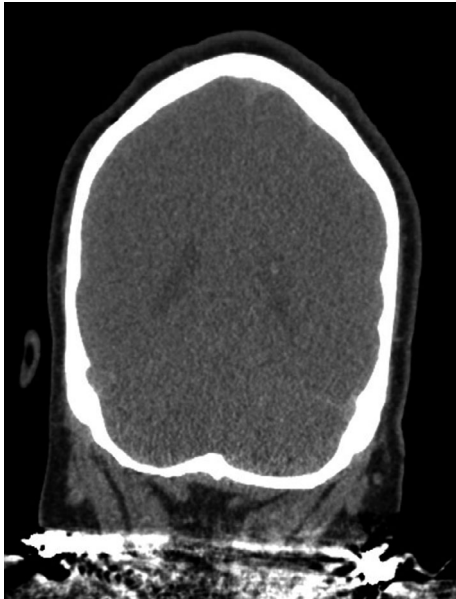

FIG. 3—Negative PMCT (coronal view) of the head from a case where a thin subdural hematoma was found at autopsy.

Furthermore, in 16 out of the 24 cases with multiple injured body regions seen on PMCT additional potentially relevant injuries were found at autopsy.

Table 3 shows sensitivity and specificity scores for PMCT by region. There are broad confidence intervals due to low case numbers. Specificity was only low for lung injuries in the thoracoabdominal group. There was a low sensitivity for cardiac and pancreatic injuries in both the thoracoabdominal and multiple-body-region-injured group and for the arms in both the head-neck and thoracoabdominal groups, along with cranial and kidney injury in the thoracoabdominal group and gastrointestinal injury in the multiple group.

Discussion

Our findings indicate that PMCT can accurately identify the major firearm injuries in homicide victims and accurately exclude injuries in other regions when only a single body region is injured. These findings imply that autopsies can be supplanted or limited to the injured region for purposes of further

TABLE 2—Nine cases out of the 56 cases with a single injured body region, based on PMCT, with additional autopsy findings outside PMCT region of interest.

Pt	Region PMCT	Sex	Age	Additional autopsy findings to PMCT outside region of interest	Discrepancy Score
A	Head-neck	Male	31	Cardiomegaly, left ventricular hypertrophy	II
B	Head-neck	Male	23	Left forearm perforation	I
C	Thoracoabdominal	Male	20	Thin bilateral SDH	I
D	Thoracoabdominal	Male	59	Thin bilateral SDH, small SAB	I
E	Thoracoabdominal	Male	37	Right arm perforation	I
F	Thoracoabdominal	Male	33	Left arm and hand perforations	I
G	Thoracoabdominal	Male	25	Right arm perforation	I
H	Thoracoabdominal	Male	39	Right-hand perforation	I
I	Thoracoabdominal	Male	37	Left-hand perforation	I

SAB, subarachnoid hemorrhage; SDH, subdural hematoma.

characterizing a wound or retrieving projectiles or projectile fragments. We recognize that practice standards currently call for complete autopsies with homicide victims (32). Nevertheless, we hope that our findings will initiate a discussion among forensic pathologists, their professional societies, and individuals working in the criminal justice system to discuss how decedents can be evaluated more efficiently and cost-effectively while at the same time meeting the need for an accurate depiction of the condition of the body and the cause and manner of death.

Our data show that, if the radiologist is blinded to all autopsy information, in 16.1% of cases important findings outside of the main injured body region are missed in the interpretation of PMCT. However, these findings were often not germane to the cause of death. In practice, PMCT scans are best interpreted in the context of other information such as body surface findings. Characterization of injuries on PMCT can easily be improved by the application of radio-opaque makers prior to scanning and during an external examination to draw a radiologist’s attention to regions where injuries might be subtle. Markers such as paperclips or ECG electrodes are helpful in wound trajectory determinations used for crime scene reconstructions (33-35). We believe that if radio-opaque markers were used during our study

TABLE 3—Sensitivity and specificity of PMCT injury potentially relevant to the cause of death scores, per allocated PMCT region.

	Head-neck region n = 24		Thoracoabdominal region n = 32		Multiple regions n = 24	
	Sens. (CI)	Spec. (CI)	Sens. (CI)	Spec. (CI)	Sens. (CI)	Spec. (CI)
Cranial	0.95 (0.78–1)	1 (0.34–1)	0 (0–0.66)	1 (0.89–1)	1 (0.76–1)	1 (0.76–1)
Neck	1 (0.57–1)	0.85 (0.64–0.95)	NA	1 (0.88–1)	0.86 (0.49–0.97)	1 (0.82–1)
Thoracic	NA	0.96 (0.80–0.99)	0.94 (0.79–0.98)	0.75 (0.30–0.95)	0.89 (0.67–0.97)	0.83 (0.44–0.97)
Pulmonary	NA	1 (0.86–1)	0.97 (0.83–0.99)	0.33 (0.06–0.79)	1 (0.83–1)	1 (0.57–1)
Cardiac	NA	1 (0.86–1)	0.35 (0.19–0.55)	1 (0.70–1)	0.17 (0.05–0.45)	1 (0.76–1)
Liver	NA	1 (0.86–1)	0.67 (0.35–0.88)	1 (0.86–1)	1 (0.65–1)	1 (0.82–1)
Spleen	NA	1 (0.86–1)	0.67 (0.30–0.90)	0.92 (0.76–0.98)	1 (0.34–1)	1 (0.85–1)
GI	NA	1 (0.86–1)	0.67 (0.39–0.86)	0.85 (0.64–0.95)	0.50 (0.19–0.81)	0.94 (0.74–0.99)
Pancreas	NA	0.96 (0.80–0.99)	0 (0–0.56)	0.97 (0.83–0.99)	0.50 (0.09–0.91)	1 (0.85–1)
Kidneys	NA	1 (0.86–1)	0.4 (0.12–0.77)	0.93 (0.77–0.98)	1 (0.44–1)	1 (0.85–1)
Reproductive system.	NA	1 (0.86–1)	NA	1 (0.89–1)	NA	1 (0.86–1)
Arms	0 (0–0.79)	1 (0.86–1)	0 (0–0.43)	1 (0.88–1)	0.93 (0.70–0.99)	1 (0.70–1)
Legs	NA	1 (0.86–1)	NA	1 (0.89–1)	1 (0.65–1)	1 (0.82–1)

CI, confidence interval; NA, not available; Sens, sensitivity, spec, specificity,

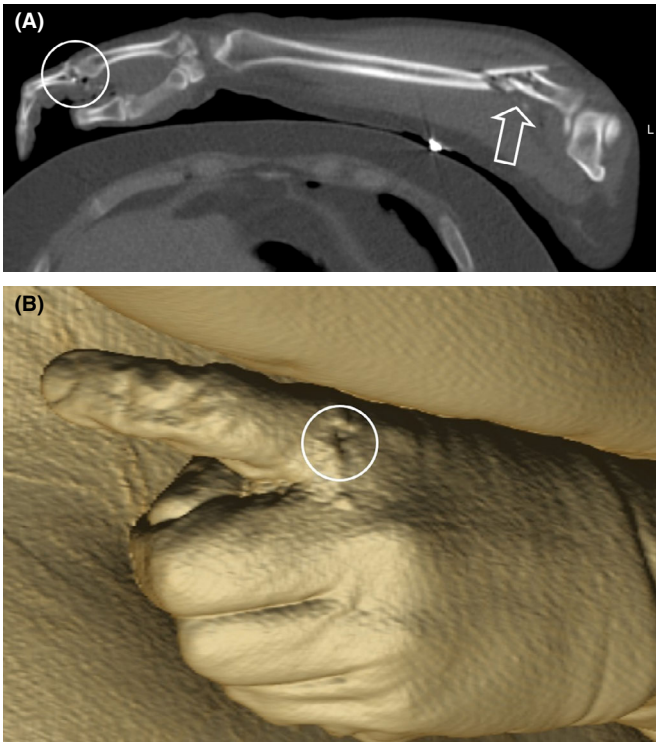


FIG. 4—(A) Postmortem computed tomography (PMCT) image with a small gunshot perforation (circle) of the left forefinger missed by radiologist review, with a distracting fracture of the forearm (arrow). (B) Three-dimensional reconstruction of the left hand showing missed small gunshot perforation (circle) illustrating that the injury would have been visible on external examination. [Color figure can be viewed at wileyonlinelibrary.com]

period, these injuries, which were seen on external examination and missed on PMCT evaluation, likely would not have been missed (Fig. 4A, B). It could be argued that the detection of cardiac and other soft tissue injuries would be improved by the use of postmortem angiography (1,6). However, this procedure is time-consuming, expensive, and except for dedicated centers not widely available.

Our study has several limitations. The first and most important limitation is the fact that pathologists were not blinded to the PMCT findings. Consequently, the pathologists could use their knowledge of these findings during the autopsy to guide dissections, potentially leading to findings that otherwise might not have been discovered. For research, comparisons of PMCT and autopsy are ideally performed in a double-blinded manner. A second limitation is the fact that there was only one radiologist who reported the PMCT studies. Future studies should use several radiologists and evaluate the interobserver variability to learn whether these outcomes are dependent on the technique or the level of expertise of the radiologist. A third limitation is that the results are not applicable to cases with severe decomposition or preceding surgery/organ donation because they were excluded from our study population. Sensitivity scores could, because of the relatively low numbers of cases, in some cases not be calculated, were low, or showed broad confidence intervals. A final, in our view minor, limitation is that we did not assess how many cases of fatal gunshot wounds did not undergo PMCT. This, however, based on the local practice will be a small minority.

While the numbers of medicolegal death investigative centers worldwide with the capacity to perform PMCT are limited, they are increasing annually (16). Thus, the need to understand how this technology can impact the practice of forensic pathology in an evidence-based manner will increase. An important area of

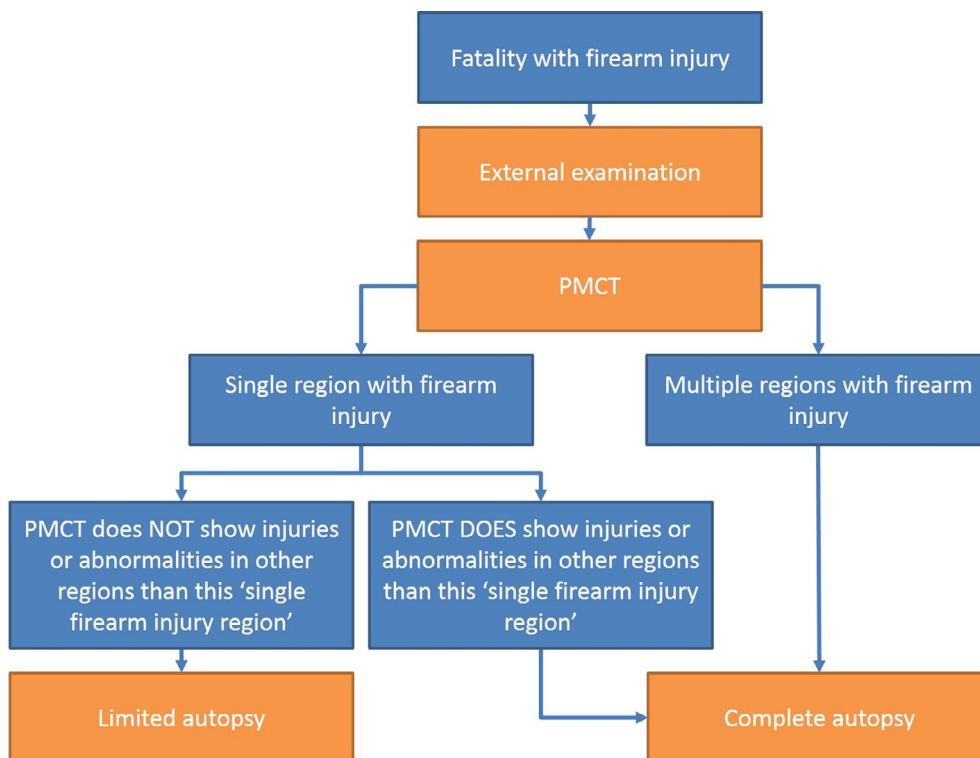


FIG. 5—Proposed workflow for medical postmortem investigation in firearm homicide. [Color figure can be viewed at wileyonlinelibrary.com]

further research would be to more precisely identify in which gunshot homicide cases a PMCT in combination with an external examination could suffice. Conversely, PMCT findings which would indicate the specific need for an autopsy should be identified. We recognize that practice standards currently call for complete autopsies in homicide victims, but we believe that procedures associated with technological developments might change this practice (32,36). In the future, autopsies might be supplanted or limited to a single injured region for purposes of further characterizing a wound or retrieving projectiles or projectile fragments. However, there will remain cases where a full autopsy is still required to address medicolegal questions. For example, a gunshot wound might not have disrupted sufficient organs or tissues to cause death. An autopsy in such a case might discover significant comorbidities such as marked coronary atherosclerosis that combined with the gunshot wound resulted in death.

In conclusion, our findings show that PMCT can accurately identify the major firearm injuries in some homicide victims and accurately exclude injuries related to the cause of death in other regions when only a single body region is injured. We propose that PMCT in combination with external examination could be used to triage cases toward no autopsy or a partial autopsy depending on the circumstances, findings, and medicolegal needs (Fig. 5).

References

1. Grabherr S, Heinemann A, Vogel H, Ruty G, Morgan B, Wozniak K, et al. Postmortem CT angiography compared with autopsy: a forensic multicenter study. *Radiology* 2018;288(1):270–6.
2. Ruty GN, Morgan B, Robinson C, Raj V, Pakkal M, Amoroso J, et al. Diagnostic accuracy of post-mortem CT with targeted coronary angiography versus autopsy for coroner-requested post-mortem investigations: a prospective, masked, comparison study. *Lancet* 2017;390(10090):145–54.
3. Nolte KB, Taylor DG, Richmond JY. Biosafety considerations for autopsy. *Am J Forensic Med Pathol* 2002;23(2):107–22.
4. Jalalzadeh H, Giannakopoulos GF, Berger FH, Fronczek J, van de Goot FRW, Reijnders UJ, et al. Post-mortem imaging compared with autopsy in trauma victims – systematic review. *Forensic Sci Int* 2015;257:29–48.
5. Scholing M, Saltzherr TP, Fung Kon Jin PH, Ponsen KJ, Reitsma JB, Lameris JS, et al. The value of postmortem computed tomography as an alternative for autopsy in trauma victims: a systematic review. *Eur Radiol* 2009;19(10):2333–41.
6. Ampanozi G, Halbheer D, Ebert LC, Thali MJ, Held U. Postmortem imaging findings and cause of death determination compared with autopsy: a systematic review of diagnostic test accuracy and meta-analysis. *Int J Legal Med* 2020;134(1):321–37.
7. Berger N, Ebert LC, Ampanozi G, Flach PM, Gascho D, Thali MJ, et al. Smaller but denser: postmortem changes alter the CT characteristics of subdural hematomas. *Forensic Sci Med Pathol* 2015;11(1):40–6.
8. Andenmatten MA, Thali MJ, Kneubuehl BP, Oesterhelweg L, Ross S, Spendlove D, et al. Gunshot injuries detected by post-mortem multislice computed tomography (MSCT): a feasibility study. *Leg Med* 2008;10(6):287–92.
9. Kirchhoff SM, Scaparra EF, Grimm J, Scherr M, Graw M, Reiser MF, et al. Postmortem computed tomography (PMCT) and autopsy in deadly gunshot wounds – a comparative study. *Int J Legal Med* 2016;130(3):819–26.
10. Makhlouf F, Scolan V, Ferretti G, Stahl C, Paysant F. Gunshot fatalities: correlation between post-mortem multi-slice computed tomography and autopsy findings: a 30-months retrospective study. *Leg Med* 2013;15(3):145–8.
11. Oehmichen M, Gehl HB, Meissner C, Petersen D, Höche W, Gerling I, et al. Forensic pathological aspects of postmortem imaging of gunshot injury to the head: documentation and biometric data. *Acta Neuropathol* 2003;105(6):570–80.

12. Peschel O, Szeimies U, Vollmar C, Kirchhoff S. Postmortem 3-D reconstruction of skull gunshot injuries. *Forensic Sci Int* 2013;233(1–3):45–50.
13. Tartaglione T, Filograna L, Roiati S, Guglielmi G, Colosimo C, Bonomo L. Importance of 3D-CT imaging in single-bullet cranioencephalic gunshot wounds. *Radiol Med* 2012;117(3):461–70.
14. Thali MJ, Yen K, Vock P, Ozdoba C, Kneubuehl BP, Sonnenschein M, et al. Image-guided virtual autopsy findings of gunshot victims performed with multi-slice computed tomography (MSCT) and magnetic resonance imaging (MRI) and subsequent correlation between radiology and autopsy findings. *Forensic Sci Int* 2003;138(1–3):8–16.
15. Harcke HT, Levy AD, Abbott RM, Mallak CT, Getz JM, Champion HR, et al. Autopsy radiography: digital radiographs (DR) vs multidetector computed tomography (MDCT) in high-velocity gunshot-wound victims. *Am J Forensic Med Pathol* 2007;28(1):13–9.
16. Aalders M, Adolphi N, Daly B, Davis G, de Boer H, Decker S, et al. Research in forensic radiology and imaging; Identifying the most important issues. *J Forensic Radiol Imaging* 2017;8:1–8.
17. Villa C. Forensic 3D documentation of skin injuries. *Int J Legal Med* 2017;131(3):751–9.
18. Villa C, Flies MJ, Jacobsen C. Forensic 3D documentation of bodies: simple and fast procedure for combining CT scanning with external photogrammetry data. *J Forensic Radiol Imaging* 2018;12:e2–7.
19. Berger F, Niemann T, Kubik-Huch RA, Richter H, Thali MJ, Gascho D. Retained bullets in the head on computed tomography – get the most out of iterative metal artifact reduction. *Eur J Radiol* 2018;103:124–30.
20. Sutherland T, O'Donnell C. The artefacts of death: CT post-mortem findings. *J Med Imaging Radiat Oncol* 2018;62(2):203–10.
21. Centers for Disease Control and Prevention (CDC). Sats of the State of New Mexico, 2016. <https://www.cdc.gov/nchs/pressroom/states/newmexico/newmexico.htm> (accessed August 8, 2018).
22. Lathrop SL. Childhood fatalities in New Mexico: medical examiner-investigated cases, 2000–2010. *J Forensic Sci* 2013;58(3):700–4.
23. Styka AN, White DS, Zumwalt RE, Lathrop SL. Trends in adult suicides in New Mexico: utilizing data from the new mexico violent death reporting system. *J Forensic Sci* 2010;55(1):93–9.
24. Werenko DD, Olson LM, Fullerton-Gleason L, Lynch AW, Zumwalt RE, Sklar DP. Child and adolescent suicide deaths in New Mexico, 1990–1994. *Crisis* 2000;21(1):36–44.
25. Wiktor SZ, Gallaher MM, Baron RC, Watson ME, Sewell CM. Firearms in New Mexico. *West J Med* 1994;161(2):137–9.
26. Wintemute GJ. The epidemiology of firearm violence in the twenty-first century United States. *Annu Rev Public Health* 2015;36:5–19.
27. Battle RM, Pathak D, Humble CG, Key CR, Vanatta PR, Hill RB, et al. Factors influencing discrepancies between pre-mortem and postmortem diagnoses. *JAMA* 1987;258(3):339–44.
28. Goldman L, Sayson R, Robbins S, Cohn LH, Bettmann M, Weisberg M. The value of the autopsy in three medical eras. *N Engl J Med* 1983;308(17):1000–5.
29. Schwanda-Burger S, Moch H, Muntwyler J, Salomon F. Diagnostic errors in the new millennium: a follow-up autopsy study. *Mod Pathol* 2012;25(6):777–83.
30. Newcombe RG. Two-sided confidence intervals for the single proportion: comparison of seven methods. *Stat Med* 1998;17(8):857–72.
31. Wilson EB. Probable inference, the law of succession, and statistical inference. *J Am Stat Assoc* 1927;22(158):209–12.
32. Peterson GF, Clark SC. Forensic autopsy performance standards. *Am J Forensic Med Pathol* 2006;27(3):200–25.
33. Breitbeck R, Sekula A, Thali MJ, Ampanozi A. 1.7. Use of radiopaque markers in reconstruction of gunshot injuries. *J Forensic Radiol Imaging* 2014;2(2):97.
34. Gale SC, Gracias VH. Imaging triage for ballistic trauma. In: Mahoney PF, Ryan J, Brooks AJ, Schwab CW, editors. *Ballistic trauma*. London, U.K.: Springer-Verlag, London Limited, 2005;465–85.
35. Ramasamy A, Hinsley D, Brooks A. The use of improvised bullet markers with 3D CT reconstruction in the evaluation of penetrating trauma. *J R Army Med Corps* 2008;154(4):239–41.
36. National Center for Health Statistics. Medical examiners' and coroners' handbook on death registration and fetal death reporting. Hyattsville, MD: Department of Health and Human Services; Centers for Disease Control and Prevention; National Center for Health Statistics, 2003;1–130.