



Contents lists available at ScienceDirect

International Journal of Surgery Case Reports

journal homepage: www.casereports.com

Depressed skull fracture by a mass of 3 kg in shot putt an adolescent of 13 years. A rare sports injury. A rare fracture of the skull-deflection shot putt

Farikou Ibrahima^{a,c,*}, Mathieu Motah^{b,c}^a Department of Surgery and Surgical Specialties, Faculty of Medicine and Biomedical Sciences, University of Yaoundé I, Cameroon^b Department of Surgery and Surgical Specialties, Faculty of Medicine and Pharmaceutical Sciences, University of Douala, Cameroon^c General Hospital of Douala, Cameroon

ARTICLE INFO

Article history:

Received 2 March 2014

Accepted 7 October 2014

Available online 11 December 2014

Keywords:

Depressed fracture

Skull

Shot putt

Adolescent

ABSTRACT

INTRODUCTION: More and more teenagers indulge in sports at school or in recreational settings. Some of these sports are considered to be purveyors of accidents and should be practiced by putting in place safety rules and regulations. This report is unusual case of a school child of age 13 who suffered from depressed skull fracture due to accidental fall of a mass of 3 kg during an athletics meeting.

PRESENTATION OF CASE: He was a 13-year-old boy who accidentally received on his head a throwing mass of 3 kg thrown by a young athlete at a school athletics meeting. He became unconsciousness for a moment. The radio clinical evaluation showed a parietal depressed fracture without mass effect on the brain parenchyma to the CT scan. Depression was surgically removed in quite favorable manner.

DISCUSSION: Karting is known as a particular sporting accident that causes head injuries affecting mostly children. Other sports such as boxing and skiing are also known to cause trauma but wearing helmets has significantly reduced these sports injuries. Throwing sports can also lead to accidents in the absence of strict security as demonstrated by this case. It was a skull depressed fracture that was operated upon because it entailed a risk leading to a compressive callus.

CONCLUSION: This accident could have been avoided if basic safety precautions were put in place.

© 2014 The Authors. Published by Elsevier Ltd. on behalf of Surgical Associates Ltd. This is an open access article under the CC BY-NC-SA license (<http://creativecommons.org/licenses/by-nc-sa/3.0/>).

1. Introduction

Nowadays, more and more teenagers are engaging in riskier sports either at school or in recreational settings. They are thus exposed to a variety of injuries including bruising or skull fractures. Their delving into sports originally thought to be exclusively preserves for adults, but by commission, they were exposed to corresponding head injuries of adult sports. Typical examples are karting, horse riding, skiing, boxing, and cycling. This is more common among teens in the Western World.¹ In our own local settings, these types of sports are practiced by children from relatively affluent backgrounds.

We presented an unusual case of a shot putt used during regular school sports and physical educational activities which resulted in calvarial depressed fracture in a 13 year old boy.

2. Presentation of case

He was a 13-year-old boy who joined his peers in the regular school sports and physical educational activities. He received on his head accidentally a mass of 3 kg thrown by his classmate. He became unconscious that lasted for a few minutes. He was reanimated at the school infirmary and got up 30 min later. Conventional radiography was done at the infirmary and it showed a depression of the right parietal bone. The patient was immediately transferred to a General (Referral) Hospital.

Reaching the hospital, the child became conscious (GCS was estimated at 15/15). His blood pressure was 110/70 mmHg and pulse was 104 cycles/min. He had a cephalhematoma “in pigeon’s egg” at the right parietal bone, very sensitive to palpation (Fig. 1). Computed tomography (CT) of the skull was requested. The head CT scan with 3D-reconstructions and bone window images confirmed and clarified the lesion. Right parietal bone depressed fracture was observed. No significant brain parenchymal mass effect was seen (Fig. 2).

Considering the fact that, absence of surgical interventions will lead to compressive malunion, a neurosurgical reduction of the depression was indicated. Under general anesthesia, we performed a plane right fronto-parietal incision.

* Corresponding author at: P.O. Box 14572, Yaounde, Cameroon.

Tel.: +237 99870267; fax: +237 22310579.

E-mail addresses: ifarikou@hotmail.com, ifarikou@yahoo.fr (F. Ibrahima).

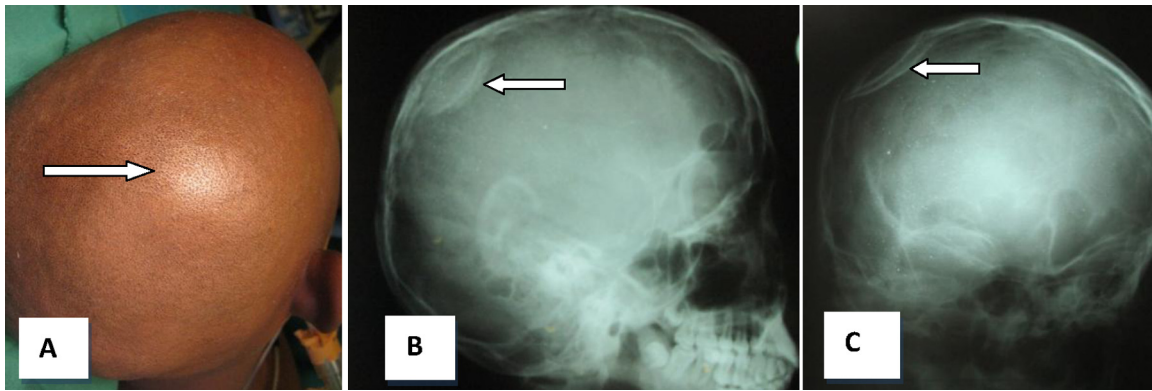


Fig. 1. On the right (A), note parietal Cephalhematoma law (white arrow). On the left (B) and (C), conventional radiographs of the head showed a depression of the right parietal bone (white arrows).

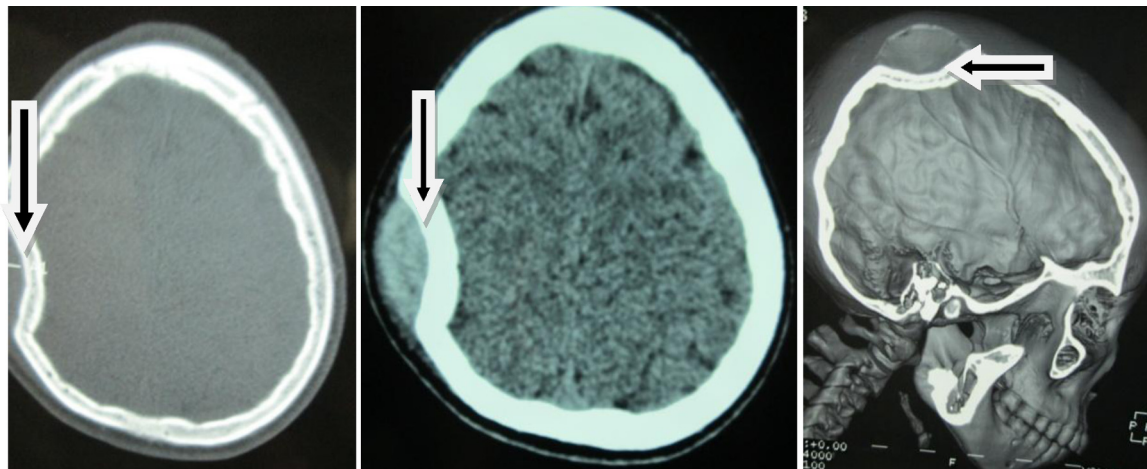


Fig. 2. CT scan: depression of the right parietal bone by a throw mass of 3 kg (arrows).

Trepanation followed by opening of the posterior lower edge of the fracture which facilitated the introduction of a spatula to lift the depression. The closure of the procedure was performed in a pair up of a suction drain (Fig. 3). He was admitted and monitored for several days. The postoperative course was gone on successfully without infection or seizure. A checked radiograph of the skull showed restoration of normal morphology of the right parietal bone (Fig. 4).

The evolution was favorable. He was discharged from the hospital after 8 days. He has regularly been reviewed in clinic and further subjected to radiological evaluations. Resumption of sports activities was allowed after 6 months.

3. Discussion

Epidemiologically, nowadays teenagers and young people are more regularly engaged in games and recreational sports in schools. Some of these games are more accident-prone than others.

Karting is one of the sports that causes head injuries. In a study of 68 cases of craniofacial trauma in the sport, Miller et al.¹ reported 69% of lesions of the skull. They also discovered 32% of such cases had fractures of the skull and facial bones while 20.6% of cases had intracranial hemorrhages. Children were affected in 60.3% during this period.¹ Boxing is also another cause of sports related head injuries in the United States. The study of trauma caused by

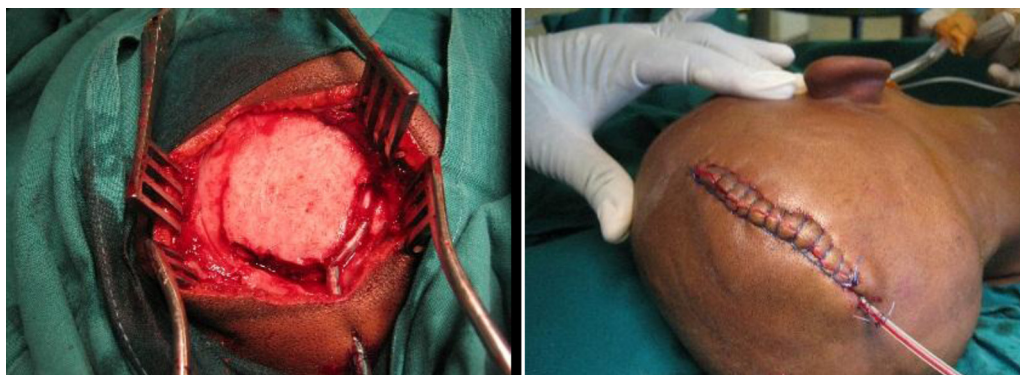


Fig. 3. Intra-operative picture showing the reduction of the penetrated right parietal bone and closing of the wound.

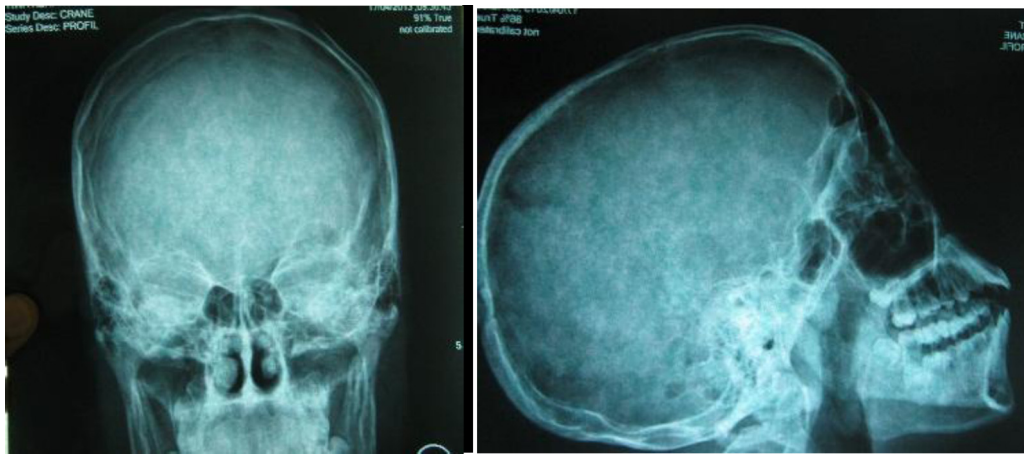


Fig. 4. Postoperative X-ray showed a good recovery of the normal morphology of the skull.

boxing was carried out by Potter et al.² They showed an incidence of 12.7% for every 1000 participants. Head and neck (22.5%) are the most affected areas after the hand (33%).² In Moroder et al. study,³ lesions of the skull and shoulder (21.2% for each site) came 3rd in position after those of back (30.3%), knee (24.2%). Ruqhani et al.⁴ have noted the effectiveness of helmets in reducing head injuries among helmeted skiers at 5.3% against 36.8% compared to non-helmeted in 57 children. Throwing sports (javelin, discus, shot, hammer) involves the use of heavy, blunt or sharp objects. Pendergraph et al.⁵ discovered that such events sometimes take place simultaneously in a large space. This, therefore requires essential precautions, demarcation of security zones, establishment of emergency medical coverage and well maintained equipments.⁵ All these safety standards are readily available in developed countries. The contrast is the case in our own environs with limited resources. The young boy who had skull depressed fracture was not wearing a helmet. There was no secured and safe boundary zone net near the throwing circle to hold the object that might have escaped the hands of an inexperienced young athlete.

Clinically and therapeutically, penetration of skull ping-pong ball like the one in our study is rare in teenagers and adolescents. They are more frequent in newborn babies with the utility of an instrumental delivery (forceps, spatula or digital printing hand of the obstetrician). Simplicity of the surgical procedure and the risk of developing compression callus underlie decidedly surgical attitude being widely shared.⁶

In terms of outcome, we noted no postoperative complications in this present clinical case report, however complications such as osteomyelitis or infection of the surgical wound have been reported by Zahed et al.⁷

4. Conclusion

A teenager involved in regular school sports had 3 kg of mass thrown on his skull. This led to orthopedic lesion of right parietal

calvarial depressed fracture but he miraculously escaped a fatal neurological complications. This fracture was elevated by a combined neurosurgical-orthopedic team without any event.

We strongly recommend the installation of a safety standard in injury-prone sports like shot putt to avert dangers to these tender teenagers.

Conflict of interest

None.

Consent

Written informed consent was obtained from the patient's family for publication of this case report and case series and accompanying images. A copy of the written consent is available for review by the Editor-in-Chief of this journal on request.

References

1. Miller BL, Waller JL, McKinnon BL. Craniofacial injuries due to golf cart trauma. *Otolaryngol Head Neck Surg* 2011;**144**(6):883–7.
2. Potter MR, Synder AJ, Smith GA. Boxing injuries presenting to U.S. emergency departments. *Am J Prev Med* 2011;**40**(4):462–7.
3. Moroder P, Runer A, Hoffelner T, Frick N, Resh H, Tauber M. A prospective study of snowkiting injuries. *Am J Sports Med* 2011;**39**(7):1534–40.
4. Ruqhani AI, Lin CT, Ares WJ, Cushing DA, et al. Helmet use and reduction in skull fractures in skiers and snowboarders admitted to the hospital. *J Neurosurg Pediatr* 2011;**7**(3):268–71.
5. Pendergraph B, Ko B, Zamora J, Bass E. Medical coverage for track and field events. *Curr Sports Med Rep* 2005;**4**(3):150–3.
6. Palchak MJ, Hommes JF, Vance LW, et al. Does an isolated history of loss consciousness or amnesia predict brain injuries in children after blunt head trauma? *Pediatrics* 2004;**113**(1):507–13.
7. Zahed Hossain M, Mondle MS, Monzurul Hoque M. Depressed skull fracture: outcome of surgical treatment. *TJ* 2008;**21**(2):140–6.

Open Access

This article is published Open Access at sciedirect.com. It is distributed under the [IJSCR Supplemental terms and conditions](#), which permits unrestricted non commercial use, distribution, and reproduction in any medium, provided the original authors and source are credited.