

A model for prediction of cisplatin induced nephrotoxicity by kidney weight in experimental rats

Mehdi Nematbakhsh^{1,2,3}, Farzaneh Ashrafi^{1,4}, Hamid Nasri^{1,3,4}, Ardeshir Talebi^{1,5}, Zahra Pezeshki¹, Fatemeh Eshraghi¹, Maryam Haghighi¹

¹Water and Electrolytes Research Center, ²Department of Physiology, ³Kidney Diseases Research Center, ⁴Hematology Oncology Division of Departments of Internal Medicine, ⁵Clinical Pathology, Isfahan University of Medical Sciences, Isfahan, Iran

Background: Cisplatin (cis-diamminedichloroplatinum II; CP) is used widely as an antitumor drug in clinics, but is accompanied with renal toxicity. Cisplatin induced nephrotoxicity consists of change in kidney weight, histological changes in kidney and increase in serum creatinine (Cr) and blood urea nitrogen (BUN). This study was designed to find out a model for prediction of cisplatin induced nephrotoxicity. **Materials and Methods:** Pathological damage score, kidney weight, BUN, and Cr of 227 rats that were involved in different projects were determined. A total of 187 rats were treated with 7 mg/kg cisplatin and sacrificed 1 week later. **Results:** There was a good significant correlation between normalized kidney weight and logarithmic scale of BUN and Cr. Relationship between BUN, Cr or normalized kidney weight and pathology damage score was significant. **Conclusion:** Normalized kidney weight and pathology damage score is a good predictor of renal function in cisplatin induced nephrotoxicity in experimental rats.

Key words: Cisplatin, kidney weight, nephrotoxicity, pathology, rat

INTRODUCTION

Cisplatin (cis-diamminedichloroplatinum II, CP) is a potent antitumor drug for a wide variety of tumors such as head, neck, lung, testis, ovary, and breast.^[1] CP leads to accumulation of platinum within the kidney and disturb renal tubular tissue and function.^[2] The renal dysfunction; renal toxicity induced by CP is involved tubular epithelial cell toxicity, apoptosis, vasoconstriction in the renal microvasculature, proinflammatory effects and activating mitogen-activated protein kinases.^[2,3] The CP-induced nephrotoxicity is manifested by increased serum level of blood urea nitrogen (BUN) and creatinine (Cr) as well as various histological aspects of kidney tissue.

The weight of kidneys tissue is another aspect that may change in CP-induced nephrotoxicity. It is reported that in animals treated with CP, the normalized kidneys weight increased, and it was correlated with intensity of tissue damage.^[4,5] Clinically, kidney tissue biopsy is an invasive procedure to evaluate the kidney damage that should be avoided in non-critical conditions hence the most available non-invasive parameters to evaluate the toxicity induced by drug such as CP is the serum level of BUN and Cr. The relationships between these non-invasive parameters with intensity of kidney tissue damage provide more knowledge to understand, to interpret, and to avoid the CP-induced nephrotoxicity. Therefore, in this study, we tried to demonstrate the

relationship between the histopathology damage scores and the weight of kidneys, as well as the relationship between the BUN or Cr and kidneys damage and weight in a large number of Wistar rats.

MATERIALS AND METHODS

The investigation was performed on Wistar rats. The rats were housed at a temperature of 23-25°C. The rats had free access to water and rat chow, and they were acclimatized to this diet for at least 1 week prior to the experiment. The experimental procedures were approved in advance by the Isfahan University Medical Sciences Ethics Committee.

In past 3 years (from 2009 to 2012) that our teams in Water and Electrolytes Research Center have been worked in the different projects on CP and its nephrotoxicity side-effect, 227 (170-220 g) rats were studied; 40 rats did not treated with CP; normal, and 187 rats received CP (7 mg/kg, ip) as a single dose, and they sacrificed 1 week later. Based on the projects, the treated rats received different supplementations to protect against CP induced nephrotoxicity. At the end of the experiment, the kidney was removed and weighted rapidly. The levels of serum Cr and BUN were determined using the quantitative diagnostic kits (Pars Azmoon, Iran). The removed kidney was fixed in 10% neutral formalin solution and was embedded in paraffin for the histopathological staining. The hematoxylin and

Address for correspondence: Dr. Farzaneh Ashrafi, Water and Electrolytes Research Center, and Hematology Oncology Division of Department of Internal Medicine, Isfahan University of Medical Sciences, Isfahan, Iran. E-mail: f_ashrafi@med.mui.ac.ir

Received: 20-08-2012; **Revised:** 18-01-2013; **Accepted:** 11-03-2013

eosin, stain was applied to examine the tubular atrophy, cast, debris and necrotic material in the tubular lumen and lymphocytes in interstitial tissue were considered as

damage in tubules. Based on the intensity of tubular lesions as mentioned above, we scored from 1 to 4 while the score of zero was assigned to normal tubules without damage.

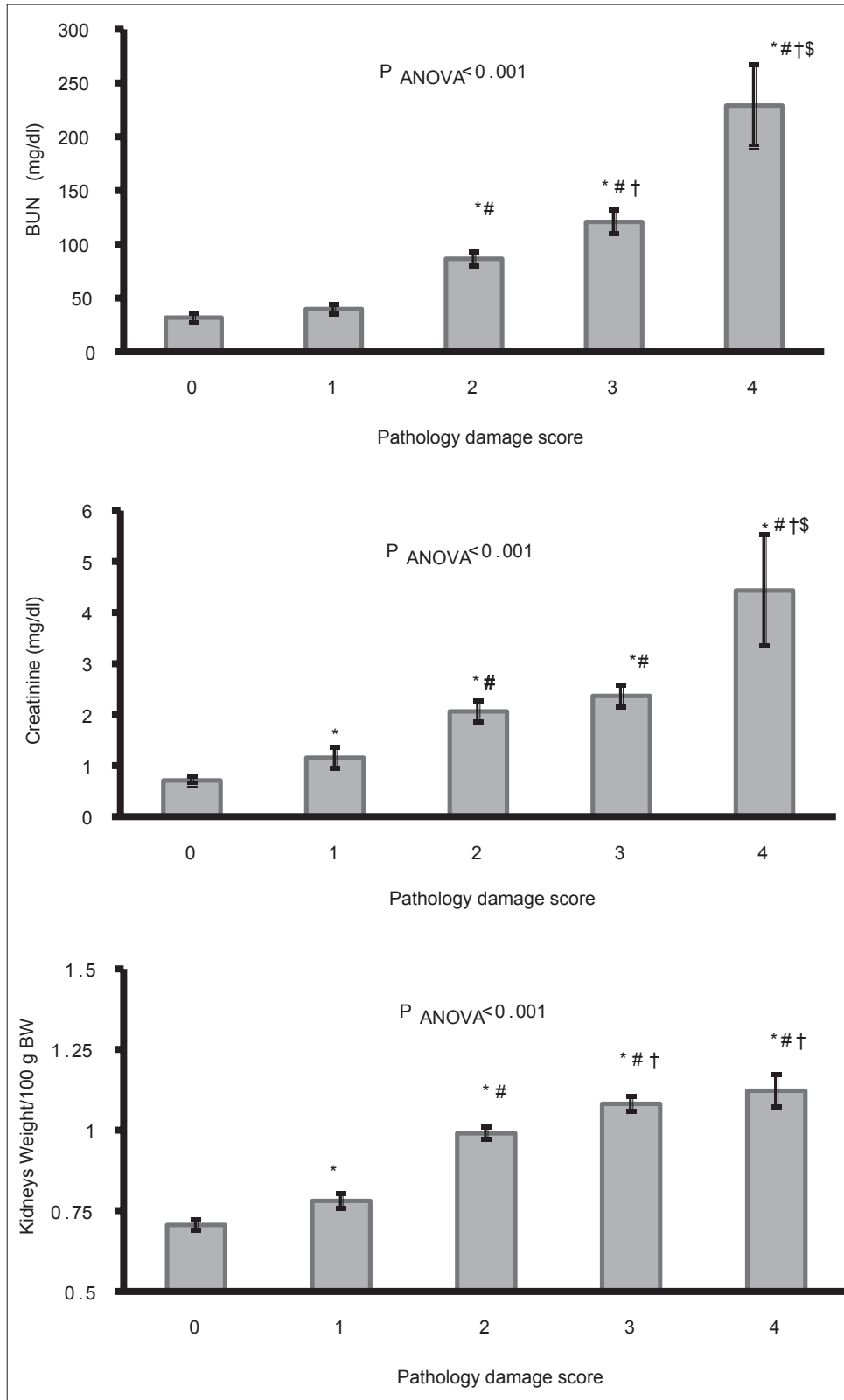


Figure 1: The relationship between the serum levels of blood urea nitrogen, creatinine, or normalized kidneys weight and pathology damage score. The signs indicate a significant difference from (*) score 0, (#) score 1, (†) score 2, or (\$) score 3, $P < 0.05$

Statistical analysis

Statistical analysis was carried out with SPSS version 16. Data are expressed as mean \pm SEM. The serum levels of BUN, Cr and normalized kidney weight between each kidney tissue damage score were compared using one-way ANOVA. To obtain a relationship between BUN or Cr with normalized kidney weight, linear regression was applied. Values of $P < 0.05$ were considered statistically significant.

RESULTS

The relationship between the serum levels of BUN, Cr, or normalized kidneys weight and the pathology damage score are shown in Figure 1. As pathology damage score increases, the serum levels of BUN and Cr, and the kidney weight increase. The normalized kidney weight also was correlated with the logarithmic scale of the serum levels of BUN and Cr significantly ($P < 0.05$) [Figure 2].

For Cr: $\text{Log}(10 \text{ Cr}) = 0.239$ (SE = 0.093, $P = 0.011$) + 0.924 KW (SE = 0.098, $P = 0.00$)

For BUN: $\text{Log BUN} = 0.845$ (SE = 0.082, $P = 0.00$) + 0.995KW (SE = 0.086, $P = 0.00$)

DISCUSSION

CP nephrotoxicity primarily causes tubulo interstitial lesions.^[6] In animal models CP damages the proximal tubules, specifically the S3 segment in the outer medulla.^[6,7] Mitochondrial swelling and nuclear pallor occur in the distal nephron. The glomerulus has no obvious morphologic changes.^[8] In this report, the pathological damage in CP treated rats was in tubules, and a grading model based on the intensity of tubular lesions (tubular atrophy, cast, debris, and necrotic material in the tubular lumen and lymphocyte in interstitial tissue) was developed for report of tubular damage, and its intensity in CP treated experimental rats.

Our analysis showed that this grading model had a good and acceptable correlation with the serum BUN and Cr (in logarithmic scale) level in CP treated rats. This finding seems to be sufficient to suggest a comment for the clinician to collect the similar data from patients who are subjected for kidney biopsy to verify or reject the correlation between biochemical and the histopathological data in human subject.

In previous reports of CP nephrotoxicity, pathological damage after CP treatment had been reported;^[8-10] however, there were no scoring system for the report of intensity of CP induced pathological damage.

The toxic kidneys gain weight as the damage increase.^[5,7,11,12] On the other hand in CP treated rats decrease in body weight

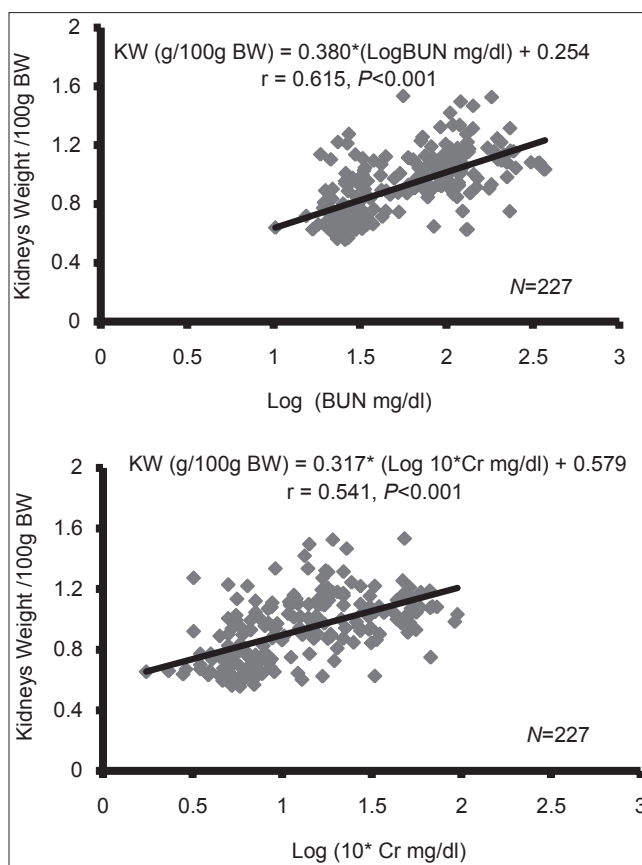


Figure 2: The relationship between the serum levels of blood urea nitrogen or creatinine (in logarithmic scale) with the normalized kidneys weight

had been reported,^[5,11,13] and polyuria is a well-known phenomenon.^[12] It seems that decrease in urine concentrating ability secondary to decrease in the papillary hyper tonicity is the main cause of decrease in body weight.^[14,15] Therefore, the kidney gain weight is not induced by body weight change or urination process disturbance.

In accordance with the other reports with a small number of an experimental rats^[5,11-13] in the present study, the normalized kidney weight in a large number of CP treated rats was increased as kidney damage increase [Figure 1]. In conclusion, it seems that change in the normalized kidney weight could be a good predictor of the pathological damage in experimental models and a reliable predictor of increase in serum Cr and BUN as well.

REFERENCES

1. Arany I, Safirstein RL. Cisplatin nephrotoxicity. *Semin Nephrol* 2003;23:460-4.
2. Miller RP, Tadagavadi RK, Ramesh G, Reeves WB. Mechanisms of Cisplatin nephrotoxicity. *Toxins (Basel)* 2010;2:2490-518.
3. Saad SY, Al-Rikabi AC. Protection effects of Taurine supplementation against cisplatin-induced nephrotoxicity in rats. *Chemotherapy* 2002;48:42-8.
4. Saad SY, Najjar TA, Daba MH, Al-Rikabi AC. Inhibition of nitric

- oxide synthase aggravates cisplatin-induced nephrotoxicity: Effect of 2-amino-4-methylpyridine. *Chemotherapy* 2002;48:309-15.
5. Haghghi M, Nematbakhsh M, Talebi A, Nasri H, Ashrafi F, Roshanaei K, *et al.* The role of angiotensin II receptor 1 (AT1) blockade in cisplatin-induced nephrotoxicity in rats: Gender-related differences. *Ren Fail* 2012;34:1046-51.
 6. Yao X, Panichpisal K, Kurtzman N, Nugent K. Cisplatin nephrotoxicity: A review. *Am J Med Sci* 2007;334:115-24.
 7. Pratibha Ravindra DA, Kulkarni SS, Padmanabh V, Rataboli Chitra Y, Dhume KU. Cisplatin induced histological changes in renal tissue of rat. *J Cell Anim Biol* 2010;4:108-11.
 8. Vickers AE, Rose K, Fisher R, Saulnier M, Sahota P, Bentley P. Kidney slices of human and rat to characterize cisplatin-induced injury on cellular pathways and morphology. *Toxicol Pathol* 2004;32:577-90.
 9. Choie DD, Longnecker DS, del Campo AA. Acute and chronic cisplatin nephropathy in rats. *Lab Invest* 1981;44:397-402.
 10. Nosaka K, Nakada J, Endou H. Cisplatin-induced alterations in renal structure, ammoniogenesis and gluconeogenesis of rats. *Kidney Int* 1992;41:73-9.
 11. Nematbakhsh M, Ashrafi F, Safari T, Talebi A, Nasri H, Mortazavi M, *et al.* Administration of vitamin E and losartan as prophylaxes in cisplatin-induced nephrotoxicity model in rats. *J Nephrol* 2012;25:410-7.
 12. Shimeda Y, Hirotsani Y, Akimoto Y, Shindou K, Ijiri Y, Nishihori T, *et al.* Protective effects of capsaicin against cisplatin-induced nephrotoxicity in rats. *Biol Pharm Bull* 2005;28:1635-8.
 13. Salama RH. *Matricaria chamomilla* attenuates cisplatin nephrotoxicity. *Saudi J Kidney Dis Transpl* 2012;23:765-72.
 14. Safirstein R, Miller P, Dikman S, Lyman N, Shapiro C. Cisplatin nephrotoxicity in rats: Defect in papillary hypertonicity. *Am J Physiol* 1981;241:F175-85.
 15. Wilson DR, Honrath U. Collecting duct function in cis-platinum nephrotoxicity. *Can J Physiol Pharmacol* 1987;65:1200-4.

How to cite this article: Nematbakhsh M, Ashrafi F, Nasri H, Talebi A, Pezeshki Z, Eshraghi F, *et al.* A model for prediction of cisplatin induced nephrotoxicity by kidney weight in experimental rats. *J Res Med Sci* 2013;18:370-73.

Source of Support: This research is supported by Isfahan University of Medical Sciences grant number 289001, **Conflict of Interest:** None declared.