

# A new familial presentation of dissecting cellulitis: The genetic implications on scarring alopecias



Lily Michel Díaz-Pérez, MD,<sup>a</sup> Karina Escobar-Ramírez, MD,<sup>b</sup> and Luis Enrique Sánchez-Dueñas, MD<sup>a</sup>  
*Guadalajara and Zapopan, Mexico*

**Key words:** dissecting cellulitis; isotretinoin; monozygous twins; perifolliculitis capitis abscedens et suffodiens.

## INTRODUCTION

Dissecting cellulitis of the scalp (DCS), also referred to as *perifolliculitis capitis abscedens et suffodiens*, is an uncommon primary neutrophilic cicatricial alopecia. DCS is characterized by perifollicular and follicular pustules that evolve into areas of noncicatricial alopecia resembling different scalp diseases. DCS can develop painful nodules and interconnected abscesses and, in the end stages, permanent alopecia. DCS can occur with follicular occlusion diseases; therefore, the term *dissecting terminal hair folliculitis* has been recently proposed.<sup>1</sup> The etiology of the disease remains unknown. The male dominance, together with the young age of onset and the vertex area suggest a hormonal risk factor. On the other hand, significant prevalence in dark photo-type individuals and a few cases of familiar DCS propose a genetic background.<sup>2,3</sup> We report a unique case of DCS in monozygous twins.

## CASE REPORT

A 17-year-old boy (twin A) presented with a 3-month history of painful scalp lesions and hair loss. There was no family history of skin appendage disorders other than a history of keratoacanthoma and basal cell carcinoma in his mother. The family was originally from Mexico and were not aware of a different ancestry.

In the clinical examination, flat plaques and a prominent erythematous nodule with overlying alopecia were found in the vertex area. The patient reported associated pain. No secretions oozed out on

### Abbreviation used:

DCS: dissecting cellulitis of the scalp

compressing the nodule, and regional lymphadenopathy was absent. Trichoscopy (DermLite 3 gen DL3N, San Juan Capistrano, CA; 10× magnification) found heterogeneous findings: dystrophic hairs, short regrowing hairs, empty follicular openings, black dots, yellow dots, erythema, amorphous white areas, structureless yellow areas, and dotted vessels. The rest of the assessment was normal.

The monozygotic twin brother of twin A (twin B) presented with simultaneous painless scalp lesions manifested as bald areas starting 2 weeks after his brother accidentally discovered a nodule on his head. The clinical examination found alopecic flat plaques that involved the vertex area with the following trichoscopic features: polytrichia, 3-dimensional yellow dots, diffuse erythema, and amorphous white and structureless yellow areas. The rest of the physical examination was normal.

No history of dermatologic or systemic diseases were mentioned regarding the twins. High body mass index was recorded in both patients as 31. Routine biochemical and hematologic analyses were within the normal ranges. The diagnosis of DCS was established in both cases, and they were initially treated with intralesional triamcinolone acetonide injections, 10 mg/mL every 4 weeks. They also started on isotretinoin, 20 mg/d, as add-on treatment. At a 2-month follow-up, inflammatory lesions

From the Department of Dermatology, Dermika Centro Dermatológico Láser, Guadalajara<sup>a</sup> and the Dermatologic Institute of Jalisco, Zapopan.<sup>b</sup>

Funding sources: None.

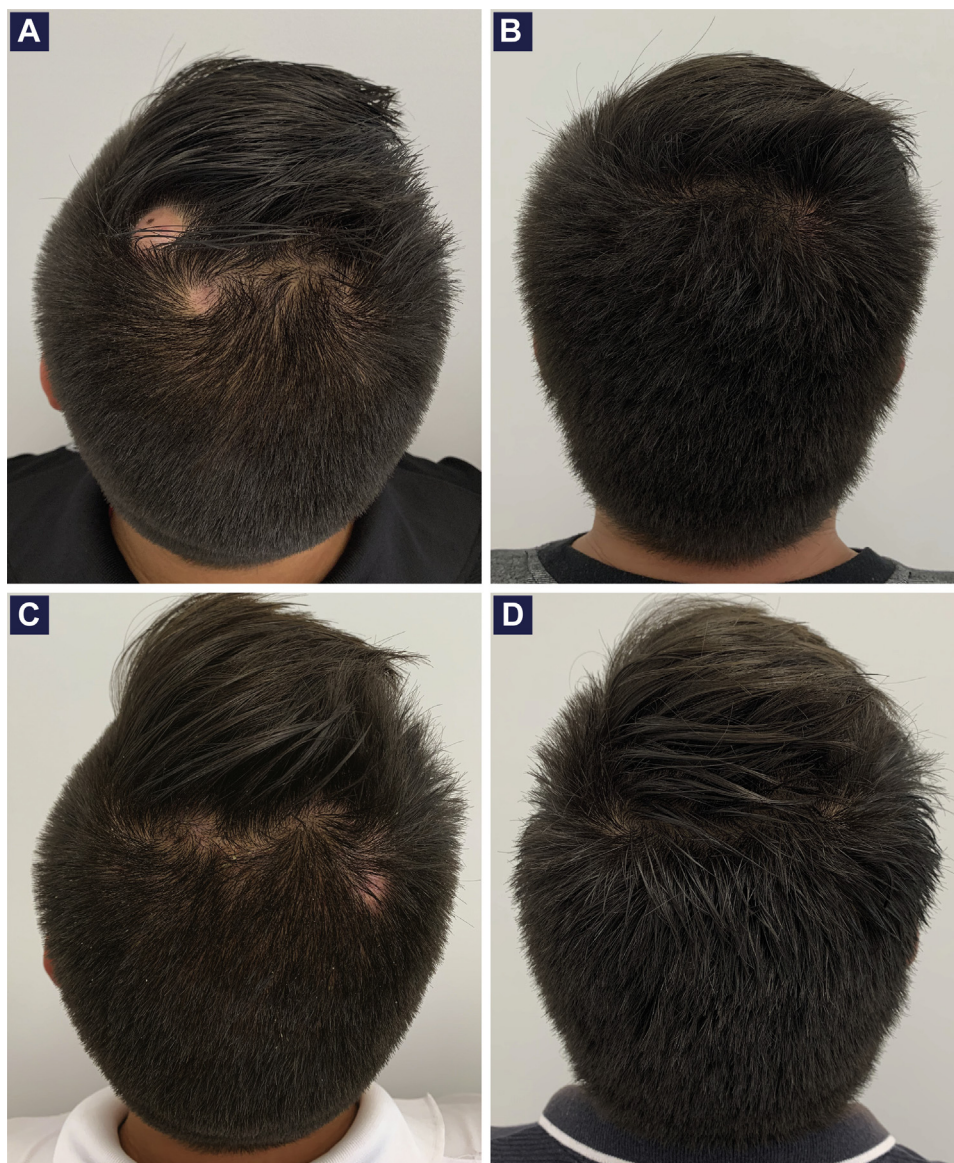
Conflicts of interest: None disclosed.

Correspondence to: Luis Enrique Sánchez Dueñas, MD, Dermatology Department, Dermika Centro Dermatológico Láser, Golfo de Cortés 3002, Col. Vallarta Norte, Guadalajara, Jalisco 44280, Mexico. E-mail: [drlapeau@hotmail.com](mailto:drlapeau@hotmail.com).

JAAD Case Reports 2020;6:705-7.  
 2352-5126

© 2020 by the American Academy of Dermatology, Inc. Published by Elsevier, Inc. This is an open access article under the CC BY-NC-ND license (<http://creativecommons.org/licenses/by-nc-nd/4.0/>).

<https://doi.org/10.1016/j.jdc.2020.05.027>



**Fig 1.** Initial clinical presentation of twin A with prominent erythematous nodule (**A**) and twin B with alopecia plaques (**C**). No clinical lesions and complete regrowth after 6 months of treatment of Twin A (**B**) and B (**D**).

subsided, and partial recovery of hair was noticeable in both patients so we decided to stop triamcinolone acetonide and continue with isotretinoin only. After a 6-month follow-up, the twins showed full hair regrowth without scarring alopecia and no relapses of inflammatory lesions (Fig 1).

## DISCUSSION

The origin of DCS is still unresolved. The role of neutrophils, microbiota, hormonal environment, hair type, and a traumatic factor have been implicated.<sup>2</sup> Inheritance pattern is suggested as being important. To the best of our knowledge, this is the first report of DCS on monozygous twins. According

to previous reports of familial cases,<sup>3</sup> we support the hypothesis of a possible genetic component in the disease.

Genetic implications in other primary cicatricial alopecias have been proposed previously as simultaneous occurrences were identified in twins.<sup>4,5</sup> Dlova et al<sup>6</sup> described the pedigrees of 14 African families with central centrifugal cicatricial alopecia demonstrating an autosomal dominant pattern of inheritance with partial penetrance. Recently, Tziotzios et al<sup>7</sup> undertook the first genome-wide association study in frontal fibrosing alopecia. They found a significant association at 4 genomic loci (2p22.2, 6p21.1, 8q24.22, and 15q2.1); therefore,

they described this subset of alopecia as a genetically predisposed immune-inflammatory disease driven by HLA-B\*07:02.

Trichoscopy is a valuable noninvasive tool for diagnosis. A heterogeneity of trichoscopy findings has been described as typical of DCS.<sup>8</sup> Nevertheless, the 3-dimensional yellow dots represents the most specific trichoscopic finding.<sup>9</sup> In our patients, twin A presented heterogeneous trichoscopic features that correlate with severity of disease, whereas twin B showed the classic 3-dimensional yellow dots; thus, trichoscopy helped us to integrate the diagnosis in both cases. Recently, 2 new trichoscopic signs (eastern pancake sign and comedo-like structures) were described as suggestive findings in the diagnosis of alopecic and aseptic nodules of the scalp, that represents a crucial entity of differential diagnosis of DCS.<sup>10</sup> Herein, we have not found these trichoscopic findings in any of the cases.

A variety of therapeutic strategies for DCS has been proposed with different levels of success. In recent years, isotretinoin has been considered the first line of treatment.<sup>2</sup> We considered treating both patients with oral isotretinoin, and after 6 months of treatment, we observed a successful recovery.

We believe this new familial presentation of DCS will contribute to the current literature of genetic implications on scarring alopecias and promote the

expansion of future genomic studies as similarly seen with other primary cicatricial alopecias.

#### REFERENCES

1. Chen W, Plewig G. Should hidradenitis suppurativa/acne inversa best be renamed as "dissecting terminal hair folliculitis"? *Exp Dermatol*. 2017;26(6):544-547.
2. Badaoui A, Reygagne P, Cavelier-Balloy B, et al. Dissecting cellulitis of the scalp: a retrospective study of 51 patients and review of literature. *Br J Dermatol*. 2016;174(2):421-423.
3. Bjellerup M, Wallengren J. Familial perifolliculitis capitis abscedens et suffodiens in two brothers successfully treated with isotretinoin. *J Am Acad Dermatol*. 1990;23:752-753.
4. Douwes KE, Landthaler M, Szeimies RM. Simultaneous occurrence of folliculitis decalvans capillitii in identical twins. *Br J Dermatol*. 2000;143(1):195-197.
5. Strowd LC, Subash J, McGregor S, et al. Cicatricial alopecia in identical twin lumbee native american women. *Skin Appendage Disord*. 2018;4(2):108-111.
6. Dlova NC, Jordaan FH, Sarig O, et al. Autosomal dominant inheritance of central centrifugal cicatricial alopecia in black South Africans. *J Am Acad Dermatol*. 2014;70(4):679-682.e1.
7. Tziotzios C, Petridis C, Dand N, et al. Genome-wide association study in frontal fibrosing alopecia identifies four susceptibility loci including HLA-B\*07:02. *Nat Commun*. 2019;10(1):1150.
8. Verzi AE, Lacarrubba F, Micali G. Heterogeneity of trichoscopy findings in dissecting cellulitis of the scalp: correlation with disease activity and duration. *Br J Dermatol*. 2017;177(6):e331-e332.
9. Melo DF, Slaibi EB, Siqueira TMFM, et al. Trichoscopy findings in dissecting cellulitis. *An Bras Dermatol*. 2019;94(5):608-611.
10. Bourezane Y, Bourezane H. Deux nouveaux signes trichoscopiques dans les nodules alopeciques et aseptiques du cuir chevelu: le « signe de la crêpe orientale » et les structures comédoniennes. *Ann Dermatol Venerol*. 2014;141(12):750-755.