



# A Rabbit Model for Peripheral Nerve Reconstruction Studies Avoiding Automutilation Behavior

Jonathan A. Sorkin<sup>1,\*</sup> Ziv Rechany<sup>1,\*</sup> Mara Almog<sup>1</sup> Nina Dietzmeyer<sup>3,4</sup> Yuval Shapira<sup>2</sup>  
Kirsten Haastert-Talini<sup>3,4</sup> Shimon Rochkind<sup>1,2</sup> 

<sup>1</sup>Research Center for Nerve Reconstruction, Department of Neurosurgery, Tel Aviv Sourasky Medical Center, Tel Aviv, Israel

<sup>2</sup>Division of Peripheral Nerve Reconstruction, Department of Neurosurgery, Tel Aviv Sourasky Medical Center, Tel Aviv University, Tel Aviv, Israel

<sup>3</sup>Institute of Neuroanatomy and Cell Biology, Hannover Medical School, Hannover, Germany

<sup>4</sup>Center for Systems Neuroscience (ZSN), Hannover, Germany

**Address for correspondence** Shimon Rochkind, MD, PhD, Division of Peripheral Nerve Reconstruction, Department of Neurosurgery, Research Center for Nerve Reconstruction, Tel Aviv Sourasky Medical Center, Tel Aviv University, 6, Weizman Street, Tel Aviv 6423906, Israel (e-mail: rochkind@zahav.net.il).

J Brachial Plex Peripher Nerve Inj 2022;17:e22–e29.

## Abstract

**Background** The rabbit sciatic nerve injury model may represent a valuable alternative for critical gap distance seen in humans but often leads to automutilation. In this study, we modified the complete sciatic nerve injury model for avoiding autophagy.

**Materials and Methods** In 20 adult female New Zealand White rabbits, instead of transecting the complete sciatic nerve, we unilaterally transected the tibial portion and preserved the peroneal portion. Thereby loss of sensation in the dorsal aspect of the paw was avoided. The tibial portion was repaired in a reversed autograft approach in a length of 2.6 cm. In an alternative repair approach, a gap of 2.6 cm in length was repaired with a chitosan-based nerve guide.

**Results** During the 6-month follow-up period, there were no incidents of autotomy. Nerve regeneration of the tibial portion of the sciatic nerve was evaluated histologically and morphometrically. A clear difference between the distal segments of the healthy contralateral and the repaired tibial portion of the sciatic nerve was detectable, validating the model.

**Conclusion** By transecting the isolated tibial portion of the rabbit sciatic nerve and leaving the peroneal portion intact, it was possible to eliminate automutilation behavior.

## Keywords

- ▶ peripheral nerve reconstruction
- ▶ rabbit model
- ▶ automutilation behavior

## Introduction

Peripheral nerves are particularly susceptible to injury by trauma due to their long course and lack of skeletal protec-

tion. These injuries may cause severe distress in the form of motor dysfunction or debilitating neuropathic pain. Peripheral nerve injuries have a significant impact on the quality of life of the patients, as well as health care costs for patients and society. Attempts to correct these potentially life-long disabilities, require numerous reconstructive and

\* *Equally contributed.*

received  
March 6, 2021  
accepted after revision  
June 8, 2021

DOI <https://doi.org/10.1055/s-0042-1747959>  
ISSN 1749-7221.

© 2022. The Author(s).

This is an open access article published by Thieme under the terms of the Creative Commons Attribution License, permitting unrestricted use, distribution, and reproduction so long as the original work is properly cited. (<https://creativecommons.org/licenses/by/4.0/>)  
Georg Thieme Verlag KG, Rüdigerstraße 14, 70469 Stuttgart, Germany

rehabilitative sessions, often with dismal recoveries. Less than half of the patients regain significant motor or sensory functions.

While peripheral nerves do have the ability to regenerate spontaneously, the outcome is limited depending on nerve size, distance between the transected ends (nerve gap and defect length), eventual neuroma formation, and scar tissue development, consequently surgical intervention is often required.<sup>1</sup> In instances where the length of the nerve gap does not allow for approximation, or if this will cause excessive traction on the nerve, interposition of autologous nerve grafts is the gold-standard repair approach.<sup>2</sup> Despite the careful selection of a donor nerve, there still exists substantial burden from autologous nerve harvesting which has prompted the medical field to further explore alternatives.

Novel nerve graft developments need to be preclinically evaluated for their potential to substitute autologous nerve grafts. After efforts to limit in vivo animal studies have been exhausted, animal models need to be selected for preclinical evaluation. Beyond the selection of the type of nerve injury, the appropriate animal species and nerve must also be selected to achieve the experimental study goals.

The most commonly studied nerve is the sciatic nerve which innervates the hindlimb.<sup>3,4</sup> While the rat model has been the most widely utilized animal model in peripheral nerve regeneration research,<sup>5</sup> the rabbit model is thought to allow for closer modeling large gap lengths repair approaches.

In the rabbit, the sacral plexus is composed of the 4–7 lumbar nerves and the 1–3 sacral nerves. The main branches of the plexus include the femoral, obturator, and sciatic nerves. The sciatic nerve passes through the sciatic notch and becomes visible near the piriform muscle. It gives off branches that innervate the gluteal, semitendinosus, and semimembranosus muscles. It branches near the knee to form the tibial and peroneal nerve. The tibial nerve innervates the gastrocnemius, soleus, tibialis posterior, flexor digitorum longus, and flexor hallucis longus muscles. In the foot, it innervates the medial and lateral plantar nerves. The peroneal nerve splits to innervate the peroneus longus and peroneus brevis superficially and the deep peroneal nerve innervates the tibialis anterior, extensor hallucis longus, peroneus tertius, and extensor digitorum longus and brevis muscles.<sup>6</sup>

We have conducted a review of 40 reports in which a rabbit animal model was used for evaluation of nerve regeneration.<sup>7–46</sup> To date, the sciatic nerve injury and repair model is the most well-documented nerve injury model in rabbits with 45% of studies performed using the sciatic nerve. In a study by Hsu et al,<sup>19</sup> a 2-cm section of the sciatic nerve was removed after making an incision from the greater trochanter to the mi-calf and splitting the muscle to expose the sciatic nerve. However, the authors note that there is limited data on functional recovery, and the metrics used for rats, such as the sciatic functional index (SFI) and dynamic catwalks (DCW), were not applicable to rabbits. They developed their own metric based on limb extension associated

with peak amplitude of compound muscle potential in electrodiagnostical testing.<sup>19</sup> In an effort to better analyze nerve regeneration and provide another model of nerve injury, recent studies have been performed in an attempt to better characterize the rabbit brachial plexus and its motor innervation.<sup>47</sup> However, nerve selection beyond the sciatic nerve or its divisions has been limited, with the peroneal nerve being the second most well-studied nerve in just 18% of studies. An isolated injury to the tibial nerve has been selected in only 8% of studies.<sup>18,48</sup> Hill et al<sup>18</sup> made a longitudinal incision in the hindlimb to expose the tibial nerve. The nerve was then transected 1-cm proximal to its insertion into the gastrocnemius muscle. A 2- or 3-cm segment of the tibial nerve was excised, and the nerve allowed retracting. This study highlights a major issue; despite efforts to prevent autotomy, such as the use of E-collars, 15% of their rabbits had to be eliminated from the study due to excessive autotomy of the foot.

### Autotomy and Mitigation Strategies

The problem of autotomy is not unique to the study by Hill et al.<sup>18</sup> A significant problem with peripheral nerve reconstruction models is the animals' tendency to attack or otherwise damage the denervated digits or limb.<sup>49</sup> Automutilation behavior was first described in rats and mice and referred to as autotomy.<sup>50</sup> Autotomy begins with the nibbling of the toenail and over time this behavior progresses proximally to the phalanges and limb, also infection and edema may follow and forces the subsequent sacrifice of the animal. Events of amputation or sacrifice of the animal make behavioral analysis of functional regeneration impossible.

Automutilation behavior after neurotmesis is also known to occur in rabbits, for example, after sciatic nerve injury.<sup>18,51,52</sup> Our literature review of peripheral nerve rabbit models showed a 30% complication rate with 29% of complications attributed to autotomy. Of interest in the rabbit model are the strain and gender selection. Approximately 65% of cases reported, used the New Zealand Rabbit (*Oryctolagus cuniculus*). Studies on this strain are privileged due to good biocompatibility of experimental prosthetic materials.<sup>53</sup> Japanese, European, and Vienna rabbits have also been used at 16, 8, and 3%, respectively. The complication rate appears to be pervasive in male rabbits; with 66% of autotomy cases found occurring in males as opposed to 16% in females, although in some studies either complications were not mentioned or complications were reported regardless gender differences.

Our own attempts with diverse methods applied to prevent autotomy in rats and rabbits did unfortunately not result in the approval of one single or combined method. As utilization of rabbit models for large gap peripheral nerve regeneration studies grows, there continues to be a need to refine the model to alleviate this distress to the rabbit.<sup>54,55</sup>

The sciatic nerve divides into the peroneal and tibial nerves. Branches of the peroneal nerve innervate the dorsal and lateral areas of the hindlimb, while branches of the tibial nerve innervate structures of the medial and plantar surface

of the hindlimb. In the present study, we describe our attempt to modify the surgical approach by performing an isolated lesion to the tibial portion of the sciatic nerve to preserve sensation to the dorsal aspect of the hindlimb and paw innervated by the peroneal nerve, and thereby to eliminate automutilation behavior.

## Materials and Methods

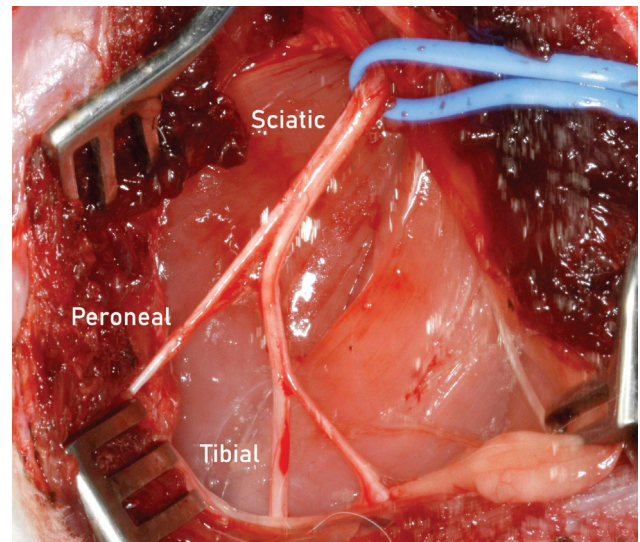
### Animals

All animal experiments were approved by the Institutional Animal Care and Usage Committee and adhered strictly to the Animal Care guidelines. Twenty female New Zealand White rabbits, weighing 2.5 to 3.0 kg each, were brought to the vivarium 2 weeks before the procedure and housed two per cage in a 12-hour light/dark cycle, with free access to food and water. The animals were marked, and each animal was ascribed to a test group by an independent researcher.

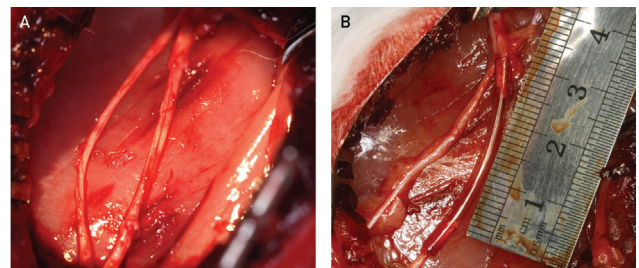
### Experimental Design and Surgical Technique

General anesthesia was induced with an intraperitoneal injection of medetomidine (0.25 mg/kg) and ketamine (15 mg/kg). The operation on the tibial portion of the sciatic nerve was performed on the left hindlimb. The rabbit was put in a prone position, the hindlimbs abducted and the skin over the lateral and caudal aspect of the limb up to the lumbar midline was sheared. An incision of approximately 6 cm in length was made along the fusion line of the muscles. The fascia was sharply divided and the two muscles (biceps femoris and semimembranosus) were bluntly retracted to enable access to the sciatic, peroneal, and tibial nerves. In one case, the entire sciatic nerve was transected, leading to a severe autotomy of the operated hindlimb; the rabbit was excluded from the study. Using a microscope, the tibial portion of the sciatic nerve was exposed and separated from the peroneal portion (►Fig. 1). The tibial portion of the sciatic nerve was transected proximally and distally, and a 2.6-cm gap created between the two ends. Then the rabbits were treated according to their group allocation: (1) group I—autologous nerve graft (control;  $n = 8$ ); (2) group II—Chitosan tube (Reaxon Nerve Guide, Medovent GmbH, Germany;  $n = 12$ ).

In group I, the 2.6-cm piece of the tibial nerve was reversed and transplanted. Immediately thereafter, an end-to-end anastomosis was performed between the peripheral nerve segment of 2.6-cm length and the proximal and distal parts of the left tibial nerve, using 10-0 sutures. Coaptation of the nerve fascicles was performed to preserve all the fascicles within the epineurial sac (►Fig. 2A). In group II, 1-cm nerve segment was removed and a 2.6-cm gap between the two ends created. The proximal and distal ends of the nerve were fixed by 10-0 epineurial sutures each with a 2-mm overlap inside 3-cm Reaxon Nerve Guides (preimmersed in saline), and microsurgically reconnected (►Fig. 2B). Then the muscles were sutured using 3-0 Vicryl threads and the skin was closed using special metal staples. Postoperative period was 6 months.



**Fig. 1** Anatomy of the rabbit sciatic nerve. The sciatic nerve divides into its main branches the peroneal nerve and the tibial nerve. The tibial nerve is the largest branch and gives rise to the sural nerve branch at midhigh level.



**Fig. 2** Reconstruction of the tibial portion of the sciatic nerve. The proximal and distal ends of the nerve were either reconstructed with autologous nerve graft (ANG), (A) or fixed by 10-0 epineurial sutures each with a 2-mm overlap inside 3-cm chitosan tube (B), creating a 2.6-cm gap between the two ends and microsurgically reconnected.

### Analysis of Axonal Regeneration—Nerve Stereology and Morphometry

Distal nerve segments of the lesioned left side (three for autograft and  $n = 4$  for chitosan tube), as well as healthy control samples ( $n = 10$ ) of the contralateral right side, were explanted for histomorphometry. Morphometrical analyses were performed according to our previous work.<sup>56–58</sup>

After fixating distal nerve segments in Karnovsky's solution (2% paraformaldehyde, 2.5% glutaraldehyde in 0.2 M sodium cacodylate buffer, pH = 7.3) for 24 hours,<sup>59</sup> samples were subjected to 0.1-M sodium cacodylate buffer containing 7.5% sucrose. For postfixation, samples were transferred to percentage osmium tetroxide for 1.5 hours. We used 1% potassium dichromate (for 24 hours), 25% ethanol (for 24 hours), and hematoxylin (0.5% in 70% ethanol for 24 hours) for staining of myelin sheaths. Samples were embedded into EPOX and afterward cut into semithin cross-sections (1- $\mu$ m thickness). To additionally enhance staining of the myelin sheaths, sections were stained with toluidine blue. Mowiol (Merck Millipore, Massachusetts, United States) was used to mount the sections.

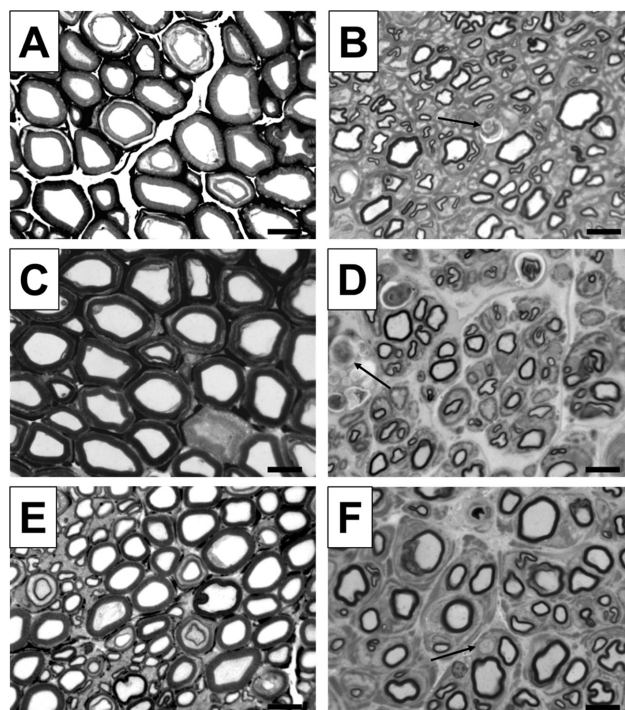
Evaluation of semithin nerve cross-sections were evaluated as described earlier<sup>56</sup> by using a BX50 microscope (Olympus Europa SE & Co. KG, Hamburg, Germany) which was expanded with a prior controller (MBF Bioscience, Williston, Vermont, United States). For analyses, two sections were randomly selected by using the Stereo Investigator software version 11.04 (MBF Bioscience). A two-dimensional procedure (optical fractionator; grid size:  $150 \times 150 \mu\text{m}^2$ ; counting frame size:  $30 \times 30 \mu\text{m}^2$ ; counting of "fiber tops" as suggested by Geuna and colleagues<sup>60</sup>) was used to determine the cross-sectional area (in  $\times 20$  magnification), the total number of myelinated fibers (in  $\times 100$  magnification), and the nerve fiber density. Samples from the autologous nerve graft repair ( $n = 3$ ) and healthy control nerve samples ( $n = 10$ ) were included into stereological and statistical evaluation. Samples from the chitosan tube repair group did not demonstrate axonal profiles in sufficient number for quantitative analysis.

After stereological evaluation, analyses of nerve morphometry were performed by taking photomicrographs of four randomly selected areas of each cross-section (in  $\times 100$  magnification). Axon and fiber diameters, myelin thicknesses, and *g*-ratios displayed the parameters which were analyzed. By using the software *g*-ratio plug-in (<http://gratio.efil.de/>) in ImageJ version 1.48 (National Institutes of Health, Bethesda, Maryland, United States), 10 axons per picture, leading to 80 axons per animal, were evaluated totally. To be able to calculate axon and fiber diameters, we made the assumption that their shape is circular as described by Geuna and colleagues.<sup>60</sup>

## Results

We changed the surgical approach for the rabbit sciatic nerve injury and repair model from lesioning all sciatic nerve (peroneal and tibial portion) to lesioning just the tibial portion (**Fig. 1**) with the hope that this nerve selection may be one method of reducing or even completely preventing autotomy behavior. By preferentially removing a segment of the tibial portion (**Fig. 2**), leaving the peroneal nerve intact, sensation at the dorsal aspect of the hindlimb should be preserved. We have not seen a case of autotomy in 20 out of the 20 female rabbits. In one separate single case, due to a transection of the entire sciatic nerve, autophagy was demonstrated within 14 days after surgery and the animal was excluded from the experiment.

As our laboratory furthered our research on nerve reconstruction model, it was necessary to obtain a larger animal model to achieve the desired gap length. The technique of sciatic nerve neurotmesis and reconstruction<sup>61–63</sup> that had been used in our rat models was attempted on the rabbit model yielding gross autophagy and early termination of the experiment. In an attempt to avoid further autophagy, the neurotmesis was selectively performed on the tibial portion of the sciatic nerve (**Fig. 2**). Preservation of the peroneal branch was implemented with the aim that the preserved partial innervation of the limb would limit autophagy. This modified procedure was found to completely eliminate



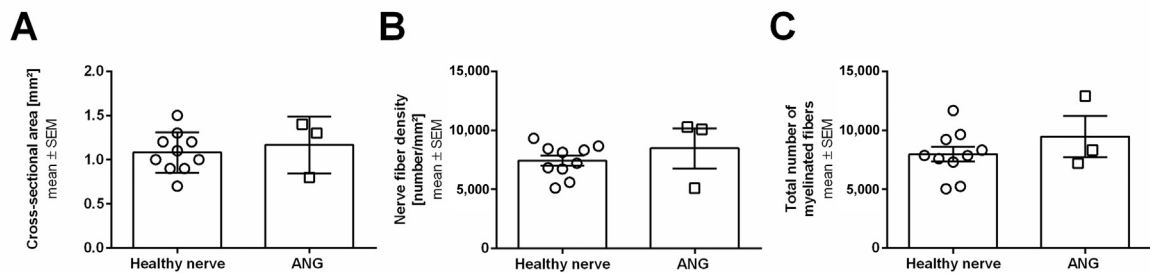
**Fig. 3** Representative pictures of toluidine blue-stained semi-thin cross-sections of distal nerve segments 6 months after reconstruction surgery. Images show healthy nerve segments (A, C, E) serving as control compared with distal nerve segments of sciatic nerves, which were reconstructed with autologous nerve grafts (ANGs) (B, D, F). Healthy nerve samples reveal axons with large diameters and thick myelin sheaths. Pictures of distal nerve segments of autologous nerve graft reconstructed sciatic nerves show successfully regenerated smaller axons with thinner myelin sheaths as well as axonal degeneration (indicated by arrow). Black scale bars display  $10 \mu\text{m}$ .

autophagy in the acute peripheral nerve injury of our rabbit model.

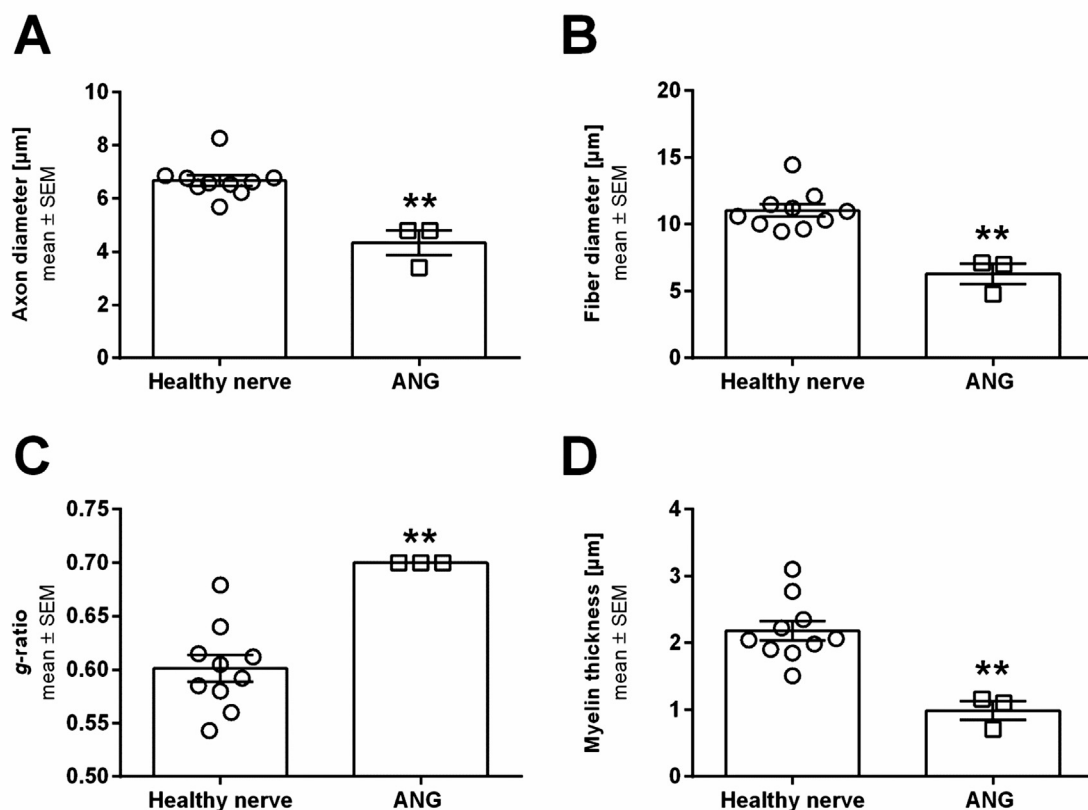
With regard to the analysis of axonal regeneration in this modified model, we could clearly detect differences. As shown in **Fig. 3**, healthy nerve samples reveal axons with large diameters and thick myelin sheaths, while distal nerve segments of autologous nerve graft reconstructed tibial nerves show successfully regenerated smaller axons with thinner myelin sheaths, as well as axonal degeneration. Quantitative analysis was also possible in the distal nerve segments obtained in our modified model (**Figs. 4 and 5**). While fiber counts did not demonstrate significant differences, the morphometrical analysis of axonal size parameters revealed the same. In contrast to detection of axonal regeneration, distal nerve segments after repair with chitosan tube appeared significantly degenerated and did not allow quantitative analysis.

## Discussion

The sciatic nerve injury and repair model has been extensively used in peripheral nerve regeneration testing, particularly in rats due to their size, ease of surgical access, presence of sensory and motor fibers, established behavioral functional tests, and number of comparable studies.<sup>4,5,49,64–67</sup> Because



**Fig. 4** Scatter plot with bar graphs displaying results from histomorphometrical analyses of distal nerve segments from healthy or autologous nerve graft reconstructed sciatic nerves at 6 months of postsurgery. Cross-sectional areas (A), nerve fiber densities (B), and total numbers of myelinated fibers (C) are shown. No significant differences ( $p < 0.05$ ) were detected by Mann–Whitney test. Results are presented as mean  $\pm$  SEM (healthy nerve:  $n = 10$ ; ANG:  $n = 3$ ). ANG, autologous nerve graft; SEM, standard error of mean.



**Fig. 5** Scatter plot with bar graphs displaying results from histomorphometrical analyses of distal nerve segments from healthy or autologous nerve graft reconstructed sciatic nerves at 6 months post-surgery. Axon diameters (A), fiber diameters (B),  $g$ -ratios (C), and myelin thicknesses (D) are shown. Significant differences ( $p < 0.05$ ) were detected by Mann–Whitney test (\*\* $p < 0.01$  vs. healthy nerve). Results are presented as mean  $\pm$  SEM (healthy nerve:  $n = 10$ ; ANG:  $n = 3$ ). ANG, autologous nerve graft; SEM, standard error of mean.

the model has been so well developed, it has extended into larger animal models. However, the use of such a model in larger animals has significant drawbacks.

Our experience with autotomy in rabbits following sciatic neurotmesis has, for this reason, prompted a change in our procedure. We have found that nerve selection may be one method of reducing this autotomy. By preferentially removing a segment of the tibial nerve, leaving the peroneal nerve preserved, sensation to the dorsal aspect of the hindlimb should remain intact. Thus, in our model, we transect only

the tibial nerve of rabbits, with the intention of preserving sensation to part of the hindlimb with the aim of limiting or preventing autophagy.

Despite the induced loss of sensation to the plantar surface of the foot, by maintaining dorsal innervation, we have detected a remarkable reduction in autophagy. Of the 20 female rabbits operated, none showed a sign of autophagy. This absence of autophagy is remarkable compared with the 16% found in the sciatic nerve model of female rabbits. We must emphasize that our study was limited to female

New Zealand rabbits. To further validate the model, it should be performed on male rabbits to see if the complication rate can be similarly lowered from that of the current 66% or eliminated altogether.<sup>7-46</sup>

## Limitations

One limitation of using a subsidiary of the sciatic nerve is a decreased resectable length. It is not possible to perform a graft greater than 3 cm, as it involves nearly the entire length of the nerve; clinically, peripheral nerve reconstruction is not performed on the entire length of the injured peripheral nerve. Our study utilized a 3-cm nerve conduit, allowing for 2 mm of distal and proximal nerve coverage, providing a 2.6-cm nerve gap, making our modified sciatic nerve model an extreme model. If a larger nerve gap is desired, for example 7 to 8 cm, another animal model, such as a sheep or monkey, may need to be selected.

Unfortunately, in the follow-up period, no functional studies were performed, due to the lack of a functional test that could examine the injured tibial nerve in the rabbit. While this is a drawback in comparison to the sciatic model in rats, the development of relevant functional testing is complicated by vast difference in gait and movement between rats, rabbits, and humans. Thus, very few functional tests have been developed for the sciatic nerve injury and repair model in rabbits and may be a focus of future development. Consistent with all other nerve regeneration models, histological evaluation can still be performed at the end of the follow-up period, and we have demonstrated its value in a peripheral nerve injury model, as well as in our modified sciatic nerve model.

## Conclusion

As our research on nerve graft guides progressed, it was necessary to obtain a larger animal model to achieve the desired gap length. The technique of sciatic nerve neurotmesis that had been used in our rat models<sup>61-63</sup> was attempted on the rabbit model yielding gross autophagy and early termination of the experiment. In an attempt to avoid further autophagy, the neurotmesis was selectively performed on the tibial portion of the sciatic nerve with preservation of the peroneal portion. This was performed with the hope that intact innervation to dorsal part of the limb would limit autophagy. It was found to completely eliminate autophagy; while nerve regeneration of the injured nerve still occurs. With such a remarkable reduction in cases of autophagy, it is our recommendation to further test and develop the described modified sciatic nerve injury model as a standard for peripheral nerve injury model in rabbits.

### Funding

This study was supported by the German-Israeli Foundation for Scientific Research and Development, grant number: G-1350-409.10/2016

### Conflict of Interest

None declared.

### Acknowledgments

The authors thank Silke Fischer, Natascha Heidrich, and Jennifer Metzen from the Institute of Neuroanatomy and Cell Biology (Hannover Medical School) for excellent technical assistance. They also thank Drs. Christina Barwig and Thomas Freier (Medovent GmbH, Germany) for fruitful discussion during preparation of the study and Dr. Alex Litvak (Tel Aviv Sourasky Medical Center) for veterinary services.

## References

- Siemionow M, Brzezicki G. Chapter 8: current techniques and concepts in peripheral nerve repair. *Int Rev Neurobiol* 2009; 87:141-172
- Kim DH, Midha R, Murovic JA, Spinner RJKline & Hudson's Nerve Injuries. *Operative Results for Major Nerve Injuries, Entrapments, and Tumors*. Philadelphia, PA: Saunders Elsevier; 2008:505
- Geuna S. The sciatic nerve injury model in pre-clinical research. *J Neurosci Methods* 2015;243:39-46
- Nichols CM, Myckatyn TM, Rickman SR, Fox IK, Hadlock T, Mackinnon SE. Choosing the correct functional assay: a comprehensive assessment of functional tests in the rat. *Behav Brain Res* 2005;163(02):143-158
- Angius D, Wang H, Spinner RJ, Gutierrez-Cotto Y, Yaszemski MJ, Windebank AJ. A systematic review of animal models used to study nerve regeneration in tissue-engineered scaffolds. *Biomaterials* 2012;33(32):8034-8039
- Malik S, Ahmed S, Azeem MA, Noushad S, Sherwani SK. Comparison of sciatic nerve course in amphibians, reptiles and mammals. *FUUAST J Biol* 2011;1(02):7-14
- Amillo S, Yáñez R, Barrios RH. Nerve regeneration in different types of grafts: experimental study in rabbits. *Microsurgery* 1995;16(09):621-630
- Barmpitsioti A, Konofaos P, Ignatiadis I, Papalois A, Zoubos AB, Soucacos PN. Nerve growth factor combined with an epineural conduit for bridging a short nerve gap (10 mm). A study in rabbits. *Microsurgery* 2011;31(07):545-550
- Bayram B, Akdeniz SS, Diker N, Helvacioğlu F, Erdem SR. Effects of platelet-rich fibrin membrane on sciatic nerve regeneration. *J Craniofac Surg* 2018;29(03):e239-e243
- Boriani F, Fazio N, Fotia C, et al. A novel technique for decellularization of allogenic nerves and in vivo study of their use for peripheral nerve reconstruction. *J Biomed Mater Res A* 2017;105(08):2228-2240
- Bulstra LF, Hundepool CA, Friedrich PF, Nijhuis THJ, Bishop AT, Shin AY. Motor nerve recovery in a rabbit model: description and validation of a noninvasive ultrasound technique. *J Hand Surg Am* 2016;41(01):27-33
- Donzelli R, Capone C, Sgulò FG, Mariniello G, Maiuri F. Vascularized nerve grafts: an experimental study. *Neurol Res* 2016;38(08):669-677
- Gao H, You Y, Zhang G, Zhao F, Sha Z, Shen Y. The use of fiber-reinforced scaffolds cocultured with Schwann cells and vascular endothelial cells to repair rabbit sciatic nerve defect with vascularization. *BioMed Res Int* 2013;2013:362918
- Geuna S, Tos P, Battiston B, Giacobini-Robecchi MG. Bridging peripheral nerve defects with muscle-vein combined guides. *Neurol Res* 2004;26(02):139-144
- Giovanoli P, Koller R, Meuli-Simmen C, et al. Functional and morphometric evaluation of end-to-side neurotmesis for muscle reinnervation. *Plast Reconstr Surg* 2000;106(02):383-392

- 16 Heijke GC, Klopper PJ, Van Doorn IB, Baljet B. Processed porcine collagen tubulization versus conventional suturing in peripheral nerve reconstruction: an experimental study in rabbits. *Microsurgery* 2001;21(03):84–95
- 17 Henry FP, Goyal NA, David WS, et al. Improving electrophysiological and histologic outcomes by photochemically sealing amnion to the peripheral nerve repair site. *Surgery* 2009;145(03):313–321
- 18 Hill PS, Apel PJ, Barnwell J, et al. Repair of peripheral nerve defects in rabbits using keratin hydrogel scaffolds. *Tissue Eng Part A* 2011;17(11,12):1499–1505
- 19 Hsu SH, Chan SH, Chiang CM, Chen CC, Jiang CF. Peripheral nerve regeneration using a microporous polylactic acid asymmetric conduit in a rabbit long-gap sciatic nerve transection model. *Biomaterials* 2011;32(15):3764–3775
- 20 Hu C, Zhang T, Deng Z, et al. Study on the effect of vacuum sealing drainage on the repair process of rabbit sciatic nerve injury. *Int J Neurosci* 2015;125(11):855–860
- 21 Ignatiadis IA, Yiannakopoulos CK, Barbitsioti AD, et al. Diverse types of epineural conduits for bridging short nerve defects. An experimental study in the rabbit. *Microsurgery* 2007;27(02):98–104
- 22 Ikumi A, Hara Y, Yoshioka T, Kanamori A, Yamazaki M. Effect of local administration of platelet-rich plasma (PRP) on peripheral nerve regeneration: An experimental study in the rabbit model. *Microsurgery* 2018;38(03):300–309
- 23 Kakinoki S, Nakayama M, Moritan T, Yamaoka T. Three-layer microfibrillar peripheral nerve guide conduit composed of elastin-laminin mimetic artificial protein and poly(L-lactic acid). *Front Chem* 2014;2:52
- 24 Lasso JM, Pérez Cano R, Castro Y, Arenas L, García J, Fernández-Santos ME. Xenotransplantation of human adipose-derived stem cells in the regeneration of a rabbit peripheral nerve. *J Plast Reconstr Aesthet Surg* 2015;68(12):e189–e197
- 25 Li YJ, Zhao BL, Lv HZ, Qin ZG, Luo M. Acellular allogeneic nerve grafting combined with bone marrow mesenchymal stem cell transplantation for the repair of long-segment sciatic nerve defects: biomechanics and validation of mathematical models. *Neural Regen Res* 2016;11(08):1322–1326
- 26 Lutz BS, Chuang DC, Chuang SS, Hsu JC, Ma SF, Wei FC. Nerve transfer to the median nerve using parts of the ulnar and radial nerves in the rabbit—effects on motor recovery of the median nerve and donor nerve morbidity. *J Hand Surg [Br]* 2000;25(04):329–335
- 27 Matsuzaki H, Shibata M, Jiang B, Takahashi HE. Distal nerve elongation vs nerve grafting in repairing segmental nerve defects in rabbits. *Microsurgery* 2004;24(03):207–212
- 28 Mekaj AY, Manxhuka-Kerliu S, Morina AA, Duci SB, Shahini L, Mekaj YH. Effects of hyaluronic acid and tacrolimus on the prevention of perineural scar formation and on nerve regeneration after sciatic nerve repair in a rabbit model. *Eur J Trauma Emerg Surg* 2017;43(04):497–504
- 29 Mekaj AY, Morina AA, Manxhuka-Kerliu S, et al. Electrophysiological and functional evaluation of peroneal nerve regeneration in rabbit following topical hyaluronic acid or tacrolimus application after nerve repair. *Niger Postgrad Med J* 2015;22(03):179–184
- 30 Meng WK, Huang Z, Tan Z, et al. [Vein nerve conduit supported by vascular stent in the regeneration of peripheral nerve in rabbits] (in Chinese). *Sichuan Da Xue Xue Bao Yi Xue Ban* 2017;48(05):687–692
- 31 Mligiliche NL, Tabata Y, Kitada M, et al. Poly lactic acid–caprolactone copolymer tube with a denatured skeletal muscle segment inside as a guide for peripheral nerve regeneration: a morphological and electrophysiological evaluation of the regenerated nerves. *Anat Sci Int* 2003;78(03):156–161
- 32 Mohammad JA, Warnke PH, Pan YC, Shenaq S. Increased axonal regeneration through a biodegradable amniotic tube nerve conduit: effect of local delivery and incorporation of nerve growth factor/hyaluronic acid media. *Ann Plast Surg* 2000;44(01):59–64
- 33 Mohanna PN, Young RC, Wiberg M, Terenghi G. A composite poly-hydroxybutyrate-glia growth factor conduit for long nerve gap repairs. *J Anat* 2003;203(06):553–565
- 34 Piskin A, Altunkaynak BZ, Çitlak A, Sezgin H, Yazıcı O, Kaplan S. Immediate versus delayed primary nerve repair in the rabbit sciatic nerve. *Neural Regen Res* 2013;8(36):3410–3415
- 35 Ruch DS, Deal DN, Ma J, et al. Management of peripheral nerve defects: external fixator-assisted primary neuroorrhaphy. *J Bone Joint Surg Am* 2004;86(07):1405–1413
- 36 Sahakyants T, Lee JY, Friedrich PF, Bishop AT, Shin AY. Return of motor function after repair of a 3-cm gap in a rabbit peroneal nerve: a comparison of autograft, collagen conduit, and conduit filled with collagen-GAG matrix. *J Bone Joint Surg Am* 2013;95(21):1952–1958
- 37 Schmitz HC, Beer GM. The toe-spreading reflex of the rabbit revisited—functional evaluation of complete peroneal nerve lesions. *Lab Anim* 2001;35(04):340–345
- 38 Sharula, Hara Y, Nishiura Y, Saijilafu, Kubota S, Ochiai N. Repair of the sciatic nerve defect with a direct gradual lengthening of proximal and distal nerve stumps in rabbits. *Plast Reconstr Surg* 2010;125(03):846–854
- 39 Shibata M, Breidenbach WC, Ogden L, Firrell J. Comparison of one- and two-stage nerve grafting of the rabbit median nerve. *J Hand Surg Am* 1991;16(02):262–268
- 40 Strauch B, Ferder M, Lovelle-Allen S, Moore K, Kim DJ, Llena J. Determining the maximal length of a vein conduit used as an interposition graft for nerve regeneration. *J Reconstr Microsurg* 1996;12(08):521–527
- 41 Strauch B, Rodriguez DM, Diaz J, Yu HL, Kaplan G, Weinstein DE. Autologous Schwann cells drive regeneration through a 6-cm autogenous venous nerve conduit. *J Reconstr Microsurg* 2001;17(08):589–595, discussion 596–597
- 42 Wang Y, Li ZW, Luo M, Li YJ, Zhang KQ. Biological conduits combining bone marrow mesenchymal stem cells and extracellular matrix to treat long-segment sciatic nerve defects. *Neural Regen Res* 2015;10(06):965–971
- 43 Whitworth IH, Doré CJ, Green CJ, Terenghi G. Increased axonal regeneration over long nerve gaps using autologous nerve-muscle sandwich grafts. *Microsurgery* 1995;16(12):772–778
- 44 Yin D, Wang XH, Yan Y, Zhang R. Preliminary studies on peripheral nerve regeneration using a new polyurethane conduit. *J Bioact Compat Polym* 2007;22:143–159
- 45 Young RC, Wiberg M, Terenghi G. Poly-3-hydroxybutyrate (PHB): a resorbable conduit for long-gap repair in peripheral nerves. *Br J Plast Surg* 2002;55(03):235–240
- 46 Zhang Z, Johnson EO, Vekris MD, et al. Repair of the main nerve trunk of the upper limb with end-to-side neuroorrhaphy: an experimental study in rabbits. *Microsurgery* 2006;26(04):245–252
- 47 Kollitz KM, Giusti G, Friedrich PF, Bishop AT, Shin AY. The rabbit brachial plexus as a model for nerve injury and repair part 1: anatomic study of the biceps and triceps innervation. *Microsurgery* 2020;40(02):183–188
- 48 Boriani F, Savarino L, Fazio N, et al. Auto-allo graft parallel juxtaposition for improved neuroregeneration in peripheral nerve reconstruction based on acellular nerve allografts. *Ann Plast Surg* 2019;83(03):318–325
- 49 Weber RA, Proctor WH, Warner MR, Verheyden CN. Autotomy and the sciatic functional index. *Microsurgery* 1993;14(05):323–327
- 50 Wall PD, Devor M, Inbal R, et al. Autotomy following peripheral nerve lesions: experimental anaesthesia dolorosa. *Pain* 1979;7(02):103–113
- 51 Magnusson JE, Vaccarino AL. Reduction of autotomy following peripheral neurectomy by a single injection of bupivacaine into the cingulum bundle of rats. *Brain Res* 1996;723(1,2):214–217

- 52 Vachon P. Self-mutilation in rabbits following intramuscular ketamine-xylazine-acepromazine injections. *Can Vet J* 1999;40(08):581–582
- 53 Calasans-Maia MD, Monteiro ML, Ascoli FO, Granjeiro JM. The rabbit as an animal model for experimental surgery. *Acta Cir Bras* 2009;24(04):325–328
- 54 Robinson V. Finding alternatives: an overview of the 3Rs and the use of animals in research. *Sch Sci Rev* 2005;87(319):111–114
- 55 Russell WMS, Burch RL. *The Principles of Humane Experimental Technique*. Wheathampstead, United Kingdom: Universities Federation for Animal Welfare; 1992:238
- 56 Stößel M, Rehra L, Haastert-Talini K. Reflex-based grasping, skilled forelimb reaching, and electrodiagnostic evaluation for comprehensive analysis of functional recovery-The 7-mm rat median nerve gap repair model revisited. *Brain Behav* 2017;7(10):e00813
- 57 Dietzmeyer N, Förthmann M, Leonhard J, et al. Two-chambered chitosan nerve guides with increased bendability support recovery of skilled forelimb reaching similar to autologous nerve grafts in the rat 10 mm median nerve injury and repair model. *Front Cell Neurosci* 2019;13:149
- 58 Dietzmeyer N, Huang Z, Schüning T, et al. In vivo and in vitro evaluation of a novel hyaluronic acid-laminin hydrogel as luminal filler and carrier system for genetically engineered Schwann cells in critical gap length tubular peripheral nerve graft in rats. *Cell Transplant* 2020;29:963689720910095
- 59 Korte N, Schenk HC, Grothe C, Tipold A, Haastert-Talini K. Evaluation of periodic electrodiagnostic measurements to monitor motor recovery after different peripheral nerve lesions in the rat. *Muscle Nerve* 2011;44(01):63–73
- 60 Geuna S, Tos P, Battiston B, Guglielmo R. Verification of the two-dimensional disector, a method for the unbiased estimation of density and number of myelinated nerve fibers in peripheral nerves. *Ann Anat* 2000;182(01):23–34
- 61 Rochkind S, Astachov L, el-Ani D, et al. Further development of reconstructive and cell tissue-engineering technology for treatment of complete peripheral nerve injury in rats. *Neurol Res* 2004;26(02):161–166
- 62 Rochkind S, Nevo Z. Recovery of peripheral nerve with massive loss defect by tissue engineered guiding regenerative gel. *BioMed Res Int* 2014;2014:327578
- 63 Shapira Y, Tolmasov M, Nissan M, et al. Comparison of results between chitosan hollow tube and autologous nerve graft in reconstruction of peripheral nerve defect: An experimental study. *Microsurgery* 2016;36(08):664–671
- 64 Bozkurt A, Deumens R, Scheffel J, et al. CatWalk gait analysis in assessment of functional recovery after sciatic nerve injury. *J Neurosci Methods* 2008;173(01):91–98
- 65 Bozkurt A, Tholl S, Wehner S, et al. Evaluation of functional nerve recovery with Visual-SSI—a novel computerized approach for the assessment of the static sciatic index (SSI). *J Neurosci Methods* 2008;170(01):117–122
- 66 Tos P, Ronchi G, Papalia I, et al. Chapter 4: methods and protocols in peripheral nerve regeneration experimental research: part I-experimental models. *Int Rev Neurobiol* 2009; 87:47–79
- 67 Varejão AS, Melo-Pinto P, Meek MF, Filipe VM, Bulas-Cruz J. Methods for the experimental functional assessment of rat sciatic nerve regeneration. *Neurol Res* 2004;26(02):186–194