



Research Paper

The infrahyoid myocutaneous flap for reconstruction after oral cancer resection: A retrospective single-surgeon study

Adit Chotipanich*, Sombat Wongmanee

Department of Otolaryngology, Chonburi Cancer Hospital, Department of Medical Services, Ministry of Public Health, Thailand

Received 3 October 2017; accepted 13 July 2018
Available online 10 August 2018

KEYWORDS

Infrahyoid flap;
Oral surgery;
Intraoral
reconstruction;
Pedicled flap;
Local flap;
Flap failure;
Tongue surgery

Abstract *Objective:* To review our experience with infrahyoid myocutaneous flap in reconstruction after oral cancer resection.

Methods: Chart reviews were completed for all patients who underwent oral reconstruction with an infrahyoid myocutaneous flap by a single surgeon in the Department of Otolaryngology at Chonburi Cancer Hospital from 2011 to 2017. Characteristics of the patients and postoperative complications were analyzed.

Results: Of the 34 patients in the study, 10 (29.4%) developed partial flap loss and 1 (2.9%) developed total flap loss. All cases of partial flap loss resolved with conservative treatment. Apparent cancer involvement of a cervical lymph node was significantly associated with flap failure (*odds ratio:* 5.0, *95% CI:* 1.03–24.28).

Conclusions: The infrahyoid myocutaneous flap is a fairly reliable reconstruction method. The flap should be performed with caution in cases with gross lymph node involvement.

Copyright © 2018 Chinese Medical Association. Production and hosting by Elsevier B.V. on behalf of KeAi Communications Co., Ltd. This is an open access article under the CC BY-NC-ND license (<http://creativecommons.org/licenses/by-nc-nd/4.0/>).

* Corresponding author. Head and Neck Unit, Chonburi Cancer Hospital, 300 Muang District, Chonburi, 20000, Thailand.
E-mail address: oad.adit@gmail.com (A. Chotipanich).
Peer review under responsibility of Chinese Medical Association.



Production and Hosting by Elsevier on behalf of KeAi

Introduction

The infrahyoid myocutaneous flap (IHF), a pedicled myocutaneous flap, is one of the flaps used in reconstructive procedures for small- and medium-sized defects following resection of head and neck cancers. The advantages of the flap include its relatively low surgical complexity, a short operative time, and little morbidity at the donor site. However, after its introduction by Wang et al¹ in 1980, the popularity of the flap has been eclipsed because of its fragile skin paddle and advances in free-flap reconstructions. Complications commonly related to the flap are caused by the unreliability of the skin paddle. In a literature review, the frequency of complications was reported as 0–47%, with failures mainly related to partial skin necrosis, and the rate of total flap necrosis was about 1%.^{2,3} Partial skin necrosis usually resolves without further surgical revision but may prolong the hospital stay and cause serious complications if a severe salivary leak occurs. Therefore, many surgeons opt for a more complex but reliable free flap rather than a simple but less reliable IHF.

In this retrospective study, we review our experience with IHF reconstruction after oral cancer resection and evaluate possible risk factors that might contribute to flap failure.

Materials and methods

The study was a retrospective review of reconstruction using IHF after oral cancer resection performed in the Department of Otolaryngology at Chonburi Cancer Hospital. This hospital has been designated a referral center for patients with cancer from 8 provinces in Eastern Thailand. Data were obtained from medical records. We began to use IHF reconstruction in 2009. To minimize the influences of experience and the surgical learning curve, only patients who underwent surgery from 2011 onward were included. All surgeries were performed by the same surgeon. Patients who underwent radiation prior to surgery were excluded. Internal review

board authorization was approved for this retrospective chart review. Patients whose photographs were taken provided their informed consent for publication. The Internal review board waived the requirement for informed consent for patients who do not appear in photographs.

Assessment of flap viability

Flap viability was determined during a clinical examination and categorized into 3 groups: normal, partial, and total flap loss. Partial flap loss was defined as loss of only the skin and dermis, an intact muscular layer, and cases not requiring surgical intervention. Total flap loss was defined as the complete loss of skin, dermis, and muscles, and cases requiring surgical intervention.

Surgical technique

The surface markings for the flap are made by drawing a line vertically from the midline of the hyoid bone to the manubrium and another line just lateral to the anterior margin of the sternocleidomastoid muscle. The upper border of the skin paddle is positioned inferior to the hyoid bone. The length of the skin paddle depends on the reconstructive requirements but the lower border should not be located below the suprasternal notch (Fig. 1). An incision is made through the platysma muscle. Care must be taken to not make the incision too deep at the superior lateral margin of the skin paddle because this may cause injury to the feeding vessels that lie beneath the platysma. The medial border of the flap is incised through the fascia until the thyroid capsule and trachea are reached. The skin paddle is attached to the underlying muscles with a few sutures to minimize the risk of a shearing injury to myocutaneous perforators. The strap muscles are sectioned at the origin. The internal jugular vein is identified at the lower level of the neck. Then, the lateral border of the flap is dissected in a superior direction along the internal jugular vein. The middle thyroid vein is identified and ligated.

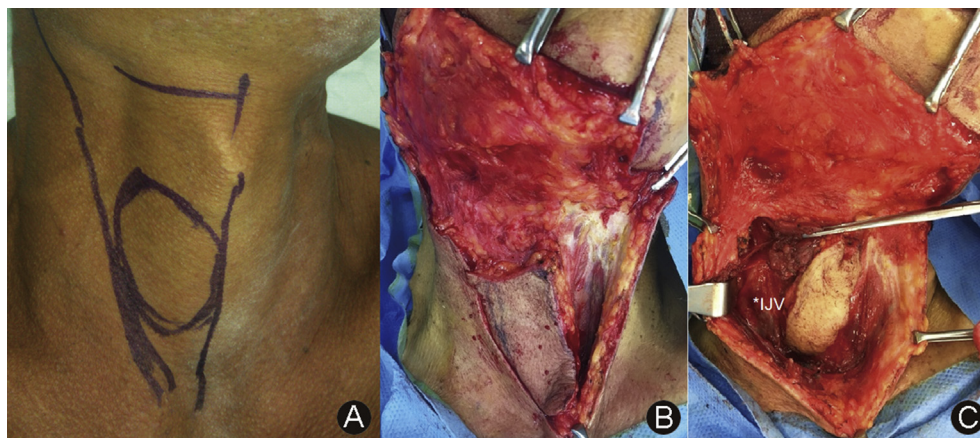


Fig. 1 The surface marking for the infrahyoid myocutaneous flap. The neck's position is slightly extended and placed in a midline position so that the skin paddle is in alignment with the infrahyoid muscles (A). The medial border of the flap is incised through the fascia until the thyroid capsule and trachea are reached (B). The internal jugular vein is identified at the lower level of the neck. Then, the lateral border of the flap is dissected in a superior direction along the internal jugular vein (C). (IJV: internal jugular vein).

The superior thyroid vessels are identified and then traced anteriorly until they reach the lateral border of the omohyoid muscle. After the feeding vessels are cleaned and preserved, the IHF is elevated from the avascular plane above the thyroid gland. The strap muscles are detached from the hyoid bone. Finally, the IHF is ready (Fig. 2); the neck dissection is then performed. Fig. 3 shows the

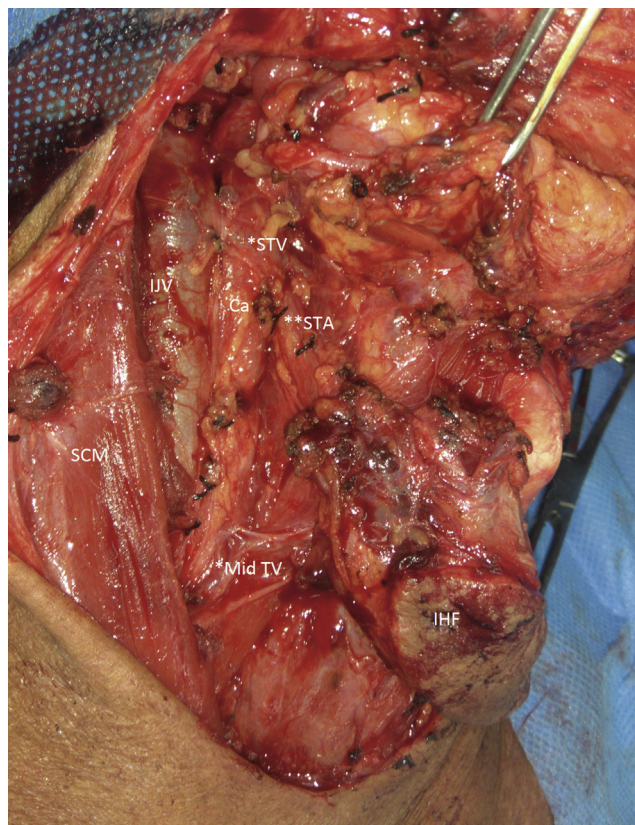


Fig. 2 The harvested flap. The middle thyroid vein is ligated later to facilitate transposition of the flap. (Ca: carotid artery; IHF: infrahyoid myocutaneous flap; IJV: internal jugular vein; Mid TV: middle thyroid vein; SCM: sternocleidomastoid muscle; STA: superior thyroid artery; STV: superior thyroid vein).

transposition of IHF for reconstruction following resection of tongue cancer. Fig. 4 shows postoperative photographs of a patient with cancer on the right side of the tongue.

Statistical analysis

Descriptive statistics were employed to characterize the data. Odds ratios were used to assess associations between flap failure and risk factors. Statistical analyses were performed using SPSS 17.0 statistical software (SPSS Inc., Chicago, IL, USA). A P -value < 0.05 was considered statistically significant.

Results

Between 2011 and 2017, 34 reconstructions utilizing an IHF met the inclusion criteria. The indication in all patients was T2–T3 oral cancer (involving the tongue and floor of the mouth). Overall flap-related complications were recorded in 11 (32.4%) patients; of these, 10 (29.4%) were partial flap losses and 1 (2.9%) developed total flap necrosis. The average lengths of the hospital stays were 14 days in the normal flap group and 19 days in the flap loss group. Of the 10 cases with partial flap loss, 6 developed wound fistulas that resolved with conservative treatments (Fig. 5). The patient who developed total flap loss underwent a revision flap surgery. Feeding tubes were successfully removed from all patients in this study. No patient died during the 6 months after the surgery. Table 1 shows comparisons of characteristics and outcomes between the normal flap viability and flap loss groups. Patients with clinically negative cervical lymph nodes underwent selective neck dissection at levels I–III. Selective neck dissection at levels I–IV or modified radical neck dissection was performed in patients with one or more palpable lymph nodes.

Discussion

Currently, free-flap reconstruction, like the radial forearm free flap, is the first choice for medium-sized defect reconstruction in the oral cavity because it is highly reliable

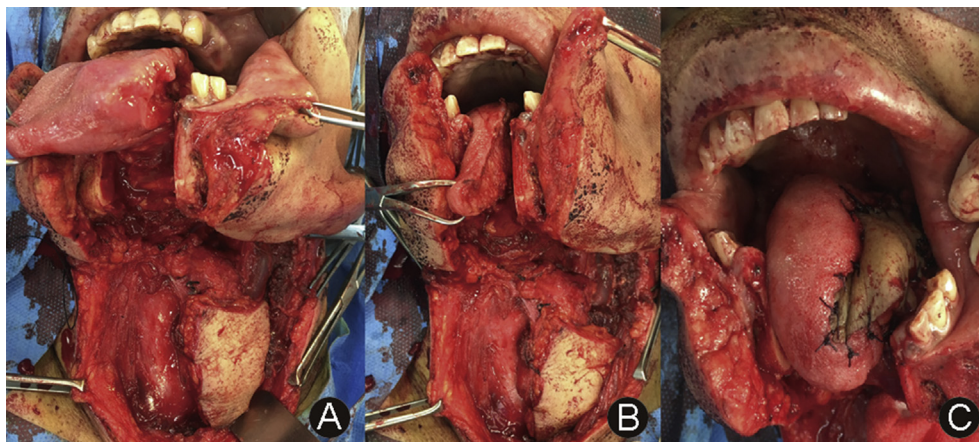


Fig. 3 Intraoperative photographs of the flap transposition. A patient with cancer on the left lateral border of the tongue before tumor resection (A), after tumor resection (B). The flap has been sutured in place (C).

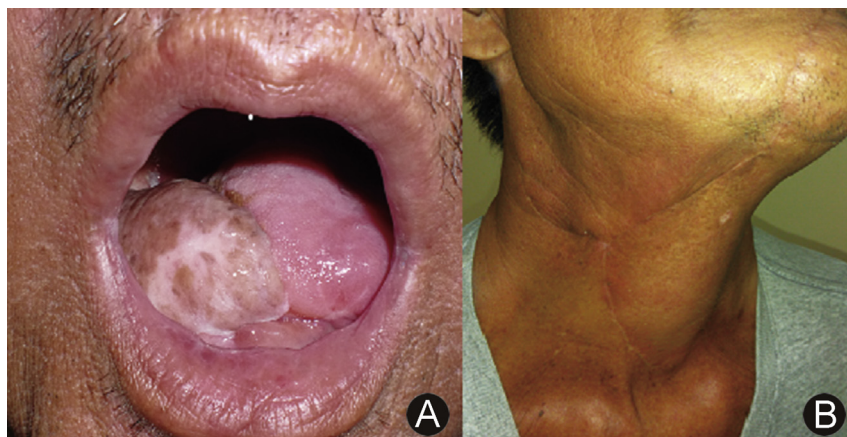

Fig. 4 Postoperative photographs of a patient. The infrahoid myocutaneous flap (IHF) provides an optimal contour for the tongue (A). Donor site morbidity is minimal and the cosmetic result is acceptable (B).

and demonstrates improved cosmetic and functional results. However, not all patients are suitable for complex free-flap surgeries. Moreover, it may not be feasible to provide free-flap surgeries for all patients in Thailand because of the large number of patients, resource constraints, and associated costs. For these reasons, reconstructions using a regional flap still play an important role in oral cancer treatment. The pectoralis major myocutaneous flap is commonly used because of its robustness and versatility. Despite the advantages of the pectoralis major myocutaneous flap, it is too bulky to use for medium-sized defect reconstruction.⁴ On the other hand, the IHF is more suitable for repairing medium-sized defects in the oral cavity.³

Reconstructions using the IHF frequently experienced problems related to skin paddle reliability.^{2,5,6} The reported complication rate was as high as 47% in one study.⁶ These problems may result from the unique nature of the venous system in the skin paddle. The IHF skin paddle is nourished by the superior thyroid vessels through the perforators of the infrahoid muscles.^{7,8} Under normal physiological conditions, the venous system in the skin and subcutaneous tissue of the infrahoid area is mainly drained by the anterior and external jugular veins; less is drained by the perforators that pierce through the platysma muscle.^{7,8} When the IHF is harvested, the venous drainage of skin via superficial veins is eliminated and leaves the main venous drainage to depend solely on perforators from the strap muscles. Minor shearing or pressure during surgery could easily injure the perforators, making the flap vulnerable to skin necrosis.

To our knowledge, this study is the largest single-surgeon case series to date on IHF reconstruction. The results of this study show that IHF is fairly reliable and safe for use in reconstruction after oral cancer resection. Most flap losses were only partial, and the rate of total flap loss was about 2.9%. This finding is similar to that reported in other studies.² Donor site morbidity was minor and no substantial swallowing dysfunction occurred in this study. Apparent cancer involvement of a cervical lymph node was significantly associated with flap failure (*odds ratio*: 5.0; *95% CI*: 1.03–24.28). The case with lymph node involvement required more aggressive treatment of the neck, which results in a greater chance of vascular trauma. This might explain why gross lymph node involvement affects flap viability.

From our experience, the largest flap dimension was 9–10 cm long and 4–5 cm wide. Primary closure of donor defects with a width greater than this is difficult to perform. Smaller sizes of the flap can be designed depending on the reconstructive requirements. However, the study result shows that the cases of a T3 stage tumor with subsequent need for a larger flap reconstruction had a lower flap failure rate than those of a T2 stage tumor (22.7% vs 50%). A larger flap contains more perforator vessels supplying the overlying skin. This explains why the larger flap is more reliable than the smaller one. But it should be noted that the difference in flap failure rates between T2 and T3 stages was not statistically significant.

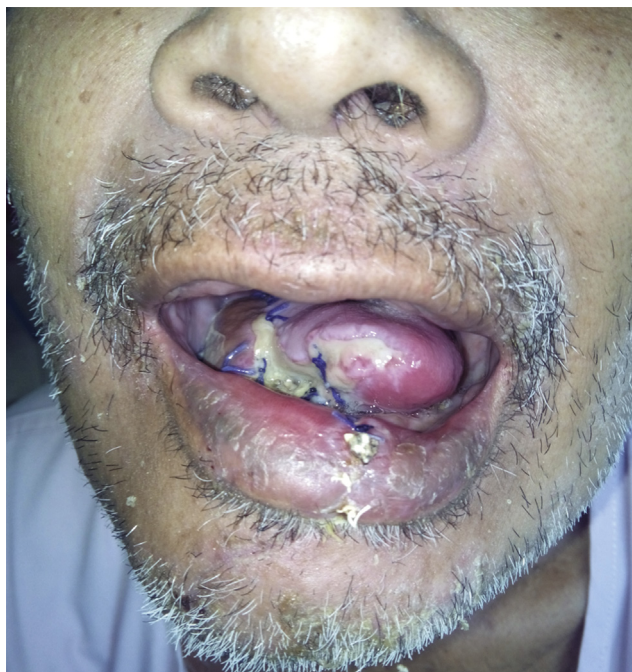

Fig. 5 Patient who developed partial flap necrosis on the 7th postoperative day. Minor wound dehiscence and a small salivary leak occurred and resolved with conservative treatments.

Table 1 Patient characteristics and outcomes.

	Normal	Flap loss (total + partial)	Odds ratio (95% CI)	P value
Number	23	11	—	—
LOS (range, days)	14 (10–25)	19 (13–22)	—	—
T stage				
T2 (%)	6 (26.1)	6 (54.5)	1	0.112
T3 (%)	17 (73.9)	5 (45.5)	0.29 (0.07–1.33)	
N stage				
N0 (%)	15 (65.2)	3 (27.3)	1	0.046 ^a
N1, 2 (%)	8 (34.8)	8 (72.7)	5.0 (1.03–24.28)	
Type of neck dissection				
SND (%)	17 (73.9)	5 (45.5)	1	0.111
MRND (%)	6 (26.1)	6 (54.5)	3.4 (0.75–15.36)	

CI: confidence interval; LOS: length of stay; SND: selective neck dissection; MRND: modified radical neck dissection; ^a*P* < 0.05.

The IHF is suitable for repairing defects in the lower part of the oral cavity due to a relatively short pedicle length. The length of its pedicle based on the superior thyroid artery varies in the range 3–4 cm.⁹ However, with precise design of the skin paddle and proper pedicle orientation, the IHF can be placed vertically along the longitudinal axis so that the tip of the flap is capable of reaching a defect in the upper part of the oral cavity and oropharynx.¹⁰

The primary limitation is the inherent selection bias and confounders associated with a retrospective study. Flap viability and lymph node involvement were assessed by clinical examination. There might be some disparities in the assessments. Although surgical factors were minimized as only surgeries performed by a single surgeon were included, this advantage was hindered by the relatively small number of cases in this study.

Conclusion

IHF reconstruction was safe and fairly reliable in restoration procedures after oral cancer resection. Although the rate of skin flap loss was somewhat high, almost all complications were minor and resolved with conservative treatments. The flap procedure should be performed with caution in cases with gross lymph node involvement.

Conflicts of interest

None.

References

1. Wang HS, Shen JW, Ma DB, Wang JD, Tian AL. The infrahyoid myocutaneous flap for reconstruction after resection of head and neck cancer. *Cancer*. 1986;57:663–668.
2. Deganello A, Leemans CR. The infrahyoid flap: a comprehensive review of an often overlooked reconstructive method. *Oral Oncol*. 2014;50:704–710.
3. Minni A, Mascelli A, Suriano M. The infrahyoid myocutaneous flap in intra-oral reconstruction as an alternative to free flaps. *Acta Otolaryngol*. 2010;130:733–738.
4. Kruse AL, Luebbbers HT, Obwegeser JA, Bredell M, Grätz KW. Evaluation of the pectoralis major flap for reconstructive head and neck surgery. *Head Neck Oncol*. 2011;3:12.
5. Peng H, Wang SJ, Yang X, Guo H, Liu M. Infrahyoid myocutaneous flap for medium-sized head and neck defects: surgical outcome and technique modification. *Otolaryngol Head Neck Surg*. 2013;148:47–53.
6. Magrin J, Kowalski LP, Santo GE, Waksman G, DiPaula RA. Infrahyoid myocutaneous flap in head and neck reconstruction. *Head Neck*. 1993;15:522–525.
7. Meguid EA, Agawany AE. An anatomical study of the arterial and nerve supply of the infrahyoid muscles. *Folia Morphol (Warsz)*. 2009;68:233–243.
8. Ouyang D, Su X, Chen WC, Chen YF, Men QQ, Yang AK. Anatomical study and modified incision of the infrahyoid myocutaneous flap. *Eur Arch Otorhinolaryngol*. 2013;270:675–680.
9. Laxmi V, Kaur K, Chhabra P. Superior thyroid artery: its origin, length, relations and branches. *Int Ann Med*. 2017;1(4).
10. Gangloff P, Deganello A, Lacave ML, et al. Use of the infrahyoid musculo-cutaneous flap in soft palate reconstruction. *Eur J Surg Oncol*. 2006;32:1165–1169.

Edited by Yi Fang